



rainbow

LABORATORIES

152-R, Model Town, Panipat
Your Own Trusted Lab



Pathology Report

Lab. No.	: 26053	Date	: 23/Mar/2024
Patient Name	: Mr. PRAVESH	UHID	: 140044
Age/Gender	: 29 Years/M	Sample Date & Time	: 23/Mar/2024 10:04 OPD No. : 2825
Referred By	: self	Reporting Date & Time	: 23/3/24

Test Name	Observed Values	Biological Ref. Range
-----------	-----------------	-----------------------

HEMATOLOGY

CBC (Complete Blood Count)

HAEMOGLOBIN	15.4	12.0 - 18.0 %
TLC	7560.0	4000.0 - 11000.0 /cumm
DIFFERENTIAL LEUCOCYTE COUNT (DLC)		
POLYMORPHS	49.1	40.0 - 70.0 %
LYMPHOCYTES	42.3	20.0 - 40.0 %
MONOCYTES	4.0	2.0 - 10.0 %
EOSINOPHILS	4.6	1.0 - 6.0 %
BASOPHIL	0.0	0.0 - 1.0 %
PCV	44.0	40.0 - 54.0 %
MCV	84.6	76.0 - 96.0 femtoliter
MCH	29.6	27.0 - 32.0 picogram
MCHC	35.1	30.0 - 35.0 gm/dl
RBC COUNT	5.2	4.5 - 6.5 mill/cumm
PLATELET COUNT	2.50	1.50 - 4.00 lacs/cumm

***** End of Report *****

Handwritten signature/initials

Handwritten signature

Dr. Abhishek Khara
MBBS, MD Pathology

Dr. Sunilana Garg
MBBS, MD Microbiology

Dr. Vinika Arora
MBBS, MD Pathology



rainbow

LABORATORIES

152-R, Model Town, Panipat
Your Own Trusted Lab



Pathology Report

Lab. No.	: 26053	Date	: 23/Mar/2024
Patient Name	: Mr. PRAVESH	UHID	: 140044
Age/Gender	: 29 Years/M	Sample Date & Time	: 23/Mar/2024 10:04 OPD No. : 2825
Referred By	: self	Reporting Date & Time	: 23/3/24

Test Name	Observed Values	Biological Ref. Range
-----------	-----------------	-----------------------

BIOCHEMISTRY

<u>B Sugar (F)</u>	108.40	70.00 - 110.00 mg/dl
--------------------	--------	----------------------

HEMATOLOGY

BLOOD GROUP & RH

Blood Group	A
RH Typing	Positive

<u>ESR (WESTERGRENS)</u>	24	02-20
mmhg		

***** End of Report *****

Signature

Signature

Dr. Abhishek Khara
MBBS, MD Pathology

Dr. Suniana Garg
MBBS, MD Microbiology

Dr. Vinika Arora
MBBS, MD Pathology



rainbow

LABORATORIES

152-R, Model Town, Panipat
Your Own Trusted Lab



Pathology Report

Lab. No.	: 26053	Date	: 23/Mar/2024
Patient Name	: Mr. PRAVESH	UHD	: 140044
Age/Gender	: 29 Years/M	Sample Date & Time	: 23/Mar/2024 10:04 OPD No. : 2825
Referred By	: self	Reporting Date & Time	: 23/3/24

Test Name	Observed Values	Biological Ref. Range
-----------	-----------------	-----------------------

CLINICAL

URINE Routine & Microscopy

VOLUME	20ml	
COLOUR	P.YELLOW	P.YELLOW
SPECIFIC GRAVITY	1.014	1.003-1.035
APPEARANCE	Clear	
PH	Acidic	4.7-7.5
URINE GLUCOSE	Nil	
URINE PROTEIN	Nil	
EPITHELIAL CELLS	Nil	2-3
PUS CELLS	0-1	2-3
RBCS	NIL	NIL
CAST	NIL	NIL
CRYSTAL	NIL	NIL
OTHER	NIL	NIL

***** End of Report *****

Dr. Abhishek Khera
MBBS, MD Pathology

Dr. Suniana Garg
MBBS, MD Microbiology

Dr. Vinika Arora
MBBS, MD Pathology

NOT FOR MEDICO-LEGAL PURPOSE. Histopathology/ Cytology diagnosis is based upon subjective interpretation of Findings. Opinion may vary. Slides in doubtful cases may be reviewed from some teaching institution. Slides, Specimens and Blocks are discarded after 6 months. Result may vary & depend on quality, timings & methods of collection of sample.

For Home Collection (M) : 93060-38690



Scanned with OKEN Scanner



rainbow **LABORATORIES**

152-R, Model Town, Panipat
Your Own Trusted Lab



Reg. No. SHCO-2020-0389
A full NABH Accredited Hospital

THYROID PROFILE

Name: Mr.Pravesh	Age: 29 Years	Sex: male
Date of sample collection: 23-03-2024		Date of Reporting : 23-03-2024

TEST	VALUE OBSERVED	NORMAL RANGE
T3,TOTAL	1.17	0.69-2.15 ng/ml
T4,TOTAL	7.33	5.20-12.70 ug/dl
TSH	1.62	0.30 - 4.50 nIU/ml

Note:-

- In primary hypothyroidism, TSH levels are significantly raised, but in secondary & tertiary hypothyroidism TSH levels may be low.
- In primary hypothyroidism, TSH levels are increased.
- Low T3,T4 with elevated TSH indicate hypothyroidism.
- High T3,T4 with low TSH indicate hyperthyroidism.
- Kindly correlate clinically.

Dr. Abhishek Kherra
MBBS, MD Pathology

Dr. Suniana Garg
MBBS, MD Microbiology

Dr. Vinika Arora
MBBS, MD Pathology



rainbow **LABORATORIES**

152-R, Model Town, Panipat
Your Own Trusted Lab



Pathology Report

Lab. No. : 26053 Date : 23/Mar/2024
 Patient Name : Mr. PRAVESH UHID : 140044
 Age/Gender : 29 Years/M Sample Date & Time : 23/Mar/2024 10:04 OPD No. : 2825
 Referred By : self Reporting Date & Time : 23/3/24

Observed Values /Biological Ref. Range

BIOCHEMISTRY

KFT

BUN	9.06	6-20 mg/dl
BLOOD UREA	21.76	15-45
CREATININE	0.73	0.7 - 1.4
URIC ACID	3.70	3.4 - 7.4
SODIUM	139.1	135 - 155
POTASSIUM	3.80	3.5 - 5.5

NOTE: KFT includes a group of blood tests to determine the functioning of kidneys. It is advised in symptoms such as puffiness around eyes, bloody urine etc and also as a part of routine health check up

***** End of Report *****



Scanned with OKEN Scanner

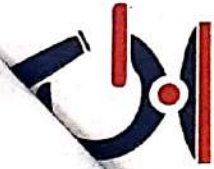Handwritten signature

Handwritten signature: Vinika

Dr. Abhishek Khera
MBBS, MD Pathology

Dr. Suniana Garg
MBBS, MD Microbiology

Dr. Vinika Arora
MBBS, MD Pathology



rainbow **LABORATORIES**

152-R, Model Town, Panipat
Your Own Trusted Lab



Reg. No. SHCO-2020-0369
A full NABH Accredited Hospital

Pathology Report

Lab. No.	: 26053	Date	: 23/Mar/2024
Patient Name	: Mr. PRAVESH	UHID	: 140044
Age/Gender	: 29 Years/M	Sample Date & Time	: 23/Mar/2024 10:04 OPD No. : 2825
Referred By	: self	Reporting Date & Time	: 23/3/24
Test Name	Observed Values <u>Biological Ref. Range</u>		

BIOCHEMISTRY

<u>LFT</u>	Observed Values	Biological Ref. Range
ALBUMIN gm/dl	3.91	3.4-5.4
SERUM GLOBULIN	3.19	2.0-3.5
Total Bilirubin	0.60	0.1-1.2
Direct Bilirubin	0.13	0.0-0.3
Indirect Bilirubin	0.47	0.1-1.0
SGPT	27.30	5-40
SGOT	19.40	8-37
ALP	169.7	60-170
Total Proteins	7.10	6.0-8.3

***** End of Report *****



Scanned with OKEN Scanner

Amey

Vinika

Dr. Abhishek Khera
MBBS, MD Pathology

Dr. Suniana Garg
MBBS, MD Microbiology

Dr. Vinika Arora
MBBS, MD Pathology



rainbow

LABORATORIES

152-R, Model Town, Panipat
Your Own Trusted Lab



Pathology Report

Lab. No.	: 26053	Date	: 23/Mar/2024
Patient Name	: Mr. PRAVESH	UHID	: 140044
Age/Gender	: 29 Years/M	Sample Date & Time	: 23/Mar/2024 10:04 OPD No. : 2825
Referred By	: self	Reporting Date & Time	: 23/3/24

Test Name	Observed Values	Biological Ref. Range
-----------	-----------------	-----------------------

BIOCHEMISTRY

LIPID PROFILE

CHOLESTROL TOTAL	181.90	60.00 - 230.00 mg /dl
TRIGLYCERIDE	119.7	25.0 - 160.0 mg /dl
HDL CHOLESTROL	39.15	35.00 - 70.00 mg /dl
VLDL CHOLESTROL	23.94	14.00 - 34.00 mg /dl
LDL CHOLESTROL	118.80	60.00 - 160.00 mg /dl
TOTAL /HDL RATIO	4.64	4.00 - 5.00 -----
LDL/HDL RATIO	3.03	

***** End of Report *****

Dr. Abhishek Khara
MBBS, MD Pathology

Dr. Suniana Garg
MBBS, MD Microbiology

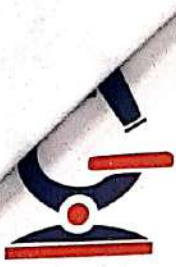Dr. Vinika Arora
MBBS, MD Pathology

NOT FOR MEDICO-LEGAL PURPOSE. Histopathology/ Cytology diagnosis is based upon subjective interpretation of Findings. Opinion may vary. Slides in doubtful cases may be reviewed from some teaching institution. Slides, Specimens and Blocks are discarded after 6 months. Result may vary & depend on quality, timings & methods of collection of sample.

For Home Collection (M) : 93060-38690



Scanned with OKEN Scanner



rainbow LABORATORIES

152-R, Model Town, Panipat
Your Own Trusted Lab



Pathology Report

Lab. No.	: 26053	Date	: 23/Mar/2024
Patient Name	: Mr. PRAVESH	UHID	: 140044
Age/Gender	: 29 Years/M	Sample Date & Time	: 23/Mar/2024 10:04 OPD No. : 2825
Referred By	: self	Reporting Date & Time	: 23/3/24
Test Name		Observed Values	Biological Ref. Range

Urine Examination

urine for suger fasting

Nil

***** End of Report *****

Dr.

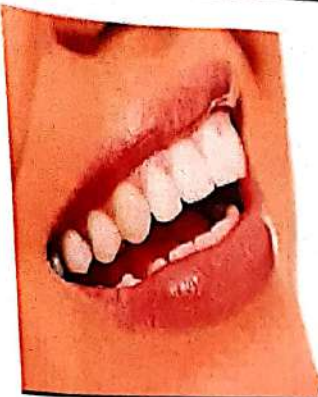Dr. Abhishek Khara
MBBS, MD Pathology

Dr. Suniana Garg
MBBS, MD Microbiology

Vinika

Dr. Vinika Arora
MBBS, MD Pathology





DENTAL STUDIO

194-L, Model Town, Panipat 132 103 (Haryana)

Ph. : 0180 - 4017707
89302-27707



Here Smile is Customized

Dr. Mansi Chawla
BDS. MIDA
Smile Designer
Ex. Deen Dayal Upadhyay (Delhi)

Timing : Morning : 10:00 AM to 2:00 PM
Evening : 4:00 PM to 7:30 PM

Dedicated Dental Team

Dr. Apoorva Bowry

BDS. MDS, MIDA
Conservative Dentistry & Endodontics

Dr. S.K. Yadav

BDS. MDS
Consultant Orthodontist
Wires & Braces Specialist

Dr. Babita Ahlawat

BDS. MDS
Pedodontics & Preventive Dentistry

Dr. Sakshi Goel

BDS. MDS
Consultant Periodontist
Gums & Pyorrhea Specialist

Facilities Available

- Root Canal Treatment
रूट कॅनल ट्रीटमेंट
- Dental Implants
डेंटल इम्प्लांट
- Tooth Whitening
दांतों की वाइटनिंग
- Fixed & Removable Denture
फिक्सड और हटाने योग्य डेन्चर
- Crown & Bridges
क्राउन और ब्रिज
- Wires & Braces
टेढ़े-मेढ़े दांतों का इलाज
- Gums Treatment
मसूड़ों की समस्या
- Ultrasonic Scaling
दांतों की स्केलिंग
- Tooth Colored Filling
दांतों की कलर फिलिंग
- Painless Dentistry for Children
बच्चों के लिए दर्द रहित दंत
चिकित्सा

Patient's Name Pooresh Age/Sex 29/M Date 23/03/2024

H/o Allergy/ Disease

Pt. wants regular dental checkup.

O/E

- ①. Deep Class II caries $\frac{5}{1}$
- ②. Deep Class I caries $\frac{7}{1}$
- ③. Impacted $\frac{8}{8}$
- ④. Missing $\frac{6}{1}$
- ⑤. Calculus ++

Adv

- ①. IOPA it $\frac{7}{5}$
- ②. Extraction it $\frac{8}{8}$
- ③. Replacement of missing tooth.
- ④. Oral prophylaxis.

Apoorva

Not for Medical Legal use
Please take appointment on Phone



GUPTA EYE HOSPITAL LLP LASIK LASER CENTRE DR. ISHA'S APEX PATH LAB



AN ISO 9001:2015 CERTIFIED HOSPITAL & LAB

332-R, MODEL TOWN, NEAR LAL TANKI MARKET, PANIPAT-132 103 (HARYANA)

Dr. B. K. Gupta

M.B.B.S., M.S. (Ophthal), F.I.A.M.S.
Ex. Resi. P.G.I., Chandigarh
Phaco, Glaucoma & Squint Surgeon
97281-00332

Dr. Kanav Gupta

M.B.B.S., M.S. (Ophthal), F.V.R.
Fellow Vitreo Retina (Rajiv Gandhi Univ.)
Ex. VR Surgeon, Centre for Sight, Delhi
Phaco, Retina & LASIK Surgeon
97285-00332

Prof. (Dr.) Isha Gupta

M.B.B.S., M.D. (Pathology)
M.U.H.S., Nashik
Consultation : 5-8 pm
0180-4011150

Name	PRAVESH	UID	8398985957A	OPD Regn No.	193255
Age/Sex	29 M	Ref. By		Dated	23-Mar-24 at 13:33
Category	General -			Amount Recd	0.00

C/o & Initial Assessment

MEDICAL CHECK UP
COLOUR VISION NORMAL

Diagnosis :

RE : : NAD (NO ABNORMALITY DETECTED)

LE : .

VA RE : 6/6

VA LE : 6/6



EYE SERVICES

Cataract :

- Phaco by Centurian Vision System
सफेद मोलिये का आप्रेशन

LASIK Laser (Zeiss Germany) :

- चश्मा हटाने का लेजर

Retina Clinic :

- FFA/OCT
- OCT Angio - Dyeless, Painless, Injectionless
Angiography of Eye
- ROP Screening
- Green Laser / पर्दे का ईलाज

Cornea Clinic :

- OCT/Pentacam/Topography - For High
Resolution Imaging of Complete Cornea
- C3R - Corneal Collagen Crosslinking for
Keratoconus

Dry Eye Clinic :

- IDRA - For Dry Eye Diagnosis & Evaluation
- IRPL - Pulse Laser Therapy for Dry Eye

Glaucoma Clinic :

- Perimetry, OCT-RNFL
- NCT, GAT

PATH LAB SERVICES

- Fully Computerised
- Hematology
- Clinical Pathology
- Biopsy
- Cytology
- Biochemistry

Preventive Care : Save Eyes from Dust

Diet Advised : Normal / Diabetic

Pain Score :

HOSPITAL TIMINGS

9.30 am to 1.00 pm, 5.00 pm to 7.00 pm

Sunday : 10.00 am to 12.00 noon

Revisit after 5 days on 28-Mar-2024 or before, if any problem.

...Dr B. K. Gupta
(Regn. No. HN 1428)

Dr. B.K. GUPTA
M.B.B.S., M.S. (Ophthalmology)
GUPTA EYE HOSPITAL -LLP
332-R, Model Town, Panipat
REG. No. HN-1428

For Appointment : 97285-00332

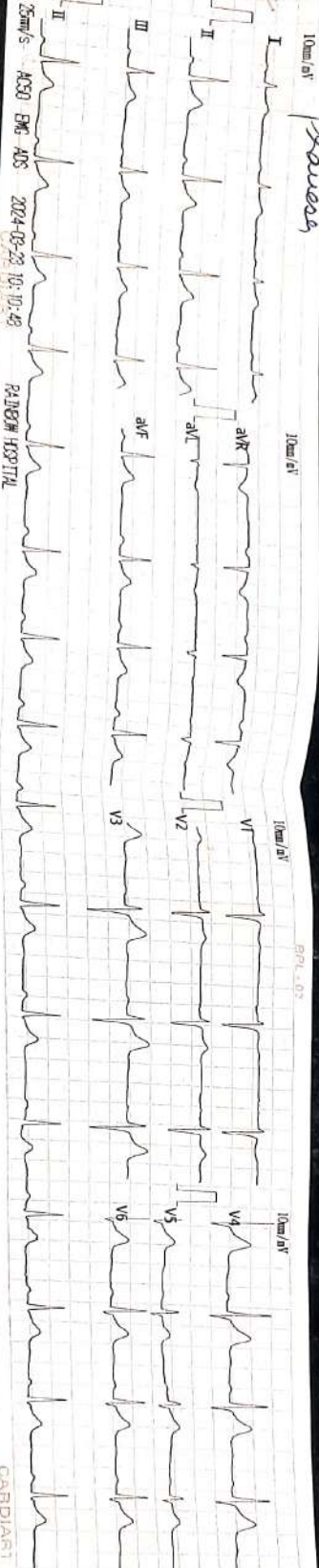
Find us on Google : Gupta Eye Hospital & Apex Path Lab

www.guptaeyehospital.com

This is Professional Opinion only ■ Not valid for Medico Legal Purpose ■ On Panel of Govt. & Private Corporates, Major TPAs & Insurance Companies



Pravara



VEC: Rhythmic: 64
 PR Interval: 172 99 166
 P/QRS/T Axis: 129 385
 QT/QTc Interval: 370 385
 P/QRS/T Axis: 51 70 78
 RV1/SV1 Amplitude: 0.13 0.19
 RV1/SV1 Amplitude: 0.38 0.52

V2 21 Technician:

Note: Unchecked Report Need to Review

CARDIAC
 QRMESH
 5398000066 N 29Y
 17/05 07/16
 17/05 07/16


rainbow
HOSPITAL
152-R, Model Town, Panipat
Ph. 0180-2650142

Mark of Excellence

Reg. No. SHCO-2020-0369
A full NABH accredited hospital

23/3/24

Ravesh
29/1/24

HK-64
- Sinus Aethymia

RAINBOW HOSPITAL
152-R, Model Town,
Panipat, Haryana



FACILITIES AVAILABLE

- General Medicine
- Gynecology
- Obstetrics
- General Surgery
- Laparoscopic Surgery
- General Pediatrics
- New Born ICU
- Pediatric Surgery
- Diagnostics
- Infertility



भारत सरकार
GOVERNMENT OF INDIA



प्रावेश

Pravesh

जन्म तिथि/DOB: 11/05/1994

पुरुष/ MALE



7378 7969 3386

VTD : 9116 5936 9369 7126

मेरा आधार, मेरी पहचान

Pravesh



भारतीय विशिष्ट पहचान प्राधिकरण
UNIQUE IDENTIFICATION AUTHORITY OF INDIA

पता:
S/O: ईश्वर सिंह, बजाना खुर्द (१२५), सोनीपत,
हरियाणा - 131102
Address :
S/O: Ishwar Singh, Bajana Khurd
(125), Sonipat,
Har yana - 131102



7378 7969 3386

VTD:-9116-5936-9369-7126



1947
1800 300 1947

help@uidai.gov.in

www.uidai.gov.in

P.O. Box No.1947,
Bengaluru-560 001



DR. SAHIL GARG

MD RADIOLOGIST
PG DIP MSK ULTRASOUND (SPAIN)

DR. POOJA GARG

MD RADIOLOGIST
FELLOWSHIP IN WOMEN'S IMAGING

DR. VENUS GARG

MD RADIOLOGIST
PG DIP IN MSK ULTRASOUND (SPAIN)

NAME: PARVESH

AGE/SEX: 29 Y/M

DATE: 23.03.2024

EXAM: ULTRASOUND WHOLE ABDOMEN

LIVER: Normal in size, outline and echotexture. Margins are smooth and regular.

No focal intra-hepatic space occupying lesion detected.

Intra-hepatic biliary radicals are not dilated.

Intrahepatic vascular patterns are within normal limits.

Portal vein is normal in calibre.

GALL BLADDER: Well distended. Wall thickness is within normal limits. No luminal debris, calculus and mass seen. Pericholecystic fat planes are normal with no sign of pericholecystic fluid. Common bile duct is normal in calibre.

PANCREAS: The head and body of the pancreas are normal in size, outline and echopattern. No focal space occupying lesion seen. No definitive peripancreatic collection noted. Main pancreatic duct not dilated.

SPLEEN: Normal in size, outline and echotexture. No space occupying lesion is noted. Splenic hilum appears normal.

KIDNEYS: Both the kidneys are normal in size, shape, outline and location. Cortico- medullary differentiation is maintained. It shows normal cortical echogenicity.

Parenchymal thickness is normal. No focal lesion or calculus seen.

Central echogenic complexes have a normal appearance with no evidence of any hydronephrosis.

URETERS: No evidence of any obvious dilatation.

URINARY BLADDER: Well distended. Wall thickness is normal.

No evidence of any trabeculation, sacculation or diverticulation seen.

No intravesical debris, calculus or mass noted.

PROSTATE: Normal in size, outline and parenchymal echogenicity. No focal space occupying lesion seen.

RIGHT ILIAC FOSSA: No focal fluid collection or mass lesion in RIF. No obvious inflamed mesentery or bowel wall thickening seen. No probe tenderness noted. Appendix measures 4.5 mm in its outer diameter. No evidence of any significant free fluid or lymphadenopathy seen.

IMPRESSION:

- No significant abnormality detected.
Advised clinical correlation.



Dr. Venus Garg (MBBS, MD)
PG DIP MSK Ultrasound UCAM (SPAIN)
Consultant Radiologist
HMC No. HN22264

**Note: For any typographical error or discrepancy please back to get it corrected. Severe fatty liver or obese patient may obscure the findings. This is a professional opinion and not final diagnosis. All medical modalities have limitations. An inter-operator variations may be seen. Report should be interpreted in correlation with clinico pathological findings. Further imaging is recommended if clinically indicated. NOT VALID FOR MEDICO-LEGAL PURPOSE