



To,

The Coordinator,
Mediwheel (Arcofemi Healthcare Limited)
Helpline number: 011- 41195959

Dear Sir / Madam,

Sub: Annual Health Checkup for the employees of Bank of Baroda

This is to inform you that the following spouse of our employee wishes to avail the facility of Cashless Annual Health Checkup provided by you in terms of our agreement.

PARTICULARS OF HEALTH CHECK UP BENEFICIARY	
NAME	SANGITA PATTNAYAK
DATE OF BIRTH	25-06-1973
PROPOSED DATE OF HEALTH CHECKUP FOR EMPLOYEE SPOUSE	31-07-2021
BOOKING REFERENCE NO.	21S165836100001582S
SPOUSE DETAILS	
EMPLOYEE NAME	MR. PATTNAYAK SAROJ KUMAR
EMPLOYEE EC NO.	165836
EMPLOYEE DESIGNATION	SINGLE WINDOW OPERATOR A
EMPLOYEE PLACE OF WORK	BERHAMPUR, BADABAZAR
EMPLOYEE BIRTHDATE	04-09-1970

This letter of approval / recommendation is valid if submitted along with copy of the Bank of Baroda employee id card. This approval is valid from **28-07-2021** till **31-03-2022**. The list of medical tests to be conducted is provided in the annexure to this letter. Please note that the said health checkup is a **cashless facility** as per our tie up arrangement. We request you to attend to the health checkup requirement of our employee's spouse and accord your top priority and best resources in this regard. The EC Number and the booking reference number as given in the above table shall be mentioned in the invoice, invariably.

We solicit your co-operation in this regard.

Yours faithfully,

Sd/-

Chief General Manager
HRM Department
Bank of Baroda

(Note: This is a computer generated letter. No Signature required. For any clarification, please contact Mediwheel (Arcofemi Healthcare Limited))

bob 52219



भारत सरकार
Government of India



आधार

भारत सरकार
Government of India

भारतीय विशिष्ट पहचान प्राधिकरण
Unique Identification Authority of India

Enrollment No. : 0623/00851/39376

To
Sangita Pattnayak


08/01/2015

C/O: Saroj Kumar Pattnayak,
B 408, RAJARANI APPARTMENT, BERHAMPUR,
VTC: Brahmapur Sadar, PO: Gosaninugam,
Sub District: Brahmapur Sadar, District: Ganjam,
State: Odisha, PIN Code: 760003,
Mobile: 8353065255

22360756



KF223607562F1



आपका आधार क्रमांक / Your Aadhaar No. :

4897 1446 9721

मेरा आधार, मेरी पहचान



भारत सरकार
Government of India



आधार



Sangita Pattnayak
DOB: 25/06/1973
Female

08/01/2015


4897 1446 9721

मेरा आधार, मेरी पहचान

7000366538
1 April 2015



बैंक ऑफ़ बड़ौदा
Bank of Baroda



नाम
Name : SAROJ KUMAR PATTNAYAK

कार्यवाही क्र. क.
E.C. No. - 165836

Rathwa
उत्पादक प्राधिकारी
Issuing Authority

Saroj Kumar Patt Nayak
धारक हस्ताक्षर
Signature of Holder





New NEELACHALA HOSPITAL

A Promise for Life...

(AN ISO 9001 : 2008 CERTIFIED HOSPITAL)

NAME	Sangita Pattnayak	Age/Sex	48Yrs/F
Ref. By.	New Neelachala Hospital	EC No.	165836
Sample.Dt.	31-07-2021	Reporting Dt	02-08-2021

LIVER FUNCTION TEST (L.F.T)

<u>TEST</u>	<u>OBSERVED VALUE</u>	<u>UNIT</u>	<u>NORMAL VALUE</u>
Total Protein	6.6	g/dl	5.5 - 8.0
Albumin	4.6	g/dl	3.5 - 5.0
Globulin	2.0	g/dl	2.0 - 3.0
A/G Ratio	2.3		
S.G.O.T	24	IU/L	5 - 40
S.G.P.T	27	IU/L	5 - 50
G.G.T.P	25	mg/dl	15 - 40
Serum Bilirubin (Total)	0.5	mg/dl	0.3 - 1.0
(Direct)	0.1	mg/dl	0.0 - 0.3
(Indirect)	0.4	mg/dl	0.2 - 0.8
Alkaline Phosphate	127	IU/ML	60 - 170

Thyroid Test

<u>TEST</u>	<u>OBSERVED VALUE</u>	<u>UNIT</u>	<u>NORMAL VALUE</u>
T3	0.90	ng/mL	0.6 - 1.81
T4	9.15	ug/dl	4.61 - 14.94
TSH	3.56	IU/ml	0.35 - 5.5

<u>TEST</u>	<u>OBSERVED VALUE</u>	<u>UNIT</u>	<u>NORMAL VALUE</u>
HBA1C	5.0	%	below 6.0%-Normal Value 6.0%-7.0%-Good control 7.0%-8.0%-Fair Control 8.0%-10%-Unsatisfactory Control Above 10%-Poor Control

Swayam Prava Pradhan
Signature
MD Pathologist
Regd. No.9431

N. B. : THIS REPORT IS NOT MEANT FOR MEDICO LEGAL PURPOSE

KAMAPALI - GOILUNDI LINK ROAD, NEAR NANDIGHOSH APARTMENT, BERHAMPUR - 760 004 (ODISHA)
CELL : 9438251721, 9337859729



New
NEELACHALA HOSPITAL

A Promise for Life...

(AN ISO 9001 : 2008 CERTIFIED HOSPITAL)

NAME	Sangita Pattnayak	Age/Sex	48Yrs/F
Ref. By.	New Neelachala Hospital	EC No.	165836
Sample.Dt.	31-07-2021	Reporting Dt	02-08-2021

URINE ANALYSIS REPORT

PHYSICAL EXAMINATION


VOLUME	:	10 ML.
SPECIFIC GRAVITY	:	1.018 .
COLOUR	:	PALE YELLOW.
APPEARANCE	:	CLEAR.
TURBIDITY	:	ABSENT.
SEDIMENT	:	ABSENT.
REACTION	:	ACIDIC.

CHEMICAL EXAMINATION

ALBUMIN	:	ABSENT.
SUGAR	:	NIL.
PHOSPHATE	:	ABSENT.
ACETONE	:	ABSENT.
BILE SALT	:	ABSENT.
BILE PIGMENT	:	NEGATIVE.
UROBILINOGEN	:	ABSENT.
CHYLE	:	ABSENT.
HAEMATURIA	:	ABSENT.

MICROSCOPIC EXAMINATION

EPITHELIAL CELL	:	1 - 5/ H.P.F
PUS CELL	:	2 - 4 / H.P.F
R.B.C	:	NIL.
CAST	:	NIL.
CRYSTAL	:	NIL.
YEAST	:	ABSENT.
OTHERS	:	ABSENT


Swayam Prava Pradhan
MD Pathologist
Regd. No.9431

N. B. : THIS REPORT IS NOT MEANT FOR MEDICO LEGAL PURPOSE

KAMAPALI - GOILUNDI LINK ROAD, NEAR NANDIGHOSH APARTMENT, BERHAMPUR - 760 004 (ODISHA)
CELL : 9438251721, 9337859729



New
NEELACHALA HOSPITAL


A Promise for Life...

(AN ISO 9001 : 2008 CERTIFIED HOSPITAL)

NAME	Sangita Pattnayak	Age/Sex	48Yrs/F
Ref. By.	New Neelachala Hospital	EC No.	165836
Sample.Dt.	31-07-2021	Reporting Dt	02-08-2021

STOOL ANALYSIS REPORT

COLOUR	: -	Yellow
CONSISTENCY	: -	Pesty
REACTION	: -	Acidic
MUCUS	: -	Absent
BLOOD	: -	Absent
PARASITS	: -	Adequate
R.B.C.	: -	Not Seen
VEG.CELLS	: -	Present
STARCH	: -	Not Seen
MICROPHAGES	: -	Not Seen
FAT GLOBULES	: -	Not Seen
BACTERIAL FLORA	: -	Reduced.
YEAST/MOULDS	: -	Not Seen
SUGAR	: -	Not Seen
OVA/LARVA OF HELMINTUS	: -	Not Seen
CYST.VEG FORMS PROTOZOA	: -	Not Seen
OCCULT BLOOD	: -	Not Seen
PROTOZOA (Cysts/Trohozoites)	: -	Not Seen
HELMINTHES (Ova/Larva)	: -	Not Seen


Swayam Prava Pradhan
Signature
MD Pathologist
Regd. No.9431

N. B. : THIS REPORT IS NOT MEANT FOR MEDICO LEGAL PURPOSE

KAMAPALI - GOILUNDI LINK ROAD, NEAR NANDIGHOSH APARTMENT, BERHAMPUR - 760 004 (ODISHA)
CELL : 9438251721, 9337859729



New
NEELACHALA HOSPITAL

A Promise for Life...

(AN ISO 9001 : 2008 CERTIFIED HOSPITAL)

NAME	Sangita Pattnayak	Age/Sex	48Yrs/F
Ref. By.	New Neelachala Hospital	EC No.	165836
Sample.Dt.	31-07-2021	Reporting Dt	02-08-2021

BIOCHEMICAL TEST

<u>TEST</u>	<u>OBSERVED VALUE</u>	<u>UNIT</u>	<u>NORMAL VALUE</u>
Fasting Blood Sugar	85.2	mg/dl	70 - 110
Fasting Urine Sugar	0.4	mmol/L	0 - 0.8
2H PPBS	81	mg/dl	> 140
PP Urine Sugar	06	mg/dl	0 - 15
Serum Uric Acid	4.9	mg/dl	3.4 - 7.0
Serum Creatinine	0.9	mg/dl	0.0 - 1.2
Blood Urea Nitrogen	12.4	mg/dl	07 - 20
BUN Ratio	13.8		

LIPID PROFILE

<u>TEST</u>	<u>OBSERVED VALUE</u>	<u>UNIT</u>	<u>NORMAL VALUE</u>
Cholesterol	166	mg/dl	130 - 220
Triglycerides	136	mg/dl	50 - 160
HDL Cholesterol	53.8	mg/dl	35 - 70
LDL Cholesterol	85.0	mg/dl	60 - 130
VLDL	34	mg/dl	25 - 50
Cholesterol/HDL Ratio	3.08	mg/dl	< 4.5
LDL/HDL Ratio	1.58		

Signature
Swamy Prava Pradhan
MB Pathologist
Regd. No.9431

N. B. : THIS REPORT IS NOT MEANT FOR MEDICO LEGAL PURPOSE

KAMAPALI - GOILUNDI LINK ROAD, NEAR NANDIGHOSH APARTMENT, BERHAMPUR - 760 004 (ODISHA)
CELL : 9438251721, 9337859729

July 31, 2021
Time: 09:41:53

QT / QTc : 0.148 / 0.183 Sec
P-QRS-T Axis (54)-(5)-(22:1) deg

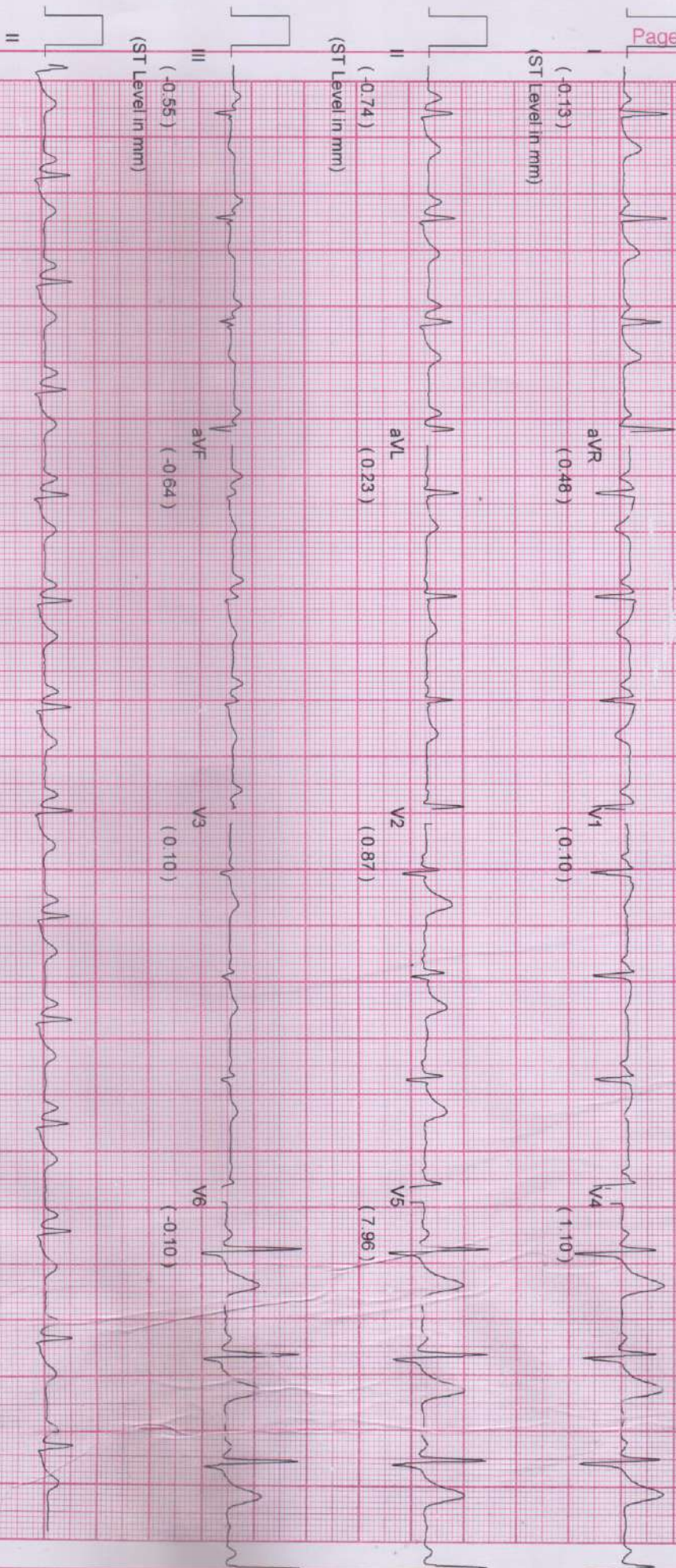
PR Interval: 0.15 sec
QRS Duration: 0.072 Sec

RR Interval: 0.55 sec

HR : 92 bpm

TP : 0.0 mmHg

Page No.



Comments :-

Suspected, towards QRS width

Normal QT Interval, QRS Axis normal
PR wave normal, lead I, II, III, aVR, aVL, aVF

Dr. Susanta Kumar Salla

Dr. S. K. Salla (M.D., D.M.)

(M.D.) D.M. Cardiology

M.K.C.G. Medical College, RAIPUR
25th/Sec NARSAN (C), Sim U - GBL U 4/31/13

Date:



New
NEELACHALA HOSPITAL

A Promise for Life...

(AN ISO 9001 : 2008 CERTIFIED HOSPITAL)

NAME	Sangita Pattnayak	Age/Sex	48Yrs/F
Ref. By.	New Neelachala Hospital	EC No.	165836
Sample.Dt.	31-07-2021	Reporting Dt	02-08-2021

HAEMOGRAM REPORT

<u>INVESTIGATION</u>	<u>RESULT</u>	<u>UNIT</u>	<u>NORMAL VALUE</u>
Hb%	: 12.8	gm%	(11.0 - 15.0 gm%)
TWBC	: 8200	Cumm	(4500-11000/ Cumm)
TRBC	: 4.2	Mill	(4.0- 5.5 Mill/ Cumm)
TPC	: 2.1	Lacs / Cumm	(1.5 - 4.0 Lacs / Cumm)
PCV	: 42	%	(35- 50%)
MCV	: 83	fl	(76 - 96 fl)
MCH	: 29.5	pg	(28 - 32 pg)
MCHC	: 31.5	%	(28 - 43%)
RDW (CV)	: 14.4	%	(13 - 16%)
MPV	: 8.7	fl	(8.0 - 10. 5 fl)
PDW	: 8.9	fl	(8.2 - 10.0 fl)

DIFFERENTIAL COUNT

<u>INVESTIGATION</u>	<u>RESULT</u>	<u>UNIT</u>	<u>NORMAL VALUE</u>
Neutrophil	68	%	40 - 70
Eosinophil	02	%	01 - 06
Basophil	00	%	00 - 01
Lymphocyte	25	%	15 - 40
Monocyte	05	%	02 - 10

<u>INVESTIGATION</u>	<u>RESULT</u>	<u>UNIT</u>	<u>NORMAL VALUE</u>
ESR	: 14	/mm in 1 st hour	05 - 20

Grouping

ABO Group & Rh Typing

"B" & Positive.

("B"+ve.)

Swayam Pradya Pradhan
Signature
MD Pathologist
Regd. No.9431

N. B. : THIS REPORT IS NOT MEANT FOR MEDICO LEGAL PURPOSE

KAMAPALI - GOILUNDI LINK ROAD, NEAR NANDIGHOSH APARTMENT, BERHAMPUR - 760 004 (ODISHA)
CELL : 9438251721, 9337859729



BHABANI DIAGNOSTIC CENTRE

Goilundi-Kamapalli Road,
Infront of Nandighos Apartment, Brahmapur
Mob. : 9078214639, 7008833151

PATIENT NAME : Mrs...SANGEETA PATTNAYAK AGE : 47 Yrs SEX: F

REFERRED BY : NEELANCHAL HOSPITAL DATE: 1-Aug-21....

ULTRASOUND EXAMINATION OF WHOLE ABDOMEN

LIVER:

Normal in size & measures 12.4 cm
Normal parenchymal echotexture. No focal lesion or IHBR Dilatation is seen.
P.V—normal.

GALL BLADDER:

Normal in shape and size with anechoic lumen.
Wall thickness is normal. CBD-normal.

PANCREAS:

Normal in size & outline. Parenchymal echo is normal. Pancreatic duct is not dilated.

KIDNEYS:

Rt. Kidney: Normal in shape and size-10.0x4.5 cm.
Parenchymal echogenicity is normal. Cortical thickness is normal.
Cortico medullary differentiation is well maintained.
Collecting system appears normal.

No evidence of calculus or any pathological abnormalities is seen.
Lt. Kidney: Normal in shape and size-9.8x4.5cm..
Parenchymal echogenicity is normal. Cortical thickness is normal.
Cortico medullary differentiation is well maintained.
Collecting system appears normal.
No evidence of calculus or any pathological abnormalities is seen.

SPLEEN:

Normal in size & measures 7.8 cm
Parenchymal echogenicity appears normal.

URINARY BLADDER:

Normal in outline. Wall thickness is normal. .

UTERUS:

Enlarged in size- 11.3x6.0x5.0 cm. Myometrial echotexture is normal
Endometrial thickness measure -5mm.

OVARIES:

Right ovary-2.0x1.2 cm.
Left ovary -2.0x1.3 cm..

Both ovaries show normal echotexture.
No fluid is seen in peritoneal cavity.

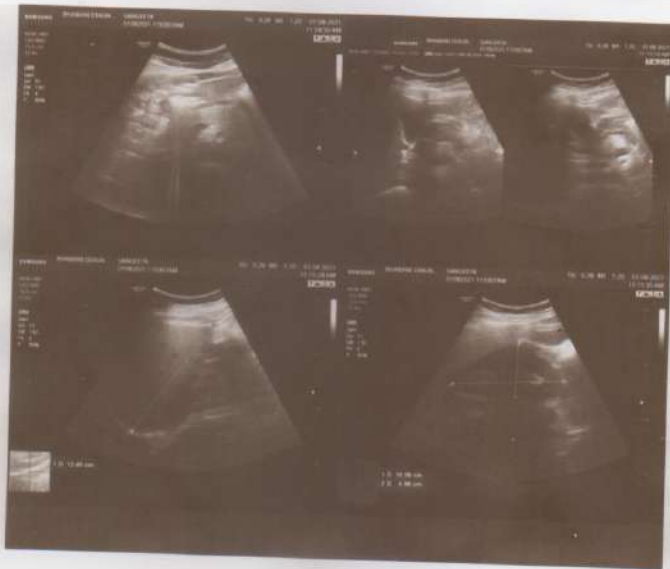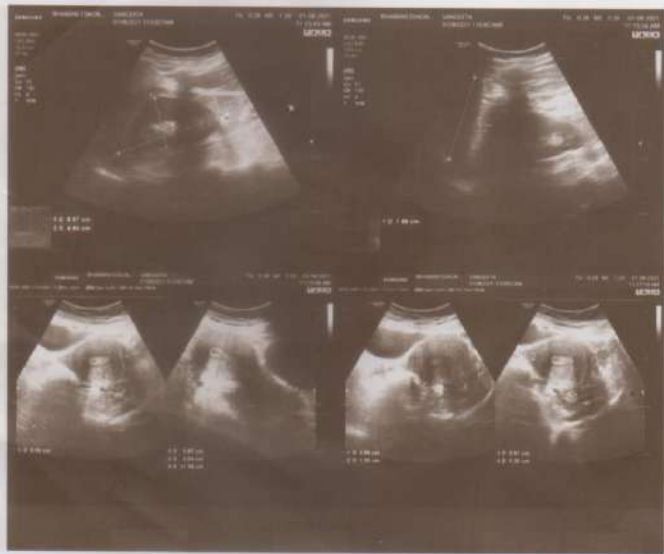IMPRESSION

- **BULKY UTERUS .**


DR. B. A. SUBUDHI, M.D
RADIOLOGIST

NB. : This report is not valid for medico legal purpose

ULTRA SOUND, DIGITAL X-RAY, VIDEO ENDOSCOPY, ECG, ALL PATHOLOGICAL INVESTIGATION DONE HERE



**BHABANI DIAGNOSTIC CENTRE**

Goilundi-Kamapalli Road,
Infront of Nandighos Apartment, Brahmapur
Mob. : 9078214639, 7008833151

PATIENT NAME : Mrs...SANGEETA PATTNAYAK AGE : 47 Yrs SEX: F

REFERRED BY : NEELANCHAL HOSPITAL DATE: 1-Aug-21....

RADIOGRAPH CHEST (PA VIEW)

- Trachea is central with normal para-tracheal shadows.
- Mediastinum is central in position and width.
- Cardiac silhouette appears normal in shape, size and position.
- Lung fields are adequately aerated with no active pulmonary parenchymal pathology detected.
- Both Hila are normal in position and density.
- Broncho pulmonary markings appear normal .
- Domes of Diaphragm appear normal in position and contour bilaterally.
- Both CP Angles appear clear.
- Soft tissues and bony cage of the thorax appear normal.

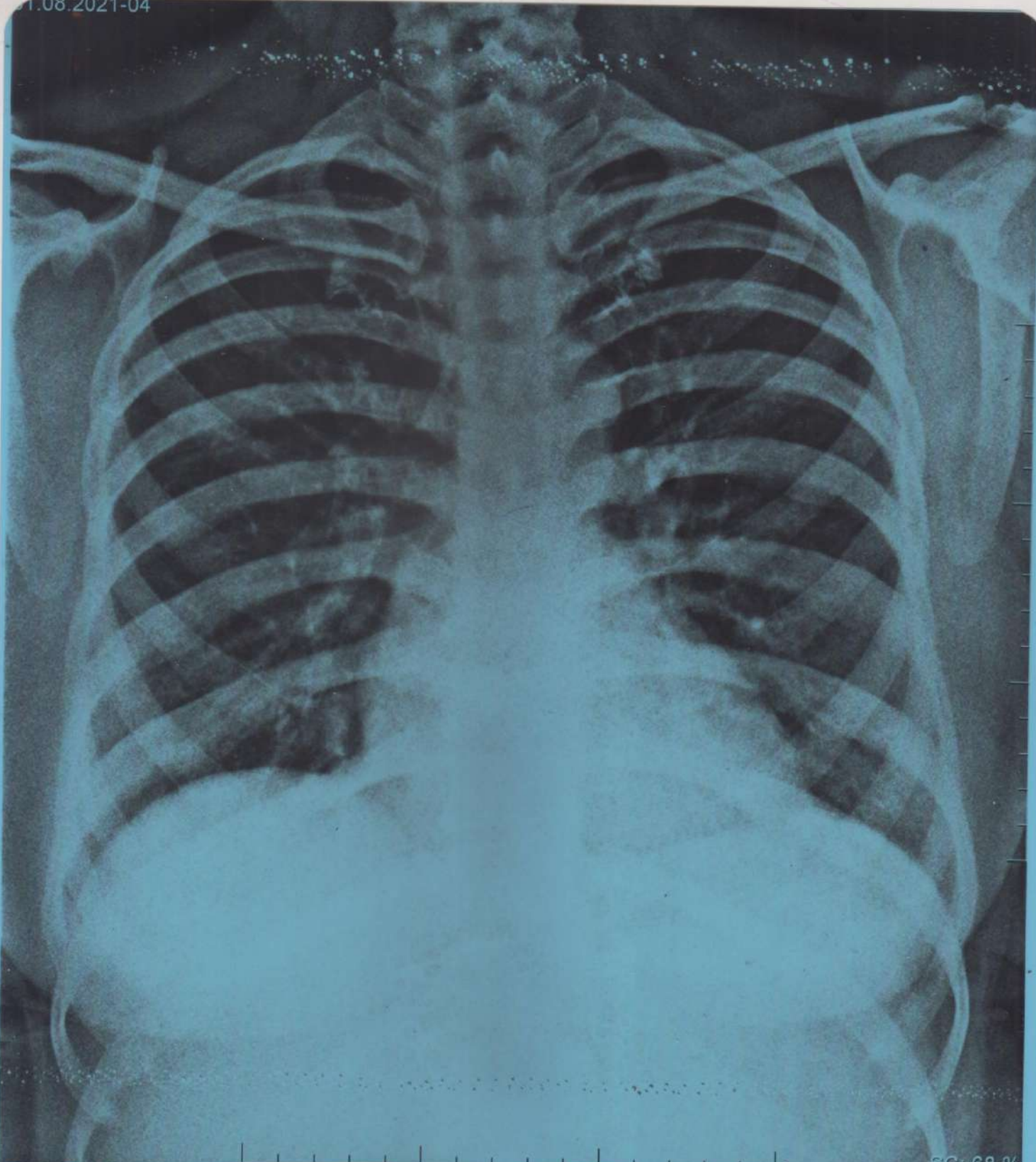
IMPRESSION

- **NO SIGNIFICANT ABNORMALITY DETECTED.**

**DR.B.A SUBUDHI,MD
CONSULTANT RADIOLOGIST**

Comparison –No old film available for comparison.

01.08.2021-04



SC: 68 %

01.08.2021-04 SANGITA PATTNAYAK , AGE-47 YEARS (NEELACHALA HOSPITAL)
FEMALE , X-RAY CHEST PA VIEW
2021.AUG.01
BHABANI DIAGNOSTIC CENTER, BERHAMPUR