



બંક ઝીરો સરોદા
Bank of Saroda

MD. RAIJUDDIN

97925



MD. RAJUDDIN

સહીકર્તા
Signature of Holder



MD. RAJUDDIN

MD. RAJUDDIN

મુદ્રિત સહી
મુદ્રિત સહી



Dr. Nitish Chandra

[Signature]
 Dr. NITISH CHANDRA
 Regn. No. D-24-1436

ONEPLUS ULTRASOUND LAB
 47 Harsh Vihar Pitampura
 Ph: 011-26101222
 E-mail: info@oneplusultrasound.com

ONEPLUS ULTRASOUND LAB

47, HARISH VIHAR, PITAMPURA, DELHI-110034

Mr. RAJUDDIN
Age: 41M
Ref By: MEDWHEEL
Indication1:
Indication2:
Indication3:
COMMENTS: Normal ECG

ID: 2313
HMM: 17/1/79
Recorded: 29-9-2023 11:51
Medication1:
Medication2:
Medication3:

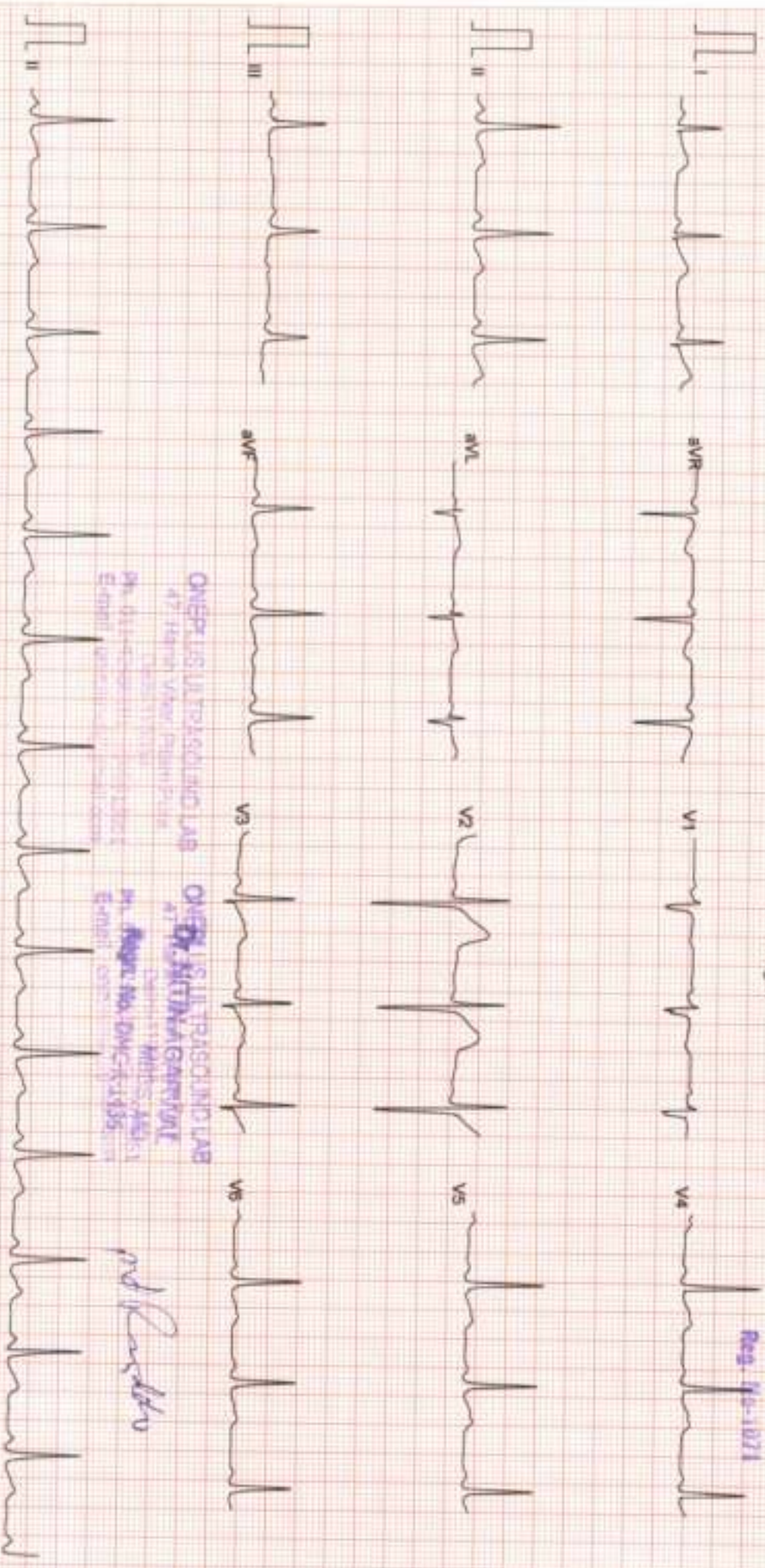
HRM : 98
BP : 136/96
P Axis : 63 deg
QRS Axis : 69 deg
T Axis : 24 deg

P duration : 96 msec
PR duration : 120 msec
QRS duration : 106 msec
QT interval : 310 msec
QTc interval : 358 msec

Uncertified Report Reviewed By:
Cardiologist

Raw E.C.G (Sec)

Dr. P. K. Sharma
Reg. No. 1071



ONEPLUS ULTRASOUND LAB
47 Harish Vihar, Pitampura,
Delhi-110034
Dr. Harish Vihar, Pitampura,
Delhi-110034

ONEPLUS ULTRASOUND LAB
Dr. P. K. Sharma
47 Harish Vihar, Pitampura,
Delhi-110034

Dr. P. K. Sharma

Filtered

Zimmersec 10mm/mV

CardiCom, INDIA

ONEPLUS ULTRASOUND LAB

47, HARSH VIHAR PITAMPURA DELHI 110034

Mr. RAJUDDIN
 Age/Sex : 41/M
 Ref by : MEDWHEEL
 Indication1 :
 Indication2 :
 Indication3 :

ID : 999
 H/W/M : 174/79
 Recorded : 29-9-2023 11:53

TREADMILL TEST SUMMARY REPORT
 Protocol: BRUCE
 History:
 Medication1 :
 Medication2 :
 Medication3 :

PHASE	PHASE TIME	STAGE TIME	SPEED (Km./Hr.)	GRADE (%)	H.R. (BPM)	B.P. (mmHg)	RPP X100	II	ST LEVEL (mm) V2	V5	METS
SUPINE											
STANDING											
STAGE 1	2:59	2:59	2.70	10.00	90	136/86	122	0.7	3.8	0.8	
STAGE 2	5:59	2:59	4.00	12.00	96	136/86	116	0.7	3.7	0.8	
STAGE 3	8:59	2:59	5.40	14.00	109	136/86	148	0.5	4.0	0.9	4.80
STAGE 4	9:44	0:44	6.70	16.00	121	146/88	176	0.8	4.5	0.7	7.10
PEAK EXER	9:47	0:47		16.00	142	160/90	227	0.2	4.5	0.7	10.00
RECOVERY	2:59	2:59	0.00	0.00	157	170/92	266	-0.3	4.5	0.1	10.98
					156	170/92	265	0.0	4.8	0.2	
					107	136/86	147	0.5	3.2	0.3	11.05

RESULTS
 Exercise Duration : 9:47 Minutes
 Max Heart Rate : 157 bpm 87 % of target heart rate 179 bpm
 Max Blood Pressure : 170/92 mmHg
 Max Work Load : 11.05 METS
 Reason of Termination : *Stop for all test*

Dr. P. K. Sharma
 Reg. (D.O.-101)
 Cardiologist

ONEPLUS ULTRASOUND LAB
 47 Harsh Vihar, Pitampura, Delhi
 Ph: 011-26141171, 261413051
 E-mail: oneplusultrasound@gmail.com

Dr. Rajuddin

ONEPLUS ULTRASOUND LAB

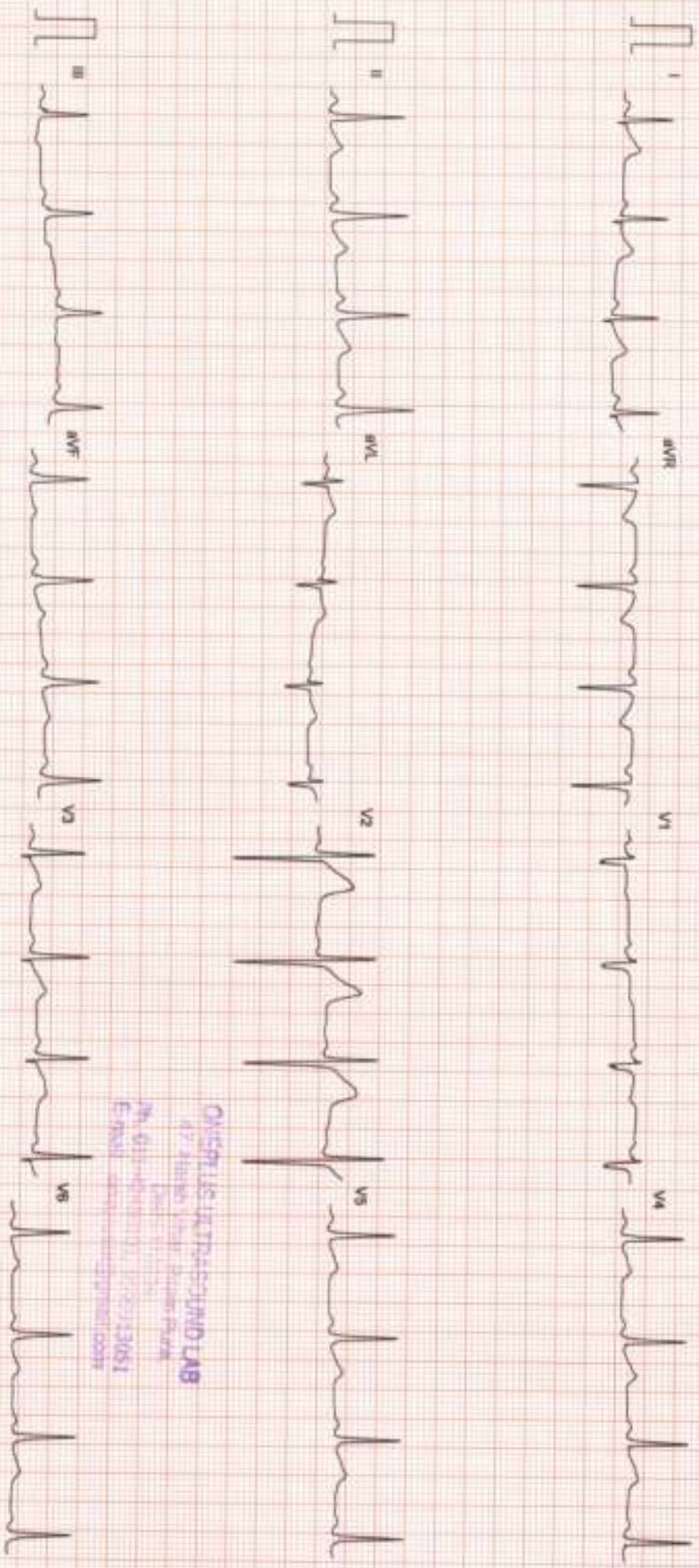
SUPINE
PRETEST

ST @ 10mm/mV
80ms PostU

Mr. RAJUDDIN
I.D. : 999
AGE/SEX : 41/M
RECORDED : 29-9-2023 11:53

RATE : 90 BPM
B.P. : 136/86 mmHg

RAW E.C.G



ONEPLUS ULTRASOUND LAB
47, Alwaro Road, Poonam Pally,
Durgam Cheruvu, Hyderabad,
Telangana, India - 500083
Ph: 01-731-2620740, 731-2431214
Email: oneplusultrasound@gmail.com

Filtered

25mm/sec 10mm/mV

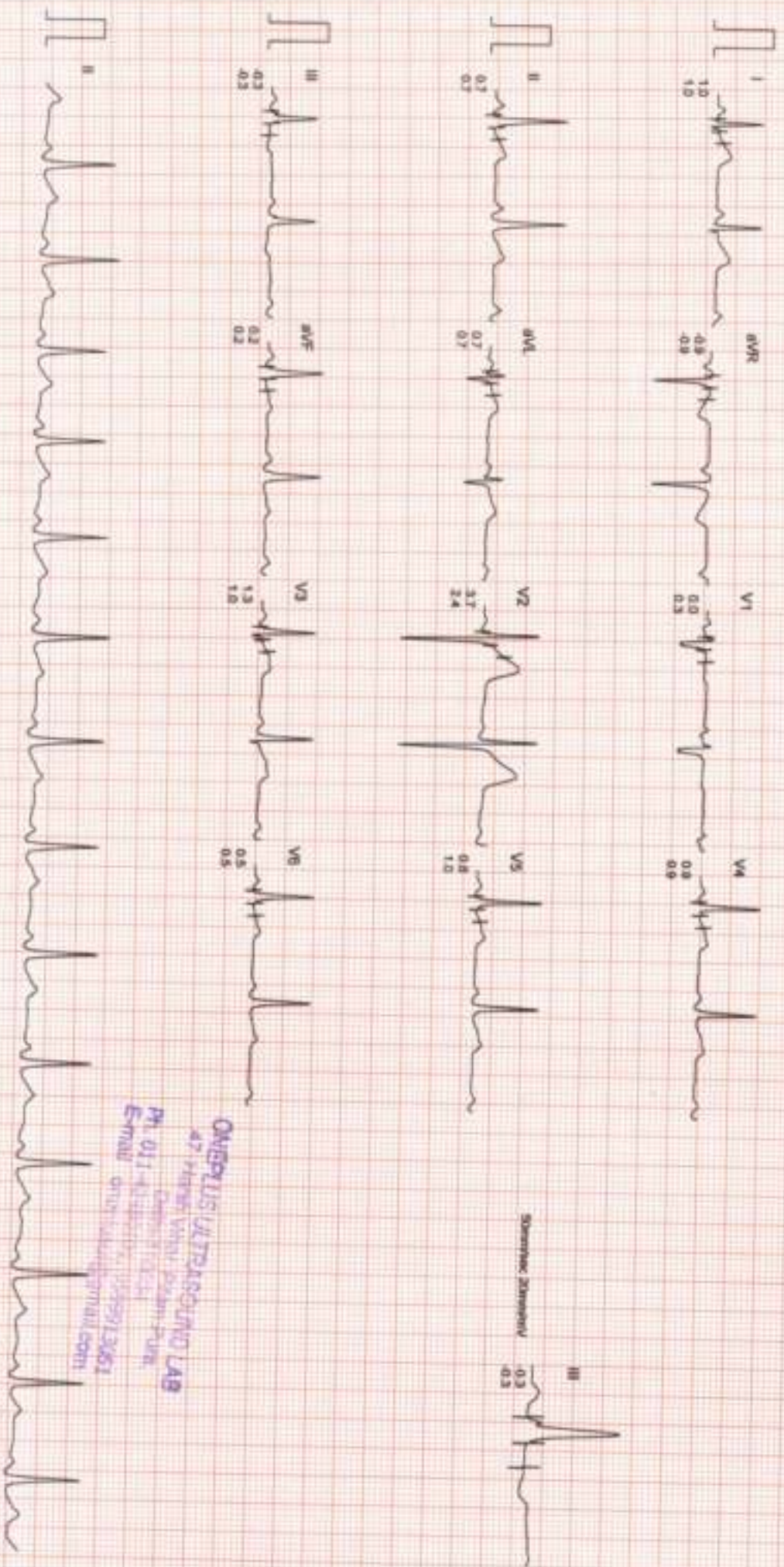
CardiCom, INDIA Ph. 091-731-2620740, Tihar' sec 091-731-2431214

ONEPLUS ULTRASOUND LAB

MR. RAJUDDIN
I.D. : 999
AGE/SEX : 41/M
RECORDED : 29-9-2023 11:53

ST @ 10mm/mV
80ms PostU

LINKED MEDIUM



ONEPLUS ULTRASOUND LAB
47 VIKAS VIHAR, JALAN PUNJ, CANTONMENT, CHENNAI
Ph: 011-43333333, 9959133601
Email: onepplusultrasound@gmail.com

ONEPLUS ULTRASOUND LAB

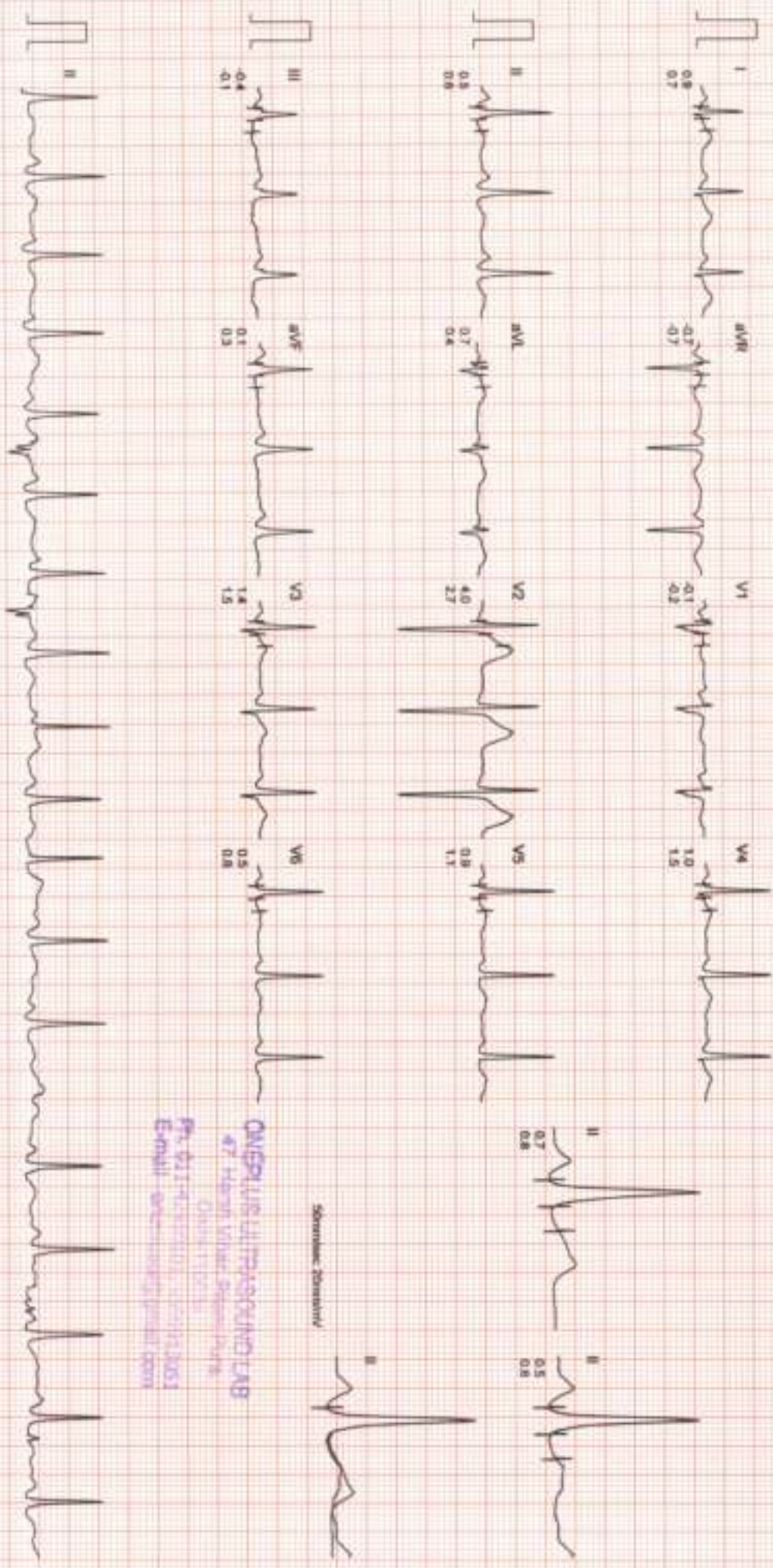
Mr. RAJUDDIN
ID : 999
AGE/SEX : 41/M
RECORDED : 29-9-2023 11:53

RATE : 109 BPM
B P : 136/86 mmHg

BRUCE
EXERCISE 1
PHASE TIME : 2:59
STAGE TIME : 2:59

ST @ 10mm/mV
80ms PostJ
SPEED : 2.7 Km./Hr.
GRADE : 10.0 %

LINKED MEDIAN



ONEPLUS ULTRASOUND LAB
47, Hiran Vihar, Sector-14, Gurgaon
Gurgaon, Haryana
Ph: 011-45320001, 45320002
E-mail: oneplus@oneplus.com

Shreehar Jaiswal

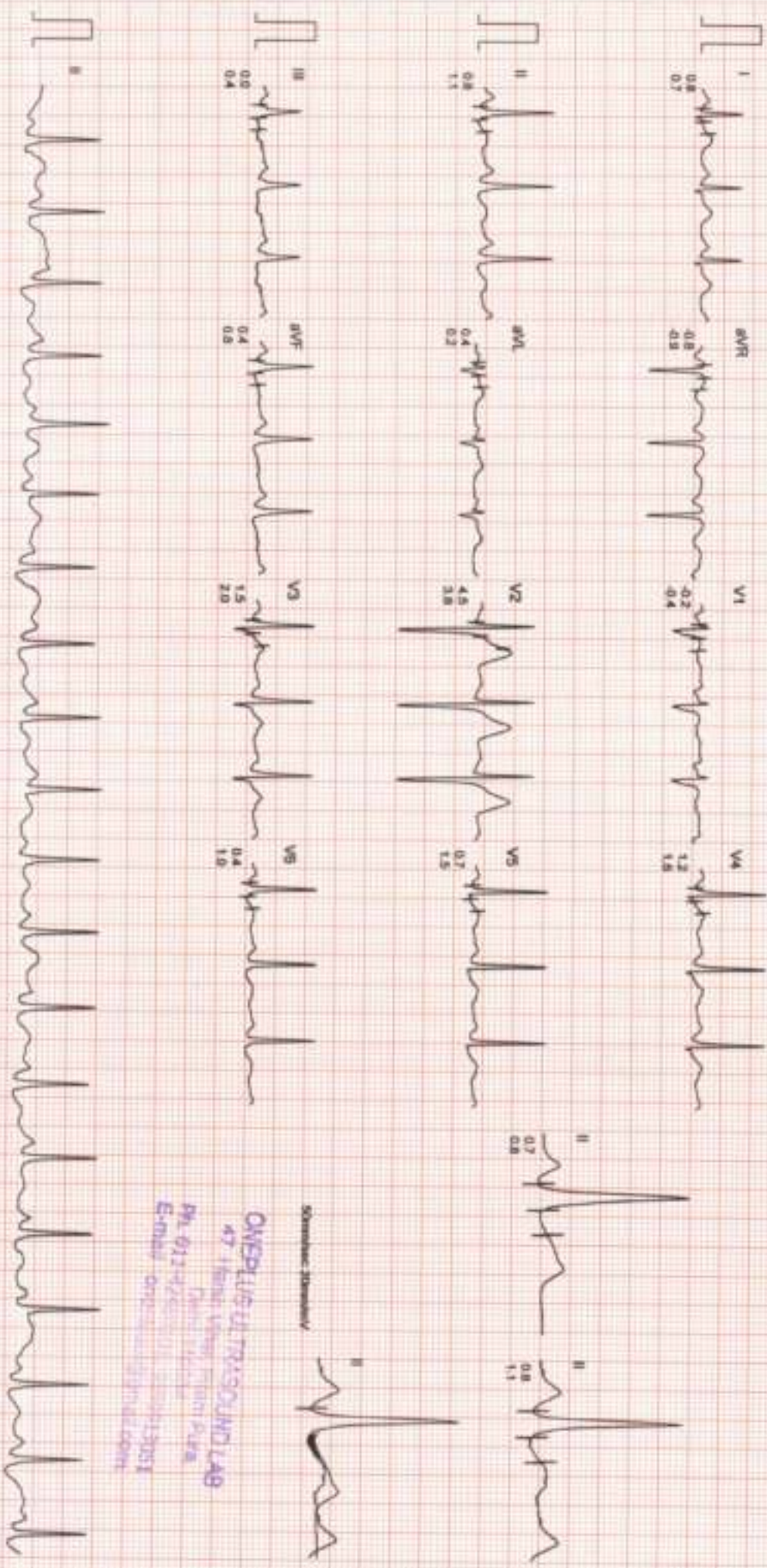
ONEPLUS ULTRASOUND LAB

Mr. RAJUDDIN
I.D : 999
AGE/SEX : 41/M
RECORDED : 29-9-2023 11:53

BRUCE
EXERCISE 2
PHASE TIME : 5:59
STAGE TIME : 2:59

ST @ 10mm/mV
80ms PostJ
SPEED : 4.0 Km./Hr.
GRADE : 12.0 %

LINKED MEDIAN



ONEPLUS ULTRASOUND LAB
47, 1st Floor, West, Rajinagar,
P.O. 612 02, Chennai, Tamil Nadu.
E-mail: onepplusultrasound.com

Filtered Computer Corrected Baseline

Zoom/Speed 10mm/mV

Cardicom, INDIA Ph: 091-731-2620740, T: 0647-96-091-731-2431214

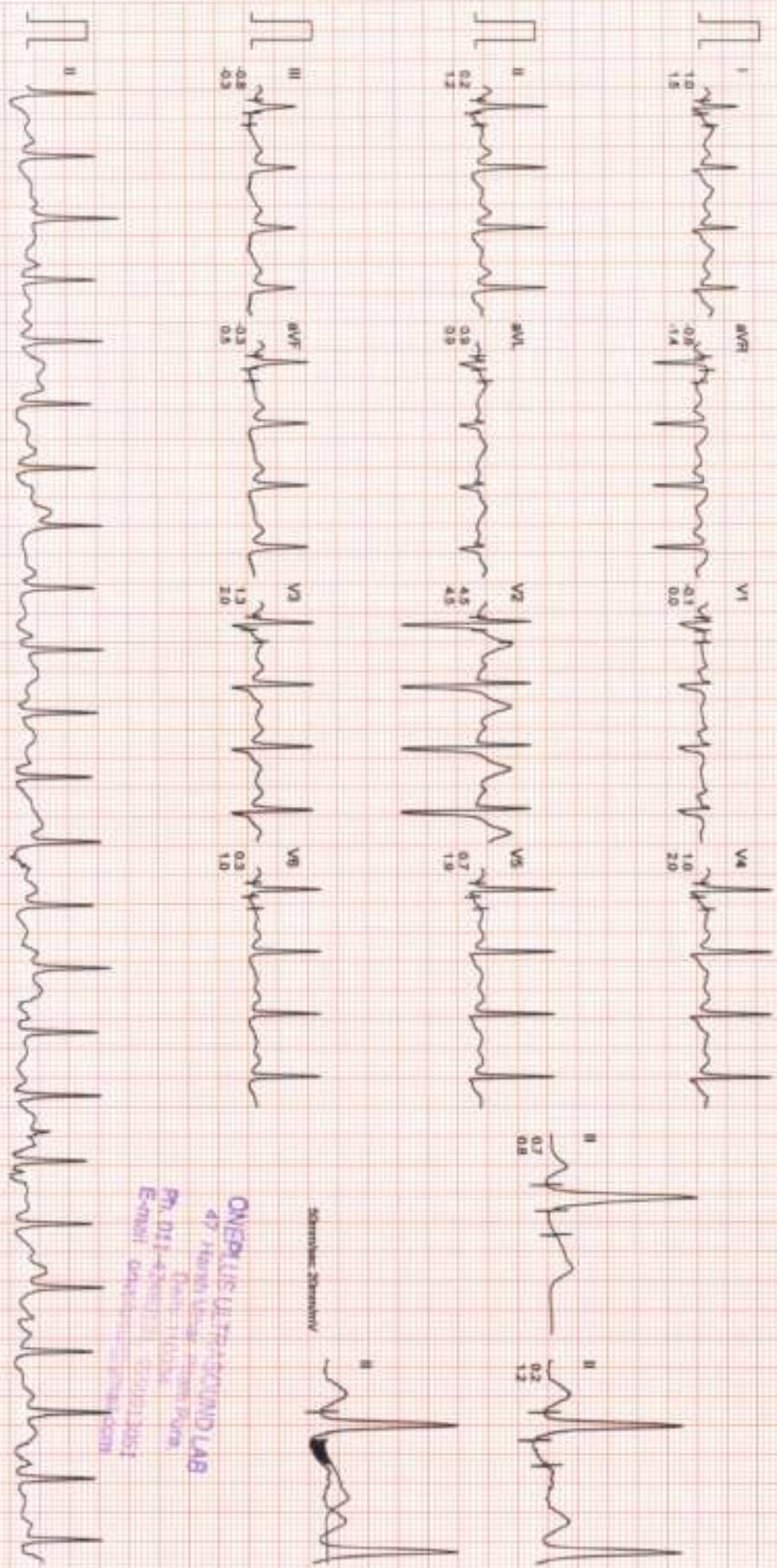
ONEPLUS ULTRASOUND LAB

MR. RAJUDDIN
I.D : 999
AGE/SEX : 41/M
RECORDED : 29-9-2023 11:53

BRUCE
EXERCISE 3
PHASE TIME : 8:59
STAGE TIME : 2:59

ST @ 10mm/mV
80ms PostJ
SPEED : 5.4 Km./hr.
GRADE : 14.0 %

LINKED MEDIAN



Standard: 25mm/mV

ONEPLUS ULTRASOUND LAB
47, HANMANTEMBAH STREET, RAJIV
GANDHI NAGAR,
SRINAGAR, JAMMUSHIR
E-MAIL: oneplusultrasound@gmail.com

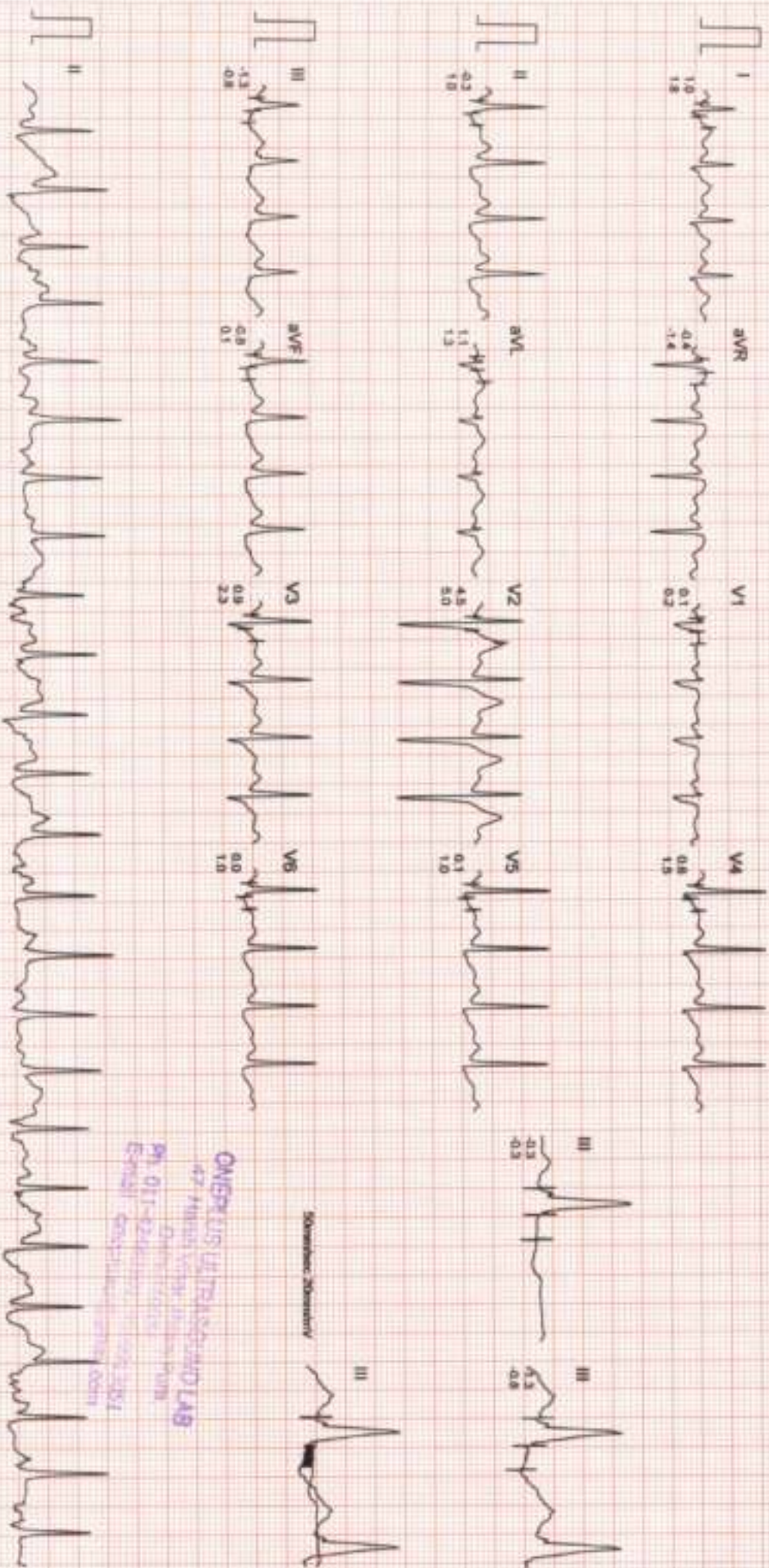
ONEPLUS ULTRASOUND LAB

MR. RAJUDDIN
I.D. : 999
AGE/SEX : 41M
RECORDED : 29-9-2023 11:53

RATE : 157 BPM
B.P. : 170/92 mmHg

BRUCE
EXERCISE 4
PHASE TIME : 9:44
STAGE TIME : 0:44

LINKED MEDIAN



ONEPLUS ULTRASOUND LAB
47, MIDC, VENTURA, PUNE
PH: 020-26220000
EMAIL: konyak@oneplusultrasound.com

Shreebhac 10mm/mV

Filtered Computer Corrected Baseline

Zenerbac 10mm/mV

CardiCom, INDIA Ph. 091-731-2620740, 1666 Fax 091-731-2431214

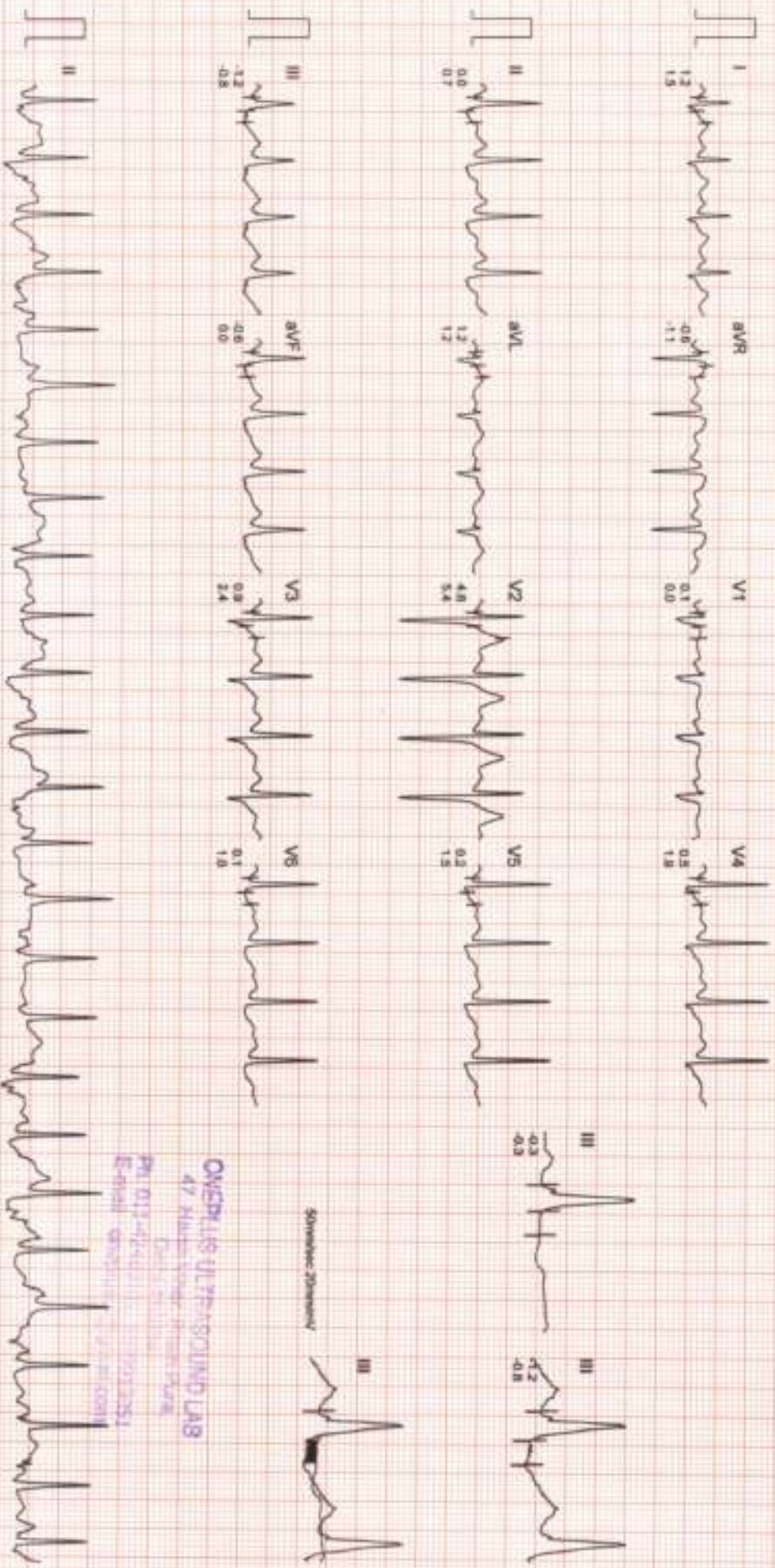
ONEPLUS ULTRASOUND LAB

M. RAJUDDIN
ID : 999
AGE/SEX : 41/M
RECORDED : 29-9-2023 11:53

BRUCE
PEAK EXERCISE
PHASE TIME : 9:47
STAGE TIME : 0:47

ST @ 10mm/mV
80ms PostJ
SPEED : 6.7 Km./Hr.
GRADE : 16.0 %

LINKED MEDIAN



ONEPLUS ULTRASOUND LAB
47 MUDAIR STREET, SINGAPORE
DR. S. S. SIVASUBRAMANIAM
PH: 011-43411111 / 011-23512351
Email: drsiv@oneplus.com

ONEPLUS ULTRASOUND LAB

Mr. RAJUDIN

I.D. : 999

AGE/SEX : 41/M

RECORDED : 29-9-2023 11:53

RATE : 107 BPM

B.P : 138/88 mmHg

BRUCE

RECOVERY

PHASE TIME : 2:59

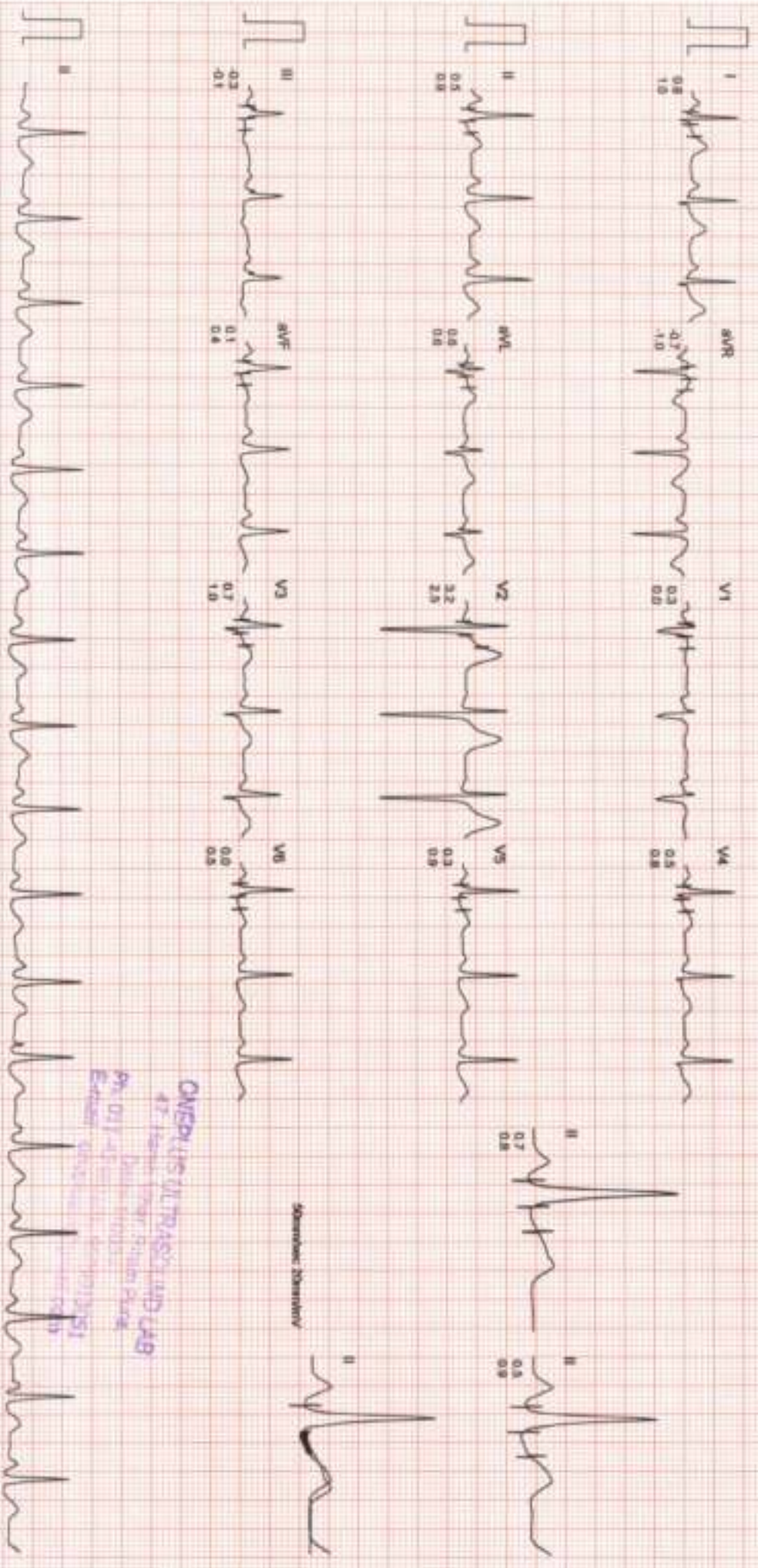
ST @ 10mm/mV

80ms PostJ

SPEED : 0.0 Km./Hr.


GRADE : 0.0 %

LINKED MEDIAN



ONEPLUS ULTRASOUND LAB
47, Medan, Pengkajenean, Palembang
Ph: 011-41511111, 41511112
Email: oneplus@onepluslab.com

Speed: 20mm/mV



ONEPLUS ULTRASOUND LAB
 47, Jalan Sultan Ahmad Shah, Seksyen 13, 40100 Shah Alam, Selangor, Malaysia
 Tel: 03-2921740, 03-2921741, 03-2921742
 Email: info@oneplusultrasound.com

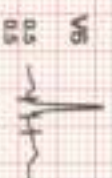
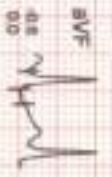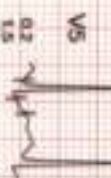
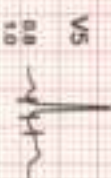

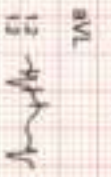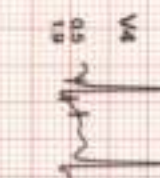
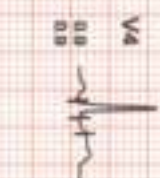

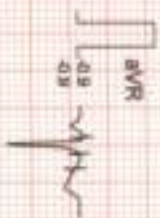
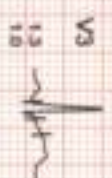
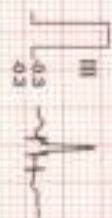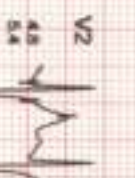

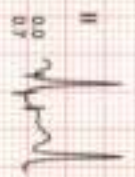
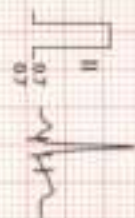
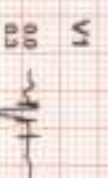

ONEPLUS ULTRASOUND LAB

STANDING
 0.00gms
 0.0%
 66 bpm
 S.P. 130/80
 80mm Hg

PEAK EXERCISE
 9.47
 0.47
 6.70gms
 10.2%
 156 bpm
 S.P. 170/92
 80mm Hg

STANDING
 0.00gms
 0.0%
 66 bpm
 S.P. 130/80
 80mm Hg

PEAK EXERCISE
 9.47
 0.47
 6.70gms
 10.0%
 156 bpm
 S.P. 170/92
 80mm Hg



ONEPLUS ULTRASOUND LAB
 47, Madhav Nagar, Mysore
 Ph: 011-43488888
 Email: oneplusultrasound@gmail.com



NAME	:Mr. RAJUDDIN	Barcode No	:10155112
AGE/GENDER	:41 YRS/Male	SPECIMEN DATE	:29/Sep/2023 09:47AM
PATIENT ID	:122294	SPECIMEN RECEIVED	:29/Sep/2023 10:51AM
REFERRED BY	:Dr. MEDIWHEEL	REPORT DATE	:29/Sep/2023 01:00PM
CENTRE NAME	:ONEPLUS ULTRASOUND LAB	LAB NO.	:012309290013

Test Name	Result	Unit	Ref. Range
Non cyanide Hb analysis			
Total Leucocyte Count	5900	/cumm	4000-10000
Electrical Impedance			
Differential leucocyte count			
Neutrophils	64.5	%	40-80
Electrical Impedance & Microscopic			
Lymphocyte	28.90	%	20-40
Electrical Impedance & Microscopic			
Monocytes	4.60	%	2-10
Electrical Impedance & Microscopic			
Eosinophils	1.6	%	1-6
Electrical Impedance & Microscopic			
Basophils	0.4	%	0-2
Electrical Impedance & Microscopic			
RBC Count	5.10	million/cumm	4.5 - 5.5
Electrical Impedance			
Hematocrit(PCV)	46.2	%	40-50
Flow Cytometry			
MCV	91.1	fl	83-101
Calculated			
MCH	27.7	pg	27-32
Calculated			
MCHC	30.4	g/dL	31.5-34.5
Calculated			
RDW-CV	14.7	%	11.4-14.0
Calculated			
Platelet count	132000	/cumm	150000-410000
Electrical Impedance			


BIOCHEMISTRY

Sample Type:Fluoride F

Blood sugar fasting
GCD-POD

99 mg/dl 70-100 mg/dl

Checked By.

Dr. Nitin Agarwal
Regn. No. 122294

DR. NITIN AGARWAL
MBBS,MD(PATHOLOGIST)



OnePLUS
Ultrasound Lab
— QUALITY FIRST... ALWAYS! —

Dr. Nitin Agarwal

Pathologist & Director
MBBS MD (Pathology)
Ex. Sr. Res. MAMC& Lok Nayak Hospital
Ex. Chief of Lab Dr. Lal Path labs.

Dr. Pooja (Garg) Agarwal

Radiologist & Director
MBBS (MAMC) DMRD (MAMC)
Imaging Expert In Fetal And Maternal Medicine,
University of Barcelona, Spain
Fetal Medicine Foundation (UK) Accreditation



NAME	:Mr. RAJUDDIN	Barcode No	:10155112
AGE/GENDER	:41 YRS/Male	SPECIMEN DATE	:29/Sep/2023 09:47AM
PATIENT ID	:122294	SPECIMEN RECEIVED	:29/Sep/2023 01:05PM
REFERRED BY	:Dr. MEDIWHEEL	REPORT DATE	:29/Sep/2023 03:35PM
CENTRE NAME	:ONEPLUS ULTRASOUND LAB	LAB NO.	:012309290013

Test Name	Result	Unit	Ref. Range
-----------	--------	------	------------

BIOCHEMISTRY

Sample Type:Fluoride PP

Blood sugar pp
GOD-POD

205

mg/dL

70.0-140.0

Checked By.

Dr. NITIN AGARWAL
DR. NITIN AGARWAL
MBBS, MD(PATHOLOGIST)
Reg. No. D-21113

47, Harsh Vihar, Pitampura, Delhi-34 ☎ 011-4248 0101, 9599913051

✉ Email: oneplusul@gmail.com 🌐 www.oneplusul.in

Page 3 of 8

* Clinical correlation is essential for final diagnosis. * If test results are unsatisfactory please contact personally or on phone. * This report is for perusal of doctors only.
* All disputes are subject to Delhi jurisdiction only. * Not for medico legal case. * All congenital anomalies in a foetus may not be diagnosed in routine obstetric ultrasound.



OnePLUS
Ultrasound Lab
— QUALITY FIRST... ALWAYS! —

Dr. Nitin Agarwal
Pathologist & Director
MBBS MD (Pathology)
Ex. Sr. Res. MAMC& Lok Nayak Hospital
Ex. Chief of Lab Dr. Lal Path labs.

Dr. Pooja (Garg) Agarwal
Radiologist & Director
MBBS (MAMC) DMRD (MAMC)
Imaging Expert in Fetal And Maternal Medicine,
University of Barcelona, Spain
Fetal Medicine Foundation (UK) Accreditation



NAME	:Mr. RAJUDDIN	Barcode No	:10155112
AGE/GENDER	:41 YRS/Male	SPECIMEN DATE	:29/Sep/2023 09:47AM
PATIENT ID	:122294	SPECIMEN RECEIVED	:29/Sep/2023 10:52AM
REFERRED BY	:Dr. MEDIWHEEL	REPORT DATE	:29/Sep/2023 01:00PM
CENTRE NAME	:ONEPLUS ULTRASOUND LAB	LAB NO.	:012309290013

Test Name	Result	Unit	Ref. Range
-----------	--------	------	------------

BIOCHEMISTRY

Sample Type:Serum

Bun (blood urea nitrogen) CALCULATED	10.20	mg/dl	8.9-21.6
Uric Acid, serum Uricase-PAP	4.2	mg/dl	3.5-7.2
Creatinine, serum Enzymatic	0.80	mg/dl	0.71-1.16

LFT(LIVER FUNCTION TEST)

Bilirubin Total Modified tab	0.54	mg/dl	0.2-1.1
Bilirubin Conjugated	0.24	mg/dL	0.11-0.42
Bilirubin Unconjugated Calculated	0.30	mg/dl	up to 0.7
SGOT (AST) Tris buffer	57	U/L	0-46
SGPT (ALT) Tris buffer	77	U/L	0-49
Alkaline phosphatase Amp buffer	102	U/L	40-129
GAMMA GT Szasz Method	32	U/L	10-45
Total Protein Biuret	7.6	gm/dl	6.60 - 8.70
Albumin serum BCG	4.4	g/dL	3.0-5.2
Globulin Calculated	3.20	gm/dl	1.8-3.4
Albumin/Globulin Ratio Calculated	1.38		1.10 - 2.50

LIPID PROFILE

Cholesterol CHOD-PAP	261	mg/dl	50-200
Triglycerides GPO-PAP	197	mg/dL	25-150

Checked By.

Dr. NITIN AGARWAL
MBBS, MD(PATHOLOGIST)
Regn. No. DMC-2013-033

47, Harsh Vihar, Pitampura, Delhi-34 ☎ 011-4248 0101, 9599913051

Page 4 of 8

Email: oneplusul@gmail.com www.oneplusul.in

* Clinical correlation is essential for final diagnosis. * If test results are unsatisfactory please contact personally or on phone. * This report is for perusal of doctors only.
* All disputes are subject to Delhi jurisdiction only. * Not for medico legal case. * All congenital anomalies in a foetus may not be diagnosed in routine obstetric ultrasound.



NAME	:Mr. RAJUDDIN	Barcode No	:10155112
AGE/GENDER	:41 YRS/Male	SPECIMEN DATE	:29/Sep/2023 09:47AM
PATIENT ID	:122294	SPECIMEN RECEIVED	:29/Sep/2023 10:52AM
REFERRED BY	:Dr. MEDIWHEEL	REPORT DATE	:29/Sep/2023 01:00PM
CENTRE NAME	:ONEPLUS ULTRASOUND LAB	LAB NO.	:012309290013

Test Name	Result	Unit	Ref. Range
HDL Cholesterol Selective Inhibition	58	mg/dL	40 - 60
LDL cholesterol Calculated	164	mg/dL	<100
VLDL cholesterol Calculated	39.4	mg/dL	5-40
Cholesterol/HDL Ratio Calculated	4.5		Low Risk 3.3-4.97 Average Risk 4.4-7.1 Moderate Risk 7.1-11.0 High Risk >11.0
LDL/HDL Ratio Calculated	2.8		0 - 3.55

LDL Cholesterol	Total Cholesterol	HDL Cholesterol
<100 Optimal	<200 Desirable	<40 Low
100-129 Near optimal	200-239 Borderline high	>60 High
130-159 Borderline high	>240 High	
160-189 High		
>190 Very high		

According to NCEP, ATP-III Guidelines

	BUN/Creatinine ratio		
UREA UREASE-GLDH	22.00	mg/dl	15-45
Bun (blood urea nitrogen) CALCULATED	10.28	mg/dl	8.9-21.6
CREATININE ENZYMATIC	0.80	mg/dl	0.30-1.10
Bun/Creatinine Ratio CALCULATED	12.85		10.0 - 20.0

ENDOCRINOLOGY

THYROID PROFILE(T3,T4,TSH)

Triiodothyronine total [t3] ECLIA	0.64	ng/dl	0.52-1.9
Thyroxine total [t4]	6.82	µg/dl	4.4 - 10.8

Checked By.


DR. NITIN AGARWAL
MBBS,MD(PATHOLOGIST)
Regn. No. [unclear]



NAME	:Mr. RAJUDDIN	Barcode No	:10155112
AGE/GENDER	:41 YRS/Male	SPECIMEN DATE	:29/Sep/2023 09:47AM
PATIENT ID	:122294	SPECIMEN RECEIVED	:29/Sep/2023 10:52AM
REFERRED BY	:Dr. MEDIWHEEL	REPORT DATE	:29/Sep/2023 01:00PM
CENTRE NAME	:ONEPLUS ULTRASOUND LAB	LAB NO.	:012309290013

Test Name	Result	Unit	Ref. Range
ECLIA TSH (Thyroid Stimulating Hormone) Enzyme linked fluorescent assay	2.11	µIU/ml	0.25-5.0

AGE WISE VARIATION IN TSH

AGE	TSH(µIU/ml)	AGE	TSH(µIU/ml)
1-4 weeks	1.00 - 19.0	16-20 yrs	0.25 - 5.0
1-12 mths	1.70 - 9.1	21 - 80 yrs	0.25 - 5.0
1-5 yrs	0.80 - 8.2	I st trimester	0.25 - 5.0
6-10 yrs	0.25 - 5.0	II nd trimester	0.50 - 5.0
11-15 yrs	0.25 - 5.0	III rd trimester	0.4 - 6.0

Reference ranges - Interpretation of Diagnostic tests - (Jacques Wallach)

1. Primary hypothyroidism is accompanied by depressed serum T3 and T4 values and elevated serum TSH level.
2. Primary hyperthyroidism is accompanied by elevated serum T3 and T4 levels along with depressed TSH values.
3. Slightly elevated T3 levels may be found in pregnancy and estrogen therapy, while depressed levels may be encountered in severe illness, renal failure and during therapy with drugs like propranolol and propyl thiouracil.
4. Although elevated TSH levels are nearly always indicative of primary hypothyroidism, and may be seen in secondary thyrotoxicosis

CLINICAL PATHOLOGY

URINE ROUTINE (Strip/microscopy)

Sample Type:Urine


Physical examination

Colour	PALE YELLOW	PALE YELLOW
Transparency	CLEAR	CLEAR
Sp.gravity	1.010	1.005-1.030
BROMOTHYMOLO BLUE	6.50	5.0-8.0
pH	ACIDIC	ACIDIC
Double Indicators Test		
Reaction		

Chemical examination

Urine protein	NIL	NIL
Protein Ionization		

Checked By.


Dr. NITIN AGARWAL
MBBS, MD(PATHOLOGIST)
Regn. No. D-11-12345



OnePLUS
Ultrasound Lab
— QUALITY FIRST... ALWAYS! —

Dr. Nitin Agarwal

Pathologist & Director
MBBS MD (Pathology)
Ex. Sr. Res. MAMC& Lok Nayak Hospital
Ex. Chief of Lab Dr. Lal Path labs.

Dr. Pooja (Garg) Agarwal

Radiologist & Director
MBBS (MAMC) DMRD (MAMC)
Imaging Expert in Fetal And Maternal Medicine,
University of Barcelona, Spain
Fetal Medicine Foundation (UK) Accreditation



NAME	:Mr. RAJUDDIN	Barcode No	:10155112
AGE/GENDER	:41 YRS/Male	SPECIMEN DATE	:29/Sep/2023 09:47AM
PATIENT ID	:122294	SPECIMEN RECEIVED	:29/Sep/2023 10:52AM
REFERRED BY	:Dr. MEDIWHEEL	REPORT DATE	:29/Sep/2023 01:00PM
CENTRE NAME	:ONEPLUS ULTRASOUND LAB	LAB NO.	:012309290013

Test Name	Result	Unit	Ref. Range
Urine sugar Oxidation Reaction	NIL		NIL
Bilirubin, urine	NEGATIVE		NEGATIVE
Urobilinogen P-Aminobenzotic Acid and Phenazopyridine Reaction	NORMAL		NORMAL
Ketones Acetoacetate and Dichloroacetone Reaction	NEGATIVE		NEGATIVE
Microscopic examination			
Pus cells. Microscopy	1-2	/HPF	0-2
Epithelial cells Microscopy	1-2	/HPF	NIL
R.B.C. Microscopy	NIL	/HPF	NIL
Casts Microscopy	NIL	/HPF	NIL
Crystals Microscopy	NIL	/HPF	NIL
Bacteria Microscopy	NIL	/HPF	NIL
Others	NIL	NIL	NIL

STOOL ROUTINE(MANUAL METHOD/MICROSCOPY)

Sample Type:Stool

Physical examination

Colour	BROWNISH	
Consistency	SEMI LOOSE	Semi Formed
Blood	ABSENT	Absent
Mucus	ABSENT	Absent

Chemical examination, stool

pH Double Indicators Test	6.50	5.0-8.0
------------------------------	------	---------

Microscopic examination

Pus cells Microscopy	0-1	/HPF
-------------------------	-----	------

Checked By.

Dr. NITIN AGARWAL
DR. NITIN AGARWAL
MBBS, MD(PATHOLOGIST)
Regn. No. D-107-2018

47, Harsh Vihar, Pitampura, Delhi-34 ☎ 011-4248 0101, 9599913051

✉ Email: oneplusul@gmail.com 🌐 www.oneplusul.in

Page 7 of 8



OnePLUS
Ultrasound Lab
— QUALITY FIRST... ALWAYS! —

Dr. Nitin Agarwal

Pathologist & Director
MBBS MD (Pathology)
Ex. Sr. Res. MAMC& Lok Nayak Hospital
Ex. Chief of Lab Dr. Lal Path labs.

Dr. Pooja (Garg) Agarwal

Radiologist & Director
MBBS (MAMC) DMRD (MAMC)
Imaging Expert in Fetal And Maternal Medicine,
University of Barcelona, Spain
Fetal Medicine Foundation (UK) Accreditation




NAME	:Mr. RAJUDDIN	Barcode No	:10155112
AGE/GENDER	:41 YRS/Male	SPECIMEN DATE	:29/Sep/2023 09:47AM
PATIENT ID	:122294	SPECIMEN RECEIVED	:29/Sep/2023 10:52AM
REFERRED BY	:Dr. MEDIWHEEL	REPORT DATE	:29/Sep/2023 01:00PM
CENTRE NAME	:ONEPLUS ULTRASOUND LAB	LAB NO.	:012309290013

Test Name	Result	Unit	Ref. Range
R.B.C. Microscopy	NIL	/HPF	NIL
Ova Microscopy	NIL		NIL
Cysts Microscopy	NIL		NIL
Bacteria Microscopy	PRESENT	/HPF	NIL
Others	NIL		

*** End Of Report ***

Checked By.


Dr. NITIN AGARWAL
MBBS, MD (PATHOLOGIST)
Regn. No. DMC-136

47, Harsh Vihar, Pitampura, Delhi-34 ☎ 011-4248 0101, 9599913051

✉ Email: oneplusul@gmail.com 🌐 www.oneplusul.in

Page 8 of 8

* Clinical correlation is essential for final diagnosis. * If test results are unsatisfactory please contact personally or on phone. * This report is for perusal of doctors only.
* All disputes are subject to Delhi jurisdiction only. * Not for medico legal case. * All congenital anomalies in a foetus may not be diagnosed in routine obstetric ultrasound.

Name	: Mr. RAJUDDIN	Age/Sex	: 37 YRS/Male
Ref. By	: Dr. MEDIWHEEL	Lab No	: 012309290013
Date	: 29-Sep-2023	Patient ID	: LSHHI122294

ULTRASOUND EXAMINATION—WHOLE ABDOMEN

Liver is normal in size (13.2 cm) and normal in outline with **altered echopattern. Diffuse increase in echogenicity of liver parenchyma is noted, suggestive of fatty infiltration (grade I).** Intrahepatic biliary radicles are not dilated. No abscess or mass lesion seen. Hepatic veins, portal vein, IVC and aorta are normal. CBD is normal (5.5 mm) in caliber.

Gall bladder is partially distended. A single calculus noted in the gall bladder lumen, measuring upto 10.6 mm. The gallbladder walls are not thickened. No Pericholecystic edema is seen. No local tenderness over gallbladder is present.

Both kidneys are normal in size, shape, position, outline and echopattern. Corticomedullary differentiation is maintained. No pelvicalyceal dilation or mass lesion is seen.

Spleen is normal in size and echotexture. No mass lesion seen.

Pancreas is normal in size, outline and echotexture .

Urinary bladder is normal in shape and position. No evidence of intravesical stone or mass seen.

Prostate is normal in size, shape and echopattern.

Prostate measures 3.0 x 2.8 x 4.1 cm. Weight of prostate is 17.6 grams.

No abnormal bowel wall thickening seen in right iliac fossa.

No free fluid seen anywhere in abdomen.

IMPRESSION:

- Fatty infiltration of liver (grade I) with no hepatomegaly.
- Cholelithiasis.

DR. POOJA GARG
RADIOLOGIST
REG NO- DMC/R/03398

Type By : anshika

47, Harsh Vihar, Pitampura, Delhi-34 ☎ 011-4248 0101, 9599913051

✉ Email: oneplusul@gmail.com 🌐 www.oneplusul.in

Name	: Mr. RAIJUDDIN	Age/Sex	: 37 YRS/Male
Ref. By	: Dr. MEDIWHEEL	Lab No	: 012309290013
Date	: 29-Sep-2023	Patient ID	: LSHHI122294

ULTRASOUND EXAMINATION—WHOLE ABDOMEN

Liver is normal in size (13.2 cm) and normal in outline with altered echopattern. Diffuse increase in echogenicity of liver parenchyma is noted, suggestive of fatty infiltration (grade I). Intrahepatic biliary radicles are not dilated. No abscess or mass lesion seen. Hepatic veins, portal vein, IVC and aorta are normal. CBD is normal (5.5 mm) in caliber.

Gall bladder is partially distended. A single calculus noted in the gall bladder lumen, measuring upto 10.6 mm. The gallbladder walls are not thickened. No Pericholecystic edema is seen. No local tenderness over gallbladder is present.

Both kidneys are normal in size, shape, position, outline and echopattern. Corticomedullary differentiation is maintained. No pelvicalyceal dilation or mass lesion is seen.

Spleen is normal in size and echotexture. No mass lesion seen.

Pancreas is normal in size, outline and echotexture .

Urinary bladder is normal in shape and position. No evidence of intravesical stone or mass seen.

Prostate is normal in size, shape and echopattern.

Prostate measures 3.0 x 2.8 x 4.1 cm. **Weight of prostate is 17.6 grams.**

No abnormal bowel wall thickening seen in right iliac fossa.

No free fluid seen anywhere in abdomen.

IMPRESSION:

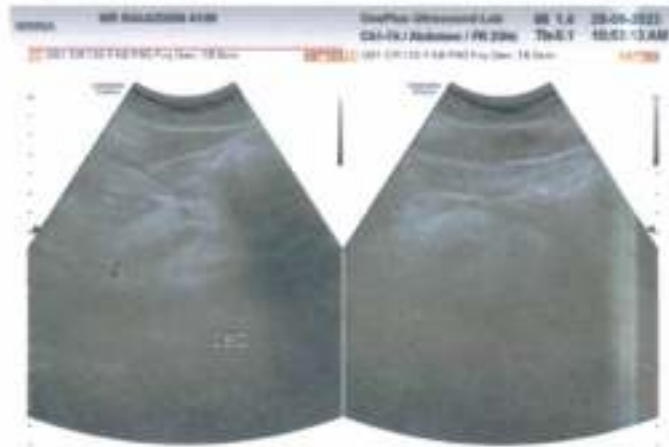- Fatty infiltration of liver (grade I) with no hepatomegaly.
- Cholelithiasis.

DR. POOJA GARG
RADIOLOGIST
REG NO- DMC/R/03398

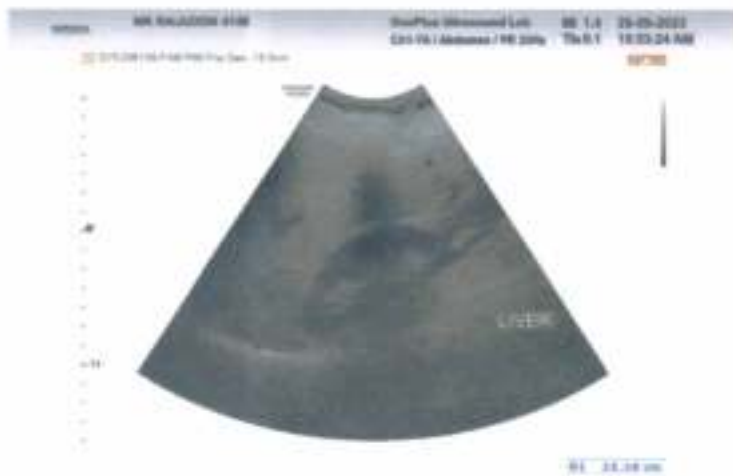
Type By : anshika

47, Harsh Vihar, Pitampura, Delhi-34 ☎ 011-4248 0101, 9599913051

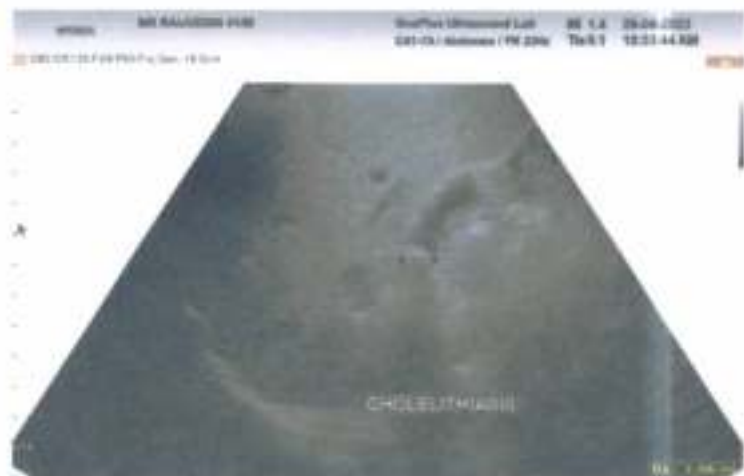✉ Email: oneplusul@gmail.com 🌐 www.oneplusul.in



8.58 cm



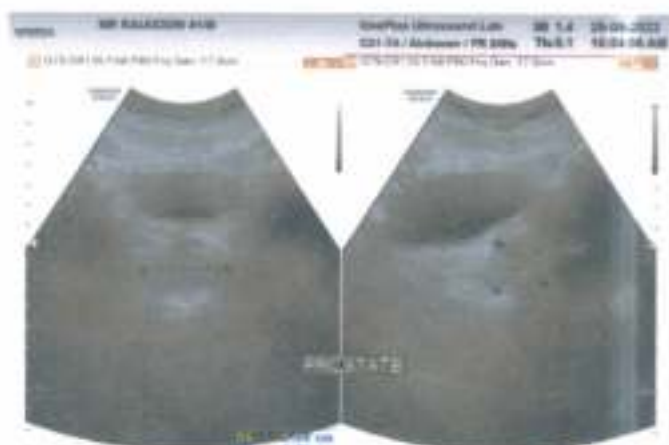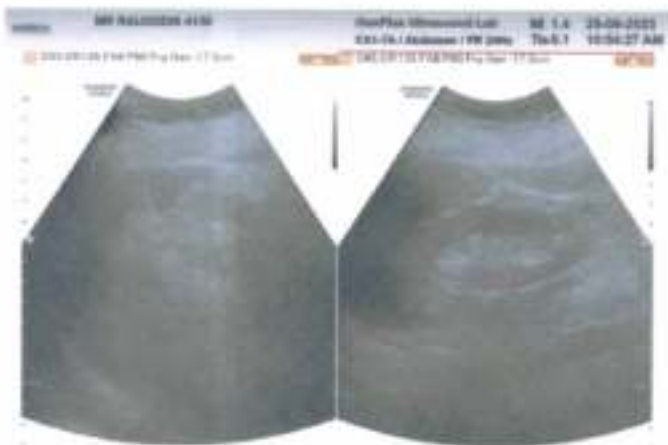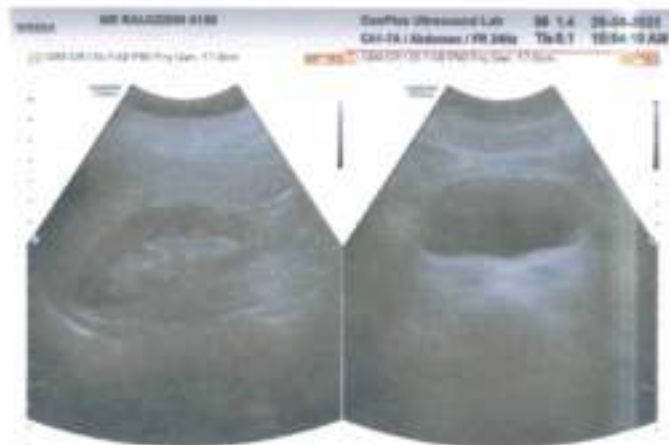8.18 cm



8.18 cm



FATTY LIVER



8.78 cm
8.78 cm
8.78 cm

8.18 cm
8.18 cm

Name	: Mr. RAIJUDDIN	Age/Sex	: 37 YRS/Male
Ref. By	: Dr. MEDIWHEEL	Lab No	: 012309290013
Date	: 29-Sep-2023	Patient ID	: LSHHI122294

X-ray-Chest PA view

Bony cage and soft tissues are normal.
Cardiothoracic ratio is normal.
Mediastinum is normal.
Both hila are normal.
Both costophrenic angles are clear.
Both domes of diaphragm are normal.
Lung fields are clear. No parenchymal lesion seen.

IMPRESSION: Normal Study.

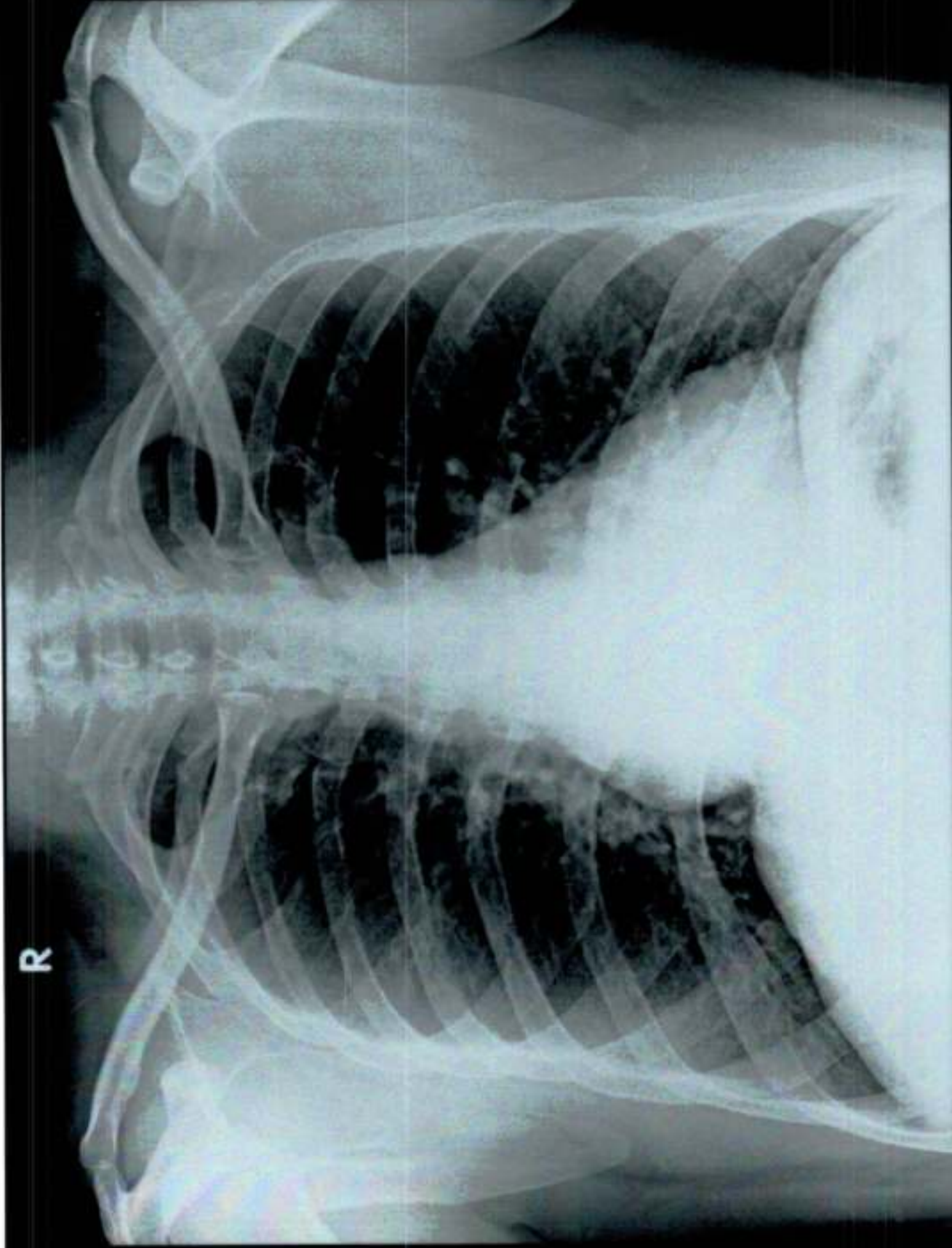
Dr. Pooja Garg
MBBS (MAMC) DMRD (MAMC)
Reg. No. DMC/R/03398
DR. POOJA GARG
RADIOLOGIST
REG NO- DMC/R/03398

Type By : anshika

47, Harsh Vihar, Pitampura, Delhi-34 ☎ 011-4248 0101, 9599913051

✉ Email: oneplusul@gmail.com 🌐 www.oneplusul.in

R



MR. RAIJUDDIN AGE 37 YRS 29-09-2023 CHEST PA VIEW 9/29/2023
ONEPLUS ULTRASOUND LAB,47-HARSH VIHAR,PITAMPURA