

HEALTH CHECK UP

Name : Ayushi Rani

Date : 27/11/24

Age : 39

Sex : Male / Female

Marital status : Married / Single

PERSONAL HISTORY

Habits : Smoking / Tobacco & Snuff / Alcohol No

Drug allergy if any : Nil

Medical : Nil

Surgical : CS by 4 years ago

Height 149 cm Weight 39 Kg. BP 100/60 mmHg Pulse 82

Vision : Rt 6/9 Lt 6/9 With Spectacles Rt Lt

Colour Vision : Normal / Abnormal Near Vision Nil / DE

FAMILY HISTORY

Father Mother Siblings

CVS : Heart Sound Normal Murmurs Absent Thrills Absent

RS : Rate /mt Breath sounds Normal Adventitious Absent

ABDOMEN : Tenderness Absent Rigidity Absent Bowel sound Normal

Liver NAD Kidney NAD Hernia Absent

CNS : Cranial Nerves NAD Sensory System NAD Motor System NAD

ENT NAD

Remarks

Dr. Bharti Jeswani
MBBS

Dr. Seema Kale
MBBS, MD

Dr. S. K. Suri
MBBS

Dr. Meenakshi
MBBS

HOME SAMPLE COLLECTION FACILITY AVAILABLE

NAME: MS AYUSHI RANI
REF

AGE: 29 / Sex / F
DATE 27/01/2024

ECHO ADULT (COLOUR DOPPLER)

DIMENSIONS		NORMAL	DIMENSIONS		NORMAL
Ao (ed)	27.5 mm	(1.5 cm/m ²)	IVS (Ed)	07.0 mm	(0.6-1.2cm)
LA (es)	28.0 mm	(1.5 cm/m ²)	LVPW (Ed)	07.0 mm	(.6-1.1cm)
RVID (ed)	Normal	(0.9cm/m ²)	EF	60.0 %	(0.62-0.85)
LVID (ed)	38.7 mm	(2.6-3.4 cm/m ²)	FS	30.0	
LVID (es)	24.0 mm				

MORPHOLOGICAL DATA

Mitral Valve Normal

Aortic Valve Normal

Tricuspid Valve Normal

Pulmonary Valve Normal

Right Ventricle Normal

Left Ventricle Normal

Pericardium Normal

Interatrial Septum Normal

Interventricular Septum Normal

Pulmonary Artery Normal

Aorta Normal

Right Atrium Normal

Left Atrium Normal

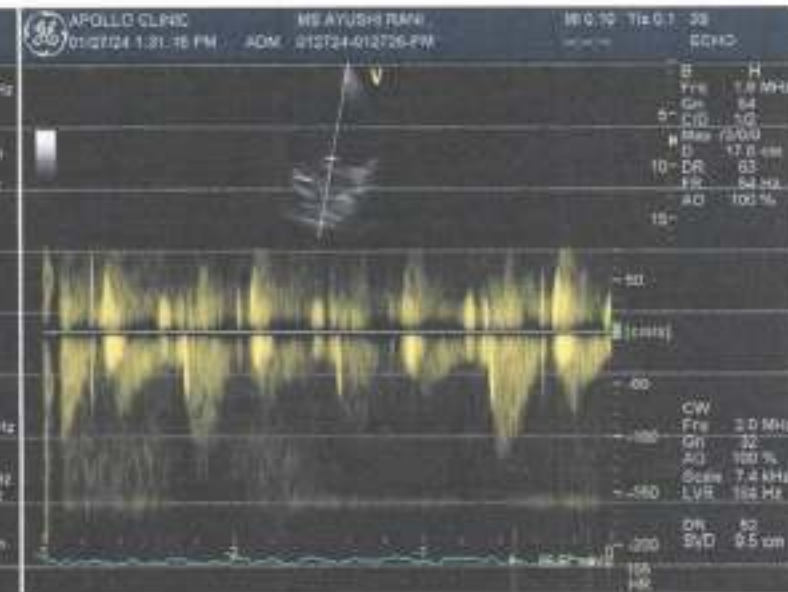
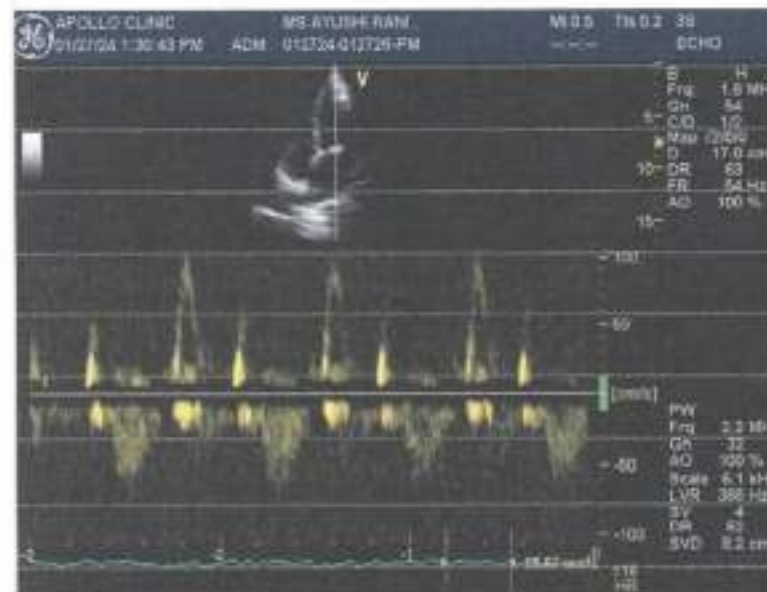
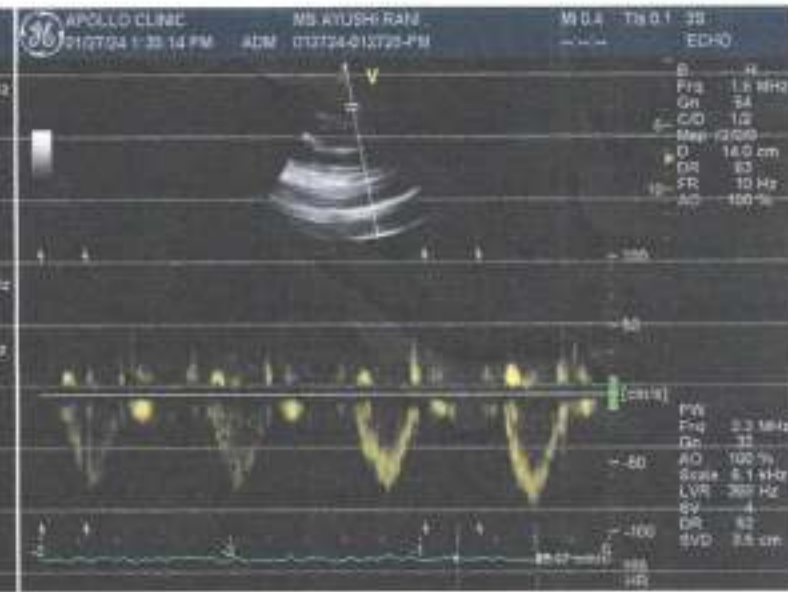
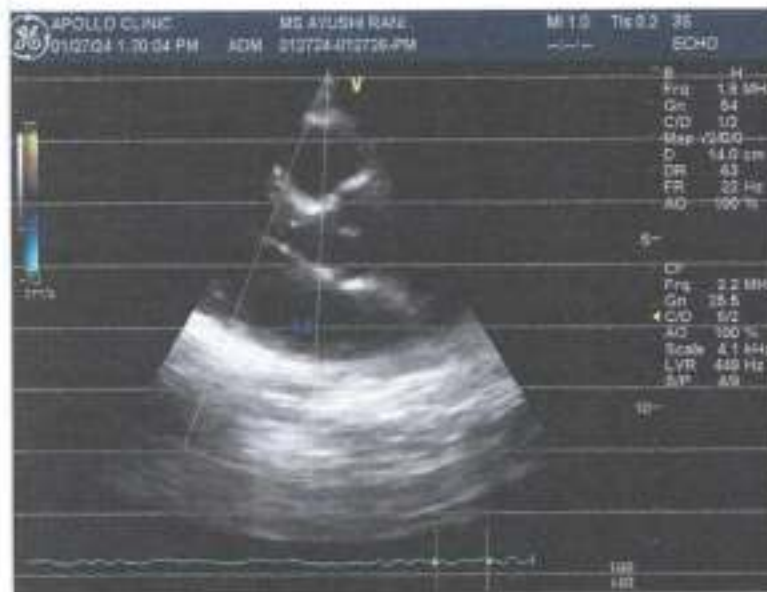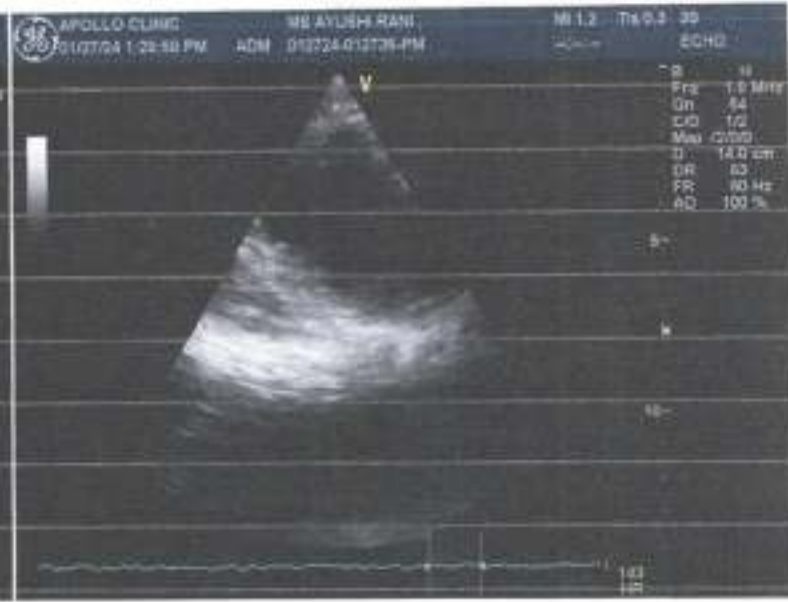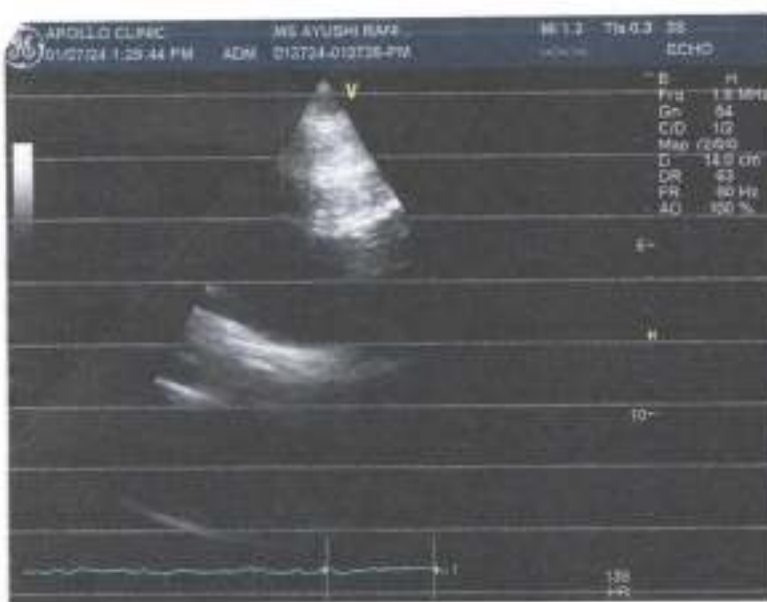Colour Doppler NORMAL, NO PAH, IVC NORMAL, LV DIASTOLIC FUNCTION NORMAL

Wall motion Normal

IMPRESSION : NORMAL STUDY



DR SEEMA KALE MD
SEN. (PHYSICIAN)



Rate 82
PR 120
QRSD 72
QT 336
QTc 392

--Axis--
P 61
QRS 66
T 25

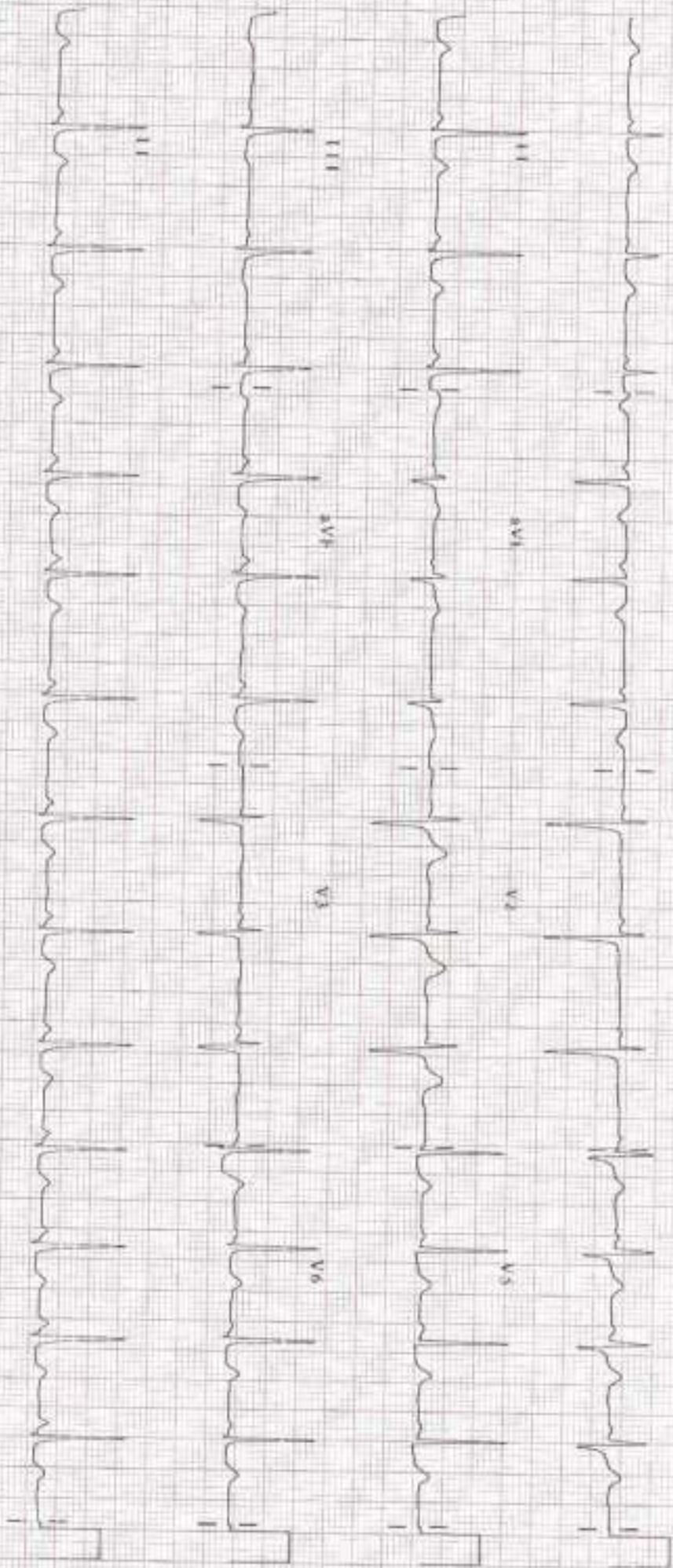
NORMAL SINUS RHYTHM, RATE 82..... Normal P axis, PR, rate & rhythm

NORMAL ECG

Unconfirmed diagnosis



HEALTHCARE INC. 08/03/24 2.5 mm/s 100mm/mV P 5.0 s 11.2 - 1.0 Hz W 10.70 s 0.5 mV



Please note the following health check-up booking summary on 27/01/2024

Customer Care :Mediwheel : New Delhi <customercare@mediwheel.in>

To: "theapolloclinicrajourigarden@gmail.com" <theapolloclinicrajourigarden@gmail.com>

Thu, Jan 25, 2024 at 7:26 PM

Member Name	Member Age	Mobile	Package Name
YOGENDER KUMAR	48 year	9756253729	Mediwheel Full Body Health Checkup Male Above 40
Diwakar kumar	36 year	9122186690	Mediwheel Full Body Health Checkup Male Below 40
MR. GONI	53 year	9810582413	Mediwheel Full Body Health Checkup Male Below 40
MR. SANGWAN NAVEEN	25 year	8050778540	Mediwheel Full Body Health Checkup Male Below 40
MS. RANI AYUSHI	29 year	9122186690	Mediwheel Full Body Health Checkup Female Below 40

Thanks & Regards



Arcofemi Health Care Ltd. | F-701 A, Lado Sarai, Mehrauli | New Delhi – 110 030

Ph No. 011-41195959

Email : customercare@mediwheel.in | Web: www.mediwheel.in

Health Check up Booking Request(bobE6155), Beneficiary Code-155627



Mediwheel
to the customers

Mon, Jan 22, 4:01 PM (5 days ago)

Reply



011-41195959

Dear Apollo Bharti Apollo Bharti Medicare Pvt. Ltd.

We have received a booking request for the details are following. Please provide your confirmation by clicking on the yes button.

Are you sure to confirm the booking?

Name : MS. RANI AYUSHI
Package Name : Mediwheel Full Body Health Checkup
Female Below 40
Package Code : PKG10000475
Location : C70, Opp. Madhav Park, Major Sudesh
Kumar Marg -110027
Contact Details : 9122186690
E-mail id : ayushisingh@gmail.com
Booking Date : 22-01-2024
Appointment Date : 27-01-2024

Member Information		
Booked Member Name	Age	Gender
MS. RANI AYUSHI	29 year	Female

Please login to your account to confirm the same. Also you mail us for confirmation

Hospital Package Name : Mediwheel Full Body Health Checkup
Female Below 40
User Package Name : Mediwheel Full Body Health Checkup
Female Below 40

Are you sure to confirm the booking?

23 Tests included in this Package:

- Pap Smear
- Stool Test
- Gynae Consultation
- Thyroid Profile
- ESR
- Blood Glucose (Fasting)
- General Physician Consultation
- TMT OR 2D ECHO
- Blood Group
- Blood Glucose (Post Prandial)
- Chest X-ray
- ECG
- USG Whole Abdomen
- Eye Check-up consultation
- Urine Sugar Fasting
- Urine Sugar PP
- Dental Consultation
- Urine analysis
- CBC

- HbA1c
- Lipid Profile
- Kidney Profile
- Liver profile

Patient Name : Mrs. Ayushi Rani
UHID/MR No. : FRAJ.0000241391
Visit Date : 27-01-2024 10:10
Sample Collected on : 27-01-2024 11:24
Ref Doctor : SELF
Emp/Auth/TPA ID : jgoi858wewe
Sponsor Name : MEDIWHEELS HEALTH CARE

Age / Gender : 29Y/Female
OP Visit No : FRAJOPV116946
Reported on : 27-01-2024 14:25
Specimen : Whole Blood (Edta)
Pres Doctor: :

DEPARTMENT OF LABORATORY MEDICINE

TEST NAME	RESULT	BIOLOGICAL REFERENCE INTERVALS	UNITS
COMPLETE BLOOD COUNT			
Hb (Haemoglobin) Method: Non Cyanide	8.4*	11 - 15	gm/dl
PCV/Haematocrit Method: RBC pulse height detect	26.3*	36 - 46	%
ESR Method: Westergren's Method	28*	0 - 20	mm/1st Hr
TLC Method: DC Detection Method	4900	4000 - 10000	/cumm.
RBC COUNT Method: DC Detection Method	3.1*	3.8 - 4.8	Million/cmm
PLATELET COUNT Method: DC Detection Method	1.90	1.5 - 4.1	lakh/cumm.
MCV Method: Derived	84.8	77 - 98	f
MCH Method: Derived	27.0	27 - 32	pg
MCHC Method: Derived	31.8	31.5 - 34.5	gm/dl
NEUTROPHIL Method: Microscopy	68	40 - 70	%
LYMPHOCYTE Method: Microscopy	26	20 - 40	%
EOSINOPHIL Method: Microscopy	02	1.0 - 6.0	%
MONOCYTE Method: Microscopy	04	2.0 - 10.0	%
BLOOD GROUP AND RH TYPE			
ABO Group	O		
RH	Positive		

End of the report

Results are to be correlated clinically

Lab Technician / Technologist
Surinder

Dr. Prashant Purwar
MBBS, DCP
Consultant Pathologist

• CLINICAL CORRELATION IS ESSENTIAL FOR FINAL DIAGNOSIS. • IF THE TESTS RESULTS ARE UNEXPECTED PLEASE CONTACT THE LABORATORY.
 • ALL THE CONGENITAL ANOMALIES IN THE FETUS MAY NOT BE DIAGNOSED IN ULTRASONOGRAPHY. • THIS REPORT IS NOT VALID FOR MEDICOLEGAL PURPOSE.

Licensee : Bharti Medicare Pvt. Ltd. The Apollo Clinic, C-70, Major Sudesh Kumar Marg, Opp. Madhav Park, Near Main Market, Rajouri Garden, New Delhi-110 027
 Phone : (011) 2591 8222 / 8333 / 8444, 9811061009, E-mail : rajourigarden@theapolloclinic.com, Website : www.apolloclinicrajourigarden.com

MSME UAM NO. : DI 11E0021531

Patient Name : Mrs. Ayushi Rani
 UHID/MR No. : FRAJ.0000241391
 Visit Date : 27-01-2024 10:10
 Sample Collected on : 27-01-2024 11:24
 Ref Doctor : SELF
 Emp/Auth/TPA ID : jfgo658wewe
 Sponsor Name : MEDIWHEELS HEALTH CARE

Age / Gender : 29Y/Female
 OP Visit No : FRAJOPV116946
 Reported on : 27-01-2024 16:54
 Specimen : Plasma(Fluoride)
 Pres Doctor :


DEPARTMENT OF LABORATORY MEDICINE

TEST NAME	RESULT	BIOLOGICAL REFERENCE INTERVALS	UNITS
GLUCOSE - (FASTING)			
GLUCOSE - (FASTING) Method: GOD-POD)	89	70 - 110	mg/dL
GLUCOSE - (POST PRANDIAL)			
GLUCOSE - (POST PRANDIAL) Method: GOD-POD)	102	70-140	mg/dl
GLYCOSYLATED HEMOGLOBIN (HBA1C)			
GLYCOSYLATED HEMOGLOBIN (HBA1C) - WHOLE BLOOD Method: BORONATE AFFINITY	5.2	4.2 - 6.0	%
LIPID PROFILE TEST (PACKAGE)			
CHOLESTEROL Method: CHOD - PAP	158	Desirable < 200 Borderline High : 200-239 High : > 240	mg/dl
Triglyceride Method: GPO-PAP	77	50-200	mg/dl
HDL Method: DIRECT	67.0	30 - 70	mg/dl
LDL Method: DIRECT	75.6	60 - 100	mg/dl
VLDL Method: Calculated	15.4	<40	mg/dl
CHOLESTEROL / HDL RATIO Method: Calculated	2.3	0 - 4.5	
Thyroid Profile 2(Free T4, Free T3 And TSH)			
Serum FT3	3.9	3.2 - 5.9	pmol/l
Serum FT4	13.1	10.6 - 21.0	pmol/l
Serum TSH	2.6	0.38 - 5.0	uIU/ml

End of the report

Results are to be correlated clinically

Lab Technician / Technologist
Yogita


Dr. Prashant Purwar
MBBS, DCP
Consultant Pathologist

• CLINICAL CORRELATION IS ESSENTIAL FOR FINAL DIAGNOSIS. • IF THE TESTS RESULTS ARE UNEXPECTED PLEASE CONTACT THE LABORATORY
 • ALL THE CONGENITAL ANOMALIES IN THE FETUS MAY NOT BE DIAGNOSED IN ULTRASONOGRAPHY. • THIS REPORT IS NOT VALID FOR MEDICOLEGAL PURPOSE

Licensee : Bharti Medicare Pvt. Ltd. The Apollo Clinic, C-70, Major Sudesh Kumar Marg, Opp. Madhav Park, Near Main Market, Rajouri Garden, New Delhi-110 027
 Phone : (011) 2591 8222 / 8333 / 8444, 9611081009, E-mail : rajourigarden@theapolloclicin.com, Website : www.apolloclicinrajourigarden.com

Patient Name : Mrs. Ayushi Rani
 UHID/MR No. : FRAJ.0000241391
 Visit Date : 27-01-2024 10:10
 Sample Collected on : 27-01-2024 10:30
 Ref Doctor : SELF
 Emp/Auth/TPA ID : jfgoi858wewe
 Sponsor Name : MEDIWHEELS HEALTH CARE

Age / Gender : 29Y/Female
 OP Visit No : FRAJOPV116946
 Reported on : 27-01-2024 16:55
 Specimen : Serum
 Pres Doctor :


DEPARTMENT OF LABORATORY MEDICINE

TEST NAME	RESULT	BIOLOGICAL REFERENCE INTERVALS	UNITS
LIVER FUNCTION TEST (PACKAGE)			
BILIRUBIN - TOTAL Method: Jendrassik	0.88	0.1 - 1.3	mg/dl
Bilirubin (Direct)-Serum Method: Diazo.	0.17	0 - 0.3	mg/dl
A/G Method: Calculated	1.5	1.0 - 2.0	
BILIRUBIN - INDIRECT. Method: Calculated.	0.71	<1.1	mg/dl
SGOT /AST Method: IFCC (With P5P)	25.0	0 - 35	U/L
SGPT/ALT Method: IFCC (With P5P)	14.5	0 - 45	U/L
ALKALINE PHOSPHATE Method: AMP BUFFER	60.1	30 - 117	U/L
GGT. Method: SZAZ	12.6	10 - 50	U/L
TOTAL PROTEIN Method: Biuret	7.0	5.8-8.0	g/dl
ALBUMIN Method: BCG	4.3	3.7-5.2	g/dl
GLOBULIN Method: Calculated	2.7	2.5 - 3.5	mg/dL

End of the report

Results are to be correlated clinically

Lab Technician/Technologist
Yogita


 Dr. Prashant Purwar
 MBBS, DCP
 Consultant Pathologist

• CLINICAL CORRELATION IS ESSENTIAL FOR FINAL DIAGNOSIS. • IF THE TESTS RESULTS ARE UNEXPECTED PLEASE CONTACT THE LABORATORY
 • ALL THE CONGENITAL ANOMALIES IN THE FETUS MAY NOT BE DIAGNOSED IN ULTRASONOGRAPHY. • THIS REPORT IS NOT VALID FOR MEDICOLEGAL PURPOSE

Licensee : Bharti Medicare Pvt. Ltd. The Apollo Clinic, C-70, Major Sudesh Kumar Marg, Opp. Madhav Park, Near Main Market, Rajouri Garden, New Delhi-110 027
 Phone : (011) 2591 8222 / 8333 / 8444, 9811061009, E-mail : rajourigarden@theapolloclinic.com, Website : www.apolloclinicrajourigarden.com

MEME UAM NO. - DL1450021524



Patient Name : Mrs. Ayushi Rani
UHID/MR No. : FRAJ.0000241391
Visit Date : 27-01-2024 10:10
Sample Collected on : 27-01-2024 10:30
Ref Doctor : SELF
Emp/Auth/TPA ID : jfgol658wewe
Sponsor Name : MEDIWHEELS HEALTH CARE

Age / Gender : 29Y/Female
OP Visit No : FRAJOPV116946
Reported on : 27-01-2024 16:57
Specimen : Serum
Pres Doctor :


DEPARTMENT OF LABORATORY MEDICINE

TEST NAME	RESULT	BIOLOGICAL REFERENCE INTERVALS	UNITS
KFT - RENAL PROFILE-SERUM			
UREA Method: Urinase	16.3	10-50	mg/dl
Creatinine Method: Jaffe	0.80	0.5 - 1.3	mg/dl
Uric Acid Method: Urinase	3.6	2.6 - 6	mg/dl
Sodium(Na) Method: ISE	136.0	136 - 142	mmol/L
Potassium(K) Method: ISE	4.0	3.8 - 5.0	mmol/L
Chloride(Cl) Method: ISE	97.1	95 - 103	mmol/L
Calcium Method: OCPC	9.5	9.2 - 11.0	mg/dl
Phosphorus Method: Molybdate UV	2.8	2.3 - 4.7	mg/dl

End of the report

Results are to be correlated clinically

Lab Technician/Technologist
Yogita


Dr. Prashant Purwar
MBBS, DCP
Consultant Pathologist

• CLINICAL CORRELATION IS ESSENTIAL FOR FINAL DIAGNOSIS. • IF THE TESTS RESULTS ARE UNEXPECTED PLEASE CONTACT THE LABORATORY.
• ALL THE CONGENITAL ANOMALIES IN THE FETUS MAY NOT BE DIAGNOSED IN ULTRASONOGRAPHY. • THIS REPORT IS NOT VALID FOR MEDICOLEGAL PURPOSE.

Patient Name : Mrs. Ayushi Rani
UHID/MR No. : FRAJ.0000241391
Visit Date : 27-01-2024 10:10
Sample Collected on : 27-01-2024 10:30
Ref Doctor : SELF
Emp/Auth/TPA ID : jgoi658wewe
Sponsor Name : MEDIWHEELS HEALTH CARE

Age / Gender : 29Y/Female
OP Visit No : FRAJOPV116946
Reported on : 27-01-2024 15:50
Specimen : Urine
Pres Doctor: :

DEPARTMENT OF LABORATORY MEDICINE

URINE ROUTINE EXAMINATION


URINE EXAMINATION TEST REPORT

Test Name	Observed Value	Unit	Reference Range
Urine R/M Examination			
Quantity	30	ml.	
Colour	Pale Yellow		Pale Yellow
Transparency	Clear		Clear
Urine Specific Gravity	1.010		1.005 - 1.030
Dipstick			
pH	6.0		5.5 - 7.5
Dipstick / pH paper			
Chemical Examination			
Protein	Nil		Nil
Dipstick/Heat & acetic acid			
Sugar	Nil		Nil
Microscopic Examination			
Pus Cells	1-2		1-2
RBC'S	Nil	/HPF	Nil
Casts	Nil	/HPF	Nil
Crystals	Nil	/HPF	Nil
Epithelial Cells	1-2		1-2
Bacteria	Nil	/HPF	Nil

End of the report

Results are to be correlated clinically

Lab Technician / Technologist
Surinder


 Dr. Prashant Purwar
 MBBS, DCP
 Consultant Pathologist

• CLINICAL CORRELATION IS ESSENTIAL FOR FINAL DIAGNOSIS • IF THE TESTS RESULTS ARE UNEXPECTED PLEASE CONTACT THE LABORATORY.
 • ALL THE CONGENITAL ANOMALIES IN THE FETUS MAY NOT BE DIAGNOSED IN ULTRASONOGRAPHY • THIS REPORT IS NOT VALID FOR MEDICOLEGAL PURPOSE

Licensee : Bharti Medicare Pvt. Ltd. The Apollo Clinic, C-70, Major Sudesh Kumar Marg, Opp. Madhav Park, Near Main Market, Rajouri Garden, New Delhi-110 027
 Phone : (011) 2591 8222 / 8333 / 8444, 9811061009, E-mail : rajourigarden@theapolloclinic.com, Website : www.apolloclinicrajourigarden.com

Patient Name : Mrs. Ayushi Rani
Age/Sex : 29 Y/F
Pres Doctor :
Ref.by : SELF

MR No : FRAJ.0000241391
Visit No : FRAJOPV116946
Bill Date : 27-01-2024 10:12
Report Date : 27-01-2024 16:06

ULTRASOUND WHOLE ABDOMEN

LIVER: Liver is normal in shape, size and echotexture. No focal intra-hepatic lesion detected. Intra-hepatic biliary radicals are not dilated. Portal vein is normal in calibre.

GALL BLADDER: Gall bladder is well visualized. Its wall thickness is normal. No calculus or mass lesion is seen in gall bladder.

PANCREAS: Pancreas appears normal in size and echopattern.

SPLEEN: Spleen appears normal in size and echopattern.

KIDNEYS: Both kidneys are normal in position, size and outline. Cortico-medullary differentiation of both kidneys is maintained. Central sinus echoes are compact. No calculus / hydronephrosis seen.

URINARY BLADDER: Urinary bladder is well distended and shows clear contents.

UTERUS: Uterus is anteverted and normal in size. Endometrium is central and appears normal in thickness. Myometrial echogenicity appears normal.

OVARY: B/L ovaries are normal in size, shape & echopattern. Both adnexal regions are normal. No free fluid is seen in cul-de-sac.

IMPRESSION: - NORMAL STUDY.
To be correlate clinically.

Dr. Manish Kumar
Consultant Radiologist.

Disclaimer: Renal calculi less than 5mm could be missed on an Ultrasound. NCCT KUB is the modality of choice for the same.

Patient Name : Mrs. Ayushi Rani
Age/Sex : 29 Y/F
Pres Doctor :
Ref.by : SELF


MR No : FRAJ.0000241391
Visit No : FRAJOPV116946
Bill Date : 27-01-2024 10:12
Report Date : 27-01-2024 10:14

X-RAY CHEST PA VIEW

- Both lungs fields do not show any active parenchymal lesion.
- Both costophrenic angles are normal.
- B/L hila appear normal in size & density.
- Both domes of diaphragm are normal.
- Cardiac silhouette appears normal.
- Visualised soft tissues and bony cage appear normal.

IMPRESSION:- NORMAL STUDY.

To be correlate clinically.


Dr. Manish Kumar
Consultant Radiologist.