


R

50 60

SUANTA 59 Y/F PT184055 CHEST PA 25/Mar/2023 10:49 AM

RADIX HEALTH CARE 15 FIRMAY BLDG 1TH 2011106

| | | | |
|-----------|-------------|----------------------|----------------------|
| UHID | PT184055 | LAB No. | XRY2210957 |
| Name | Mrs. SHANTA | Regn. No. | GEN2243352 |
| Age / Sex | 59 Yrs / F | Receiving Dt/Time | 25/Mar/2023 10:59 |
| | | Reporting Dt/Time | 25/Mar/2023 11:55 AM |

**XRAY**

CHEST (PA)

Both lung fields are normal.

Cp angles are clear.

Hila are normal...


Heart size appears within normal limits.

Soft tissue shadows and bony thorax are normal.

IMP- NORMAL CHEST X-RAY

Advised....please correlate clinically.

***** END OF REPORT *****

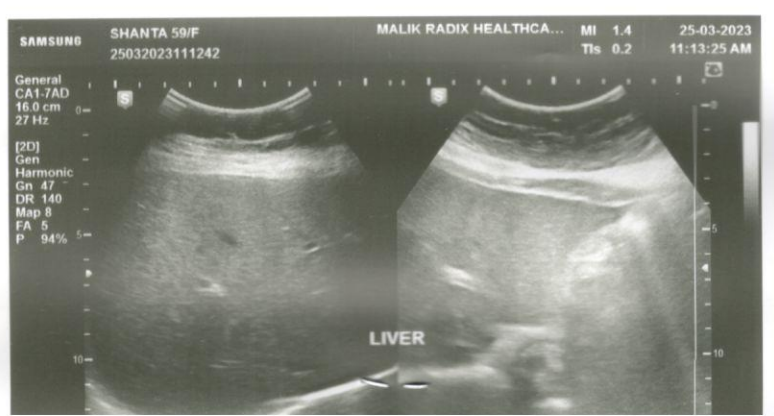
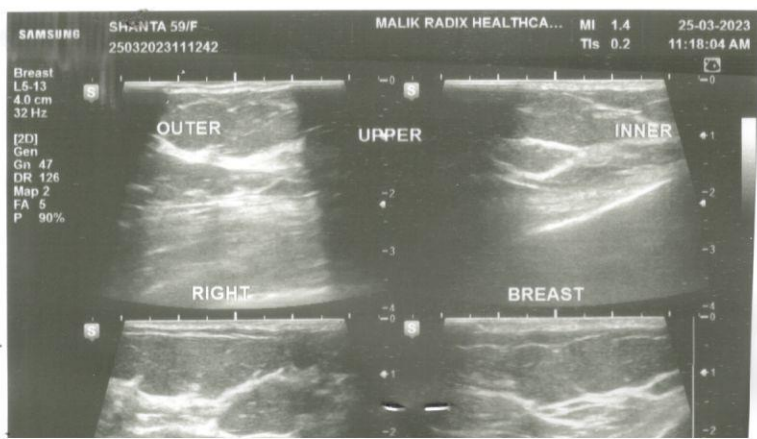
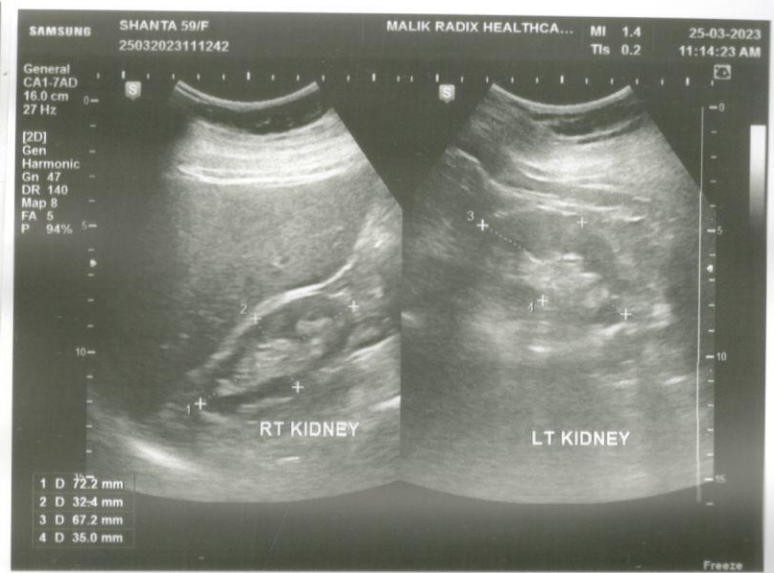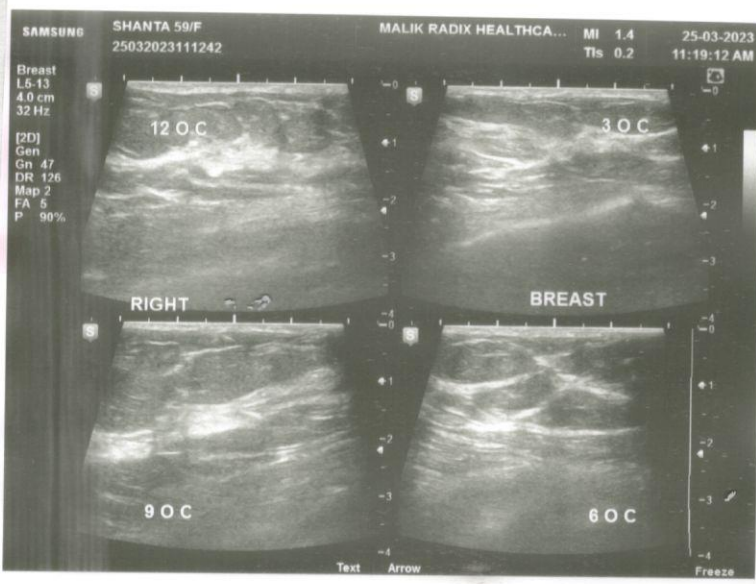
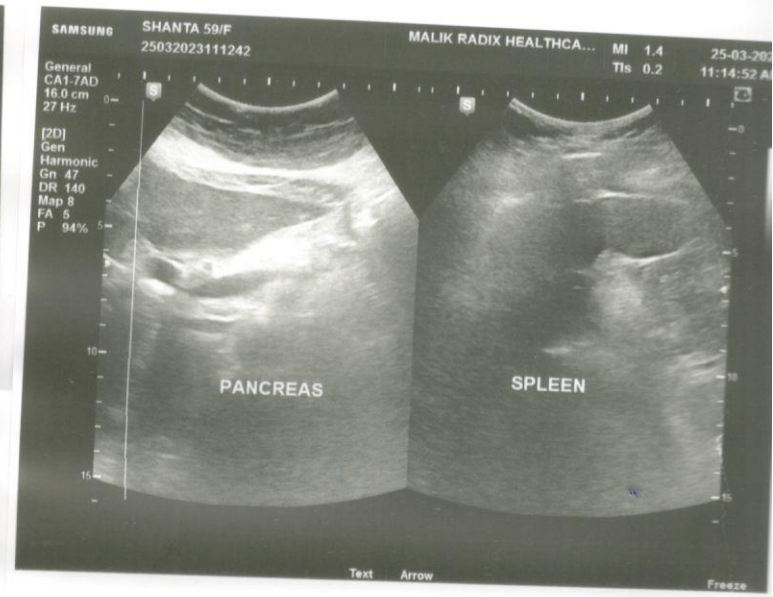
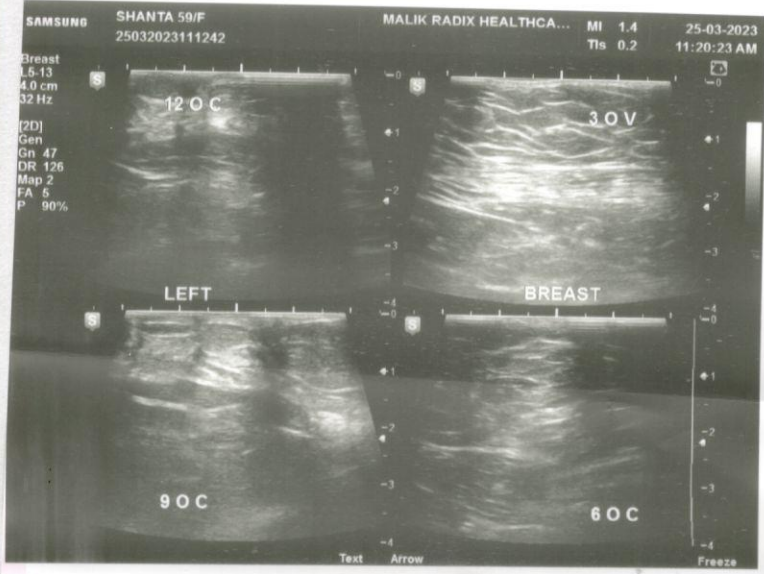
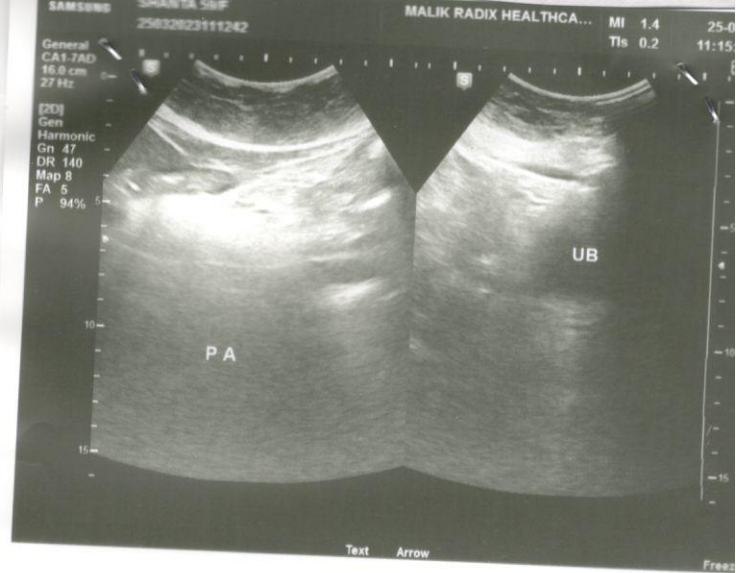
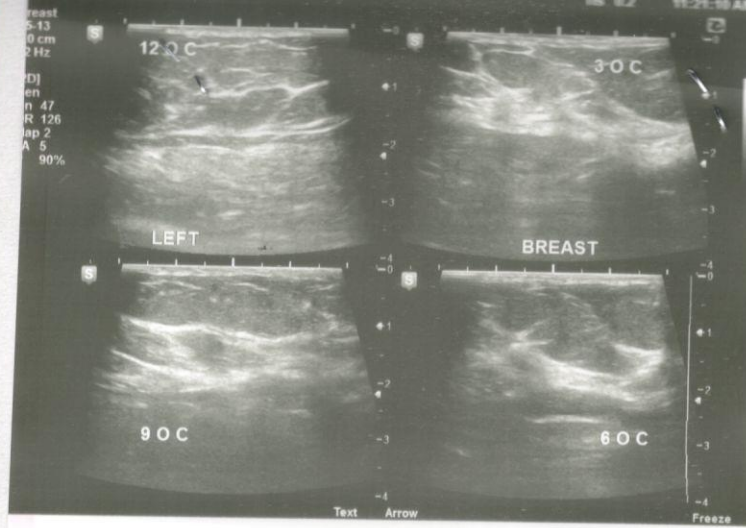


DR. K.K. SINHA
M.B.B.S., D.M.R.D.
SENIOR CONSULTANT
Reg. No. 25437 (DMC)

DR. RAJESH MALHOTRA
MBBS, MD (RADIOLOGY)
CONSULTANT RADIOLOGY
Reg.No.DMC9299

DR. T. K VOHRA
MD (RADIODIAGNOSIS)
SENIOR CONSULTANT
Reg. No. 3272 (DMC)

DR. MUKESH KOSHAL
MBBS, MD (RADIOLOGY)
CONSULTANT RADIOLOGY
Reg.No.DMC10407





| | | | |
|------------------|------------------|-------------|-----------------|
| NAME | MRS SANTA | AGE | 59 Y/F |
| REFD. BY. | | DATE | 25.03.23 |

Ultrasound Examination of Whole Abdomen & Pelvis :

Liver: Liver shows grade 1 fatty change No focal SOL is seen in liver. IHBR & portal radicles are normal.

Gallbladder: Gallbladder is not seen (postcholecystectomy).

Pancreas: Pancreas shows normal size & echotexture.

Spleen: Spleen shows normal size, outline & echotexture.

Kidneys: Kidneys show normal shape, position & echotexture but are small (7- 7.2 cm). No calculus, hydronephrosis or SOL is seen in kidneys. Cortico- medullary differentiation normal on both sides.
 No supra- renal mass seen.
 Great abdominal vessels are normal.

Domes of diaphragm are seen to move normally & synchronously in respiration. No infra- or supradiaphragmatic collection seen.

No ascites or pericardial effusion seen.

No para aortic lymph nodes seen.

Urinary bladder: Urinary bladder shows normal anechoic pattern. No calculus, SOL, or diverticulum seen.

Uterus: Uterus & adnexa are normal for age.

Regards.


Dr Mukesh Koshal MD (Rad- diag)
 Regn. No. DMC 10407

RADIOLOGIST :

Facilities Available

Multispeciality Hospital - 24 Hours Emergency - X-Ray/ ECG/ Ultrasound/ CT Scan - Dental - Fully Equipped Operation Theatre
 Fully Functional Lab - 24/7 Casualty/ ICU-Nursery 24/7 Pharmacy - Labour Room - All Speciality OPD - Laproscopic Surgery -
 ECHO - Plastic Surgery



| | | | |
|-----------|-----------------|------|----------|
| NAME | MRS SANTA | AGE | 59 Y/F |
| REFD. BY. | HEALTH CHECK UP | DATE | 25.03.23 |

Ultrasound Examination of Breasts:

US examination of both breasts was performed using a high frequency probe.

On US both breasts show the normal appearances of adult menopausal breasts. Normal echogenic adipose tissue is seen. The glandular elements are relatively sparse. The fibrous tissue stroma is well defined. No evidence of any abnormal calcification seen. No evidence of any abscess seen. Areolar and axillary regions are normal.

IMP- NORMAL STUDY

Regards.


Dr Mukesh Koshal MD (Rad- diag)
Regn. No. DMC 10407

RADIOLOGIST :

Facilities Available

- Multispeciality Hospital - 24 Hours Emergency - X-Ray/ ECG/ Ultrasound/ CT Scan - Dental - Fully Equipped Operation Theatre
- Fully Functional Lab - 24/7 Casualty/ ICU-Nursery 24/7 Pharmacy - Labour Room - All Speciality OPD - Laproscopic Surgery -
ECHO - Plastic Surgery