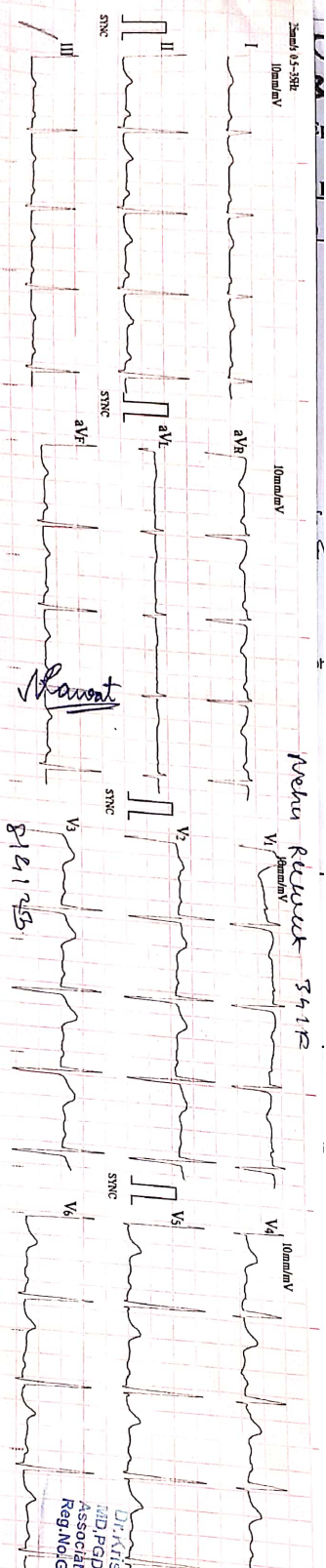


VI-006 (Rev:VI-010) 2014-01-08 02:09



Neetu R. Raut 5412


*Neetu*

HR : 85 bpm  
 P-R : 701 ms  
 P-R : 159 ms  
 QRS : 90 ms  
 QT/QTc : 359/428 ms  
 P/QRS/T : 60/65/55 ms  
 RMS/SVL : 1.720/0.890 mV  
 RV5/SVL : 2.610 mV

Age : \_\_\_\_\_ Sex : \_\_\_\_\_

Unconfirmed report Verified by: \_\_\_\_\_

Dr. K. V. Srinivas  
 MD, PGDCC  
 Associate Consultant  
 Reg. No. G-50510  
 Cardiology



# Heart & General Clinic

Icure Heart & Diet Clinic, 402, Epsilon tower, opp Pasha bhai park, Race course, Vadodara

## :: PERSONAL HEALTH REPORT ::

Neha Rewat		*DATE 8/4/23
		SR. NO. SEX. Female AGE 34/Year HEIGHT 167cm WEIGHT 61k.g.

### HISTORY

Present History : No  
 Past Illness History : No Diabetes/Hypertension/Tuberculosis/Asthma/Epilepsy  
 Past Occupational History : No  
 Family History : No  
 Personal History : She had c-section in October 2020  
 Addiction : No Tobacco/Gutkha/Smoking/Alcohol

### GENERAL EXAMINATION

T.P.R. : 76/min B.P. : 120/80 mm Hg  
 Pallor/Icterus/Cyanosis/Varicosity/Lymph Nodes/Thyroid/Oedema/NVE/Other :

### SYSTEMIC EXAMINATION

R.S. : NAD  
 C.V.S : NAD  
 C.N.S : NAD  
 A.S. : NAD  
 Musculo-skelet System : NAD



E.N.T. Ex.	NAD	ACUITY OF VISION		RT EYE -1.5	LT EYE -1.75
		Dental Ex.	NAD	Without Glass	DISTANT 6/
Skin Ex.	NAD			Near	6/
		Psychic Ex.	NAD	With Glass	DISTANT 6/ 6
Near	6/ 6			6/ 6	
		COLOUR BLINDNESS		NAD	

### REMARK

### ADVICE

The Worker is FIT/UNFIT for the assigned job.

Dr. Krish P. Vaidya  
 MD, PGDCS  
 Associate Consultant-Cardiology  
 Reg.No. G-50510

DR. KRISH VAIDYA \*

MD G-50510, CIH

भारतीय विशिष्ट पहचान प्राधिकरण

भारत सरकार

Unique Identification Authority of India  
Government of India


नामांकन क्रम/Enrolment No.: 1539/78608/07337

Download Date: 10/05/2017  
Generation Date: 08/04/2017

To  
Neha Rawat  
Neha Rawat  
D/O Madan Singh Rawat  
b-302  
fortune v  
tandalja  
sun phama road  
Vadodara  
Vadodara Tandalja  
Gujarat - 390012  
9173159462

Signature Not Verified

DEMAND FILED BY  
UNIQUE IDENTIFICATION  
AUTHORITY OF INDIA 03  
Date: 20/11/2017 @ 11:12:10  
ET



आपका आधार क्रमांक / Your Aadhaar No. :

4735 6188 6424

मेरा आधार, मेरी पहचान



भारत सरकार

Government of India



Neha Rawat

Neha Rawat

जन्म तिथि/DOB: 06/01/1989

महिला / FEMALE



4735 6188 6424

मेरा आधार, मेरी पहचान

*Neha Rawat*





# BARODA DIAGNOSTIC LABORATORY



\* 2 9 3 2 1 \*

Patient's name : Neha Rawat  
Age/Sex : 34 Years/Female  
Referred by : C/o. I Cure Heart & Diet Clinic  
Sample From : LAB  
UHID :

Reg. ID : icure-56-19  
Accession : 29321  
Reg. Date : 08/04/2023  
Collection Time : 08/04/2023 13:25

## COMPLETE BLOOD COUNT

Sample Type: EDTA

Test Name	Result	Units	Biological Reference Interval
<b><u>Blood Counts</u></b>			
Haemoglobin :	14.0	Gms%	12.5 - 16.0
Total R.B.C. :	4.48	mill/c.mm	4.2 - 5.4
Total W. B. C. :	6800	/cu mm	4000 - 10500
Platelet Count :	305000	/cu.mm	1,50,000 - 4,50,000
<b><u>Differential Count</u></b>			
Neutrophils :	60	%	40 - 70
Lymphocytes :	38	%	20 - 40
Eosinophils :	01	%	1 - 4
Monocytes :	<u>01</u>	%	2 - 6
Basophils :	00	%	0 - 01
<b><u>Blood Indices</u></b>			
P. C. V. :	37.1	%	37 - 47
M. C. V. :	82.8	fl	78 - 100
M.C.H. :	<u>31.2</u>	pg	27 - 31
M. C. H. C. :	<u>37.7</u>	%	32 - 36
R.D.W. :	12.0	%	11.5 - 14.0

### E.S.R.( Westergren Method )

After one hour : 08 mm 3 - 12



*Dr Harsh Pandya*  
(MD)  
Consultant Pathologist  
Reg. No.: G-32582

*Dr. Priya Kriplani*  
(MD)  
Consultant Pathologist  
Reg. No.: G-46004

302, Trivia Complex, Natubhai Circle, Race Course, Vadodara. ☎: +91 88660 09950 / 74050 09950 ✉: bdi95950@gmail.com

Laboratory results serve as an aid to diagnosis & should be interpreted in relation to clinical findings. Please refer back to laboratory in case of any discrepancy.



Scanned with OKEN Scanner



# BARODA DIAGNOSTIC LABORATORY



Patient's name : Neha Rawat  
Age/Sex : 34 Years/Female  
Referred by : C/o. I Cure Heart & Diet Clinic  
Sample From : LAB  
UHID :  
Reg. ID : icure-56-19  
Accession : 29321  
Reg. Date : 08/04/2023  
Collection Time : 08/04/2023 13:25

## HbA1C REPORT

Sample Type: EDTA

Test Name	Result	Units	Biological Reference Interval
HbA1C :	5.20	%	Excellent control: 4.2-6.2 Good Control : 6.3-7.2 Fair Control : 7.3-8.2 Poor Control : >8.3
Mean Blood Glucose levels : of last 03months	102.54	mg/dl	

### NOTE

\*As per the new 2009 update of American Diabetes Association regarding HbA1C & Mean Blood Glucose relationship.

This test is used to monitor diabetic patients compliance with the therapeutic regimen and long term blood glucose control. It's level is proportional to both the average blood glucose concentration and the life span of the red blood cells (RBC) in circulation. HbA1c values are free of day to day glucose fluctuations and are unaffected by exercise or recent food intake.

Dr. Priya Kriplani  
M.D. Pathology.  
Reg. No. G-46004

Dr. Niti Adhwaryu  
M.D. Pathology  
Reg. No. G-34888

LAB  
LAB USE ONLY (Entered by :AP Enter Date/Time:08/04/2023 2:19:00 PM) (Verify by :OP1 Verify Date/Time:08/04/2023 2:23:00 PM)



**Dr Harsh Pandya**  
(MD)  
Consultant Pathologist  
Reg. No.: G-32582

**Dr. Priya Kriplani**  
(MD)  
Consultant Pathologist  
Reg. No.: G-46004

302, Trivia Complex, Natubhai Circle, Race Course, Vadodara. ☎ : +91 88660 09950 / 74050 09950 ✉ : bdi95950@gmail.com

Laboratory results serve as an aid to diagnosis & should be interpreted in relation to clinical findings. Please refer back to laboratory in case of any discrepancy.



Scanned with OKEN Scanner





# BARODA DIAGNOSTIC LABORATORY



\* 2 9 3 2 1 \*

Patient's name : Neha Rawat  
Age/Sex : 34 Years/Female  
Referred by : C/o. I Cure Heart & Diet Clinic  
Sample From : LAB  
UHID :

Reg. ID : icure-56-19  
Accession : 29321  
Reg. Date : 08/04/2023  
Collection Time : 08/04/2023 13:25

## LIPID PROFILE

Sample Type: Serum

Test Name	Result	Units	Biological Reference Interval
Cholesterol :	130	mg/dl	0 - 200
Triglyceride :	105	mg/dL	0 - 150
HDL - Cholesterol :	43	mg/dL	35 - 65
LDL - Cholesterol :	66	mg/dL	0 - 130
VLDL - Cholesterol :	21	mg/dL	0 - 30
Total Cholesterol/HDL Ratio :	3.02		1 - 6
LDL / HDL Cholesterol Ratio :	1.53		0 - 3.5

Done on Fully automated biochemistry analyser - COBAS C 111

Dr. Niti Adhwaryu  
M.D. Pathology  
Reg. No. G-34888

Dr. Priya Kriplani  
M.D. Pathology.  
Reg. No. G-46004

LAB  
LAB USE ONLY (Entered by : AP Enter Date/Time:08/04/2023 2:19:00 PM) (Verify by : OP1 Verify Date/Time:08/04/2023 2:22:00 PM)



**Dr Harsh Pandya**  
(MD)  
Consultant Pathologist  
Reg. No.: G-32582

**Dr. Priya Kriplani**  
(MD)  
Consultant Pathologist  
Reg. No.: G-46004

302, Trivia Complex, Natubhai Circle, Race Course, Vadodara. ☎: +91 88660 09950 / 74050 09950 ✉: bdl95950@gmail.com

Laboratory results serve as an aid to diagnosis & should be interpreted in relation to clinical findings. Please refer back to laboratory in case of any discrepancy.



Scanned with OKEN Scanner



# BARODA DIAGNOSTIC LABORATORY



\* 2 9 3 2 1 \*

Patient's name : Neha Rawat  
Age/Sex : 34 Years/Female  
Referred by : C/o. I Cure Heart & Diet Clinic  
Sample From : LAB  
UHID :

Reg. ID : icure-56-19  
Accession : 29321  
Reg. Date : 08/04/2023  
Collection Time : 08/04/2023 13:25

## LIVER FUNCTION TEST

Sample Type: Serum

Test Name	Result	Units	Biological Reference Interval
S.G.P.T (ALT) :	15	U/L	0 - 40
S.G.O.T (AST) :	19	U/L	0 - 37
ALK.PHOSPHATASE :	50	U/L	35 - 105
G.G.T :	18.5	U/L	8 - 78
<b><u>Bilirubin</u></b>			
Total :	0.50	mg/dl	0.2 - 1.0
Direct :	0.24	mg/dl	0 - 0.6
Indirect :	0.26	mg/dl	0 - 0.5
<b><u>Serum Proteins</u></b>			
Total Protein :	6.96	gms/dl	6.4 - 8.3
Albumin :	3.96	gms/dl	3.8 - 4.4
Globulins :	3.00	gms/dl	2.3 - 3.5
A/G Ratio :	1.32		0.9 - 2.9

Done on Fully automated biochemistry analyser - COBAS C 111

Dr. Niti Adhwaryu  
M.D. Pathology  
Reg. No. G-34888

Dr. Priya Kriplani  
M.D. Pathology.  
Reg. No. G-46004

LAB  
LAB USE ONLY (Entered by :AP

Enter Date/Time:08/04/2023 2:18:42 PM)



Dr. Harsh Pandya  
(MD)

Consultant Pathologist  
Reg. No.: G-32582

Dr. Priya Kriplani  
(MD)

Consultant Pathologist  
Reg. No.: G-46004







# BARODA DIAGNOSTIC LABORATORY



Patient's name : Neha Rawat  
Age/Sex : 34 Years/Female  
Referred by : C/o. I Cure Heart & Diet Clinic  
Sample From : LAB  
UHID :

Reg. ID : icure-56-19  
Accession : 29321  
Reg. Date : 08/04/2023  
Collection Time : 08/04/2023 13:25

## RENAL FUNCTION TEST

Test Name	Result	Units	Biological Reference Interval
Urea :	15	mg/dl	10 - 50
Bun (Calculated) :	7	mg/dl	0 - 18
Creatinine :	0.94	mg/dl	0.4 - 1.5
Uricacid :	4.80	mg/dl	3.4 - 7.0


Done on Fully automated biochemistry analyser - COBAS C 111

Dr. Niti Adhwaryu  
M.D. Pathology  
Reg. No. G-34888

Dr. Priya Kriplani  
M.D. Pathology.  
Reg. No. G-46004

LAB

LAB USE ONLY (Entered by : OP1 Enter Date/Time: 08/04/2023 2:23:00 PM) (Verify by : OP1 Verify Date/Time: 08/04/2023 2:23:00 PM)



**Dr Harsh Pandya**  
(MD)  
Consultant Pathologist  
Reg. No.: G-32582

**Dr. Priya Kriplani**  
(MD)  
Consultant Pathologist  
Reg. No.: G-46004

302, Trivia Complex, Natubhai Circle, Race Course, Vadodara. ☎: +91 88660 09950 / 74050 09950 ✉: bdl95950@gmail.com

Laboratory results serve as an aid to diagnosis & should be interpreted in relation to clinical findings. Please refer back to laboratory in case of any discrepancy.



Scanned with OKEN Scanner





# BARODA DIAGNOSTIC LABORATORY



\* 2 9 3 2 1 \*

Patient's name : Neha Rawat  
Age/Sex : 34 Years/Female  
Referred by : C/o. I Cure Heart & Diet Clinic  
Sample From : LAB  
UHID :

Reg. ID : icure-56-19  
Accession : 29321  
Reg. Date : 08/04/2023  
Collection Time : 08/04/2023 13:25

## THYROID FUNCTION

Sample Type: Serum

Test Name	Result	Units	Biological Reference Interval
TOTAL T3 :	1.01	ng/ml	0.84 - 2.0
TOTAL T4 :	8.90	ug/dl	5.1 - 14.0
TSH :	3.02	mIU/L	0.25 - 5.0

Method : CLIA

Dr. Niti Adhwaryu  
M.D. Pathology  
Reg. No. G-34888

Dr. Priya Kriplani  
M.D. Pathology  
Reg. No. G-46004

LAB  
LAB USE ONLY (Entered by :AP Enter Date/Time:08/04/2023 2:18:00 PM) (Verify by :OP1 Verify Date/Time:08/04/2023 2:22:00 PM)

BARODA DIAGNOSTIC LABORATORY



**Dr Harsh Pandya**  
(MD)  
Consultant Pathologist  
Reg. No.: G-32582

**Dr. Priya Kriplani**  
(MD)  
Consultant Pathologist  
Reg. No.: G-46004

302, Trivia Complex, Natubhai Circle, Race Course, Vadodara. ☎ : +91 88660 09950 / 74050 09950 ✉ : bdl95950@gmail.com

Laboratory results serve as an aid to diagnosis & should be interpreted in relation to clinical findings. Please refer back to laboratory in case of any discrepancy.



Scanned with OKEN Scanner

 **icure™**  
**Heart & General Clinic**

iCure Heart& Diet Clinic, 402, Epsil on tower, opp Pasha bhai park, Race course, Vadodara

**Name** : NEHA RAWAT  
**Ref By** : ICURE HEART & DIET CLINIC

**Age/Sex** : 34 Yrs./F  
**Date** : 08/04/2023  
**Report ID.** : 5

**HAEMOGRAM PROFILE**

<u>TEST</u>	<u>RESULT</u>
Blood Group	: " B "
Rh Factor (Anti D.)	: " POSITIVE "

**BIOCHEMISTRY**

<b><u>FASTING (FBS)</u></b>			
Blood Glucose	: 106.0	mg/dL	70.00 - 110.00 mg/dL
<b><u>POST-PRANDIAL</u></b>			
Blood Glucose	: 120.0	mg/dL	80 - 140 mg/dL

*Done By Fully Auto Analyzer MIURA, A-1004*



END OF REPORT



  
**Heart & General Clinic**


iCure Heart& Diet Clinic, 402, Epsil on tower, opp Pasha bhai park, Race course, Vadodara

**Name** : NEHA RAWAT  
**Ref By** : ICURE HEART & DIET CLINIC

**Age/Sex** : 34 Yrs./F  
**Date** : 08/04/2023  
**Report ID.** : 5

**EXAMINATION OF URINE**

<u>TEST</u>	<u>RESULT</u>	<u>UNIT</u>
Sample	: FASTING	
<b><u>PHYSICAL EXAMINATION</u></b>		
Quantity	: 10	mL
Colour	: PALE YELLOW	
Transperancy	: CLEAR	
Specific Gravity	: 1.030	
Reaction	: ACIDIC	
Deposits	: ABSENT	
<b><u>CHEMICAL EXAMINATION</u></b>		
Albumin	: NIL	
Sugar	: NIL	
Acetone	: ABSENT	
Bile Salts	: ABSENT	
Bile Pigments	: ABSENT	
Urobilinogen	: NORMAL : ~ < 1.0 mg/dL	
Occult Blood	: ABSENT	
Nitrate	: ABSENT	
<b><u>MICROSCOPIC EXAMINATION</u></b>		
Pus Cells	: 0-1 / hpf	
RBC	: NIL	
Epithelial Cells	: NIL	
Crystals	: NIL	
Amorphous Phosphate	: NIL	
Cast	: NIL	



END OF REPORT





  
**Heart & General Clinic**

**2D Echocardiography & Color Doppler Report**

iCure Hear care, 402, Epsilon tower, opp Pasha bhai park, Race course, Vadodara

**Patient Name: Mrs Neha Rawat**

**Dates: 08 / 04 / 2023**

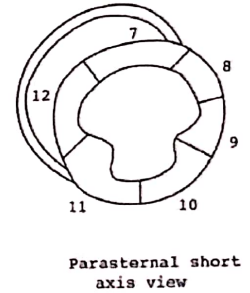
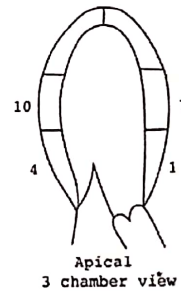
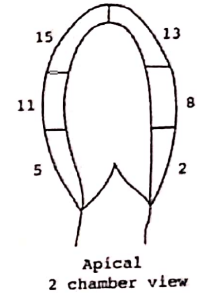
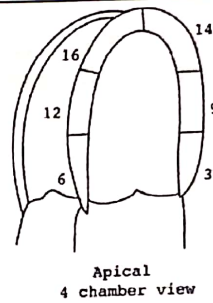
**Age Gender: female - 34 Years**

**M. Mode Study:**

<b>LA</b>	<b>32</b>	<b>IVS</b>	<b>09</b>	<b>PWD</b>	<b>09</b>
<b>AO</b>	<b>25</b>	<b>LVDs</b>	<b>26</b>	<b>LVDd</b>	<b>48</b>

**Doppler Study:**

<b>Mitral Valve</b>	<b>E: 0.65 A: 0.98</b>
<b>Aortic Valve</b>	<b>Normal</b>
<b>Tricuspid Valve</b>	<b>Normal</b>
<b>Pulmonary Valve</b>	<b>Normal</b>



**Conclusion:**

- **Normal LV Systolic function**
- **LVEF: 62 % ,No RWMA**
- **Cardiac Chambers: Normal**
- **Diastolic function: Normal**
- **TR: No PAH: No RVSP: 17mmhg**
- **No Ms , No MR**
- **No AR , No AS**
- **ASD/VSD/PDA/Co-A : No**
- **No Clots or vegetations found**
- **IVC: 10mm size with Normally collapsive**



**Dr. Krish P. Vaidya**  
MD, PGCC  
Associate Consultant-Cardiology  
Reg.No.G-50510

**Dr. Krish P Vaidya**  
Consultant Cardiologist, Diabetologis  
& General Physician

**Note:**

Normal 2D echo report does not rule out cardiac diseases  
this report shall not be used for Medico legal purposes,  
Clinical Correlation advisable.

  
**Heart & General Clinic**

NAME : Mrs Neha Rawat	AGE : 34 Y/F	DATE : 08/04/2023
-----------------------	--------------	-------------------

**ULTRASONOGRAPHY OF WHOLE ABDOMEN**  
(Screening Only)

**Liver** is normal in size and echotexture and shows normal parenchymal reflectivity. No focal lesion is seen. Hepatic veins appear normal. There is no evidence of any dilated intra hepatic billiary radicals.

**Portal Vein** appears normal in diameter.

**Common Bile Duct** is of normal diameter.

**Gallbladder** is physiologically distended with normal wall thickness. There is no evidence of gallstones. No evidence of peri-cholecystic fluid or probe tenderness.

**Pancreas** is normal in size and shows homogenous reflectivity. There is no evidence of any calcification or ductal dilatation.

**Spleen** is normal size and shows a homogenous echotexture. There is no evidence of any focal lesion.

**Both Kidneys** are normal in position and size. They show normal cortical reflectivity and cortico-medullary distinction. Right kidney measures 94 x36mm. Left kidney measures 89x40mm. There is no evidence of renal calculi, hydronephrosis or mass seen.

**Bladder** is well distended and shows normal wall thickness. No evidence of intra-luminal mass or calculi.

**Uterus** appears normal in size. Uterine myometrial echotexture is homogeneous. No focal lesion is seen. CET measures 5mm.

**Both Ovaries** appears normal in size & reflectivity. No evidence of any adnexal mass.

There is no evidence of ascites.

No evidence of any gross bowel mass seen.

No evidence of any aorto-caval or mesenteric root lymphadenopathy.

No mass or collection in right iliac fossa.

**CONCLUSION:** No sonographic abnormality is seen.



*Mehul Prajapati*

**DR. MEHUL PRAJAPATI**  
**CONSULTANT RADIOLOGIST**



 **iCure™**  
**Heart & General Clinic**

iCure Heart& Diet Clinic, 402, Epsil on tower, opp Pasha bhai park, Race course, Vadodara

<b>NAME</b>	NEHA RAWAT	<b>AGE/SEX</b>	34/FEMALE
<b>REF BY</b>	I CURE HEART & DIET CLINIC	<b>DATE</b>	08-04-2023

**X-RAY CHEST PA VIEW**

BOTH LUNG FIELDS ARE NORMAL.

BOTH COSTOPHRENIC RECESS ARE CLEAR.

CARDIAC CONFIGURATION IS NORMAL.

MEDIASTINUM AND BONY THORACIC CAGE REVEAL NO ABNORMALITY.

**IMPRESSION : NORMAL LUNGS HEART AND MEDIASTINUM**



**DR.HIMANI VIRAPARA**  
**Regn. No: G.28771**  
**M.D. [Radiodiagnosis]**  
**(CONSULTANT RADIOLOGIST)**

