



भारत सरकार
Unique Identification Authority of India
Government of India


नामांकन क्रम / Enrollment No.: 0648/01941/40308

To
दिव्या शर्मा
Divya Sharma
D-302 FIRST FLOOR NIRMAN VIHAR
NIRMAN VIHAR DELHI
Nirman Vihar
Laxmi Nagar
Gandhi Nagar East Delhi
Delhi 110092
8469450567

18/01/2017
141339298



ME413392981FH



आपका आधार क्रमांक / Your Aadhaar No. :

5829 4190 2461

मेरा आधार, मेरी पहचान



भारत सरकार
Government of India



दिव्या शर्मा
Divya Sharma
जन्म तिथि / DOB : 01/10/1978
महिला / Female



5829 4190 2461

मेरा आधार, मेरी पहचान

Divyasharma



MALIK RADIX HEALTH CARE

(UNIT OF MALIK RADIX HEALTHCARE PVT. LTD)

C-217, 218, Nirman Vihar, Vikas Marg, New Delhi - 110092

Tel.: 011-22011192, 22011196, 47060150 • Fax.: 22011208

E-mail : radixhealthcare@yahoo.co.in

Website : www.radixhealthcare.org



Safety at WEI now accredited by NABH

Name - Divya Sharma
Age - 44 yr / F

08/12/22

bc 6/12 ~~2/2~~

6/12 ~~2/2~~

Not brought out for

Healed $\left\{ \begin{array}{l} NG \\ NB \end{array} \right.$

HM

Color U: WNL

Endu: WNL (BS)

No hypertensive retinopathy

so far

Dr. Anjali Gupta

MBBS, MS, DNB

Casualty Ophthalmologist

Malik Radix Healthcare Pvt. Ltd.

DMC No. 121661

Facilities Available :

- ★ Multispeciality Hospital ★ 24 Hours Emergency ★ X-Ray/ ECG/ Ultrasound ★ Dental
- ★ Fully Equipped Operation Theatre ★ Fully Functional Lab ★ Casualty/ICU ★ Nursery
- ★ Labour Room ★ All Speciality OPD ★ Laparoscopic Surgery ★ ECHO ★ Plastic Surgery

Home Collection Facility Available Contact : 8587915647

MAC600 1.02

ID: 8469450567

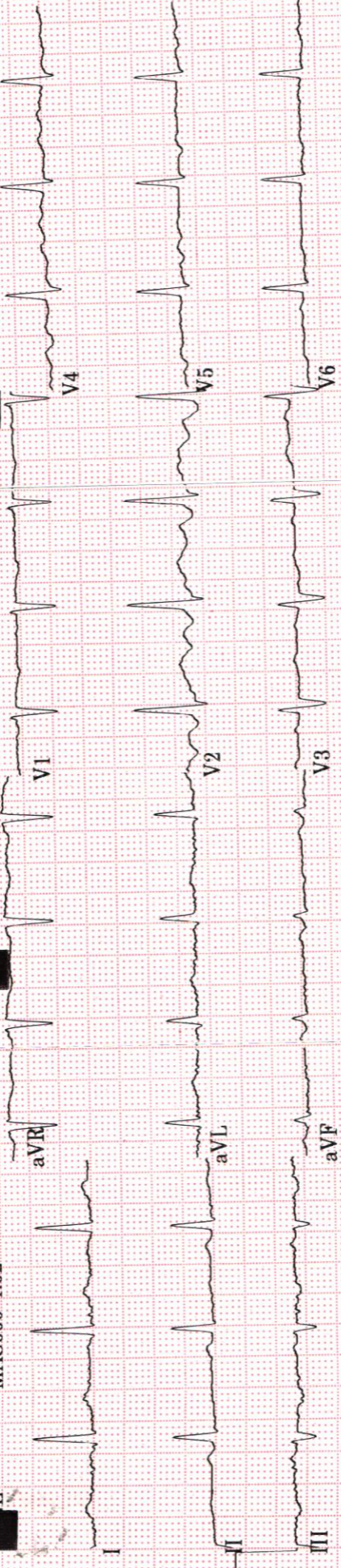
8-Dec-2022 9:53:51

ID: 8469450567

FE

Singh, Aruna

44years Female



Vent. rate 88 bpm
 QRS duration 90 ms
 QT/QTc 384/464 ms
 PR interval 198 ms
 P duration 150 ms
 RR interval 681 ms
 P-R-T axes 65 15 -12

MAC600 1.02 12SL™ v239

4 by 2.5s

50Hz 88 bpm

25.0 mm/s 10.0 mm/mV

0.16-20Hz

Malik Radix HealthCare.

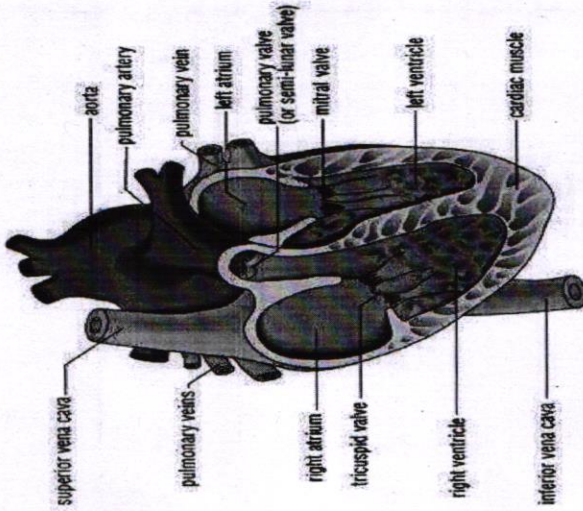
ELECTROCARDIOGRAM

Name: MRS. DIVYA SHARMA

Age & Sex: 44YR/FEMALE

Ref by: MEDIWHEEL

Date: 08/12/2022



ECG FINDINGS:

Rate 88bpm Rhythm Sinus Mechanism Normal

Axis Normal P Wave Normal PR Interval 0.19/Sec

QRS Complex Normal QT Interval Normal Q Wave Normal

ST Segment Normal T Wave Normal

Conclusion Sinus Rhythm, Normal Axis, TWNL.


 Dr. SHEIKH NAJAR AHMED
 M.D. "Physician"
 PGDCC
 DMC-46499

Doctors Signature



LAB REPORT

Reg. Date	08/12/2022	Patient Id	2212080002	DOB.	01/10/1978
Name	MRS. DIVYA SHARMA			Perm. ID	
Age	44 Yrs. 2 Mn. 8 Day	Gender	F	Reported	08/12/2022 17:51:36
Ref. By	MEDIWHEEL	Panel	MEDIWHEEL		

Test Name	Result	Units	Ref. Range
MEDIWHEEL F ABOVE 40			

HAEMATOLOGY

COMPLETE HAEMOGRAM

HAEMOGLOBIN (HB%)	12.8	gm/dl	12 - 15
TOTAL LEUCOCYTE COUNT (TLC)	8,300	/cumm	4000 - 11000

DIFFERENTIAL LEUCOCYTE COUNT (DLC)

NEUTROPHIL	69	%	40 - 80
LYMPHOCYTE	25	%	28 - 55
MONOCYTE	04	%	02 - 10
EOSINOPHIL	02	%	01 - 06
BASOPHIL	00	%	0 - 0
ESR (WESTEGREN'S METHOD)	16	mm/Ist hr.	0 - 15
R B C COUNT	3.82	Millions/cmm	4.247 - 5.4
P.C.V / HAEMATOCRIT	39.5	%	35 - 45
M C V	103.4	fl.	80 - 100
M C H	33.5	Picogram	27.0 - 31.0
M C H C	32.4	gm/dl	33 - 37
PLATELET COUNT	3.11	Lakh/cu mm	1.50 - 4.50

Urine Routine Examination

PHYSICAL EXAMINATION

QUANTITY	20	ml.	
COLOUR	Pale Yellow		Pale Yellow
TRANSPARENCY	Clear		
SPECIFIC GRAVITY	1.010		
PH	6.0		

Checked by : _____
Page 1 Contd...2

If test results are alarming or unexpected, patient is advised to contact the laboratory immediately for possible remedial action.

Facilities Available

- Multispeciality Hospital - 24 Hours Emergency - X-Ray/ ECG/ Ultrasound/ CT Scan - Dental - Fully Equiped Operation Theatre
- Fully Functional Lab - Casualty/ ICU-Nursery - Labour Room - All Speciality OPD - Laproscopic Surgery - ECHO - Plastic Surgery



LAB REPORT

Reg. Date	08/12/2022	Patient Id	2212080002	DOB.	01/10/1978
Name	MRS. DIVYA SHARMA			Perm. ID	
Age	44 Yrs. 2 Mn. 8 Day	Gender	F	Reported	08/12/2022 17:51:36
Ref. By	MEDIWHEEL	Panel	MEDIWHEEL		

Test Name	Result	Units	Ref. Range
CHEMICAL EXAMINATION			
ALBUMIN	Nil		
SUGAR	Nil		
MICROSCOPIC EXAMINATION			
PUS CELLS	0-1	/HPF	
RBC'S	Nil	/HPF	
CASTS	Nil		
CRYSTALS	NIL		
EPITHELIAL CELLS	0-1	/HPF	
BACTERIA	Nil		
OTHERS	Nil		
Stool Examination Report			
BLOOD GROUP ABO	" O "		
RH TYPING	Positive		
BLOOD SUGAR FASTING	77.06	mg/dl	70 - 100
BLOOD SUGAR PP	99.00	mg/dl	90 - 140
HB A1C	4.92	%	

Interpretation

Non Diabetic	: 4-6%
Good Diabetic Control	: 6-8%
Fair Control	: 8-10%

Checked by : _____
Page 2 Contd...3

If test results are alarming or unexpected, patient is advised to contact the laboratory immediately for possible remedial action.

Facilities Available

- Multispeciality Hospital - 24 Hours Emergency - X-Ray/ ECG/ Ultrasound/ CT Scan - Dental - Fully Equipped Operation Theatre
- Fully Functional Lab - Casualty/ ICU-Nursery - Labour Room - All Speciality OPD - Laproscopic Surgery - ECHO - Plastic Surgery



LAB REPORT

Reg. Date	08/12/2022	Patient Id	2212080002	DOB.	01/10/1978
Name	MRS. DIVYA SHARMA	Gender	F	Perm. ID	
Age	44 Yrs. 2 Mn. 8 Day	Panel	MEDIWHEEL	Reported	08/12/2022 17:51:36
Ref. By	MEDIWHEEL				

Test Name	Result	Units	Ref. Range
Poor Control	:>10%		

The Glycosylated haemoglobin assay has been validated as a reliable indicator Of mean blood glucose levels for a period of 8-12 week period. ADA recommended the testing twice a year in patients with stable blood glucose and quarterly. If treatment change, or if blood glucose levels are unstable.

TO BE CORRELATED CLINICALLY.

THYROID PROFILE

Free T3 ELFA	2.31	ng/ml	02 - 04
Free T4 ELFA	1.12	ug/dl	0.8 - 2.7
TSH Serum/ELFA	1.150	uIU/ml	0.25 - 5.50 uIU/ml

Interpretation

Clinical Use

- Diagnose Hypothyroidism and Hyperthyroidism
- Monitor T4 replacement or T4 suppressive Therapy
- Quantify TSH levels in the subnormal range

Increased Levels : Primary Hypothyroidism Subclinical Hypothyroidism, TSH dependent, Thyroid Hormone Resistance.

Decreased Levels : Grave's Disease, Autonomous Thyroid Hormone Secretion, TSH Deficiency

LIPID PROFILE

TOTAL CHOLESTEROL	183.90	mg/dL	130.0 - 200.0 (<200)
-------------------	--------	-------	-------------------------

Checked by : _____
 Page 3 Contd...4

If test results are alarming or unexpected, patient is advised to contact the laboratory immediately for possible remedial action.

Facilities Available

- Multispeciality Hospital - 24 Hours Emergency - X-Ray/ ECG/ Ultrasound/ CT Scan - Dental - Fully Equipped Operation Theatre
- Fully Functional Lab - Casualty/ ICU-Nursery - Labour Room - All Speciality OPD - Laproscopic Surgery - ECHO - Plastic Surgery



LAB REPORT

Reg. Date	08/12/2022	Patient Id	2212080002	DOB.	01/10/1978
Name	MRS. DIVYA SHARMA	Gender	F	Perm. ID	
Age	44 Yrs. 2 Mn. 8 Day	Panel	MEDIWHEEL	Reported	08/12/2022 17:51:36
Ref. By	MEDIWHEEL				

Test Name	Result	Units	Ref. Range
TRIGLYCERIDES	154.90	mg/dL	80.5 - 150.0 (<150)
H D L CHOLESTEROL DIRECT	65.11	mg/dL	42.0 - 60.0 (<40->59)
V L D L	31.0	mg/dL	4.0 - 30. (23-45)
L D L CHOLESTEROL	87.8	mg/dL	50.0 - 150.0 (50-150)
TOTAL CHOLESTEROL / HDL RATIO	2.8		3.3 - 5.1
LDL / HDL CHOLESTEROL RATIO	1.3		1.5 - 3.5
SERUM URIC ACID	4.10	mg/dl	2.4 - 6.0
BLOOD UREA NITROGEN (BUN)	12.90	mg/dl	6.0 - 21.0
SERUM CREATININE	0.90	mg/dl	0.6 - 1.2
BUN/CREAT RATIO	14.3	mg/dl	
<u>LIVER FUNCTION TEST (LFT)</u>			
BILIRUBIN TOTAL	1.02	mg/dl	0.2 - 1.2
CONJUGATED (D. BILIRUBIN)	0.62	mg/dl	0.00 - 0.3
UNCONJUGATED (I.D. BILIRUBIN)	0.40	mg/dl	0.2 - 0.9
SGOT / AST	32.92	IU/L	0 - 35
SGPT / ALT	36.32	IU/L	0 - 35
ALKALINE PHOSPHATASE	81.20	U/L	64 - 306
TOTAL PROTEIN	7.90	gm/dl	6.0 - 8.3
ALBUMIN	5.15	gm/dl	3.2 - 5.0
GLOBULIN	2.75	gm/dl	2.5 - 5.6
A/G RATIO	1.87		0.9 - 2.0
GAMMA GT	25.60	IU/L	0.0 - 35.0

10 - 20

Dr. REEMA DAHIYA
M.B.B.S., MD (Path)
DR. REEMA DAHIYA
M.B.B.S., MD (Path)
Checked by

DR. MEENU AGGARWAL
M.B.B.S., MD (Path.)

If test results are alarming or unexpected, patient is advised to contact the laboratory immediately for possible remedial action.

Facilities Available

- Multispeciality Hospital - 24 Hours Emergency - X-Ray/ ECG/ Ultrasound/ CT Scan - Dental - Fully Equipped Operation Theatre
- Fully Functional Lab - Casualty/ ICU-Nursery - Labour Room - All Speciality OPD - Laproscopic Surgery - ECHO - Plastic Surgery



MALIK RADIX HEALTH CARE

(UNIT OF MALIK RADIX HEALTHCARE PVT. LTD)

C-217, 218, Nirman Vihar, Vikas Marg, New Delhi - 110092

Tel.: 011-22011192, 22011196, 47060150 • Fax.: 22011208

E-mail : radixhealthcare@yahoo.co.in

Website : www.radixhealthcare.org



Safety at WEI now
accredited by NABH

Echocardiogram Report

Patient Name	MRS. DIVYA SHARMA
Date of Test	08/12/2022
Age	44 YRS/FEMALE
Ref. by	MEDIWHEEL

Dimensions	Result	Normal Range
AO (ed)	2.7 cm	(2.1 -3.7cm)
LA (es)	3.6 cm	(2.1 -3.7cm)
RVID (ed)	2.6 cm	(1.1-3.0cm)
LVID (ed)	4.4 cm	(3.6 – 5.5 cm)
LVID (es)	3.0 cm	(2.3-3.9cm)
IVS (ed)	1.2 cm	(0.6 – 1.2 cm)
LVPW (ed)	1.2 cm	(0.6 – 1.2 cm)
EF	60 %	
FS	30 %	(28 % - 42 %)

Impression

NO REGIONAL WALL MOTION ABNORMALITY SEEN.

LVEF= 60 %.

NORMAL CHAMBERS DIMENSIONS.

MILD CONCENTRIC LV HYPERTROPHY.

NORMAL COLOR FLOW.

NORMAL MIP

NO INTRA CARDIAC CLOT/MASS/ VEGETATION/PERICARDIAL EFFUSION SEEN.

Dr. Nishant Tyagi
(M.D. Medicine. DNB Cardiology)
(Senior Consultant, Cardiology)

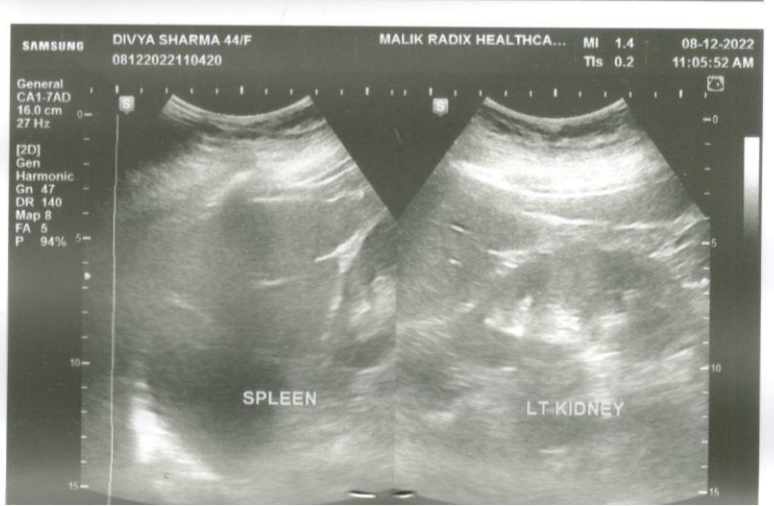
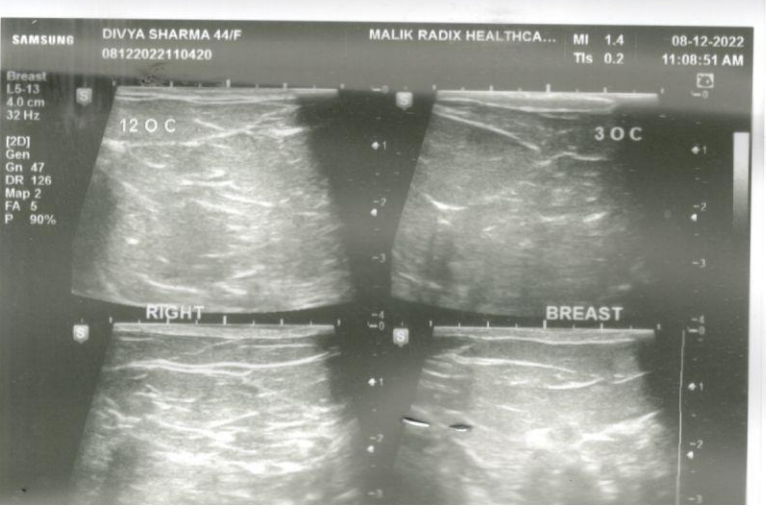
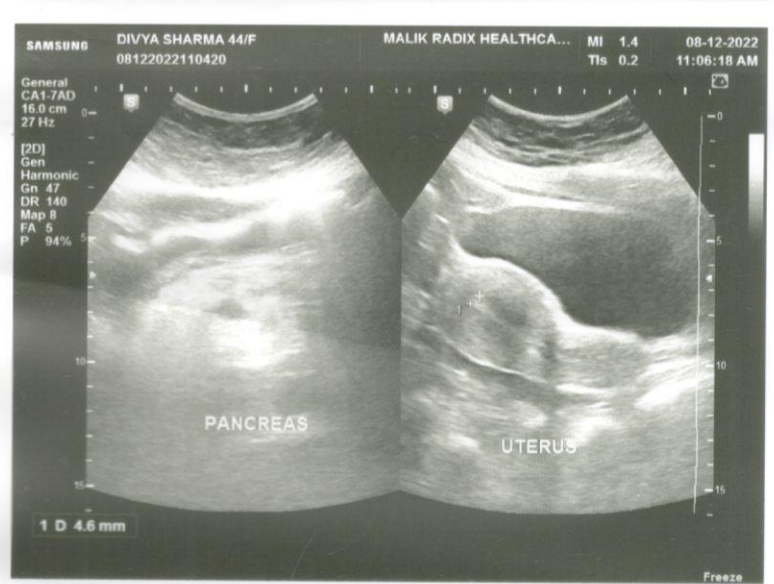
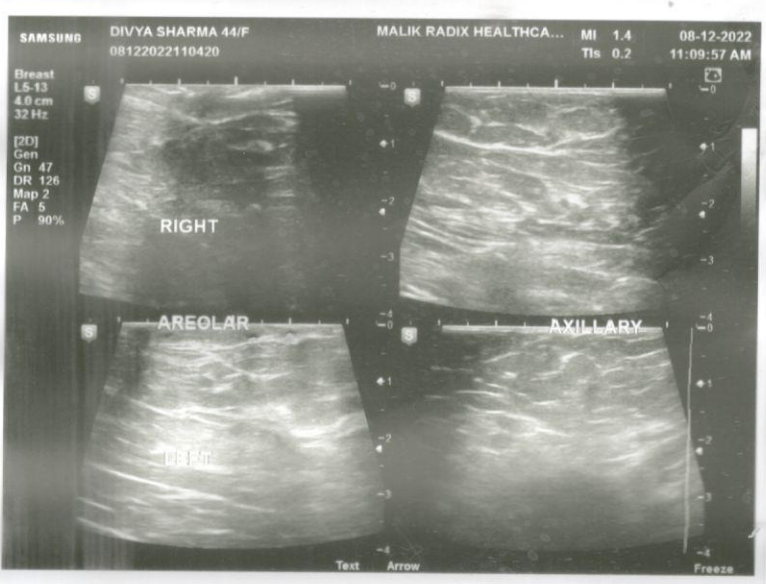
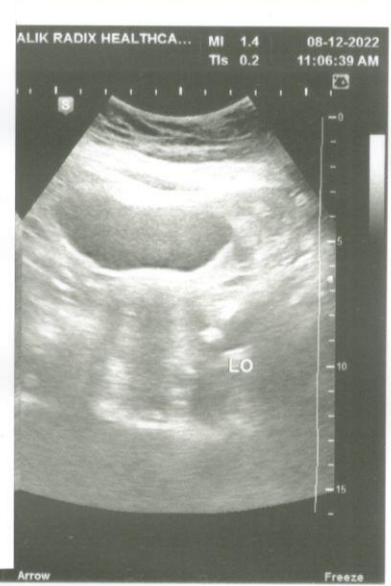
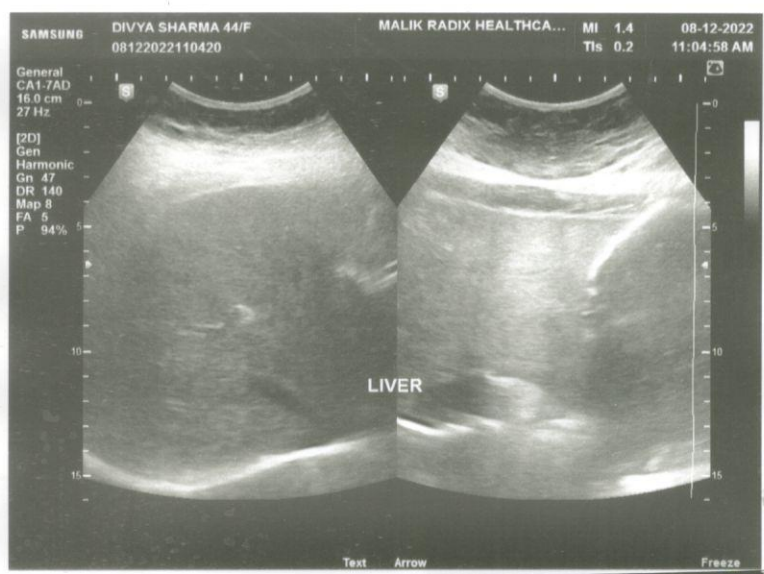
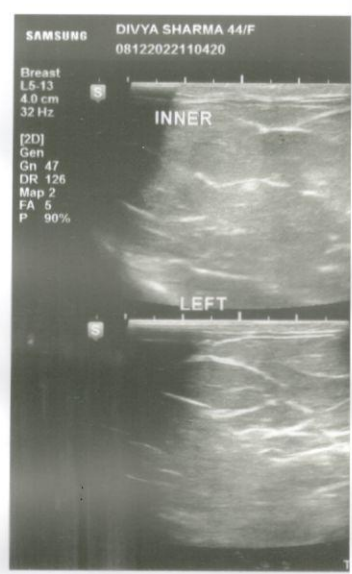
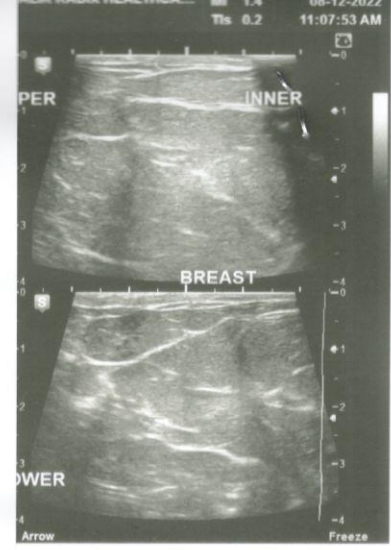
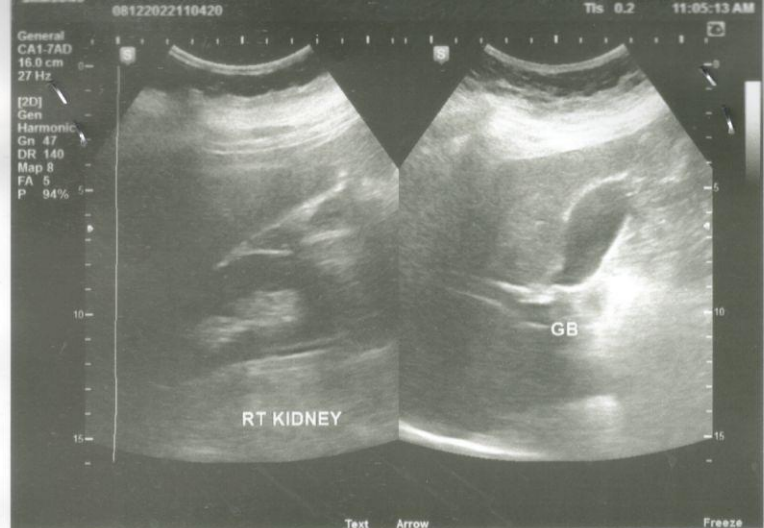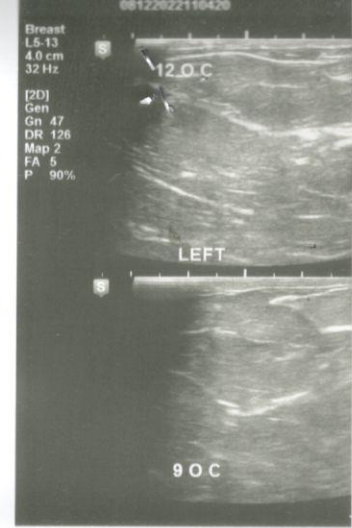
Dr. Sheikh Nazir Ahmed
M.D. "Physician" PGDCC
(Consultant Non – Invasive Cardiologist)

Facilities Available :

MRHC / GEN / FR / 15

- ★ Multispeciality Hospital
- ★ 24 Hours Emergency
- ★ X-Ray/ ECG/ Ultrasound
- ★ Dental
- ★ Fully Equipped Operation Theatre
- ★ Fully Functional Lab
- ★ Casualty/ICU
- ★ Nursery
- ★ Labour Room
- ★ All Speciality OPD
- ★ Laparoscopic Surgery
- ★ ECHO
- ★ Plastic Surgery

Home Collection Facility Available Contact : 8587915647





MALIK RADIX HEALTH CARE

(UNIT OF MALIK RADIX HEALTHCARE PVT. LTD)

C-217, 218, Nirman Vihar, Vikas Marg, New Delhi - 110092

Tel.: 011-22011192, 22011196, 47060150 • Fax.: 22011208

E-mail : radixhealthcare@yahoo.co.in

Website : www.radixhealthcare.org



Safety at WEI now
accredited by NABH

NAME	MRS DIVYA SHARMA	AGE	44 Y/F
REFD. BY.	HEALTH CHECK UP	DATE	08.12.22

Ultrasound Examination of Breasts:

US examination of both breasts was performed using a high frequency probe.

On US both breasts show the normal appearances of adult breasts.
Normal echogenic adipose tissue is seen. The glandular elements are normal.
The fibrous tissue stroma is well defined.
No evidence of any SOL or abnormal calcification seen.
No evidence of any abscess seen.
Areolar and axillary regions are normal.

NORMAL STUDY.

Regards.


Dr Mukesh Koshal MD (Rad- diag)
Regn. No. DMC 10407

RADIOLOGIST :

MRHC / GEN / FR / 15

Facilities Available :

- ★ Multispeciality Hospital ★ 24 Hours Emergency ★ X-Ray/ ECG/ Ultrasound ★ Dental
- ★ Fully Equipped Operation Theatre ★ Fully Functional Lab ★ Casualty/ICU ★ Nursery
- ★ Labour Room ★ All Speciality OPD ★ Laparoscopic Surgery ★ ECHO ★ Plastic Surgery

Home Collection Facility Available Contact : 8587915647

NAME	MRS DIVYA SHARMA	AGE	44 Y/F
REFD. BY.	HEALTH CHECK UP	DATE	08.12.22

Ultrasound Examination of Whole Abdomen & Pelvis :

Liver: Liver shows grade 1 fatty change . No focal SOL is seen in liver. IHBR & portal radicles are normal.

Gallbladder: Gallbladder shows normal anechoic pattern. No evidence of cholecystitis or cholelithiasis seen. Common bile duct is normal in course & caliber.

Pancreas: Pancreas shows normal size & echotexture.

Spleen: Spleen shows normal size, outline & echotexture.

Kidneys: Kidneys show normal size, shape, position & echotexture. No calculus, hydronephrosis or SOL is seen in kidneys. Cortico- medullary differentiation and cortical thickness is normal on both sides.

No supra- renal mass seen.

Great abdominal vessels are normal.

Domes of diaphragm are seen to move normally & synchronously in respiration. No infra- or supradiaphragmatic collection seen.

No ascites or pericardial effusion seen.

No para aortic lymph nodes seen.

Urinary bladder: Urinary bladder shows normal anechoic pattern. No calculus, SOL or diverticulum seen.

Uterus: Uterus is anteverted and normal in size & echotexture. No intrinsic SOL is seen in uterus. Endometrial thickness is 4.6 mm.

Adnexa: Adnexal regions including the ovaries are sonographically normal.

IMP- GRADE 1 FATTY LIVER

Regards.


CM
Dr Mukesh Koshal MD (Rad- diag)
 Regn. No. DMC 10407

RADIOLOGIST :

R

DIVYA SHARMA 44 Y/F PI176074 CHEST PA 08/Dec/2022 09:38 AM

UHID	PT176074	LAB No.	XRY2207283
Name	Mrs. DIVYA SHARMA	Regn. No.	GEN2230912
Age / Sex	44 Yrs / F	Receiving Dt/Time	08/Dec/2022 09:38
		Reporting Dt/Time	08/Dec/2022 10:40 AM



XRAY

CHEST (PA)

Both lung fields are normal.

Cp angles are clear.

Hila are normal...


Heart size appears within normal limits.

Soft tissue shadows and bony thorax are normal.

IMP- NORMAL CHEST X-RAY

Advised....please correlate clinically.

***** END OF REPORT *****


DR. K.K. SINHA
M.B.B.S. D.M.R.D.
SENIOR CONSULTANT
Reg. No. 25437 (DMC)

DR. RAJESH MALHOTRA
MBBS, MD (RADIOLOGY)
CONSULTANT RADIOLOGY
Reg.No.DMC9299

DR. T. K VOHRA
MD (RADIODIAGNOSIS)
SENIOR CONSULTANT
Reg. No. 3272 (DMC)

DR. MUKESH KOSHAL
MBBS, MD (RADIOLOGY)
CONSULTANT RADIOLOGY
Reg.No.DMC10407