



PANACEA HOSPITAL

B 36/44 F.K KABIR NAGAR, DURGAKUND
TOLLFREE NO-18001233070. Whatsapp No - 8795832852
www.piire.org
panaceaquery@gmail.com|panceahospitalit@gmail.com



OP Slip

Print Date : 24-Feb-2024 12:27PM



UHID No :- UD-23240006398	OP No :- OP-23240019608	OP Date :- 24 Feb 2024 12:23PM
Patient Name :- Mr IQBAL FAHIM KHAN	Age/Sex :- 33 Y/Male	Mobile No :- 8839563405
Father :- FAHIM AHMAD KHAN	Department :- GENERAL MEDICINE	
Pay Type :- Cr	Consultant :- Dr Pallavi Mishra (MBBS,MD,MBBS)	
Token No :- NOR. - 19	Paid/Bal :- 0.00 /1030.00	
Patient Type :- Normal		
Address :- HO NO G-108, P.C COLONY, KANKARBAGH, PATNA, 800020, BIHAR		

BP :- 100/70

height :- 165

Weight (kg) :- 85

BMI :-

~~Rx~~

~~PC 38~~

~~WC 110'~~

~~CH 109~~

~~SP02 98~~

~~PR 106~~

~~PLPR 200~~

~~AW~~

~~EEG~~

~~co-synkpinat.~~

Rx.

As. Amyeloheli (1000) Or

As. Roumy (20) Or

As. (60) AD x 10

↓

WHITM

R/A 10 days

Printed By : Mr Nitin Kumar Yadav
Created By : Mr Nitin Kumar Yadav

Pallavi Mishra

DR. Pallavi Misra
MBBS, MD(GENERAL MEDICINE)
MCI Reg. No.52033



PANACEA HOSPITAL

B 36/44 F.K KABIR NAGAR, DURGAKUND
TOLLFREE NO-18001233070. Whatsapp No - 8795832852
www.piire.org
panaceaquery@gmail.com|panceahospitalit@gmail.com



OP Slip

Print Date : 24-Feb-2024 12:39PM



UHID No :- UD-23240006398	OP No :- OP-23240019612	OP Date :- 24 Feb 2024 12:38PM
Patient Name :- Mr IQBAL FAHIM KHAN	Age/Sex :- 33 Y/Male	Mobile No :- 8839563405
Father :- FAHIM AHMAD KHAN	Department :- DENTAL	
Pay Type :- Cr	Consultant :- Dr SHRUTI MISHRA (AA)	
Token No :- NOR. - 12	Paid :- 0.00	
Patient Type :- Normal		
Address :- HO NO. G-108, P.C COLONY, KANKARBAGH ,PATNA,800020,BIHAR		

BP :-
height :-
Weight (kg) :-
BMI :-

Rx c/c => patient came for routine dental check up.

O/E => stain / calculus - ++/++

P/O => chronic gen gingivitis

T/A => scaling & polishing

To pay - 1000

Shruti
Dr. SHRUTI MISHRA
— BDS, (DENTIST)
MCI Reg. No. (A-09784)

Printed By : Mr Nitin Kumar Yadav
Created By : Mr Nitin Kumar Yadav



PANACEA HOSPITAL

B 36/44 F.K KABIR NAGAR, DURGAKUND
TOLLFREE NO-18001233070. Whatsapp No - 8795832852
www.piire.org
panaceaquery@gmail.com|panceahospital@gmail.com



OP Slip

Print Date : 24-Feb-2024 12:39PM



UHID No :- UD-23240006398	OP No :- OP-23240019613	OP Date :- 24 Feb 2024 12:39PM
Patient Name :- Mr IQBAL FAHIM KHAN	Age/Sex :- 33 Y/Male	Mobile No :- 8839563405
Father :- FAHIM AHMAD KHAN	Department :- DERMATOLOGY	
Pay Type :- Cr	Consultant :- Dr RAVI BHUSHAN (MBBS,MD)	
Token No :- NOR. - 11	Paid/Bal :- 0.00 /1000.00	
Patient Type :- Normal		
Address :- HO NO. G-108, P.C COLONY, KANKARBAGH ,PATNA,800020,BIHAR		

BP :-
height :-
Weight (kg) :-
BMI :-

Rx SIBL Reg Insulin

No skin abnormality

→ Mometridil 5% salm
= 1ml LABD(H)
1 Tab Reelima Plus
1 tab

Free 7 days

x 4
CWB

Printed By : Mr Nitin Kumar Yadav

Created By : Mr Nitin Kumar Yadav



PANACEA HOSPITAL

B 36/44 F.K KABIR NAGAR, DURGAKUND
TOLLFREE NO-18001233070. Whatsapp No - 8795832852
www.piire.org
panaceaquery@gmail.com|panceahospitalit@gmail.com



OP Slip

Print Date : 24-Feb-2024 12:40PM



UHID No :- UD-23240006398	OP No :- OP-23240019614	OP Date :- 24 Feb 2024 12:40PM
Patient Name :- Mr IQBAL FAHIM KHAN	Age/Sex :- 33 Y/Male	Mobile No :- 8839563405
Father :- FAHIM AHMAD KHAN	Department :- OPHTHALMOLOGY	
Pay Type :- Cr	Consultant :- Dr SANTOSH VERMA (MBBS,MS)	
Token No :- NOR. - 12	Paid :- 0.00	
Patient Type :- Normal		
Address :- HO NO. G-108, P.C COLONY, KANKARBAGH, PATNA, 800020, BIHAR		

BP :-
height :-
Weight (kg) :-
BMI :-

Rx

VA < 6/6 4/4
6/6 4/4

BE ant. segmt: WNL

BE Central fundus: WNL

3. Cap 2 FORTY PLUS 1000 Viny
B/C
9. LUBSTONE ULTRA 735

Ass. - Annulara. |

Printed By : Mr Nitin Kumar Yadav
Created By : Mr Nitin Kumar Yadav

Dr. SANTOSH VERMA
MBBS, MS (Ophthalmologist)
MCI Reg. No. 09-34327

Facilities:

All clinical Biomedical & Hematology Investigations including Bone Marrow Examination
VPT, Podiascan & Complete Foot Care (First Time in Purvanchal)
All Hormonal Investigation by Chemiluminescent Method
Visceral Fat by (AB-140) Ambulatory BP Monitoring
CGMS & Insulin Pump Available
PFT, 2D-ECHO (Color Doppler), Holter, TMT, Cardiac-3 available
VIA, VILI, Colposcopy available
Special Endocrinological Investigation Protocols.

ISO 9001:2008 Certified
Mobile: 9389994334, 9554572190, 9453837595



Panacea Pathology

Clinical Reference Lab

Persistence, Preparedness and Precision
EQAS (CMC Vellore Attached) & IQAS System
पूर्वांचल की सर्वोत्तम गुणवत्ता वाली पैथोलॉजी

UHID No :- UD-23240006398
Patient Name :- Mr IQBAL FAHIM KHAN
Father :- FAHIM AHMAD KHAN
Address :- HO NO. G-108, P.C COLONY, KANKARBAGH, PATNA, 800020, BIHAR
Consultant :- Dr Pallavi Mishra (MBBS, MD)

Booking No/Date :- 190 / 24-Feb-2024 05:54 PM
Age/Sex :- 33 Y/M
OP No :- OP-23240019608
Mobile No :- 8839563405

Investigations	Observations	Biological Ref. Interval	Unit
HAEMATOLOGY			
CBC			
HAEMOGLOBIN <small>DefaultMethod / test Machine</small>	14.3	13.00 - 16.00	gm/dl
TLC <small>Methology / Carm</small>	6,900	4000.00 - 11000.00	Cells/cumm.
DLC DIFFERENTIAL LEUCOCYTE COUNT			
NEUTROPHILS	52	40.00 - 75.00	%
LYMPHOCYTES	39	20.00 - 45.00	%
EOSINOPHILS	04	1.00 - 6.00	%
MONOCYTES	05	2.00 - 10.00	%
BASOPHILS	00	<1-2	%
PLATELET COUNT	1.35	1.50 - 4.10	lacs /cumm
PCV	45.6	33.00 - 42.00	%
RBC <small>Methology / Carm</small>	5.21	4.50 - 5.50	million/cumm
MCV(MEAN CELL VOLUME)	87.5	83.00 - 101.00	fl
MCH(MEAN CELL HAEMOGLOBIN)	27.5	27.00 - 32.00	pg
MCHC	31.4	31.50 - 35.00	gm%
RDW-CV	13.6	11.00 - 16.00	%
RDW-SD	48.1	37.00 - 57.00	fl

Lab Technician

Consulting Pathologist
DR. UMESH KUMAR
MBBS, MD (PATHOLOGIST)
MCD, Pathology

Timing : 24/7 hrs

This Report is not valid for medico legal purpose

Note: These tests have technical limitations. Clinico-pathological interpretation is necessary. In case of any disparity test may be repeated immediately.

Address : 36/44 FK Kabir Nagar, Durgakund, Varanasi – 221005

Email: dramishra@gmail.com, drpallaviojha@gmail.com Website: panaceahospital.org

Facilities:

All clinical Biomedical & Hematology Investigations including Bone Marrow Examination
VPT, Podiascan & Complete Foot Care (First Time in Purvanchal)
All Hormonal Investigation by Chemiluminescent Method
Visceral Fat by (AB-140) Ambulatory BP Monitoring
CGMS & Insulin Pump Available
PFT, 2D-ECHO (Color Doppler), Holter, TMT, Cardiac-3 available
VIA, VILI, Colposcopy available
Special Endocrinological Investigation Protocols.

ISO 9001:2008 Certified
Mobile: 9389994334, 9554572190, 9453837595



Panacea Pathology

Clinical Reference Lab

Persistence, Preparedness and Precision
EQAS (CMC Vellore Attached) & IQAS System
पूर्वांचल की सर्वोत्तम गुणवत्ता वाली पैथोलॉजी

UHID No	:- UD-23240006398	Booking No/Date	:- 190 / 24-Feb-2024 05:54 PM
Patient Name	:- Mr IQBAL FAHIM KHAN	Age/Sex	:- 33 Y/M
Father	:- FAHIM AHMAD KHAN	OP No	:- OP-23240019608
Address	:- HO NO. G-108, P.C COLONY, KANKARBAGH, PATNA, 800020, BIHAR	Mobile No	:- 8839563405
Consultant	:- Dr Pallavi Mishra (MBBS,MD)		

Investigations	Observations	Biological Ref. Interval	Unit
----------------	--------------	--------------------------	------

URINE EXAMINATION

URINE ROUTINE EXAMINATION

PHYSICAL EXAMINATION

QUANTITY 25 ml

COLOR STRAW CLEAR YELLOW
Methology

APPEARANCE CLEAR CLEAR
DefaultMethod

CHEMICAL EXAMINATION

SPECIFIC GRAVITY 1.015 1.01 - 1.03

PH 6.0 4.60 - 8.00

GLUCOSE NIL 60.00 - 100.00 mg/dl

PROTEIN- NIL

MICROSCOPIC EXAMINATION

PUS CELLS NIL 2.00 - 3.00 /HPF

RBCS (RED BLOOD CELLS) NIL 4.50 - 5.50 /HPF

EPITHELIAL CELLS 01-02 /HPF

CASTS ABSENT ABSENT

CRYSTALS ABSENT ABSENT

Lab Technician

Consulting Pathologist
DR. UMESH KUMAR
MBBS, MD (PATHOLOGIST)
MD Pathology

Timing : 24/7 hrs

This Report is not valid for medico legal purpose

Note: These tests have technical limitations. Clinico-pathological interpretation is necessary. In case of any disparity test may be repeated immediately.

Address : 36/44 FK Kabir Nagar, Durgakund, Varanasi – 221005

Email: dramishra@gmail.com, drpallaviojha@gmail.com Website: panaceahospital.org

Facilities:

All clinical Biomedical & Hematology Investigations including Bone Marrow Examination
VPT, Podiascan & Complete Foot Care (First Time in Purvanchal)
All Hormonal Investigation by Chemiluminescent Method
Visceral Fat by (AB-140) Ambulatory BP Monitoring
CGMS & Insulin Pump Available
PFT, 2D-ECHO (Color Doppler), Holter, TMT, Cardiac-3 available
VIA, VILI, Colposcopy available
Special Endocrinological Investigation Protocols.

ISO 9001:2008 Certified
Mobile: 9389994334, 9554572190, 9453837595



Panacea Pathology

Clinical Reference Lab

Persistence, Preparedness and Precision
EQAS (CMC Vellore Attached) & IQAS System
पूर्वाचल की सर्वोत्तम गुणवत्ता वाली पैथोलॉजी

UHID No :- UD-23240006398
Patient Name :- Mr IQBAL FAHIM KHAN
Father :- FAHIM AHMAD KHAN
Address :- HO NO. G-108, P.C COLONY, KANKARBAGH, PATNA, 800020, BIHAR
Consultant :- Dr Pallavi Mishra (MBBS, MD)

Booking No/Date :- 190 / 24-Feb-2024 05:54 PM
Age/Sex :- 33 Y/M
OP No :- OP-23240019608
Mobile No :- 8839563405

Investigations	Observations	Biological Ref. Interval	Unit
HAEMATOLOGY			
ESR	16.0	0.00 - 15.00	mm at 1 hr
BLOOD GROUP ABO & RH FACTOR			
BLOOD GROUP	"B"		
RH FACTOR	POSITIVE		
HBA1C -(BY GOLD STANDARD METHOD :HPLC)	6.4	Normal: 4.0 - 5.4 Prediabetic : 5.5 -6.3 Diabetes mellitus := 6.4	%
IMMUNOLOGY			
THYROID PROFILE (T3,T4,TSH)			
T3	1.09	0.60 - 1.81	ng/ml
T4	7.6	4.50 - 10.90	ug/dl
TSH	1.06	0.39 - 6.10	uIU/mL
BIOCHEMISTRY			
BLOOD SUGAR FASTING			
GLUCOSE	103.0	60.00 - 100.00	mg/dl
PRE-DIABETICS(IMPAIRED FASTING TOLER)	-	100.00 - 125.00	mg/dl
DIABETICS	-	upto 126	mg/dl
TARGET IN DM	-	80.00 - 130.00	mg/dl

Lab Technician

Consulting Pathologist
DR. UMESH KUMAR
MBBS, MD (PATHOLOGIST)
MO. Reg. No. 3

Timing : 24/7 hrs

This Report is not valid for medico legal purpose

Note: These tests have technical limitations. Clinico-pathological interpretation is necessary. In case of any disparity test may be repeated immediately.

Address : 36/44 FK Kabir Nagar, Durgakund, Varanasi - 221005

Email: dramishra@gmail.com, drpallaviojha@gmail.com Website: panaceahospital.org

Facilities:

All clinical Biomedical & Hematology Investigations including Bone Marrow Examination
 VPT, Podiascan & Complete Foot Care (First Time in Purvanchal)
 All Hormonal Investigation by Chemiluminescent Method
 Visceral Fat by (AB-140) Ambulatory BP Monitoring
 CGMS & Insulin Pump Available
 PFT, 2D-ECHO (Color Doppler), Holter, TMT, Cardiac-3 available
 VIA, VILI, Colposcopy available
 Special Endocrinological Investigation Protocols.

ISO 9001:2008 Certified
 Mobile: 9389994334, 9554572190, 9453837595



Panacea Pathology

Clinical Reference Lab

Persistence, Preparedness and Precision
 EQAS (CMC Vellore Attached) & IQAS System
 पूर्वांचल की सर्वोत्तम गुणवत्ता वाली पैथोलॉजी

UHID No :- UD-23240006398
Patient Name :- Mr IQBAL FAHIM KHAN
Father :- FAHIM AHMAD KHAN
Address :- HO NO. G-108, P.C COLONY, KANKARBAGH, PATNA, 800020, BIHAR
Consultant :- Dr Pallavi Mishra (MBBS, MD)

Booking No/Date :- 190 / 24-Feb-2024 05:54 PM
Age/Sex :- 33 Y/M
OP No :- OP-23240019608
Mobile No :- 8839563405

Investigations	Observations	Biological Ref. Interval	Unit
----------------	--------------	--------------------------	------

BIOCHEMISTRY

LIPID PROFILE

TOTAL CHOLESTROL	137.0	Desirable : - < 200 mg/dL Borderline: - 200 - 239 mg/dL High : - > 240mg/dL	mg/dl
TRIGLYCERIDES	143.0	35.00 - 160.00	mg/dl
HDL CHOLESTROL	39.0	35.30 - 79.50	mg/dl
LDL CHOLESTROL	69.4	<130	mg/dl
VLDL	28.60	<40	mg/dl
CHOLESTROL/ HDL RATIO	3.51	<3.0 LOW RISK, 3.0-5.0 AVG RISK, >5.0 HIGH RISK	ratio
LDL/HDL RATIO	1.78	<3	ratio
RFT (RENAL FUNCTION TESTS)			
SERUM CREATININE	1.10	0.60 - 1.60	mg/dl
URIC ACID	3.82	3.60 - 7.70	mg/dl
YGGT	21.0	10.00 - 50.00	U/L

PARASITOLOGY

STOOL ROUTINE

GROSS EXAMINATON

COLOR METHOLOGY YELLOW CLEAR YELLOW

Lab Technician

Consulting Pathologist

Dr. Umesh Kumar
 MBBS, MD (PATHOLOGIST)
 M.D. Pathology
 MCI Reg. No. 4133

Timing : 24/7 hrs

This Report is not valid for medico legal purpose

Note: These tests have technical limitations. Clinico-pathological interpretation is necessary. In case of any disparity test may be repeated immediately.

Address : 36/44 FK Kabir Nagar, Durgakund, Varanasi - 221005

Email: dramishra@gmail.com, drpallaviojha@gmail.com Website: panaceahospital.org

Facilities:

All clinical Biomedical & Hematology Investigations including Bone Marrow Examination
 VPT, Podiascan & Complete Foot Care (First Time in Purvanchal)
 All Hormonal Investigation by Chemiluminescent Method
 Visceral Fat by (AB-140) Ambulatory BP Monitoring
 CGMS & Insulin Pump Available
 PFT, 2D-ECHO (Color Doppler), Holter, TMT, Cardiac-3 available
 VIA, VILI, Colposcopy available
 Special Endocrinological Investigation Protocols.

ISO 9001:2008 Certified
 Mobile: 9389994334, 9554572190, 9453837595



Panacea Pathology

Clinical Reference Lab

Persistence, Preparedness and Precision
 EQAS (CMC Vellore Attached) & IQAS System
 पूर्वांचल की सर्वोत्तम गुणवत्ता वाली पैथोलॉजी

UHID No :- UD-23240006398
Patient Name :- Mr IQBAL FAHIM KHAN
Father :- FAHIM AHMAD KHAN
Address :- HO NO. G-108, P.C COLONY, KANKARBAGH, PATNA, 800020, BIHAR
Consultant :- Dr Pallavi Mishra (MBBS, MD)

Booking No/Date :- 190 / 24-Feb-2024 05:54 PM
Age/Sex :- 33 Y/M
OP No :- OP-23240019608
Mobile No :- 8839563405

Investigations	Observations	Biological Ref. Interval	Unit
CONSISTANCY	NORMAL		
BLOOD	ABSENT		
MUCUS	ABSENT		
<u>MICROSCOPIC EXAMINATION</u>			
OVA OR EGGS OF HELMINTHS	ABSENT		
CYST OF PROTOZOA	ABSENT		
PUS CELLS	02-03	2.00 - 3.00	/HPF
RBC <i>Methology / Carm</i>	NIL	4.50 - 5.50	million/cumm

* END OF REPORT *

Lab Technician

Consulting Pathologist
 DR. UMESH KUMAR
 M.B.B.S, M.D (PATHOLOGIST)
 M.D. Pathology

Timing : 24/7 hrs

This Report is not valid for medico legal purpose

Note: These tests have technical limitations. Clinico-pathological interpretation is necessary. In case of any disparity test may be repeated immediately.

Address : 36/44 FK Kabir Nagar, Durgakund, Varanasi – 221005

Email: dramishra@gmail.com, drpallaviojha@gmail.com Website: panaceahospital.org

Facilities:

All clinical Biomedical & Hematology Investigations including Bone Marrow Examination
 VPT, Podiascan & Complete Foot Care (First Time in Purvanchal)
 All Hormonal Investigation by Chemiluminescent Method
 Visceral Fat by (AB-140) Ambulatory BP Monitoring
 CGMS & Insulin Pump Available
 PFT, 2D-ECHO (Color Doppler), Holtér, TMT, Cardiac-3 available
 VIA, VILI, Colposcopy available
 Special Endocrinological Investigation Protocols.

ISO 9001:2008 Certified
 Mobile: 9389994334, 9554572190, 9453837595



Panacea Pathology

Clinical Reference Lab

Persistence, Preparedness and Precision
 EQAS (CMC Vellore Attached) & IQAS System
 पूर्वांचल की सर्वोत्तम गुणवत्ता वाली पैथोलॉजी

UHID No	:- UD-23240006398	Booking No/Date	:- 190 / 24-Feb-2024 05:54 PM
Patient Name	:- Mr IQBAL FAHIM KHAN	Age/Sex	:- 33 Y/M
Father	:- FAHIM AHMAD KHAN	OP No	:- OP-23240019608
Address	:- HO NO. G-108, P.C COLONY, KANKARBAGH, PATNA, 800020 , BIHAR	Mobile No	:- 8839563405
Consultant	:- Dr Pallavi Mishra (MBBS,MD)		

Investigations	Observations	Biological Ref. Interval	Unit
BIOCHEMISTRY			
PPBS(POST PRANDIAL BLOOD SUGAR)			
POST PRANDIAL BLOOD GLUCOSE(2 HR AFTER MEAL)	139.0	110.00 - 150.00	mg/dl
IGT(2 HR 75GM GLUCOSE)	-	140.00 - 199.00	mg/dl
DIABETES	-	upto200	mg/dl
TARGET IN DM	-	80.00 - 130.00	mg/dl

* END OF REPORT *

Lab Technician

Timing : 24/7 hrs

Consulting Pathologist

Dr. Umesh Kumar
 MBBS, MD (PATHOLOGIST)
 M.D. Pathology
 MCI Reg. No. 41413

This Report is not valid for medico legal purpose

Note: These tests have technical limitations. Clinico-pathological interpretation is necessary. In case of any disparity test may be repeated immediately.



Call Now - 1800-123-3070

PANACEA HOSPITAL



A shelter for many hearts A Home for many lives

(An ISO 9001:2008 Certified Organisation)

Lab Attached with CMC Under EQAS Scheme

Dept. of Radiodiagnosis - 32 Slice CT Scan, 3D/4D USG, 2D ECHO, Colour Doppler, Intervention Procedures, Digital X-Ray

NAME: IQBAL FAHIM KHAN

AGE/SEX: 33YRS/MALE


REF.DR. ASHUTOSH MISHRA (MD)

DATE: 24/02/2024

ULTRASOUND WHOLE ABDOMEN REPORT

<u>Liver:</u>	Normal in size, shape, & echogenicity. Intra & extra hepatic biliary radicals & vascular structures are normal. Margins are smooth and regular.
<u>Gall bladder</u>	Normally distended with echo free lumen.
<u>Portal vein:</u>	Normal in course and caliber.
<u>CBD diameter:</u>	Visualized part normal in course & caliber.
<u>Pancreas:</u>	Normal in size, shape & echogenicity. Margins are smooth & regular. No diffuse/ focal lesion seen. Pancreatic duct not visualized.
<u>Spleen:</u>	Normal in size, shape & echogenicity. Margins are smooth & regular. No diffuse / focal lesion seen.
<u>Kidney:</u>	Both normal in size, shape echogenicity & position. Cortical-medullary differentiation is maintained. Pelvicalyceal system normal. No evidence of any calculus/mass lesion seen No hydronephrosis/ hydroureter seen. No suprarenal mass lesion.
<u>Urinary bladder:</u>	Normally distended with normal wall thickness. No echogenic foci lumen or diverticula seen. Both VUJ appears normal. No evidence of calculus / mass lesion seen.
<u>Prostate:</u>	Normal in size, shape & echogenicity.
<u>Others:</u>	No free fluid in peritoneal cavity. No free fluid in bilateral pleural cavity. No evidence of significantly enlarged retroperitoneal/ mesenteric lymph nodes noted.
<u>IMPRESSION:</u> -	NO OBVIOUS SONOLOGICAL ABNORMALITY SEEN.

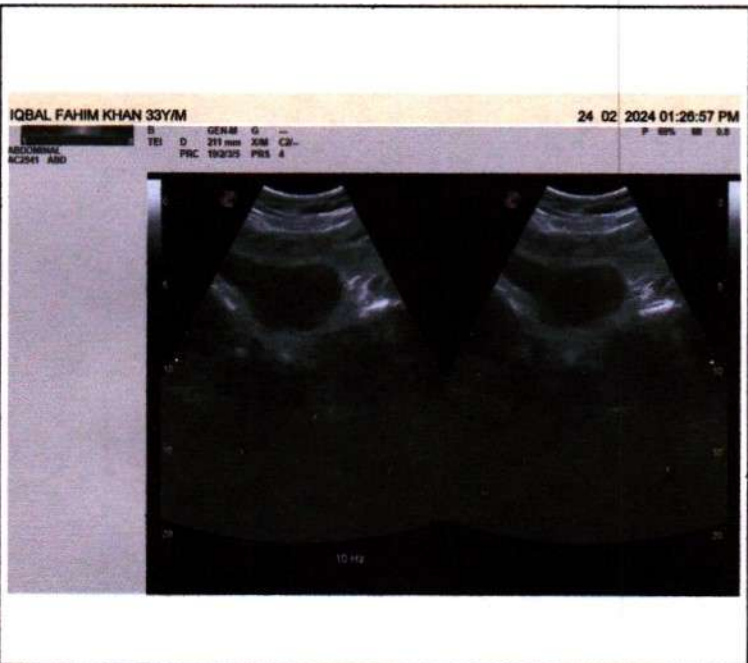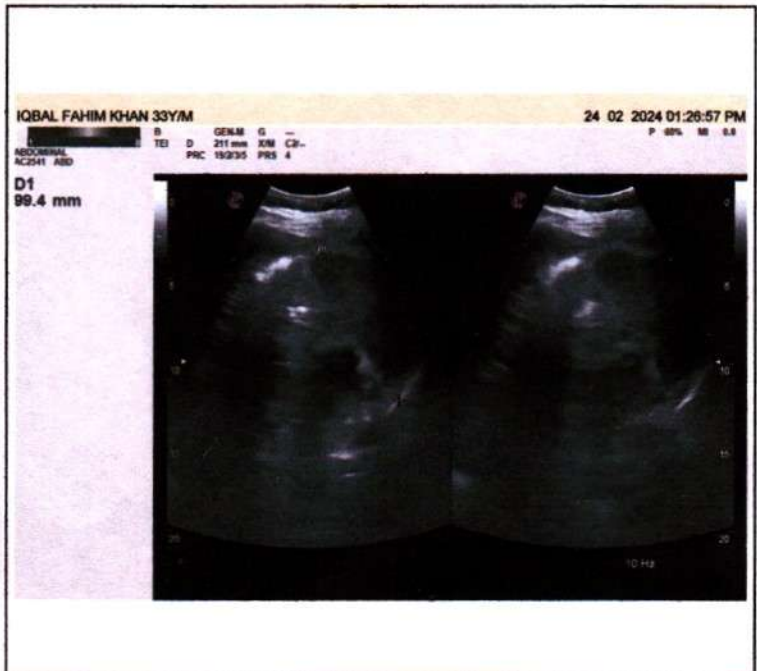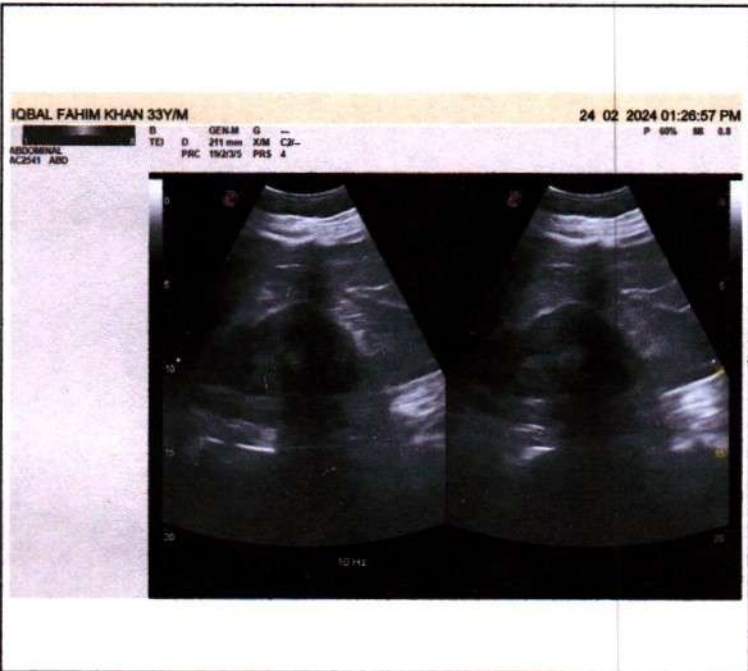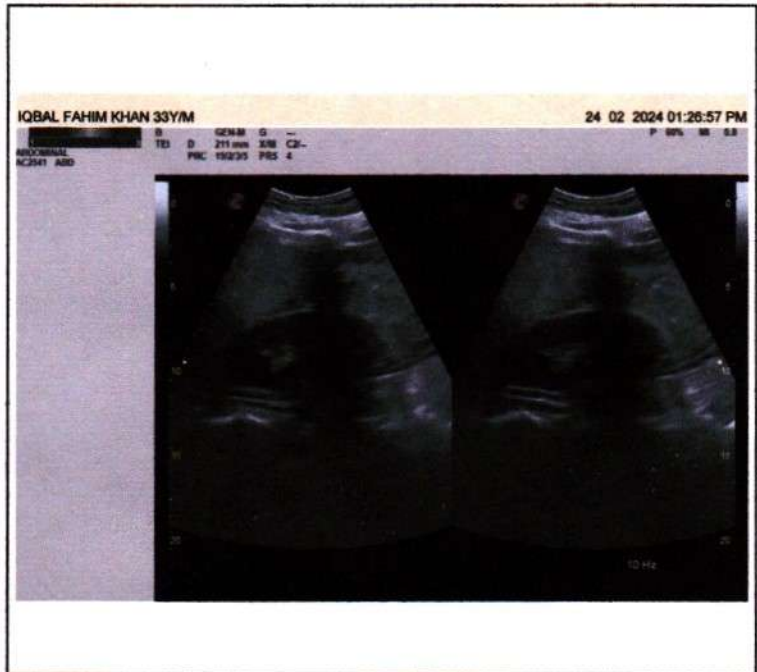
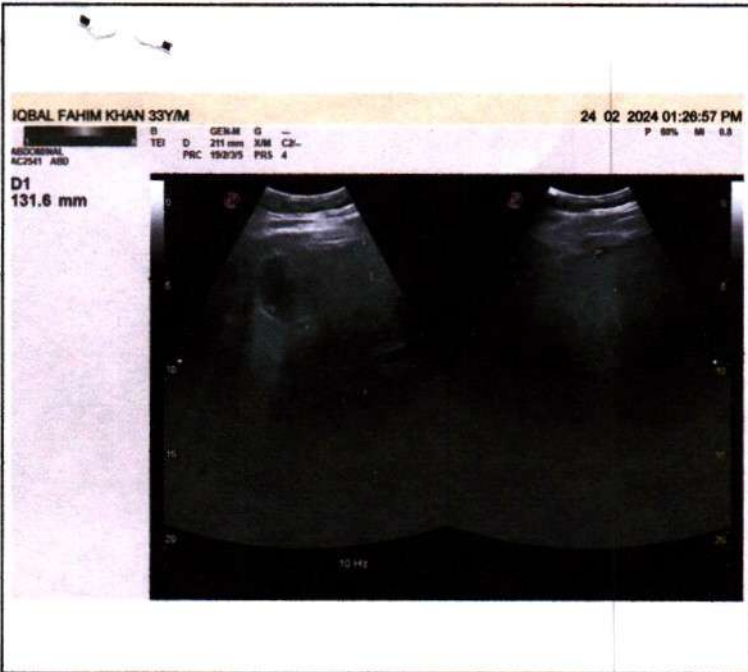Please correlate clinically and further investigations.


Sonologist
Dr. Rahul Kumar Tiwari
MBBS, MD (Radio Diagonosis)
Reg. No. 57557

- Note: (1) This report is not valid for medico-legal purposes.
(2) In case of any discrepancy due typing error, please get it Rectified immediately.

Disclaimer: This report is not valid for Madicolegal or Judicial Purpose. Radiological diagnosis is solely interpretation of images produced by tissue & may not be always conclusive.

Address : B36/44 B4 Kabir Nagar (Near Sanjay Shiksha Niketan), Durgakund, Varanasi
Mobile : 9554572190 / 9453837595 / Recpn, 9389994334
Email : dramishra@gmail.com, drpallaviojha@gmail.com, Website : www.piire.org





PANACEA HOSPITAL



A shelter for many hearts A Home for many lives

(An ISO 9001:2008 Certified Organisation)
Lab Attached with CMC Under EQAS Scheme

Dept. of Radiodiagnosis - 32 Slice CT Scan, 3D/4D USG, 2D ECHO, Colour Doppler, Intervention Procedures, Digital X-Ray

NAME: IQBAL FAHIM KHAN
REF.DR. ASHUTOSH MISHRA (MD)

AGE/SEX: 33YRS/MALE
DATE: 24/02/2024

Echo - Cardiography

MITRAL VALVE Doppler	AML - normal morphology MV Flow - E - 0.6 A-0.4 E/A=1.40	PML - normal morphology MVA - 3.0 cm ² Mitral Regurgitation - No
TRICUSPID VALVE Doppler	Normal TV Flow -No	Tricuspid Regurgitation -No
PULMONARY VALVE Doppler	Normal PV Flow -No	Pulmonary Regurgitation - No
AORTIC VALVE Doppler	Trileaflet-No AV Flow - no	Aortic Regurgitation - no
MEASUREMENT	Aorta - 28.6 (20-38) mm IVS ed - 8.6 (6 -12) mm LVID ed -49.7 (35 - 55) mm LVPW ed - 13.7 (6 -12) mm OA - 7 (> 5) mm	LA - 34.3 (24-32) mm IVS es -16.6 (6 - 12) mm LVID es - 35.7 (24 - 40) mm LVPW es -16.6 (6 -12) mm EPSS - 4 (< 9) mm

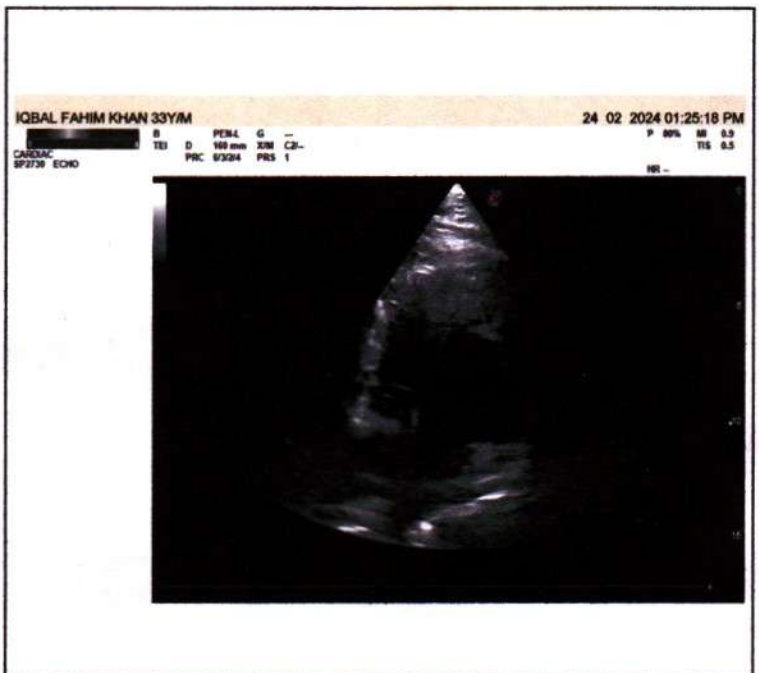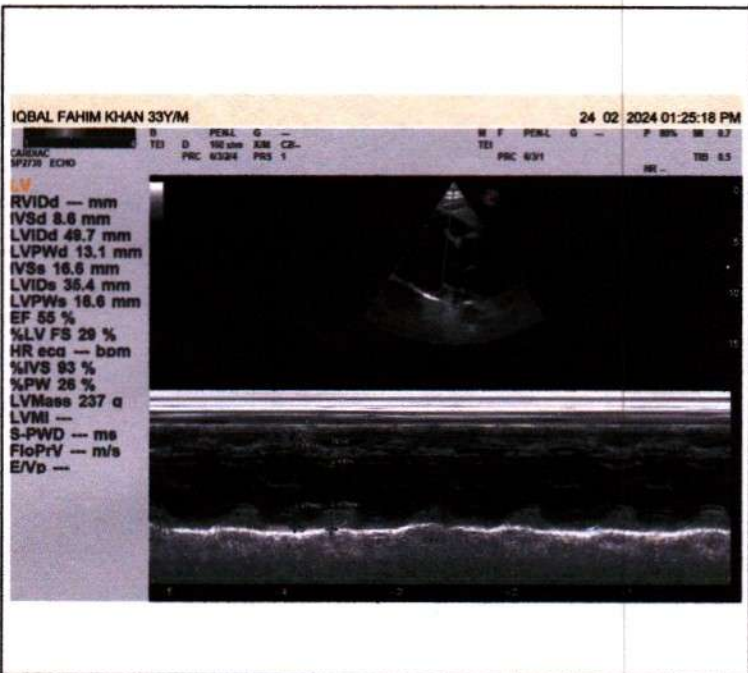
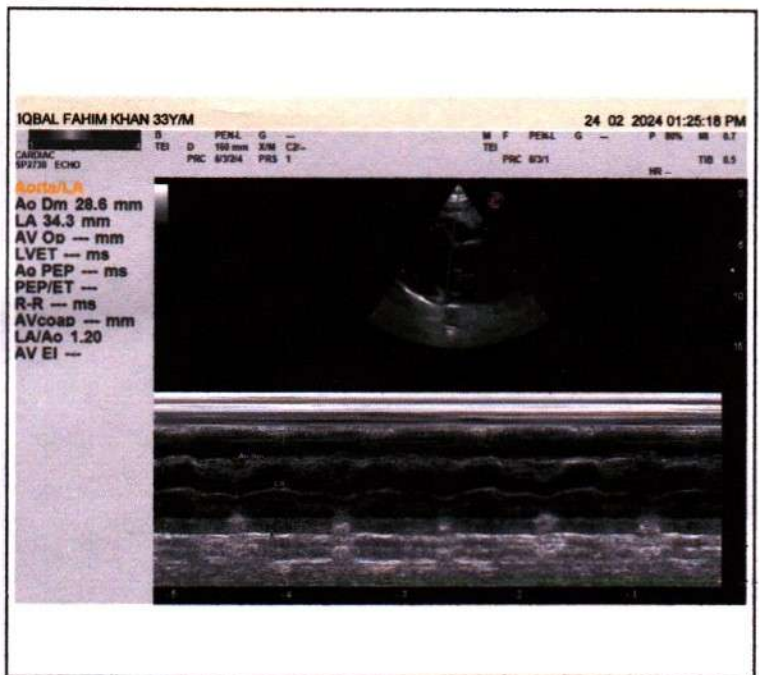
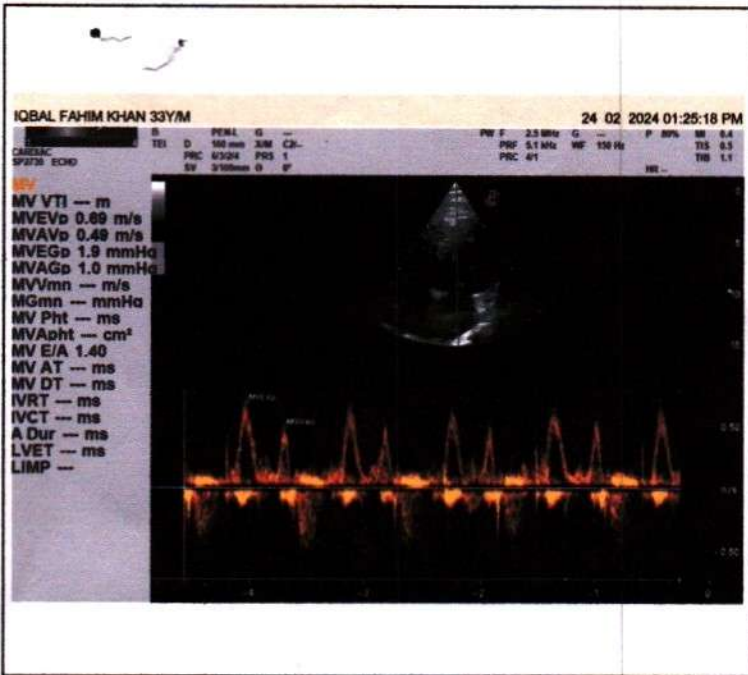
CONCLUSION

All cardiac chamber dimensions are WNL
No valvular abnormalities
Good LV systolic function present Modified Simpson's method (4C, 2C) (LVEF=55%)
No diastolic dysfunction present (E/A = 1.40)
No RWMA
No pericardial effusion
Intact IAS / IV
No PAH
No intra cardiac mass /thrombus /vegetation

IMPRESSION **Normal Echocardiogram**


Niraj Mishra
Physician Assistant
(PIRE)


DR. Pallavi Mishra
MBBS, MD(GENERAL MEDICINE)
MCI Reg. No.52033
Echocardiography Specialist, MIAE
Non-Invasive Cardiologist
Women Cardiologist
Diabetocardiologist





Call Now - 1800-123-3070

PANACEA HOSPITAL



A shelter for many hearts A Home for many lives

(An ISO 9001:2008 Certified Organisation)
Lab Attached with CMC Under EQAS Scheme

Dept. of Radiodiagnosis - 32 Slice CT Scan, 3D/4D USG, 2D ECHO, Colour Doppler, Intervention Procedures, Digital X-Ray

PATIENT'S NAME	: IQBAL FAHIM KHAN	AGE/SEX: 33Y/M
REF. BY	: Dr. ASHUTOSH MISHRA(MD)	DATE:24/02/2024

X-RAY CHEST (PA VIEW)

- Bilateral lung fields appear normal.
- Trachea and mediastinum appear normal in position.
- Both hila appear normal in size and are symmetrical.
- Transverse cardiac diameter is within normal limits.
- Great vessels appear normal
- Both CP angles appear clear. Normal position and contour diaphragms noted.
- Bony rib cage and soft tissue shadows appear normal.

IMPRESSION

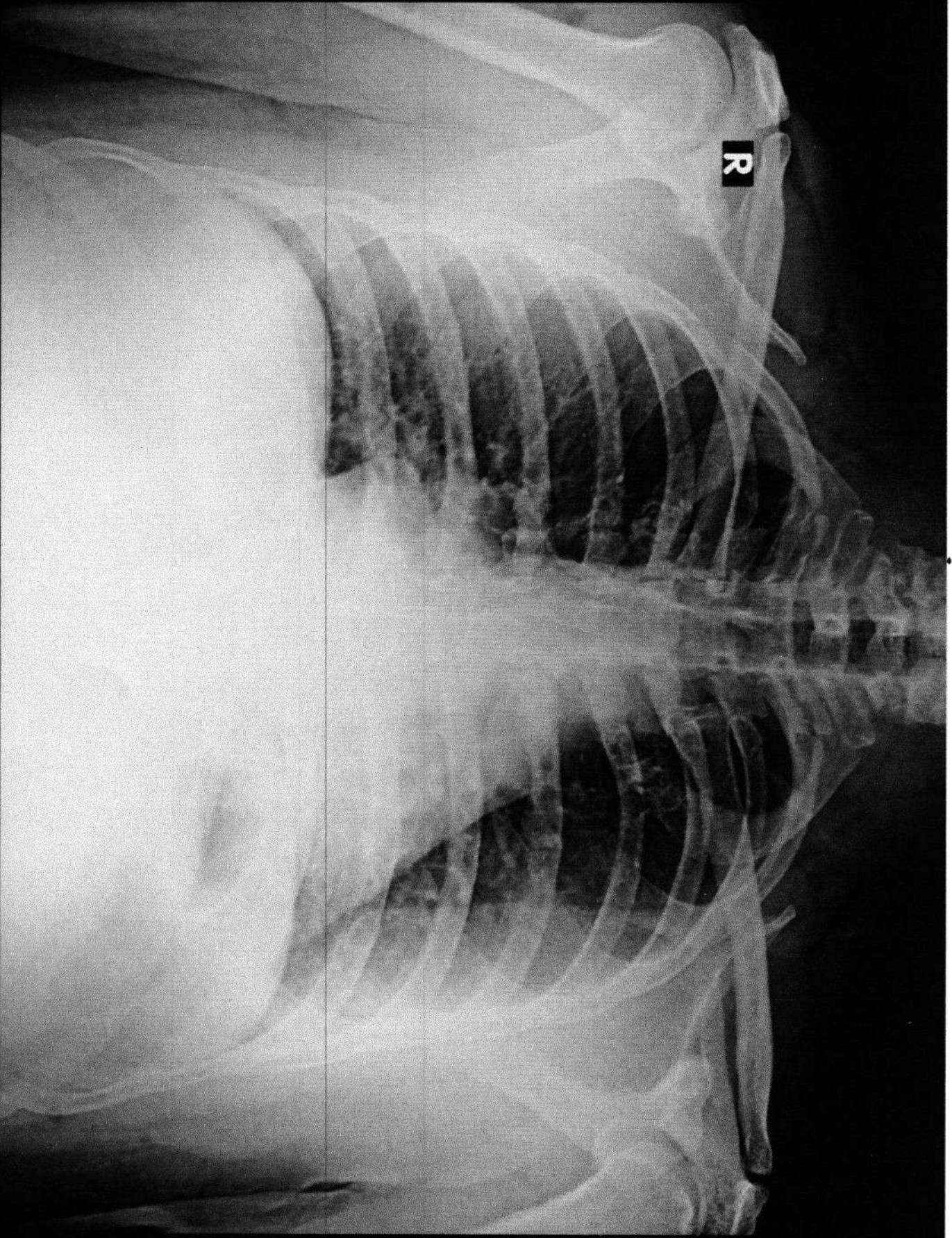
- **No obvious abnormality noted in the chest radiograph.**

Thanks for reference.


Radiologist
Dr. Rahu Kumar Tiwar
MBBS, MD (Radio Diagonosis)
Reg. No. 57557

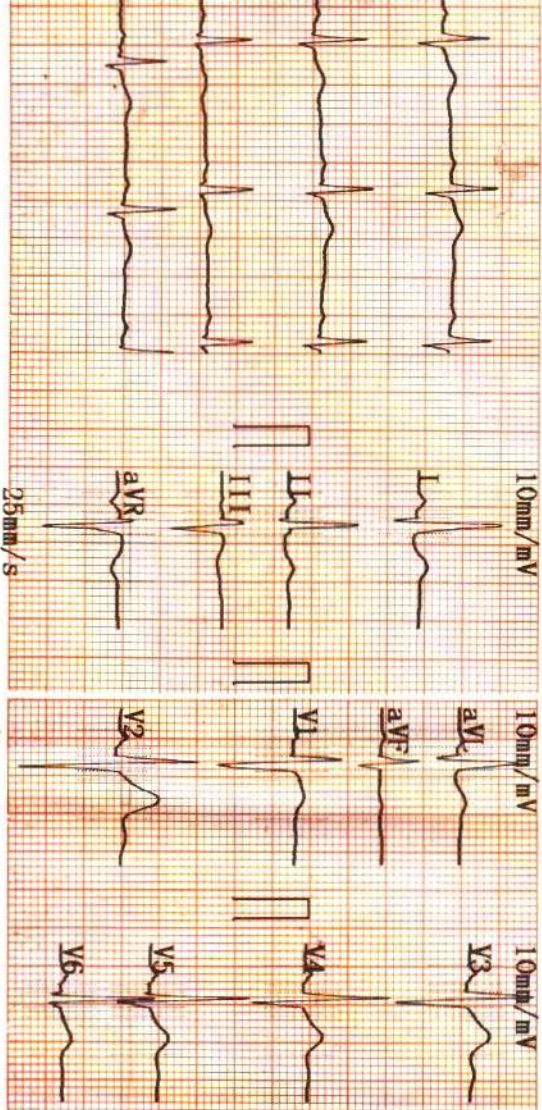
Disclaimer: This report is not valid for Madicolegal or Judicial Purpose. Radiological diagnosis is solely interpretation of images produced by tissue & may not be always conclusive.

Address : B36/44 B4 Kabir Nagar (Near Sanjay Shiksha Niketan), Durgakund, Varanasi
Mobile : 9554572190 / 9453837595 / Recpn, 9389994334
Email : dramishra@gmail.com, drpallaviojha@gmail.com, Website : www.piire.org



IQBAL FAHIM KHAN 33Y/M 6398 M CHEST P.A. 24-Feb-24 01:02 PM

PANACEA HOSPITAL, KABIR NAGAR, DURGAKUND, VARANASI



10mm/mV
25mm/s

10mm/mV

10mm/mV

2024-02-24 15:50

ID :
 Name : Tebal Hakim Icham
 Sex : M
 Height : 165
 SYS :
 DIA :
 HR : 78 bpm
 PR Interval : 147 ms
 P Duration : 103 ms
 QRS Duration : 82 ms
 T Duration : 207 ms
 QT/QTc : 339/386 ms
 P/QRS/T Axis : 19.3/9.3/-14.6 deg
 R(V5)/S(V1) : 1.30/1.00 mV
 R(V5) S(V1) : 2.31 mV

<< Conclusions >>

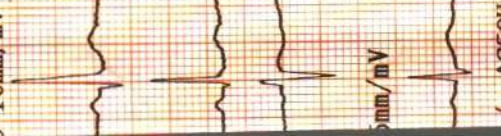
Normal Sinus Rhythm;
 Longitudinal Left axis deviation,
 old high lateral MI;
 II aVL aVF Abnormal T wave;

Report need physician confirm

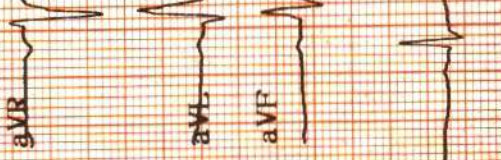DR. Pallavi Misra
 MBBS, MD(GENERAL MEDICINE)
 MCI Reg. No.52033
 Physician

AUT
 I
 II
 III
 V5
 25mm

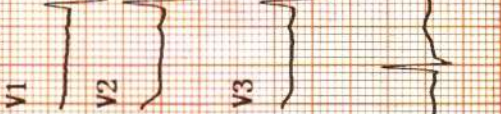
10mm/mV



10mm/mV



5mm/mV



5mm/mV

