



Mr. VINAYPRAKASH SHRIVASTAV (53 /M)

UHID : AHIL.0000508006

AHC No : AHILAH195061

Date : 25/02/2023

MEDIWHEEL-FULL BODY CHK-ABOVE40-MALE



Namaste Mr. VINAYPRAKASH SHRIVASTAV,

Thank you for choosing Apollo ProHealth, India's first AI-powered health management program, curated to help you make positive health shifts. Being healthy is about making smart choices, and you have taken the first step with this program. We are privileged to be your healthcare partner. Your health is our priority.

We are with you on your path to wellness by:

Predicting your risk: Artificial Intelligence-powered predictive risk scores are generated, based on your personal, medical, and family history and detailed multi-organ evaluation of your body through diagnostic and imaging tests.

Preventing onset or progress of chronic lifestyle diseases: Your Health Mentor is available to help you understand your physician's recommendations and helping you handle any concerns (complimentary service up to one year)

Overcoming barriers to your wellbeing: Your Health Mentor will help you set your health goals and guide you with tips to stay on track. We will also, digitally remind you to proactively prioritize your health.

Through this report, you will be able to understand your overall health status, your health goals and the recommendations for your path to wellness. Your Health Report will include the following:

- Your medical history and physical examination reports
- Results from your diagnostic and imaging tests
- AI powered health risk scores
- Your physician's impression and recommendations regarding your overall health
- Your personalized path to wellness, including your follow-up assessments and vaccinations

For Enquiry/Appointments Contact +91 76988 15003 / +91 79 66701880

Apollo Hospitals International Limited
Plot No.-1A, Bhat, GIDC, Gandhinagar, Gujarat - 382428, India.
Phone : +91 79 66701800 | Fax No. : +91 79 66701843
E-mail : info@apolloahd.com | www.ahmedabad.apollohospitals.com

Apollo Hospitals - City Centre (NON NABH-JCI)
1, Tulsibaug Society, Nr. Parnai Garden, Ahmedabad.
Phone : +91 79 66305800 / 01 or +91 76988 15148
E-mail : info@apolloahd.com

Regd. Office
19, Bishop Gardens, R.A. Puram, Chennai - 600 028
CIN No. : U85110TN1997PL0039016 | GSTin : 24AAFLA4150H225
For online appointment : www.askapollo.com



For online appointment : www.askapollo.com
Keep the records carefully and bring them along during your next visit to our Hospital

We have reviewed the results of the tests and have identified some areas for you to act on. We believe that with focus and targeted interventions, you can be healthier and happier.



Scan the QR code to download the Apollo 247 App

Organization is Accredited
by Joint Commission



You can visit your proHealth physician in person at this center, or you can book a virtual consultation for review via www.apollo247.com or through the Apollo 24*7 mobile app. You can avail 30% discount on additional tests and follow-up tests at Apollo Hospitals within one week. You may call your Health Mentor on 04048492633 or email at prohealthcare@apollohospitals.com

Stay Healthy and happy! 😊
Apollo ProHealth Care team

Disclaimer: The services offered in the program may vary depending on any prior mutual agreements between guests and the facility/unit.

For Enquiry/Appointments Contact +91 76988 15003 / +91 79 66701880

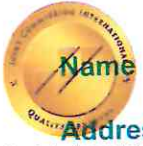Apollo Hospitals International Limited
Plot No.-1A, Bhat, GIDC, Gandhinagar, Gujarat - 382428, India.
Phone : +91 79 66701800 | Fax No. : +91 79 66701843
E-mail : info@apolloahd.com | www.ahmedabad.apollohospitals.com

Apollo Hospitals - City Centre (NON NQ24-IC)
1, Tulshibaug Society, Nr. Padmaj Garden, Ahmedabad.
Phone : +91 79 66305800 / 01 or +91 76988 15148
E-mail : infoahcc@apolloahd.com

Regd. Office
19, Bishop Gardens, R.A. Puram, Chennai - 600 028
CIN No. : U95110TN1997PLC039016 | GSTin : 24AAAH044150H225
For online appointment : www.askapollo.com



For online appointment : www.askapollo.com
Keep the records carefully and bring them along during your next visit to our Hospital



Organization is Accredited
by Joint Commission International



Date : 25/02/2023

Name : Mr. VINAYPRAKASH SHRIVASTAV (53 /M)
Address : BOB, AHMEDABAD, AHMEDABAD, GUJARAT, INDIA

UHID : AHIL.000508006

Examined by : Dr. SHASHIKANT NIGAM

AHC No : AHILAH195061

MEDIWHEEL-FULL BODY CHK-ABOVE40-MALE



Chief Complaints

For Annual health checkup
No specific complaints

Present Known illness

Hypertension Since - 2014; Medication - regular; - TAH 40
Dyslipidaemia Since - 2014; Medication - regular; - ROSUMAX



Drug Allergy

Analgesics Drug Allergy :18/03/2019



Systemic Review

Cardiovascular system : - Nil Significant
Respiratory system : - Nil Significant
Oral and dental : - Nil Significant
Gastrointestinal system : - Nil Significant
Genitourinary system : - Nil Significant
Gynaec history : - Nil Significant
Central nervous system : - Nil Significant
Eyes : - Nil Significant
ENT : - Nil Significant
Musculoskeletal system :
Spine and joints
- Nil Significant
Skin : - Nil Significant
General symptoms : - Nil Significant



Past medical history

Do you have any - No
allergies?
Allergies - Nil



Name : Mr. VINAYPRAKASH SHRIVASTAV

UHID : AHIL.0000508006

Date 25/02/2023

MEDIWHEEL-FULL BODY CHK-ABOVE40-MALE

AHC No: AHILAH195061



Organization is Accredited by Joint Commission International

Past medical history - nil significant

Covid 19 - No

Post detection (3 Weeks) - No

Hospitalization for Covid 19 - No



Surgical history

Surgical history - Nil



Personal history

Ethnicity - Indian Asian

Marital status - Married

No. of children - 2

Male - 2

Diet - Mixed Diet

Alcohol - consumes alcohol occasionally

Smoking - Yes

Type - Cigarette

Frequency - occasional

Chews tobacco - No

Physical activity - Active



Family history

Father - alive

Mother - alive

Brothers - 3

Sisters - 1

Diabetes - mother

Hypertension - mother

Coronary artery disease - none

Cancer - None

Physical Examination



General

General appearance - normal



Name : Mr. VINAYPRAKASH SHRIVASTAV

UHID : AHIL.0000508006

Date : 25/02/2023

AHC No : AHILAH195061



MEDIWHEEL-FULL BODY CHK-ABOVE40-MALE

Organization is Accredited by Joint Commission International

Build	- normal
Height	- 171
Weight	- 82.8
BMI	- 28.32
Pallor	- No
Oedema	- no



Cardiovascular system

Heart rate (Per minute)	- 65
Rhythm	- Regular
Systolic(mm of Hg)	- 140
Diastolic(mm of Hg)	- 80
	- B.P. Sitting
Heart sounds	- S1S2+

Respiratory system

Breath sounds	- Normal vesicular breath sounds
---------------	----------------------------------



Abdomen

Organomegaly	- No
Tenderness	- No

Printed By : MUKTA S ADALTI

For Enquiry/Appointments Contact +91 76988 15003 / +91 79 66701880

Apollo Hospitals International Limited
 Plot No.-1A, Bhat, GIDC, Gandhinagar, Gujarat - 382428, India.
 Phone : +91 79 66701800 | Fax No. : +91 79 66701843
 E-mail : info@apollosai.com | www.ahmedabad.apollohospitals.com

Apollo Hospitals - City Centre (NON NABH-JCI)
 1, TulsiBaag Society, Nr, Palmal Garden, Ahmedabad.
 Phone : +91 79 66305800 / 01 or +91 76988 15148
 E-mail : infoahcc@apollosai.com

Regd. Office
 19, Bishop Gardens, R.A. Puram, Chennai - 600 028
 CIN No. : U85110TN1997PLC039016 | GSTin : 24AARCA44150H225
 For online appointment : www.askapollo.com



For online appointment : www.askapollo.com
Keep the records carefully and bring them along during your next visit to our Hospital

Saving time. Saving lives.



Name : Mr. VINAYPRAKASH SHRIVASTAV
 MEDIWHEEL-FULL BODY CHK-ABOVE40-MALE

UHID : AHIL.0000508006

Date 25/02/2023
 AHC No: AHILAH195061
 Apollo HOSPITALS

Organization is Accredited
 by Joint Commission International

URINE FOR ROUTINE EXAMINATION

Urinalysis, is the physical, chemical and microscopic examination of the urine and is one of the most common methods of medical diagnosis. It is used to detect markers of diabetes, kidney disease, infection etc.

Test Name	Result	Unit	Level	Range
Volume	20	mL		
Specific Gravity	1.010			
Colour:	Pale-Yellow			
Transparency:	Clear			
pH	5.5			
Protein :	Nil			
Sugar:	Nil			
Blood:	Negative			
Ketone	Nil			
Bile Pigments:	Negative			
Urobilinogen	Nil	E.U./dL		
Nitrite	Negative			
Pus Cells	Occassional			0-5
RBC	Nil	/hpf		0-5/hpf
Epithelial Cells	Occassional			
Casts:	Absent			
Crystals:	Absent			

COMPLETE BLOOD COUNT WITH ESR

Test Name	Result	Unit	Level	Range
Hemoglobin (Photometric Measurement)	13.4	gm%	●	13.0-17.0
Packed cell volume(Calculated)	40.3	%	●	40-50
RBC COUNT (Impedance)	4.41 *	Million/ul	●	4.5-5.9
MCV (From RBC Histogram)	91.5	fl	●	80-100
MCH(Calculated)	30.38	pg	●	27-32
MCHC(Calculated)	33.2	%	●	31-36
RDW(Calculated)	13.2	%	●	11.5-14.5
WBC Count (Impedance)	6982	/cu mm	●	4000-11000

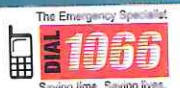● Within Normal Range ● Borderline High/Low ● Out of Range

For Enquiry/Appointments Contact +91 76988 15003 / +91 79 66701880

Apollo Hospitals International Limited
 Plot No.-1A, Bhal, GIDC, Gandhinagar, Gujarat - 392425, India.
 Phone : +91 79 66701800 | Fax No. : +91 79 66701843
 E-mail : info@apolloahd.com | www.ahmedabad.apollohospitals.com

Apollo Hospitals - City Centre (NON NASH-JCI)
 1, TulsiBang Society, Nr. Parimal Garden, Ahmedabad.
 Phone : +91 79 66305800 / 01 or +91 76988 15148
 E-mail : infoahcc@apolloahd.com

Regd. Office
 19, Bishop Gardens, R.A. Putam, Chennai - 600 028
 CIN No. : U85110TN1997PLCC039016 | GSTIN : 24AA8CA44150H225
 For online appointment : www.askapollo.com



For online appointment : www.askapollo.com
 Keep the records carefully and bring them along during your next visit to our Hospital



Name : Mr. VINAYPRAKASH SHRIVASTAV

UHID : AHIL.0000508006

Date 25/02/2023

AHC No : AHILAH195061

MEDIWHEEL-FULL BODY CHK-ABOVE40-MALE



Organization is Accredited by Joint Commission International

Neutrophils	58	%	●	40-75
Lymphocytes	30	%	●	20-40
Monocytes	8	%	●	2-10
Eosinophils	4	%	●	01-06
Basophils	0	%	●	0-1
Platelet Count (Impedance)	130000 *	/cu mm	●	150000-450000
MPV (Calculated)	12.2 *	fl	●	7-11
Platelets:	Thrombocytopenia noted			
ERYTHROCYTE SEDIMENTATION RATE (ESR) (Automated/ optic-electronic)	11	mm/1st hr	●	0-15

URINE GLUCOSE(FASTING)

Test Name	Result	Unit	Level	Range
Urine Glucose (Post Prandial)	Nil			

URINE GLUCOSE(POST PRANDIAL)

Test Name	Result	Unit	Level	Range
Urine Glucose (Post Prandial)	Nil			

BLOOD GROUPING AND TYPING (ABO and Rh)

Test Name	Result	Unit	Level	Range
BLOOD GROUP:	B Positive			

LFT (LIVER FUNCTION TEST)

Liver function tests(LFT), are groups of clinical biochemistry blood assays that give information about the state of a patient's liver. These tests can be used to detect the presence of liver disease, distinguish among different types of liver disorders, gauge the extent of known liver damage, and follow the response to treatment.

Test Name	Result	Unit	Level	Range
ALT(SGPT) - SERUM / PLASMA	39	U/L	●	0-50
ALKALINE PHOSPHATASE - SERUM/PLASMA	87	U/L	●	Adult(Male): 40 - 129
AST (SGOT) - SERUM	29	U/L	●	> 1 year Male : <40
Total Bilirubin	0.528	mg/dL	●	0.300-1.200

● Within Normal Range ● Borderline High/Low ● Out of Range



Name : Mr. VINAYPRAKASH SHRIVASTAV

UHID : AHIL.000508006

Date : 25/02/2023

MEDIWHEEL-FULL BODY CHK-ABOVE40-MALE

AHC No : AHILAH195061



Organization is Accredited by Joint Commission International

Direct Bilirubin

0.223

mg/dL



Upto 0.3 mg/dl

Indirect Bilirubin

0.305

mg/dL



1 Day ≤5.1 mg/dL
2 Days ≤7.2 mg/dL
3-5 Days ≤10.3 mg/dL
6-7 Days ≤8.4 mg/dL
8-9 Days ≤6.5 mg/dL
10-11 Days ≤4.6 mg/dL
12-13 Days ≤2.7 mg/dL
14 Days - 9 Years 0.2-0.8 mg/dL
10-19 Years 0.2-1.1 mg/dL
≥20 Years 0.2-1.2 mg/dL

CREATININE - SERUM / PLASMA

Test Name	Result	Unit	Level	Range
CREATININE - SERUM / PLASMA	0.89	mg/dL		Adult Male: 0.6 - 1.3

LFT (LIVER FUNCTION TEST)

Liver function tests(LFT), are groups of clinical biochemistry blood assays that give information about the state of a patient's liver. These tests can be used to detect the presence of liver disease, distinguish among different types of liver disorders, gauge the extent of known liver damage, and follow the response to treatment.

Test Name	Result	Unit	Level	Range
GGTP: GAMMA GLUTAMYL TRANSPEPTIDASE - SERUM	18	U/L		Male : 10 - 71 Female : 6 - 42

GLUCOSE - SERUM / PLASMA (FASTING)

Test Name	Result	Unit	Level	Range
Glucose - Plasma (Fasting)	126 *	mg/dL		70 - 100 : Normal 100 - 125 : Impaired Glucose Toleranc ≥ 126 : Diabetes Mellitus

GLUCOSE - SERUM / PLASMA (POST PRANDIAL) - PPBS

Test Name	Result	Unit	Level	Range
Glucose - Plasma (Post Prandial)	141 *	mg/dL		70-140

GLYCOSYLATED HEMOGLOBIN (HBA1C) - WHOLE BLOOD

Test Name	Result	Unit	Level	Range
-----------	--------	------	-------	-------



Within Normal Range



Borderline High/Low



Out of Range



Name : Mr. VINAYPRAKASH SHRIVASTAV

UHID : AHIL.0000508006

Date : 25/02/2023

MEDIWHEEL-FULL BODY CHK-ABOVE40-MALE

AHC No : AHILAH195061



Organization is Accredited by Joint Commission International

Glycosylated Hemoglobin (HbA1c)

6.0 *

%



Normal < 5.7

%Increased risk for Diabetes 5.7 - 6.4%

Diabetes >= 6.5%

Monitoring criteria for Diabetes Mellitus
<7.0 : Well Controlled Diabetes
7.1 – 8.0 : Unsatisfactory Control
> 8.0 : Poor Control & Needs Immediate Treatment

Estimated Average Glucose.

125.50

LFT (LIVER FUNCTION TEST)

Liver function tests(LFT), are groups of clinical biochemistry blood assays that give information about the state of a patient's liver. These tests can be used to detect the presence of liver disease, distinguish among different types of liver disorders, gauge the extent of known liver damage, and follow the response to treatment.

Test Name	Result	Unit	Level	Range
PROTEIN TOTAL - SERUM / PLASMA	7.55	g/dL	●	6.00-8.00
PROTEIN TOTAL - SERUM / PLASMA	7.55	g/dL	●	6.00-8.00
ALBUMIN - SERUM	4.75	g/dL	●	Adult(18 - 60 Yr): 3.5 - 5.2
ALBUMIN - SERUM	4.75	g/dL	●	Adult(18 - 60 Yr): 3.5 - 5.2
Globulin-Serum/Plasma	2.8		●	2.20-4.20
Globulin-Serum/Plasma	2.8		●	2.20-4.20
A/G ratio	1.7		●	1.00-2.00
A/G ratio	1.7		●	1.00-2.00

THYROID PROFILE (T3,T4 AND TSH)

Test Name	Result	Unit	Level	Range
TOTAL T3: TRI IODOTHYRONINE - SERUM	2.1	nmol/L	●	Adults(20-120 Yrs): 1.2 - 3.1 Pregnant Female : First Trimester : 1.61 - 3.53 Second Trimester : 1.98 - 4.02 Third Trimester : 2.07 - 4.02
TOTAL T4: THYROXINE - SERUM	94	nmol/L	●	Adults(20-100 Yrs):66 - 181 Pregnant Female : First Trimester : 94.3 - 190 Second Trimester : 102 - 207 Third Trimester : 89 - 202
TSH: THYROID STIMULATING HORMONE - SERUM	4.96 *	μIU/mL	●	14-120 years : 0.27 - 4.20



Within Normal Range



Borderline High/Low



Out of Range



Organization is Accredited
 by Joint Commission International

URIC ACID - SERUM

Uric acid is a product of the metabolic breakdown of purine. High blood concentrations of uric acid can lead to gout. It is also associated with other medical conditions including diabetes and the formation of kidney stones.

Test Name	Result	Unit	Level	Range
URIC ACID - SERUM	5.6	mg/dL	●	Male : 3.4-7.0 Female : 2.4-5.7

PROSTATIC SPECIFIC ANTIGEN (PSA TOTAL) - SERUM

PSA is present in small quantities in the serum of men with healthy prostates, but is often elevated in the presence of prostate cancer or some prostate disorders. PSA is not a unique indicator of prostate cancer, it may also detect prostatitis or benign prostatic hyperplasia. Only about 30 percent of patients with high PSA have prostate cancer diagnosed after biopsy. It is recommended in men above 50 years of age.

Test Name	Result	Unit	Level	Range
PROSTATIC SPECIFIC ANTIGEN (PSA TOTAL) - SERUM	1.000	ng/mL	●	0.000-4.000

BUN (BLOOD UREA NITROGEN)

Test Name	Result	Unit	Level	Range
BUN (BLOOD UREA NITROGEN)	7	mg/dL	●	6-20
UREA - SERUM / PLASMA	15	mg/dL	●	15 - 50

LIPID PROFILE - SERUM

Test Name	Result	Unit	Level	Range
Total Cholesterol	152	mg/dl	●	0 - 200 : Desirable 200 - 240 : Borderline High 240 - 280 : High > 280 : Very High
Triglycerides - Serum	121	mg/dL	●	0-150
HDL CHOLESTEROL - SERUM / PLASMA (Direct Enzymatic Colorimetric)	43 *	mg/dL	●	< 40 : Major risk factor for heart disease 40 - 59 : The higher The better. >=60 : Considered protective against heart disease
LDL Cholesterol (Direct LDL)	92	mg/dL	●	100 : Optimal 100-129 : Near Optimal 130-159 : Borderline High 160-189 : High >=190 : Very High

● Within Normal Range ● Borderline High/Low ● Out of Range



Name : Mr. VINAYPRAKASH SHRIVASTAV

UHID : AHIL.0000508006

Date : 25/02/2023

MEDIWHEEL-FULL BODY CHK-ABOVE40-MALE

AHC No : AHILAH195061



Organization is Accredited by Joint Commission International

LDL CHOLESTEROL	24	●	< 40 mg/dl
C/H RATIO	4	●	0-4.5

X-RAY CHEST PA

X-ray imaging creates pictures of the inside of your body. Chest X-ray can reveal abnormalities in the lungs, the heart, and bones that sometimes cannot be detected by examination.

Few fibrotic and calcified opacities seen in left mid zone.
Prominent bronchovascular markings seen in right lower zone.

Lung fields are otherwise clear.

Cardio thoracic ratio is normal.

Both costophrenic angles are clear.

Domes of diaphragm are well delineated.

Bony thorax shows no significant abnormality.

ECHO/TMT

Investigations Not Done / Not Yet Reported

Haematology

STOOL ROUTINE

CARDIOLOGY

ECG

● Within Normal Range ● Borderline High/Low ● Out of Range



The Emergency Specialist
Saving time. Saving lives.



Name : Mr. VINAYPRAKASH SHRIVASTAV
 MEDIWHEEL-FULL BODY CHK-ABOVE40-MALE

UHID : AHIL.0000508006

Date : 25/02/2023

AHC No : AHILAH195061



Organization is Accredited
 by Joint Commission International

Executive Summary



- .BODY WEIGHT 82.8 KG, IDEAL BODY WEIGHT 54-67- KG
- .THROMBOCYTOPENIA
- .IMPAIRED GLUCOSE TOLERANCE
- .SUBCLINICAL HYPOTHYROIDISM
- .ECG - SINUS BRADYCARDIA *LBBB*
- . ECHO - - NORMAL LV SYSTOLIC FUNCTION, LVEF 55%
 - NORMAL LV COMPLIANCE
 - NO PAH , MIDLY SCLERODEGENERATIVE CHANGES OF AORTIC VALVE
- .USG ABDOMEN - GRADE I FATTY LIVER
- .CHEST X-RAY - FEW FIBROTIC AND CALCIFIED OPACITIES SEEN IN LEFT MID ZONE, PROMINENT BRONCHOVASCULAR MARKINGS SEEN IN RIGHT LOWER ZONE
- .VISION - NORMAL
- .DENTAL - AS PER DOCTOR ADVICE

Wellness Prescription

Advice On Diet :-



- BALANCED DIET
- LOW FAT DIET
- LOW CARBOHYDRATE DIET

Advice On Physical Activity :-



- REGULAR 30 MINUTES WALK FOR HEALTH AND 60 MINUTES FOR WEIGHT REDUCTION
- PRACTICE YOGA AND MEDITATION
- MAINTAIN WEIGHT BETWEEN 54-67 KG

Follow-up and Review Plan



- PERIODIC BP MONITORING
- CHECK ANTI TPO ANTIBODIES

Conveyed

Printed By : MUKTA S ADALTI



Scan the QR code in AskApollo App to book your follow-up appointments and investigations

Dr. Shashikant Nigam
Dr. SHASHIKANT NIGAM
 M.D.B.S. (Gen. Med.)
 AHC Physician/ Consultant Internal Medicine
 Apollo Hospitals International Ltd., Gandhinagar, Gujarat-382428, INDIA. Tel: +91 79 66701880



Name : Mr. VINAYPRAKASH SHRIVASTAV
MEDIWHEEL-FULL BODY CHK-ABOVE40-MALE

UHID : AHIL.0000508006

Date : 25/02/2023

AHC No : AHILAH195061



Organization is Accredited
by Joint Commission International

Note :- The Health Check-up examinations and routine investigations have certain limitations and may not be able to detect all the diseases. Any new or persisting symptoms should be brought to the attention of the Consulting Physician. Additional tests, consultations and follow up may be required in some cases.

Page 13 of 13

For Enquiry/Appointments Contact +91 76988 15003 / +91 79 66701880

Apollo Hospitals International Limited
Plot No.-1A, Bhat, GIDC, Gandhinagar, Gujarat - 382429, India.
Phone : +91 79 66701800 | Fax No. : +91 79 66701843
E-mail : info@apolloahd.com | www.ahmedabad.apollohospitals.com

Apollo Hospitals - City Centre (NON MEDICAL)
1, Tulsiang Society, Nr. Parimal Garden, Ahmedabad,
Phone : +91 79 66305800 / 01 or +91 76988 15148
E-mail : infoahcc@apolloahd.com

Regd. Office
19, Bishop Gardens, R.A. Puram, Chennai - 600 028
CIN No. : U85110TN1997PL0039016 | GSTIN : 24AACCA4150H225
For online appointment : www.askapollo.com




For online appointment : www.askapollo.com
Keep the records carefully and bring them along during your next visit to our Hospital

Saving time. Saving lives.



Organization is Accredited
by Joint Commission International

CARDIOLOGY

Patient Details : Mr. VINAYPRAKASH SHRIVASTAV | Male | 53Yr 1Mth 16Days
UHID : AHIL.0000508006 **Patient Location:** AHC
Patient Identifier: AHILAH195061 
DRN : 5623018279 **Completed on :** 25-FEB-2023 16:59
Ref Doctor : DR. SHASHIKANT NIGAM

ECHO/TMT

FINDINGS :

Normal cardiac chamber dimensions.
 Normal LV systolic function, LVEF: 55%
 No Regional wall motion abnormalities at rest.
 Normal LV compliance.
 Mildly Sclerodegenerative changes of Aortic valve.
 Other cardiac valves are structurally normal.
 IAS/ IVS intact.
 No MR, Trivial AR, No PR, No TR.
 No PAH.
 No clots/ vegetation/ effusion.

MEASUREMENTS (mm) ::

Printed on : 27-Feb-2023 10:50 Printed By : 153182 Reported By : 1010611 Page 1 of 2

For Enquiry/Appointments Contact +91 76988 15003 / +91 79 66701880



Organization is Accredited
by Joint Commission International



Mr. VINAYPRAKASH SHRIVASTAV

AHIL.0000508006

AHILAH195061

ECHO/TMT

	LVID diastole
Measurements (mm)	

IMPRESSION

--- END OF THE REPORT ---

DR SUBIR GHOSH MD.DM

Interventional Cardiologist

Printed on : 27-Feb-2023 10:50

Printed By : 153182

Reported By : 1010611

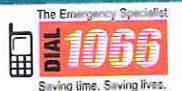Page 2 of 2

For Enquiry/Appointments Contact +91 76988 15003 / +91 79 66701880

Apollo Hospitals International Limited
Plot No.-1A, Bhat, GIIC, Gandhinagar, Gujarat - 382428, India.
Phone : +91 79 66701800 | Fax No. : +91 79 66701843
E-mail : info@apolloahd.com | www.ahmedabad.apollohospitals.com

Apollo Hospitals - City Centre (WOMEN'S) (G)
1, TulsiBaag Society, Nr. Parnal Garden, Ahmedabad.
Phone : +91 79 66505800 / 01 or +91 79688 15148
E-mail : info@ccc@apolloahd.com

Regd. Office
19, Bishop Gardens, R.A. Puram, Chennai - 600 028
CIN No. : U85110TN1997PLC039016 | GSTin : 24AABCA44150H225
For online appointment : www.askapollo.com




For online appointment : www.askapollo.com
Keep the records carefully and bring them along during your next visit to our Hospital



Organization is Accredited
by Joint Commission International



RADIOLOGY

Patient Details : Mr. VINAYPRAKASH SHRIVASTAV | Male | 53Yr 1Mth 16Days
UHID : AHIL.0000508006 **Patient Location:** AHC
Patient Identifier: AHILAH195061 
DRN : 123025260 **Completed on :** 25-FEB-2023 09:47
Ref Doctor : DR. SHASHIKANT NIGAM

X-RAY CHEST PA

IMPRESSION

Few fibrotic and calcified opacities seen in left mid zone.
Prominent bronchovascular markings seen in right lower zone.

Lung fields are otherwise clear.

Cardio thoracic ratio is normal.

Both costophrenic angles are clear.

Domes of diaphragm are well delineated.

Bony thorax shows no significant abnormality.

--- END OF THE REPORT ---

RAJVEERSINH P CHAVDA

Medical Officer

Printed on : 27-Feb-2023 10:50

Printed By : 153182

Reported By : 717876

Page 1 of 1

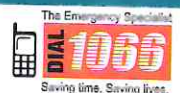For Enquiry/Appointments Contact +91 76988 15003 / +91 79 66701880

Apollo Hospitals International Limited
Plot No.-1A, Bhat, GIDC, Gandhinagar, Gujarat - 382429, India.
Phone : +91 79 66701800 | Fax No. : +91 79 66701843
E-mail : info@apolloahd.com | www.ahmedabad.apollohospitals.com

Apollo Hospitals - City Centre (NON NABH-JCI)
1, Tulshibaug Society, Nr. Parimal Garden, Ahmedabad.
Phone : +91 79 66305800 / 01 or +91 78988 15148
E-mail : info@hcc@apolloahd.com

For online appointment : www.askapollo.com
Keep the records carefully and bring them along during your next visit to our Hospital

Regd. Office
19, Bishop Gardens, R.A. Puram, Chennai - 600 028
CIN No. : U85110TN1997PLC039016 | GSTIn : 24AABCA4150H225
For online appointment : www.askapollo.com






Organization is Accredited
by Joint Commission International



RADIOLOGY

Patient Details : Mr. VINAYPRAKASH SHRIVASTAV | Male | 53Yr 1Mth 16Days
UHID : AHIL.0000508006 **Patient Location:** AHC
Patient Identifier: AHILAH195061 
DRN : 223010477 **Completed on :** 25-FEB-2023 09:55
Ref Doctor : DR. SHASHIKANT NIGAM

USG WHOLE ABDOMEN

FINDINGS :

Liver appears normal in size and shows uniform bright echotexture. No evidence of focal pathology seen. Intra and extra hepatic biliary radicles are not dilated. Portal vein is normal in calibre. Intrahepatic portal radicles appear normal.

Gall bladder appears normal with no evidence of calculus. Wall thickness appears normal. No evidence of pericholecystic collection.

Visualized pancreas appear normal in size and echotexture.

Spleen measures 11.5 cms and shows uniform echotexture.

Both kidneys are normal in size and show normal echopattern with good corticomedullary differentiation. Cortical outlines appear smooth. No evidence of calculi. Pelvicalyceal system on both sides appear normal.

No evidence of ascites or lymphadenopathy.

Urinary bladder is normal in contour and outline. Wall thickness appears normal. No evidence of any intraluminal pathology seen.

Prostate measures (volume 17 cc) is normal in size and echopattern.

IMPRESSION :

Grade I fatty liver.

Rest normal study.

Printed on : 27-Feb-2023 10:49

Printed By : 153182

Reported By : 717876

Page 1 of 2

For Enquiry/Appointments Contact +91 76988 15003 / +91 79 66701880

Apollo Hospitals International Limited
 Plot No.-1A, Bhat, GIOC, Gandhinagar, Gujarat - 382428, India.
 Phone : +91 79 66701800 | Fax No. : +91 79 66701843
 E-mail : info@apolloahd.com | www.ahmedabad.apollohospitals.com

Apollo Hospitals - City Centre (NON MASH-JCI)
 1, Tulsibaug Society, Nr. Parimal Garden, Ahmedabad.
 Phone : +91 79 66305800 / 01 or +91 76988 15148
 E-mail : infoahcc@apolloahd.com

Regd. Office
 19, Bishop Gardens, R.A. Puram, Chennai - 600 028
 CIN No. : U85110TN1997PLC039016 | GSTIn : 24AABCA4150H225
 For online appointment : www.askapollo.com



For online appointment : www.askapollo.com
 Keep the records carefully and bring them along during your next visit to our Hospital

Saving time. Saving lives.



Organization is Accredited
by Joint Commission International



Mr. VINAYPRAKASH SHRIVASTAV

AHIL.0000508006

AHILAH195061

USG WHOLE ABDOMEN

--- END OF THE REPORT ---

S. S. Parmar

SIDDHARTH S PARMAR

Medical Officer

Printed on : 27-Feb-2023 10:49

Printed By : 153182

Reported By : 717876

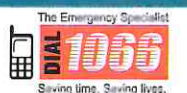Page 2 of 2

For Enquiry/Appointments Contact +91 76988 15003 / +91 79 66701880

Apollo Hospitals International Limited
Plot No.-1A, Bhat, GIDC, Gandhinagar, Gujarat - 382428, India.
Phone : +91 79 66701800 | Fax No. : +91 79 66701843
E-mail : info@apolloahd.com | www.ahmedabad.apollohospitals.com

Apollo Hospitals - City Centre (NON NABH-JCI)
1, TulsiBaag Society, Nr. Paimal Garden, Ahmedabad.
Phone : +91 79 66305800 / 01 or +91 76986 15148
E-mail : infoahcc@apolloahd.com

Regd. Office
19, Bishop Gardens, R.A. Puram, Chennai - 600 028
CIN No. : U85110TN1997PLC039016 | GSTin : 24AAAC44150H225
For online appointment : www.askapollo.com



For online appointment : www.askapollo.com
Keep the records carefully and bring them along during your next visit to our Hospital

Rate 54

PR 143
QRSD 161
QT 479
QTc 454

--AXIS--

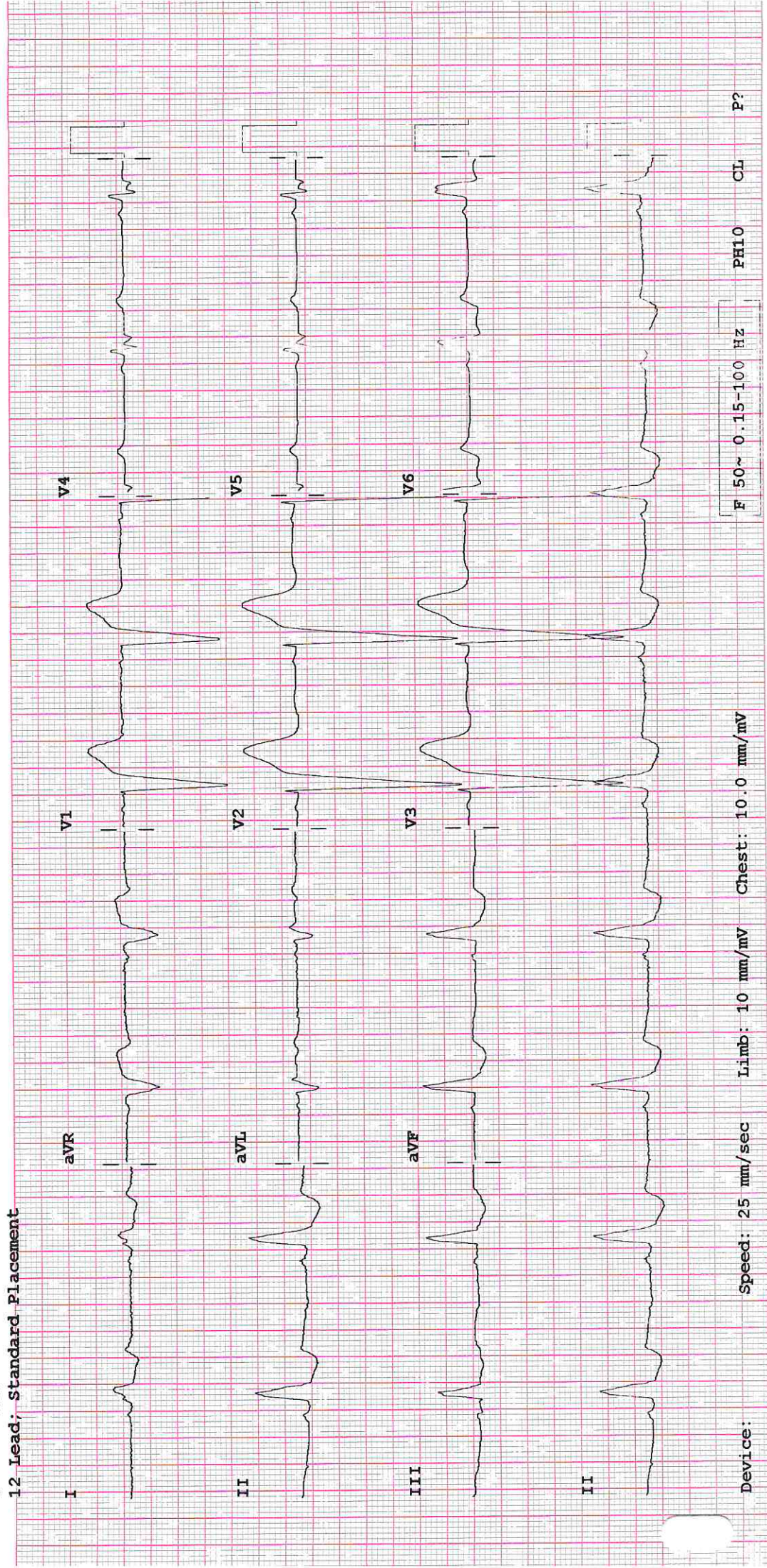
P 43
QRS 69
T 259

AHIL.0000508006
Mr. VINAYPRAKASH
SHRIVASTAV

53 Year(s) / Male



12 Lead, Standard Placement



Device:

Speed: 25 mm/sec

Limb: 10 mm/mV

Chest: 10.0 mm/mV

F 50~ 0.15-100 Hz

PH10 CL

P?



AHIL.0000508006

Mr. VINAYPRAKASH
SHRIVASTAV

53 Year(s) / Male



HID,
n

DENTISTRY

Name : Date : 25/02/23 Unit No. :
 Occupation : Ref. Physician :
 Age : Sex : Male Female Copies to :

DENTAL RECORD

ALLERGIES : None

PAIN : Score (0-10) 0 Location : Character :

DENTAL CLEANING HABIT Once Twice Occasionally
 Brush Finger Stick Any other
 Tooth Paste Powder Any other

DO THE GUMS BLEED WHEN YOU BRUSH YOUR TEETH? Yes No

ARE YOUR TEETH SENSITIVE TO HEAT / COLD? Yes No

ORAL HYGIENE Good Fair Poor

ORAL TISSUE EXAMINATION	PERIODONTAL EXAMINATION	OCCLUSION
NORMAL FINDINGS IN DISEASE	MILD MOD SEV	CLASS I II III CROSSBITE
Lips : <u>None</u>	Gingivitis <input type="checkbox"/> <input type="checkbox"/> <input type="checkbox"/>	Hypoplasia <u>None</u>
Cheeks : <u>None</u>	Calculus <input type="checkbox"/> <input type="checkbox"/> <input type="checkbox"/>	Impaction <u>None</u>
Tongue : <u>None</u>	Recession <input type="checkbox"/> <input checked="" type="checkbox"/> <input type="checkbox"/>	Non-vital <u>None</u>
Floor of the mouth : <u>None</u>	Periodontal Pockets <input type="checkbox"/> <input type="checkbox"/> <input type="checkbox"/>	Fracture <u>None</u>
Palate : <u>None</u>	Attrition <input type="checkbox"/> <input type="checkbox"/> <input type="checkbox"/>	Abcess <u>None</u>
Tonsillar Area : <u>None</u>	Erosion <input type="checkbox"/> <input type="checkbox"/> <input type="checkbox"/>	Ulcers <u>None</u>
Any other : <u>None</u>	Mobility <input type="checkbox"/> <input type="checkbox"/> <input type="checkbox"/>	Caries <u>None</u>
		Missing Teeth <u>None</u>
		Supernumerary <u>None</u>
		Others <u>None</u>

PRESENT COMPLAINT : Pourti clicky Hypoxia

PRE-MEDICAL HISTORY: DM HTN Thyroid Acidity Pregnancy
 Anticoagulant Under Drug Therapy



AHIL.0000508006
Mr. VINAYPRAKASH
SHRIVASTAV

53 Year(s) / Male

VISION RECORDS

Name :



Date :

25/2/23

UHID :

Distance Vision :

Right Eye -

6/6 CP)

Left Eye -

6/6 CP)

Near Vision :

Right Eye :

N6

Left Eye :

N6

APLN.TN - Right Eye

14

Left Eye -

16

mmHg

Both Eye - Colour Vision

Normal

Both Eye - Anterior Segment Examinations -

WM

Both Eye Posterior Segment Examinations -

WMT

Dr. Jagriti Sinha
MS (Ophthalmology)
Jr. Consultant

Apollo Hospitals International Ltd., Gandhinagar,
Gujarat-382428, INDIA. Regd. No.: G-68792

Doctor's Signature

Ophthalmologist Name