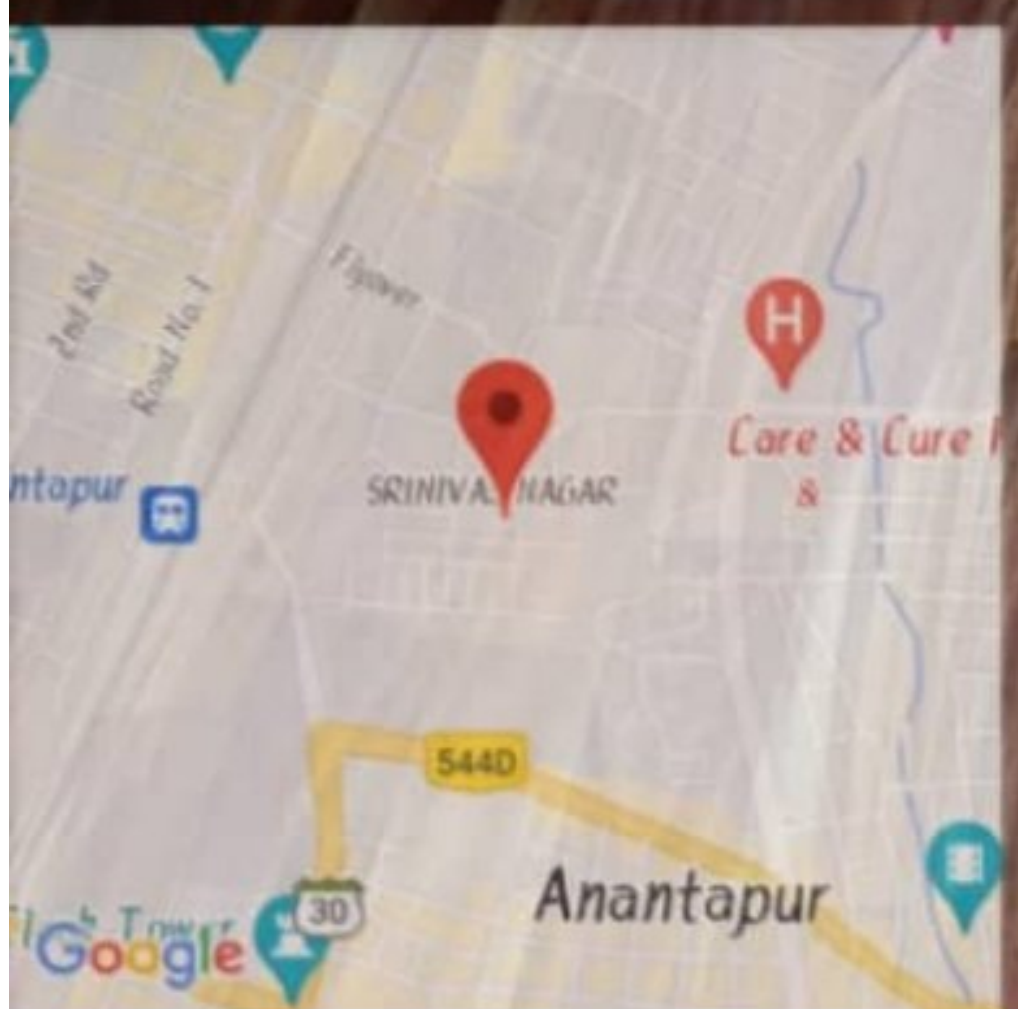


Feb 12, 2023 7:24:13 AM  
281° W  
Srinivas Nagar  
Anantapur  
Andhra Pradesh  
Altitude: 259.1m  
Index number: 979



आयकर विभाग  
INCOME TAX DEPARTMENT



भारत सरकार  
GOVT. OF INDIA

MANNURI ASHARAF  
PYARILBASHA MANNURI

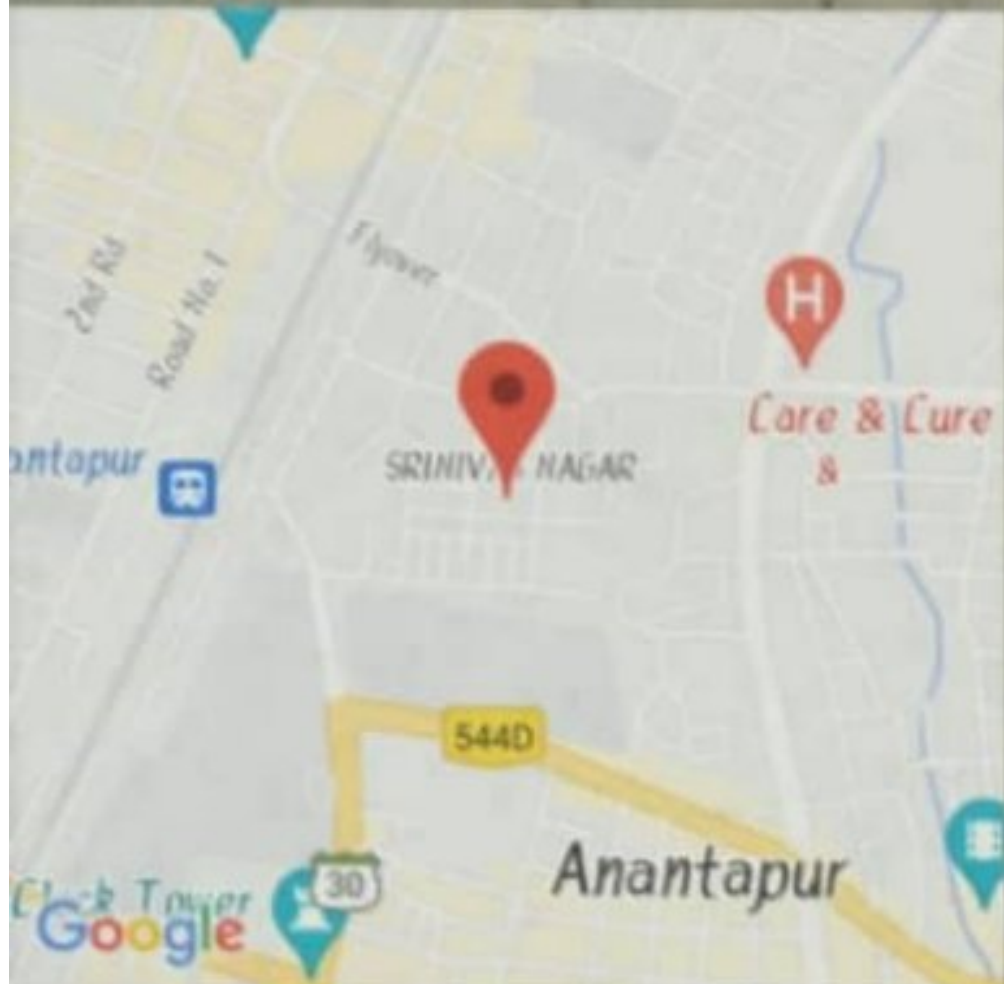


02/04/1989  
Permanent Account Number

BGFPM9772F



*H. Asharaf*  
Signature



Feb 12, 2023 7:23:45 AM  
137° SE

Srinivas Nagar  
Anantapur  
Andhra Pradesh  
Altitude: 259.1m

Index number: 978

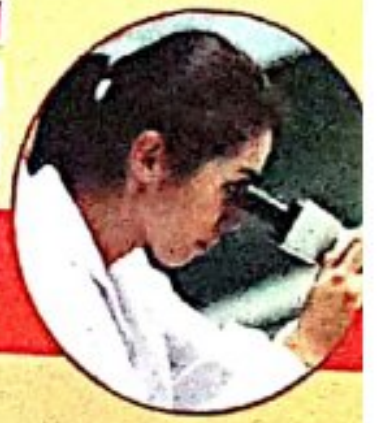

# AMRUTHA SAI DIAGNOSTIC CENTRE

Cell : 868 898 4900, 9966 77 4621

email : amruthasailab@gmail.com

ISO.9001 : 2015 Certificate Number : Q91864141412



Name :- Mr M Ashraf

Age/Sex :- 33 y/male

Date :- 12-02-2023

Ref.by :- Mediwheel (BOB)

ID.No:- D4/2023, BOBE29003, PKG-100000227, BC-16034

## EMPLOYEE MEDICAL CHEK UP FORM

### Physical Examination :-

Height :- 181 cms.

Weight :- 93 kgs.

Abdomen (CMS) :- 72 cms

Chest Expir(CMS):- 95

Chest Insp(CMS) : 100

Body mass index(BMI) :- 28.4

Pulse Rate :- 72 minute. (Regular / Abnormal)

Skin :- Normal Open Lesions :- n/c

Oral Hygeine : Healthy

Complaints if Any :- n/c

Family History :- n/c

Complaints if Any :- n/c

### Systemic Examination (Abnormality – if Yes Please Explain) :-

CVS - Yes / No

CNS - Yes/ No

Gi Tract - Yes/No

Abdomen - Yes/ No

Respiratory Tract - Yes/ No

### Personal History :-

Smoking :- Yes/No

Alcohol sim :- Yes/No

Diabetes :- Yes/No

Allergy :- Yes/No

BP :- 120/80 mm/hg

Nails :- Normal

### INVESTIGATIONS : ( N= Normal, R= See Report)

Complete Blood Picture With ESR = Normal

Complete Urine Examination = Normal

FBS, PLBS = Normal

Colour Vision = Normal

USG = Normal

Chest X-Ray = Normal

\* ECG = Normal

\* LFT = Normal

\* LIPID = Normal

\* Eye&ENT Examination = Normal

\* 2D ECHO = Normal

\* Stool R/E = Normal

Diagnosis (If Any) :- n/c

RECOMMENDATIONS / IMPRESION :- n/c

*[Signature]*  
PHYSICIAN SIGNATURE

Dr. V. Anandappa,  
M.B.B.S,FCGP.  
PHYSICIAN & SURGEON  
Regd.No. 88543  
Authorised Doctor,  
For State Bank of India  
ANANTAPUR.

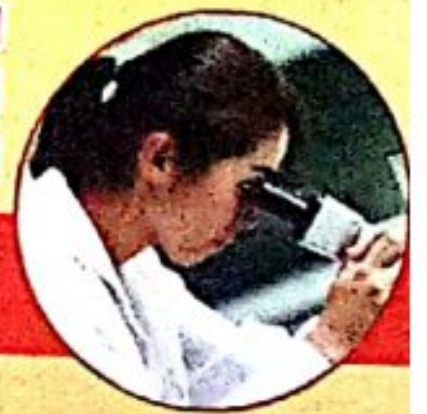
Under AP Govt. Regd. Diagnostic Centre R.No.98/2012-2013

Genuineness is our gene



# AMRUTHA SAI DIAGNOSTIC CENTRE

Cell : 868 898 4900, 9966 77 4621



email : amruthasailab@gmail.com

ISO.9001 : 2015 Certificate Number : Q91864141412

Patient Name : Mr Asharf

Sex : male

Age : 33 Yrs

Id.No : D4/22

Bill Date : 12-02-2023

Report Date : 12-02-2023

Ref. by : BOB Health Check up

Address : A T P

## LAB REPORT

Blood For :-

Parameter	Findings	Reference Range
<b>Complete Haemogram (CBP) :-</b>		
Haemoglobin % (C M G)	: 13.6 gm %	M : 12.0 – 17.0 gm %
Total WBC Count	: 7600 ce/cu mm	A : 4000 – 11000 ce/cu mm
Differential WBC Count	: Neutrophils – 60 % Lymphocytes – 35 % Eosinophils – 03 % Monocytes – 02 %	45 – 65 % 25 – 45 % 01 – 06 % 02 – 08 %
E S R (Westergren Method)	: 17 mm/ 1 hr	M : 01 – 15 mm/1 hr
RBC Count	: 4.8 mill/cu mm	M : 4.5 – 6.5 mill/cu mm
Platelet Count	: 2.5 Lach/cu mm	1.5 – 4.0 Lach/cu mm
Packed Cell Volume (PCV)	: 43.6 %	M : 40 – 54 %
Mean Corpuscular Volume (MCV)	: 90 fl	82 – 92 fl
Mean Corpuscular Haemoglobin (MCH)	: 30.6 pg	27 – 32 pg
Mean Corpuscular Haemoglobin Concentration (MCHC)	: 33.2 %	32 – 36 %
Blood Group & Rh Type	:- "O" Positive(+Ve)	

TEST NAME	METHOD	VALUE	UNITS
GLYCOSYLATED HAEMOGLOBIN (Hb A1 c) %	TURBIDOMETRY	5.36	%

Reference Range :-

BELOW 6.0 %	- NORMAL VALUE
6.0 % - 7.0 %	- GOOD CONTROL
7.0 % - 8.0 %	- FAIR CONTROL
8.0 % - 10.0 %	- UNSATISFACTORY CONTROL
ABOVE 10.0 %	- POOR CONTROL

@ Suggested clinical Correlation, If there is need, kindly discuss.

*S. Vijaya Lakshmi*  
 ABINCHARZE  
 S. Vijaya Lakshmi  
 M.Sc (Biochemistry)

Under AP Govt. Regd. Diagnostic Centre R.No.98/2012-2013

Genuineness is our gene

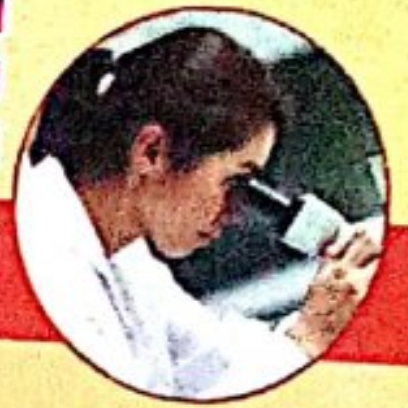

# AMRUTHA SAI DIAGNOSTIC CENTRE

Cell : 868 898 4900, 9966 77 4621

email : amruthasailab@gmail.com

ISO.9001 : 2015 Certificate Number : Q91864141412



Patient Name : Mr Asharf

Sex : male

Age : 33 Yrs

Id.No : D4/22

Bill Date : 12-02-2023

Report Date : 12-02-2023

Ref. by : BOB Health Check up

Address : A T P

Blood For :-

## LAB REPORT

Parameter	Findings	Reference Range
<b>LIPID PROFILE :-</b>		
Cholesterol Total	: 198 mg/dl	150 - 260 mg/dl
H D L Cholesterol	: 47 mg/dl	M : 35 - 55 mg/dl
L D L Cholesterol	: 101 mg/dl	66 - 178 mg/dl
V L D L Cholesterol	: 32 mg/dl	5 - 40 mg/dl
Triglycerides	: 182 mg/dl	36 - 165 mg/dl
CHOL : HDL Chole	: 3.9 : 1	3.0 - 5.0 : 1
Fasting Blood Sugar	: 89 mg/dl	65 - 110 mg/dl
Post Prandial Blood Sugar	: 126 mg/dl	80 - 160 mg/dl
<b>Reanal Function Test (RFT) :-</b>		
B U N	: 12 mg/dl	7 - 18 mg/dl
Serum Creatinine	: 1.0 mg/dl	0.7 - 1.4 mg/dl
Serum Uric Acid	: 3.6 mg/dl	3.0 - 5.7 mg/dl
Serum Calcium	: 9.1 mg/dl	8.7 - 10.4 mg/dl
<b>LIVER FUNCTION TEST (LFT) :-</b>		
Bilirubin Total	: 0.6 mg/dl	0.1 - 1.0 mg/dl
Bilirubin Direct	: 0.11 mg/dl	0.0 - 0.25 mg/dl
Bilirubin Indirect	: 0.4 mg/dl	0.2 - 0.8 mg/dl
Total Proteins	: 6.7 gm/dl	6.0 - 8.0 gm/dl
Albumin	: 4.2 gm/dl	3.7 - 5.3 gm/dl
Globulins	: 2.5 gm/dl	2.5 - 4.5 gm/dl
S G O T ( A S T )	: 29 IU/L	Upto - 40 IU/L
S G P T ( A L T )	: 36 IU/L	Upto - 47 IU/L
Alkaline Phosphatase (ALP)	: 186 IU/L	A : 100 - 290 IU/L
Gamma Glutamyl Transferase (GGT)	: 29 IU/L	M : Upto - 50 IU/L

@ Suggested clinical Correlation, If there is need, kindly discuss.

LAB INCHARGE  
*S. Vijaya Lakshmi*  
 S. Vijaya Lakshmi  
 M.Sc (Biochemistry)

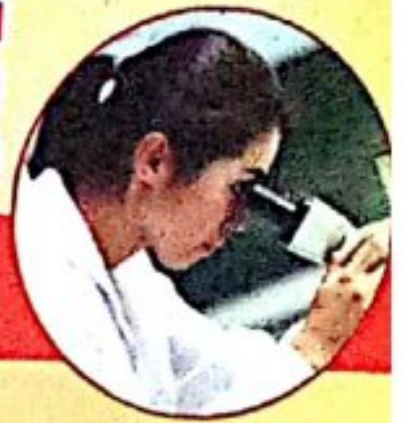Under AP Govt. Regd. Diagnostic Centre R.No.98/2012-2013

**Genuineness is our gene**



# AMRUTHA SAI DIAGNOSTIC CENTRE

Cell : 868 898 4900, 9966 77 4621



email : amruthasailab@gmail.com  
ISO.9001 : 2015 Certificate Number : Q91864141412

Patient Name : Mr Asharf                      Sex : male                      Age : 33 Yrs

Id.No : D4/22                      Bill Date : 12-02-2023                      Report Date : 12-02-2023

Ref. by : BOB Health Check up                      Address : A T P

## LAB REPORT

### Complete Urine Analysis(C U A) :-

#### Physical Examination :-

Colour	: Pale Yellow	Transparency	: Clear
Reaction	: Acidic	Sediment	: NIL
Sp.Gravity	: 1.005	pH	: 6.0

#### Chemical Examination :-

Sugar	: Absent	Proteins	: Traces
Bile Salts	: Absent	Bile Pigments	: Absent
Urobilinogen	: Normal	Ketone Bodies	: Negative
Blood	: Absent		

#### Microscopic Examination :-

Pus Cells	: 5 - 6 /hpf	E.P.Cells	: 2 - 3 /HPF
RBC's	: Absent	Casts	: Absent
Crystals	: Absent	Deposits	: Absent
Bacteria	: Absent		

### STOOL COMPLETE EXAMINATION

Colour	: Yellow
Consistency	: Solid
Mucus	: Absent

### MICROSCOPY:

Trophozoites	: Absent	Macriophages	: Absent
Ova / EGGs	: Absent	Cysts	: Absent
Pus Cells	: 2 - 3 / hpf	RBC	: Absent
Fat Globuls	: Present(+)	Veg.Cells/Fibres	: Present (+)
Parasites	: Absent	Others	: Small Bacilli Seen /hpf

@ Suggested clinical Correlation, If there is need, kindly discuss.

*S. Vijaya Lakshmi*  
S. Vijaya Lakshmi  
M.Sc (Biochemistry)

# **Note:-** Amrutha Sai Diagnostic Centre . (Fully Automated A/C Laboratory)  
\*\*\*\*\* Since - 25 Years \*\*\*\*\*

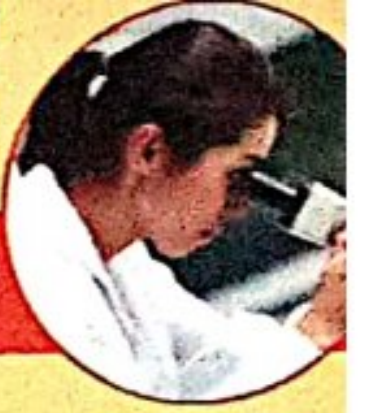Opp.Balaji Kalyana Mantapam, Near RTC Bus Stand, Reliance Mart Road,  
Srenivasa Nagar, ANANTHAPURAM. CELL - 86 88 984900.

Under AP Govt. Regd. Diagnostic Centre R.No.98/2012-2013

**Genuineness is our gene**



# AMRUTHA SAI DIAGNOSTIC CENTRE



Cell : 868 898 4900, 9966 77 4621

email : amruthasailab@gmail.com

ISO.9001 : 2015 Certificate Number : Q91864141412

Patient Name : Mr Asharf

Sex : male

Age : 33 Yrs

Id.No : D4/22

Bill Date : 12-02-2023

Report Date : 12-02-2023

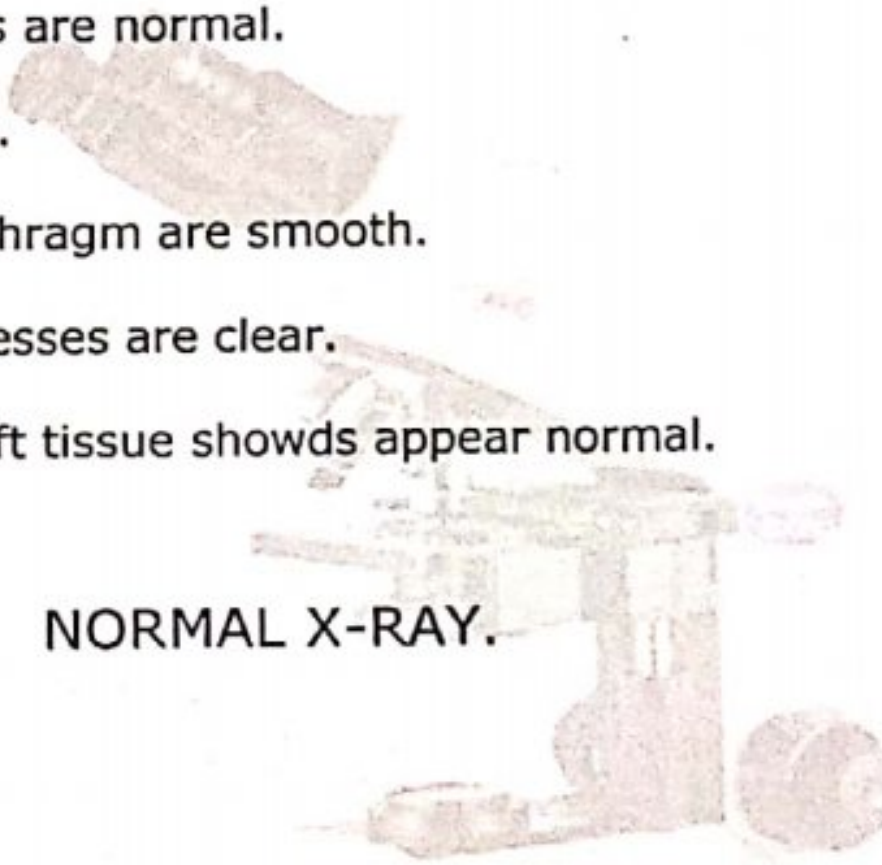
Ref. by : BOB Health Check up

Address : A T P

## XRAY-CHEST (PA) VIEW

- Trachea is central
- Both th lung fields appear normal.
- Hilar shadows are with in normal limits.
- Pulmonary vasculatures are normal.
- Cardia is normal in size.
- Both domes of the diaphragm are smooth.
- Both costophrenic recesses are clear.
- Visualized bones and soft tissue shows appear normal.

IMPRESSION :- NORMAL X-RAY.

  
Dr. K. RADHAKRAN, MD,  
Specialist in Ultra-Sound,  
Radio Diagnosis & C.T. Scan  
RADIOLOGIST SIGNATURE  
Govt. Medical College &  
General Hospital  
Chittoor

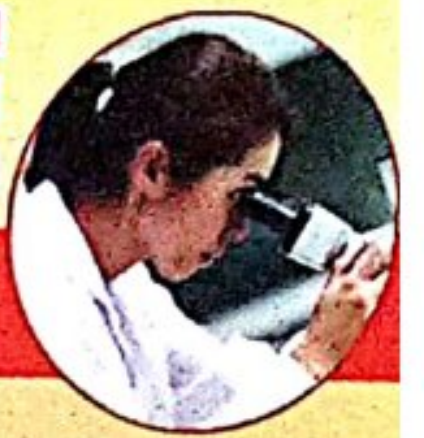# **Note:-** Amrutha Sai Diagnostic Centre . (Fully Automated A/C Laboratory)  
\*\*\*\*\* Since - 25 Years \*\*\*\*\*  
Opp. Balaji Kalyana Mantapam, Near RTC Bus Stand, Reliance Mart Road,  
Srenivasa Nagar, ANANTHAPURAM. CELL - 86 88 984900.

Under AP Govt. Regd. Diagnostic Centre R.No.98/2012-2013

**Genuineness is our gene**



# AMRUTHA SAI DIAGNOSTIC CENTRE



Cell : 868 898 4900, 9966 77 4621

email : amruthasailab@gmail.com

ISO.9001 : 2015 Certificate Number : Q91864141412

Name : Mr. M Ashraf

Age/Gender : 33 Yrs / M

Ref. Dr. : Self

Req No. : SMN2311675

Sample Type : Serum

Client Name : AMRUTHA SAI DIAGNOSTICS-CMLAPF10

COMP0125 :

Vial ID : 240125

Collected On : 12-Feb-2023 07:00 AM

Registered On : 13-Feb-2023 07:30 AM

Reported On : 01-Feb-2023 12:10PM

Client Code : CMLAPF10

## IMMUNOASSAY THYROID PANEL-II

Test Name	Observed Values	Units	Biological Reference Intervals
* TOTAL TRIIODOTHYRONINE ( T3 ) Method:ECLIA	1.09	ng/mL	0.82 - 2.0
* TOTAL THYROXINE ( T4 ) Method:ECLI	8.52	ug/dl	5.1 - 14.1
* THYROID STIMULATING HORMONE (TSH) Method:ECLIA	3.26	µIU/mL	Adult : 0.35 – 5.5 pediatric range: Birth – 4 days:1.0-39 2- 20 Weeks: 1.7- 9.1 20 weeks- 20 yrs:0.7-6.4

### INTERPRETATION::

The determination of T3 is utilized in the diagnosis of T3hyperthyroidism,the detection of early stages of hyperthyroidism and for indicating a diagnosis of thyrotoxicosis factitia.

The determination of T4 can be utilized for the following indications: the detection of hyperthyroidism, the detection of primary and secondary hypothyroidism, and the monitoring of TSH-suppression therapy.

The determination of TSH serves as the initial test in thyroid diagnostics.Even very slight changes in the concentrations of the free thyroid hormones bring about much greater opposite changes in the TSH level. Accordingly,TSH is a very sensitive and specific parameter for assessing thyroid function and is particularly suitable for early detection or exclusion of disorders in the central regulating circuit between the hypothalamus, pituitary and thyroid.

U Mehatha.M.Sc  
BIOCHEMIST

Dr.Tamkinath Fatima,MD  
CONSULTANT BIOCHEMIST

Please Corelate With Clinical Findings If Necessary Discuss. This is an Electronically Authenticated Report

Page 1 of 1



Under AP Govt. Regd. Diagnostic Centre R.No.98/2012-2013

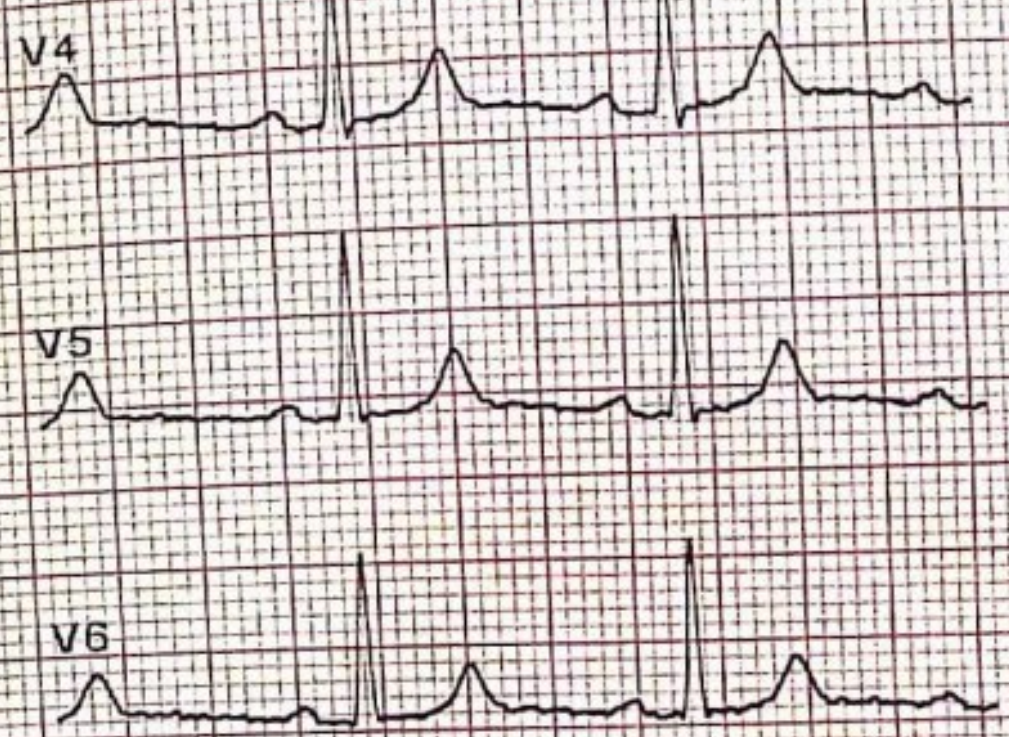
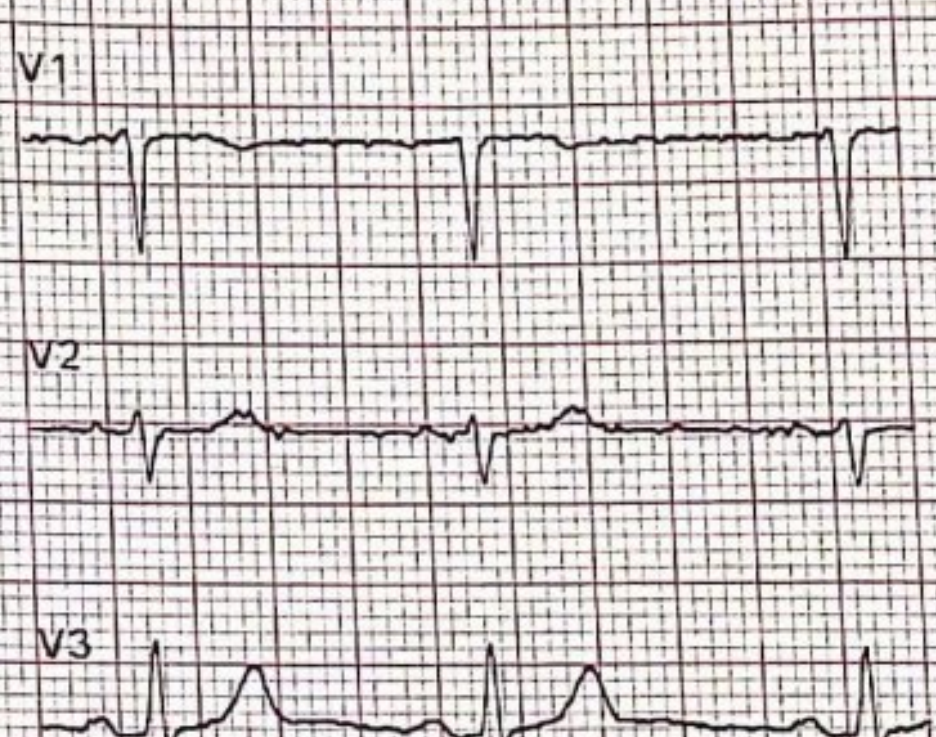
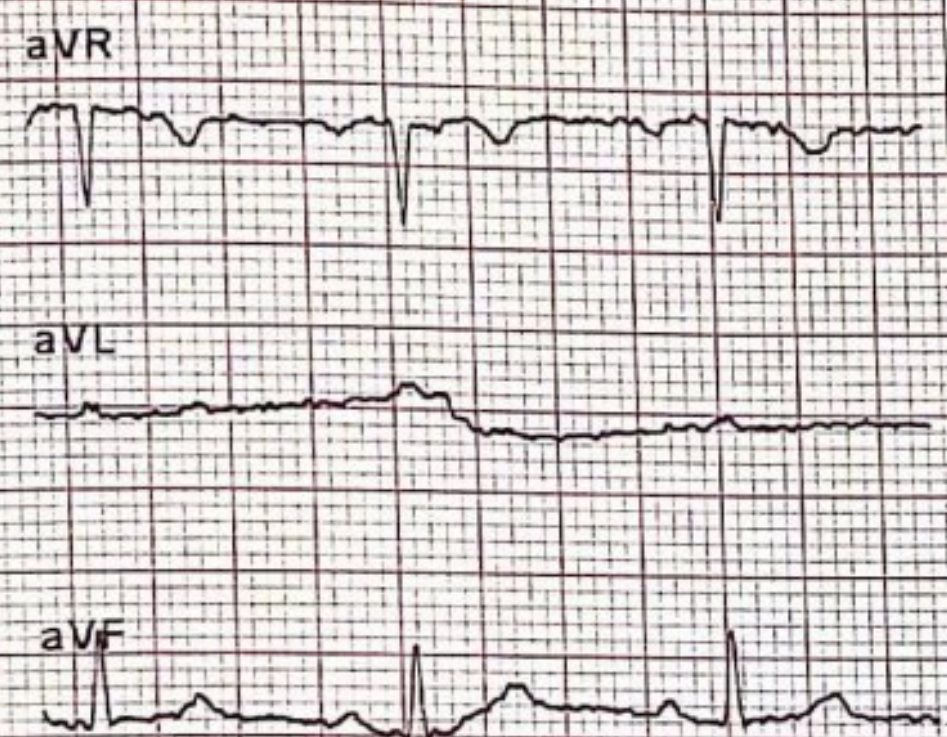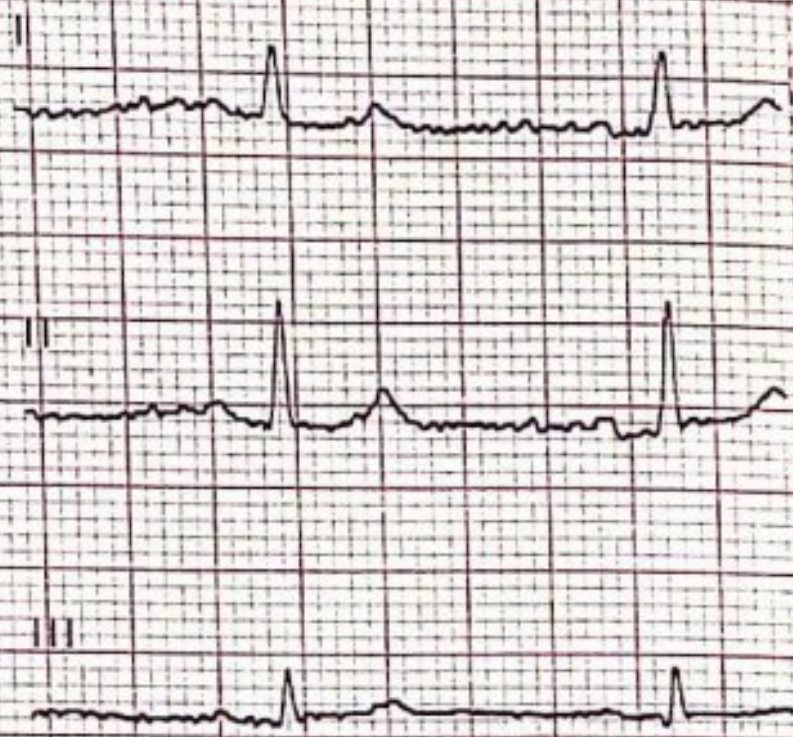Genuineness is our gene

Scanned with CamScanner



HR 73 /bpm

12.02.2023 07:21:34



25 mm/s, 10 mm/mV

LP 25 Hz, AC 50 Hz

Sequential

Poor lead quality

AT-1 G2 (1070.006301), 1.2.1

SCHILLER Part No 2 157044M CE 0123

SCHILLER Part No 2 157044M CE 0123 SRR

SCHILLER Part No 2 157044M CE 0123

SCHILLER Part No 2 157044M CE 0123 S.BB

12.02.2023 07:21:34

Normal ECG

Sinus rhythm  
Normal electrical axis

Unconfirmed report

Mr. N. Ashraf

38y/med

Date: 12/2/23

Time: 07:21 AM

**Dr. V. Narayanappa,**  
M.B.B.S, FCCP  
PHYSICIAN & SURGEON  
Regd. No. 88543  
Authorised Doctor,  
For State Bank of India  
ANANTAPUR.

HR 73/bpm

RR	821 ms	P axis	43°
P	88 ms	QRS axis	49°
PR	158 ms	T axis	52°
QRS	74 ms		
QT	368 ms		
QTc	406 ms		
(Bazett)			
Sokolow	2.23 mV		
Cornell	0.41 mV		
Lewis	0.05 mV		
Romhilt	-		

12.02.2023 07:21:34

Name

Patient ID  
Date of Birth  
Gender  
Pacemaker

Height ..... cm

Weight ..... kg

BP ..... / ..... mmHg

Medication

Remark

AT-1 G2 (1070-006301), 1-2-1

SCHILLER Part No. 2.157044M 0123 S.BB

SCHILLER Part No. 2.157044M 0123 S.BB

SCHILLER Part No. 2.157044M 0123 S.BB

SCHILLER Part No. 2.157044M 0123 S.BB



## 2D ECHOCARDIOGRAM- COLOUR DOPPLER STUDY

NAME:-MR.M.ASHARAF	AGE/GENDER:33Y/MALE	DATE:12/02/2023
REFERED BY:-	MRNO:-	OP/IP NO:-
ECHO DONE BY:- DR.R.KATYAYINI	S.NO:-	TAPE NO:-

MITRAL VALVE :- NORMAL  
 AORTIC VALVE :- NORMAL  
 TRICUSPID VALVE :- NORMAL  
 PULMONARY VALVE :- NORMAL  
 RIGHT ATRIUM :- NORMAL  
 RIGHT VENTRICLE :- NORMAL  
 LEFT ATRIUM :-3.7cm  
 LEFT VENTRICLE :-NO RWMA

\*EDD :- 4.3 cm      IVSD :- 1.0 cm      EF:- 60 %  
 \*ESD :- 2.9 cm      PWD :- 1.0 cm      FS:- 30 %  
 \*EDV :- MI      ESV :- MI      EF:- %

IAS :- INTACT  
 IVS :- INTACT  
 AORTA :-3.0cm  
 PULMONARY ARTERY :- NORMAL  
 PERICARDIUM :-NORMAL  
 INTRACARDIAC MASSES :-NO  
 IVS/SVC/CS :- NORMAL  
 PULMONARY VEINS :- NORMAL  
 OTHERS :- NORMAL

### COLOUR FLOW MAPPING & DOPPLER

MR:-1+ AR:-NO TR:- 1+ PR:- NO

### DOPPLER

MITRAL :- E= 0.6m/sec A= 0.9m/sec EDT= 210 ms  
 TDI :- E/E'- A'-  
 AORTA :- VMAX = 1.2 m/sec  
 PULMONARY :- VMAX = 1.0 m/sec  
 TRICUSPID :- RVSP 20 mmHg  
 OTHERS :-

### ECHO DIAGNOSIS

- 1 NORMAL SIZED CARDIAC CHAMBERS
- 2 NO LV RWMA
- 3 TRIVIAL MR/TR
- 3 NORMAL LV/RV FUNCTION (EF – 60%)
- 4 NO PERICARDIAL EFFUSION
- 5 NO CLOT & NO VEGITATION,NO PAH

*Katyayini*

Dr. KATYAYINI MD.DNB  
 Consultant Interventional Cardiologist

**Dr. R. KATYAYINI**

MBBS., MD(Gen Med), DrNB(Cardiology)  
 Consultant Interventional Cardiologist

APMC Reg. No. 12345

CONSULTANT CARDIOLOGIST

*M.A.S.*

#13-2-392-4, Care & Cure Circle, NTR Marg, Near RTC Bus-Stand, Ananthapuramu - 515001.

Ph:08554 - 220555, 278999 Cell: 74166 84286, e-mail: careandcureatp@gmail.com website:www.careandcurehospitals.com

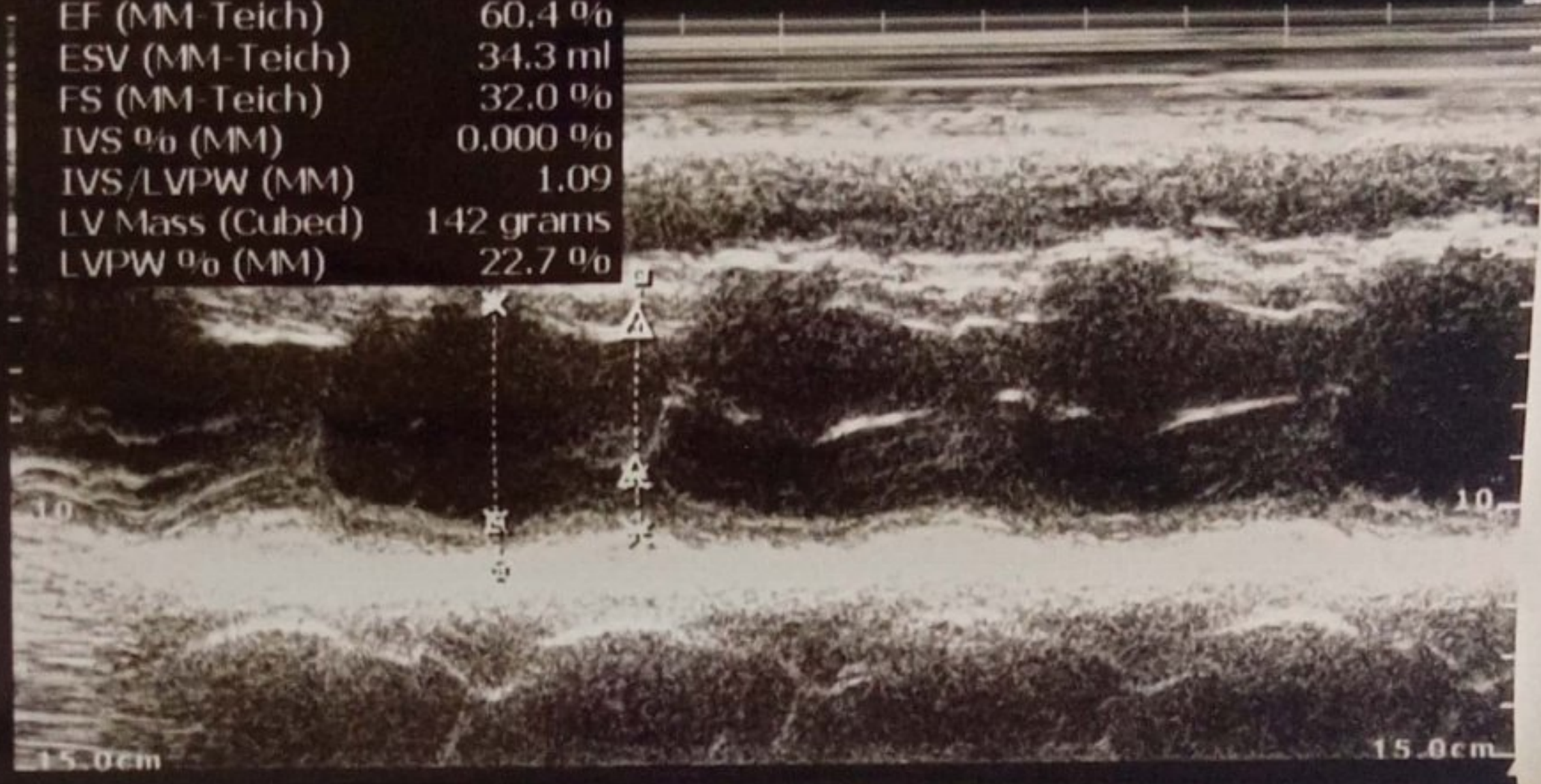
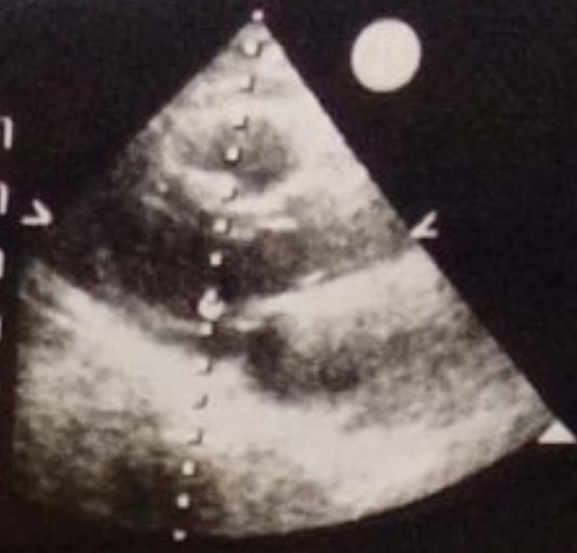PHILIPS M ASHARAF

MI 1.3 2/12/2023

23-02-12-101334 Care & Cure Hospital anantl TIS 0.5 10:27:31 AM

Adult Echo

S5-1	+ IVSd (MM)	1.02 cm
29 Hz	X LVIDd (MM)	4.38 cm
15.0cm	⊕ LVPWd (MM)	0.935 cm
	□ IVSs (MM)	1.02 cm
2D	Δ LVIDs (MM)	2.97 cm
HGen	X LVPWs (MM)	1.15 cm
Gn 60	EDV (MM-Teich)	86.6 ml
C 50	EF (MM-Teich)	60.4 %
3/2/0	ESV (MM-Teich)	34.3 ml
	FS (MM-Teich)	32.0 %
M-mode	IVS % (MM)	0.000 %
3/3	IVS/LVPW (MM)	1.09
75 mm/s	LV Mass (Cubed)	142 grams
	LVPW % (MM)	22.7 %



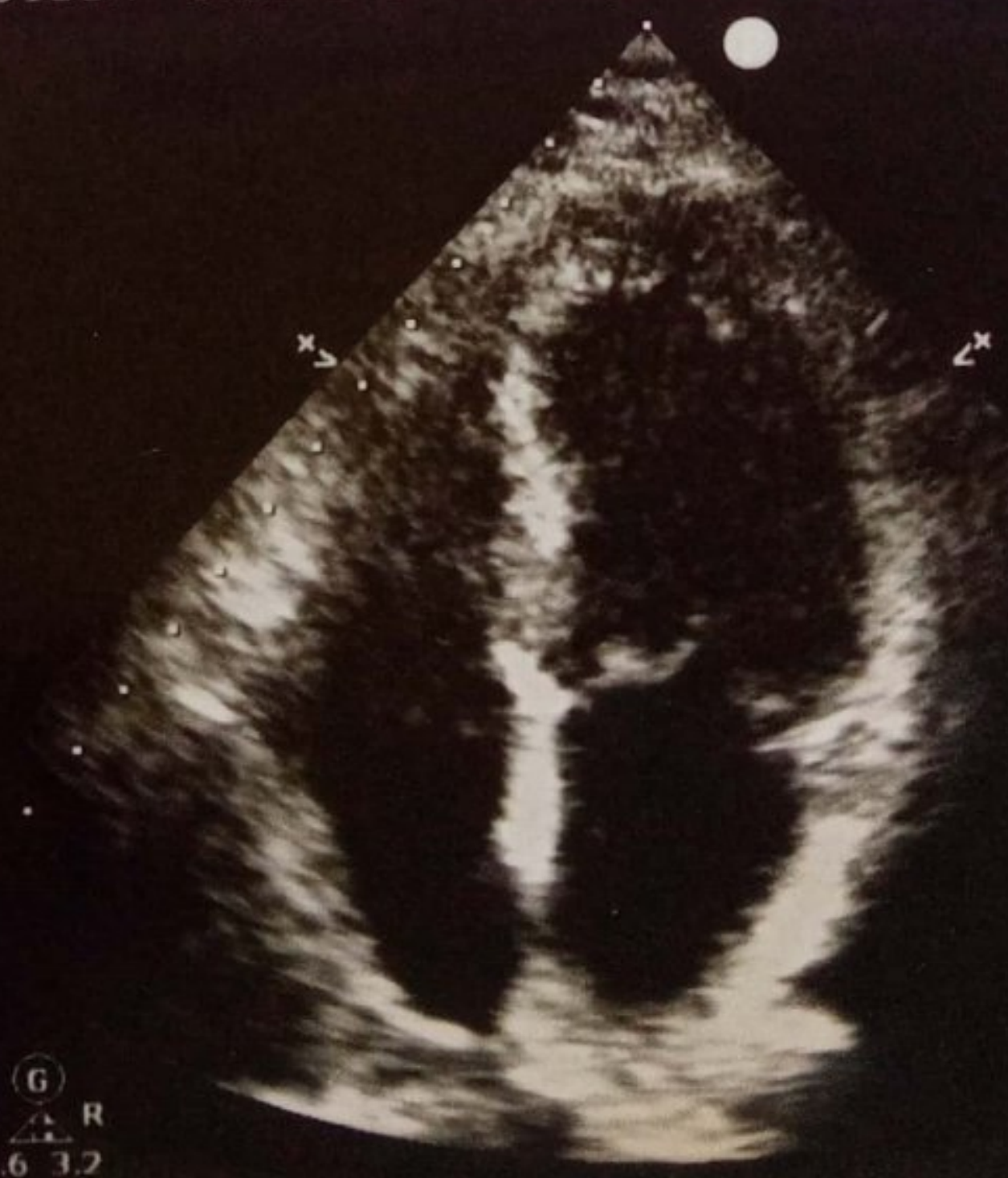PHILIPS M ASHARAF

MI 1.3 2/12/2023

23-02-12-101334 Care & Cure Hospital anantl TIS 0.3 10:19:00 AM

Adult Echo

S5-1  
34 Hz  
15.0cm  
2D  
HGen  
Gn 60  
C 50  
3/2/0  
75 mm/s



Ⓞ  
P R  
1.6 3.2

1st Cross, Sai Nagar,  
Near Surya Nagar Bus Stop,  
ANANTAPURAMU - 515001.  
Contact : +91 79893 30974



**VASUNDHARA**  
DIAGNOSTICS  
FETAL MEDICINE CENTRE

Patient Name : Mr. M.Ashraf  
Referred By : Amrutha Sai diagnostic center

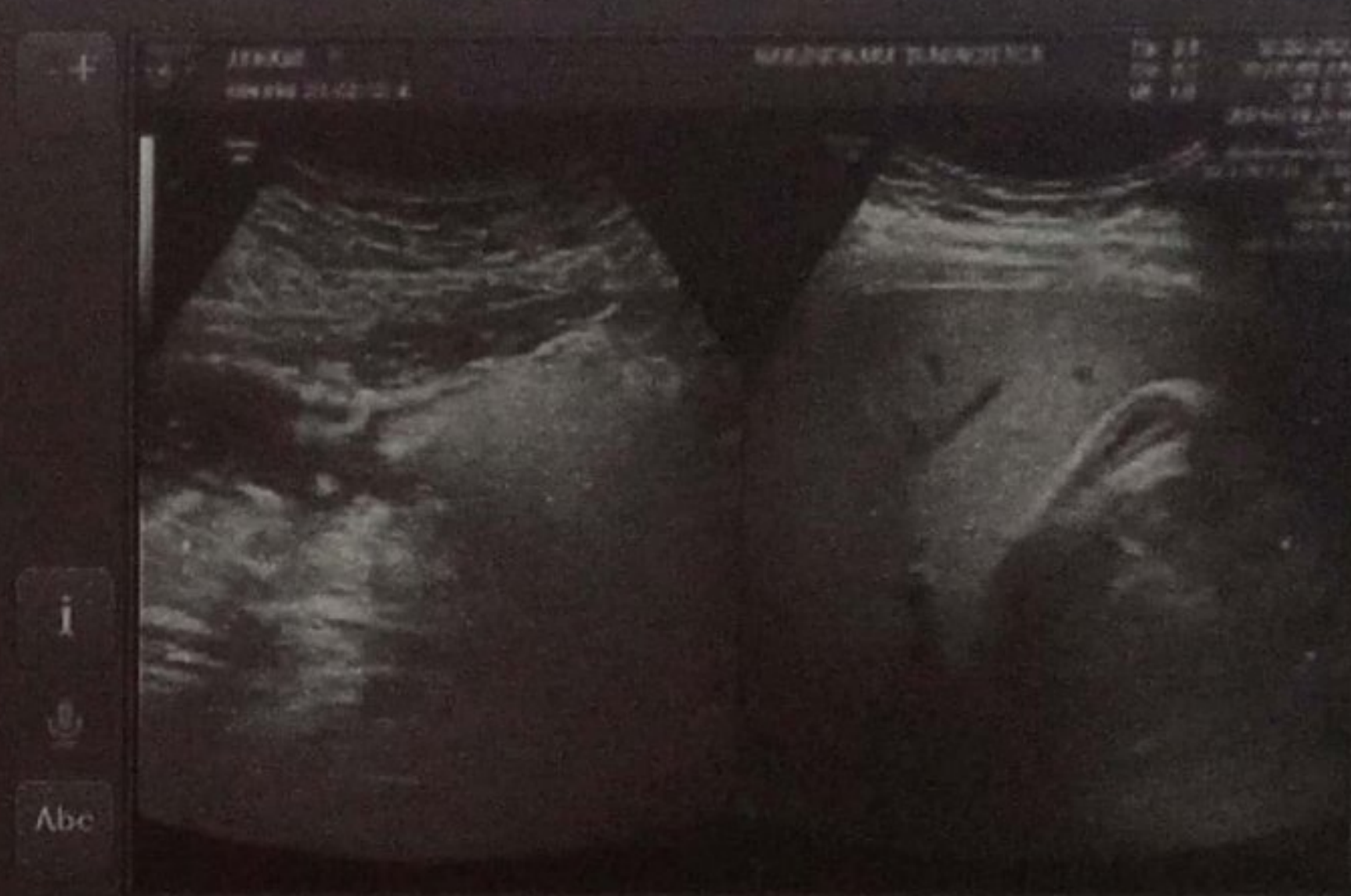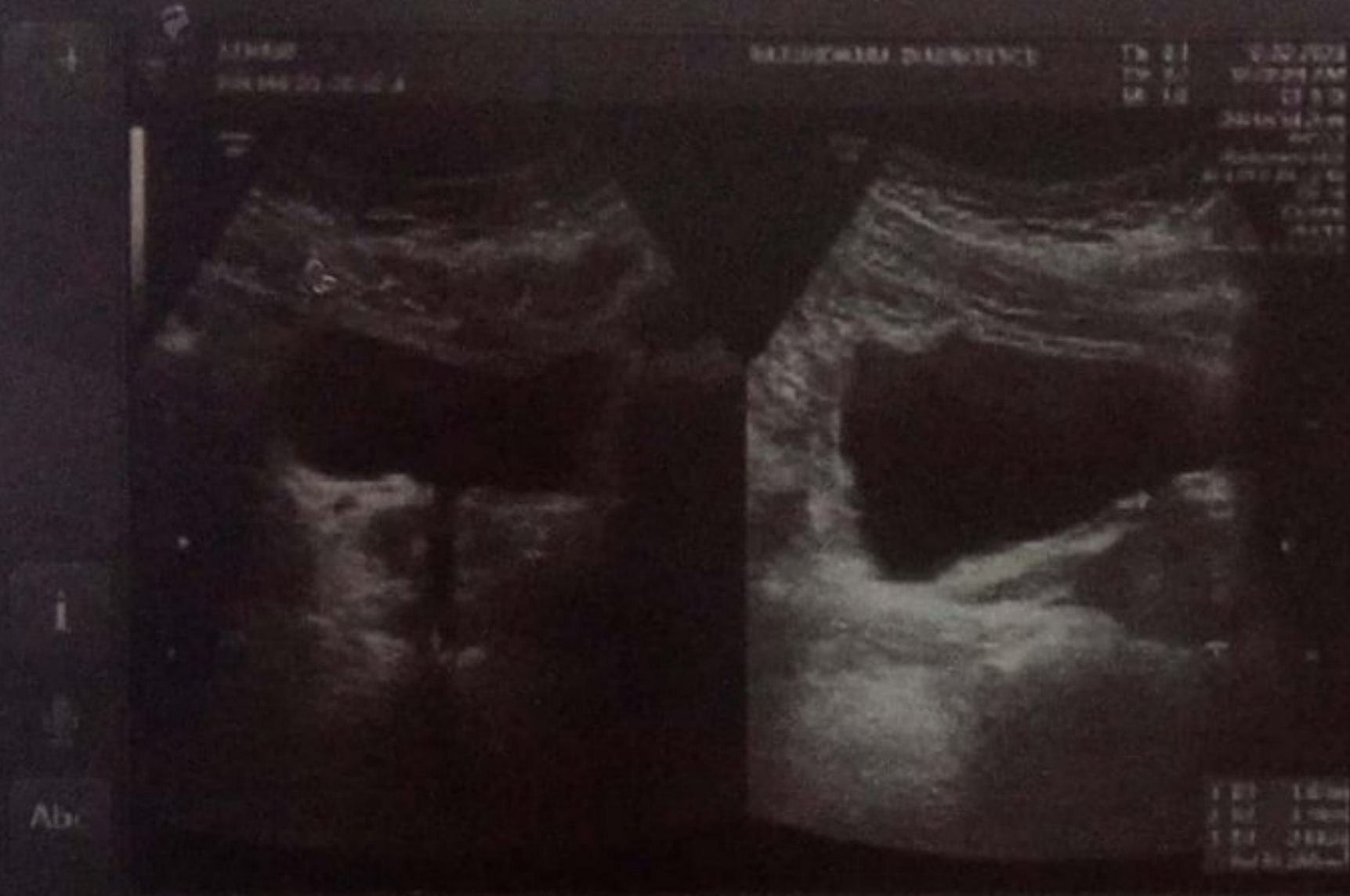Patient Id : 230212-015 Gender/Age : Male / 33 Year  
Reg Date : 12-02-2023

### ULTRASONOGRAPHY OF WHOLE ABDOMEN

- Liver** : Normal in size(12.5cm) with **Increased** echotexture.  
No focal lesions or dilated biliary radicles.  
No IHBD / CBD dilatation. Portal vein is normal.
- Gall bladder** : Contracted
- CBD** : Normal in course and calibre .Lumen echo free.
- Portal vein** : Normal in size and course. Lumen echo free .
- Spleen** : Normal in size(10.1cm ) with normal echotexture. No focal lesions.
- Pancreas** : Head, body, visualized parts of tail are normal. No focal lesions  
or peripancreatic collections are seen.
- Kidneys** : Right kidney: 9 x 4.1 cm Left kidney: 9.8 x 4.4 cm.  
Normal in size, shape and echotexture.Corticomedullary junction made out.  
Renal cortical thickness measuring 21.2 mm on right side and 20mm on left side  
No calculi or hydronephrosis on both sides.
- Urinary bladder** : Well distended. No calculi are seen.No wall thickening seen.
- Prostate** : Normal in size and echotexture.Volume measuring
- Others** : No evidence of ascites. **Appendix not seen- H/O post operative status**  
No evidence of lymph node enlargement. No obvious inflammed bowel seen
- Impression** : **Grade I fatty liver**

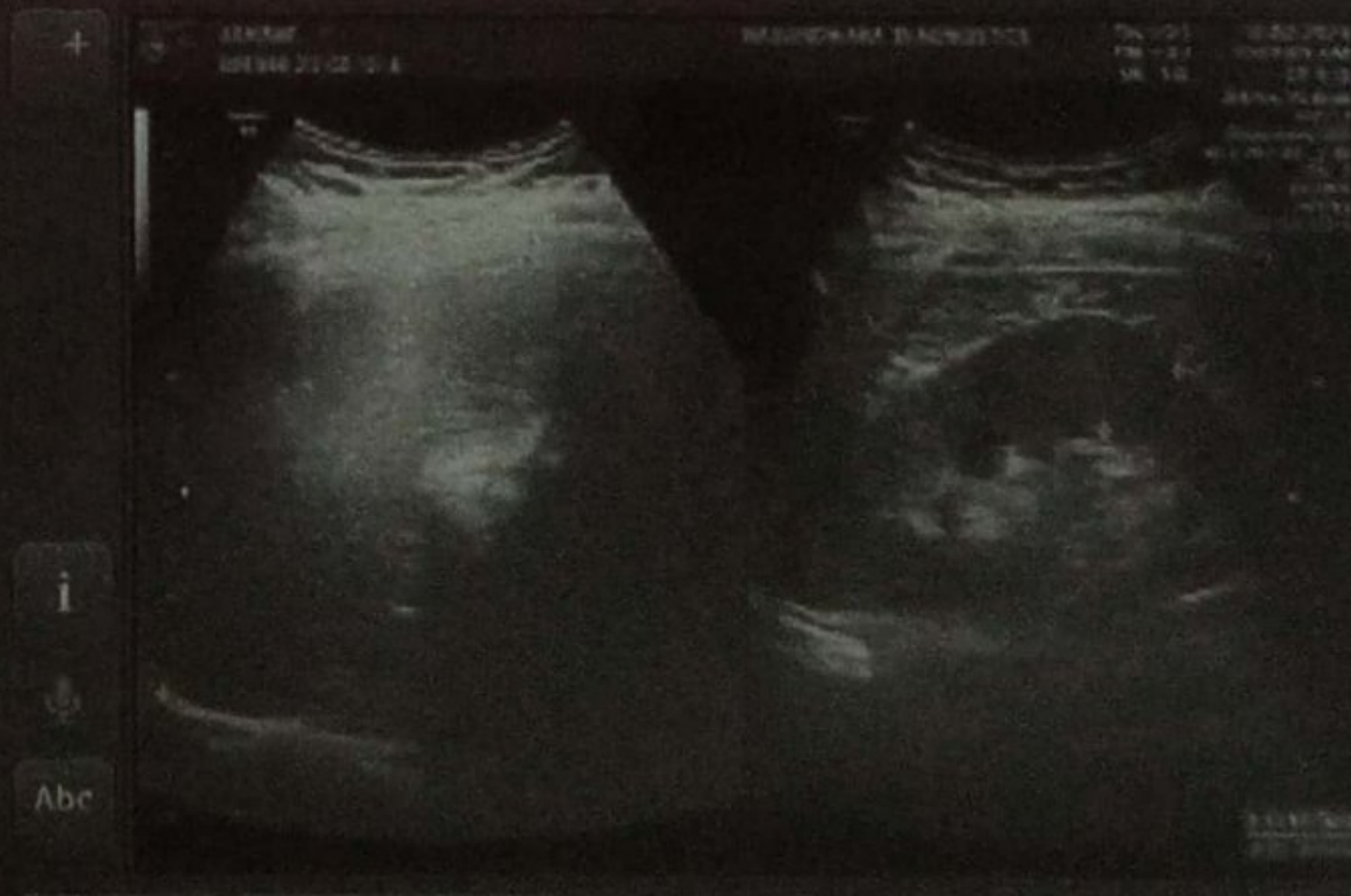
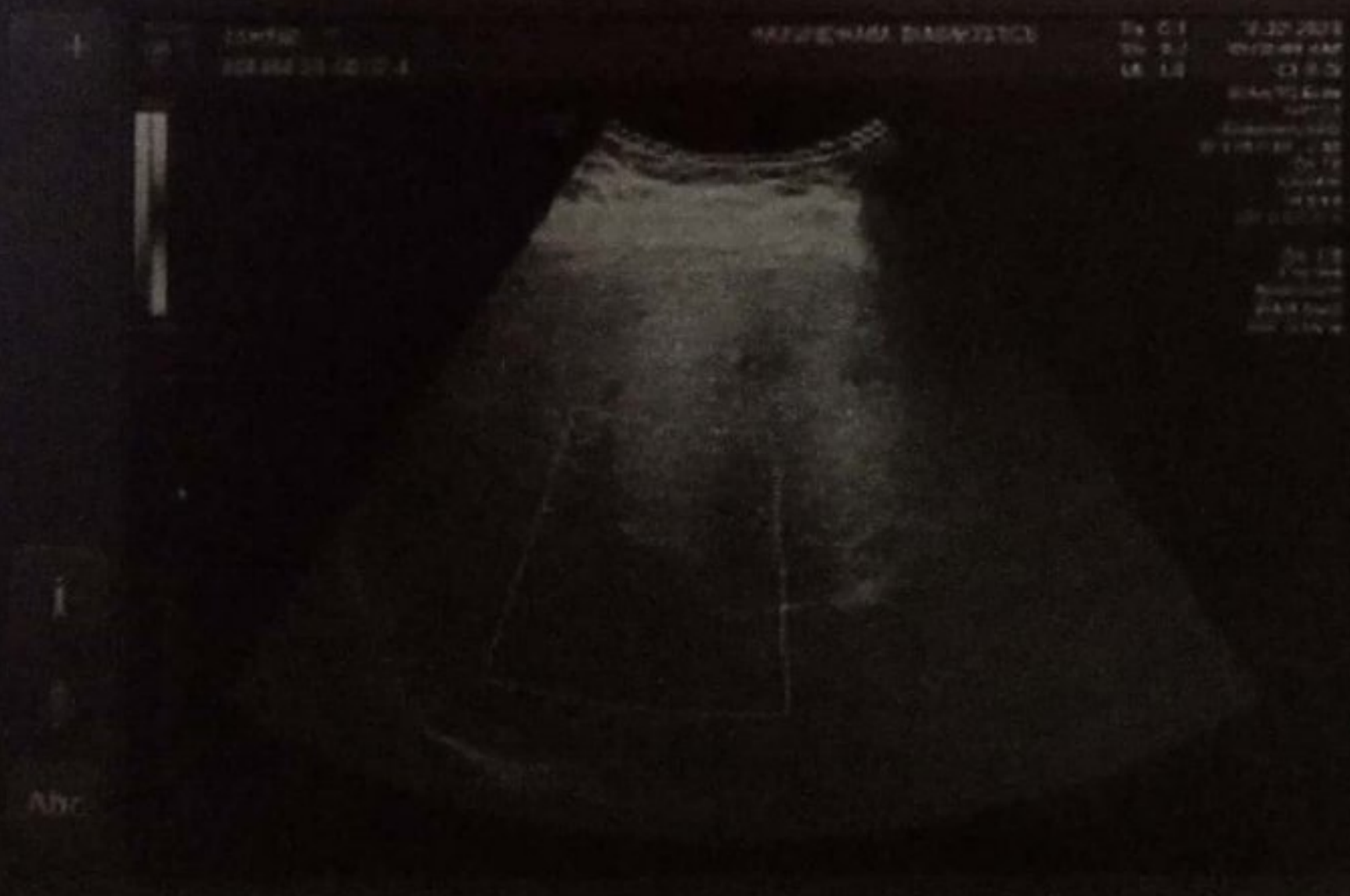For clinical correlation please...

Dr.N.Vasundhara  
MD Radiology  
Consultant in fetal medicine



Reload Full Data 2D

Reload Full Data 2D



Reload Full Data HDF

Reload Full Data 2D

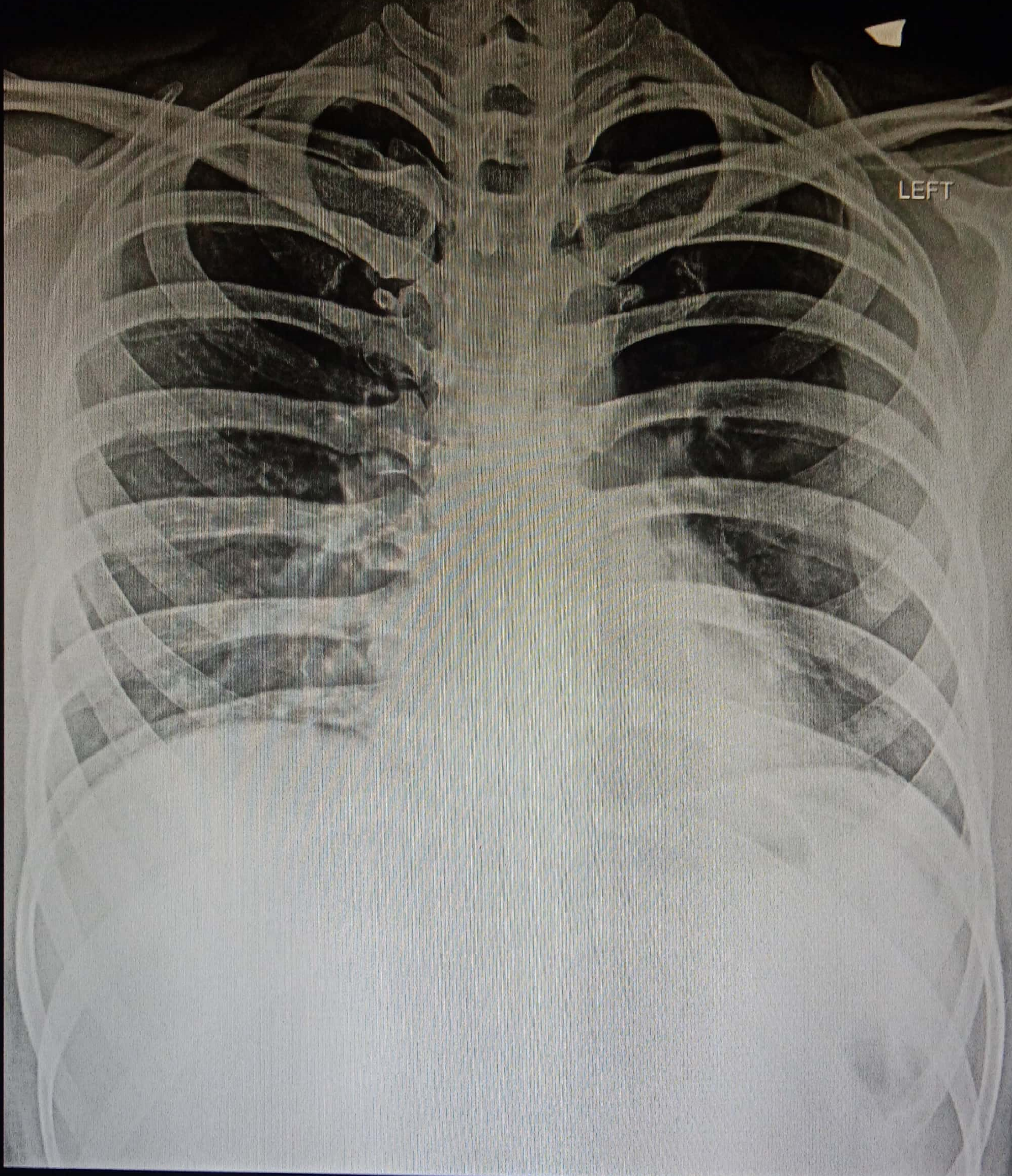
Select All

Deselect All

Prev Frame  
Next Frame  
Prev Frame  
Next Frame

▼

▼



LEFT

MR M ASHRAF 33Y 02 CHEST PA 12/02/2023 11:30 AM MED WHEEL HEALTH

AMRUTHA SAI DIAGNOSTIC CENTRE, OPP. BALAJI KALYANAMANDAPAM, SRINIVASA NAGAR, ANANTAPUR, 8688984900