

SARDA

CENTRE FOR DIABETES & SELF CARE

NAME: MR. DINESH PATIL

SEX : Male

REF. BY : MEDIWHEEL

DATE:12/02/2022

COMPLETE BLOOD COUNT

TEST	RESULT	NORMAL RANGE
WBC COUNT	7200 /cumm	4.0 - 11.0 x 10 ³ /cumm
Haemoglobin:	13.2 g%	13.0 - 18.0 g%
Platelets:	263000 /cumm	1,50,000 - 4,50,000 / cumm
Red Blood Cells:	4.97 /Mill/ul	4.20 - 6.00 Mill/ul
MCV:	80.2 fL	80.0 - 97.0 fL
MCH:	26.5 pg	26.0 - 32.0 pg
MCHC:	33.1 g/dL	31.0 - 36.0 g/dL
HCT:	39.8 %	37.0 - 51.0 %
Differential Count		
Neutrophils:	52 %	40 - 75 %
Lymphocyte:	41 %	20 - 45 %
Monocytes:	03 %	2 - 10 %
Eosinophills:	04 %	1 - 06 %
Basophills:	00 %	0 - 1 %
ESR:	08 mm at 1 Hr.	Male: 0 - 8 mm at 1 Hr. Female: 0 - 20 mm at 1 Hr.

GYCOCYTED HAEMOGLOBIN

TEST	RESULT	NORMAL
HbA1C:	5.5 %	4.7-5.9 %
M.B.G	105.55% mg	70 - 120 mg

INTERPRETATION:

FOR DIABETIC PATIENT

Good Control:	6.0 - 7.0 %
Fair Diabetic Control:	7.0 - 8.0 %
Unsatisfactory control:	8.0 - 10 %
Poor Diabetic Control:	Above 10 %

Dr.S R. SARDA

M.D Reg. No.56462

SARDA CENTER FOR DIABETES & SELF CARE

4, Vyankatnagar, Jalna Road, Aurangabad

Dr.Sampat Sarda
M.D.(Pathology)
Vyankatnagar, Jalna Road, Aurangabad (MH). Ph.: 2333851, 2334858, Mob.: 9823040323

SARDA

CENTRE FOR DIABETES & SELF CARE

NAME: MR. DINESH PATIL


SEX : Male

REF. BY : MEDIWHEEL

DATE:12/02/2022

BLOOD SUGAR EXAMINATION

TEST	RESULT		
Fasting Blood Sugar:	90 mg/dl		
Post Meal Blood Sugar Level:	142 mg/dl		
REFERANCE RANGE :	NON DIABETIC	IGT	DIABETIC
FASTING	≤ 90 MG	90-126 mg %	≥ 126 mg %
POSTMEAL	≤ 140 mg	140-200mg%	≥ 200 mg


Dr. S. R. SARDA
Dr. Sampat Sarda
M.D.(Pathology)
No. 56462
CENTRE FOR DIABETES & SELF CARE
Jalna Road, Aurangabad
Phone No. 2333851, 2334858

SARDA

CENTRE FOR DIABETES & SELF CARE

NAME: MR. DINESH PATIL

SEX : Male

REF. BY : MEDIWHEEL

DATE:12/02/2022

BLOOD PROFILE

TEST	RESULT	NORMAL
BLOOD UREA N2	16 mg%	5-25 mg %
CREATININE	1.2mg%	0.6-1.4 mg %
BILIRUBIN TOTAL	0.59mg%	0.2-1.0 mg
DIRECT	0.15	0.0-0.3
INDIRECT	0.44	0.3-0.7
S.G.O.T	22 IU/L	15-40 IU/L
S.G.P.T	26 IU/L	15-40 IU/L
ALK PHOSPHATASE	112 IU/L	70-306 IUL
S.PROTEIN TOTAL	7.3gm%	6.0-8.0 gm%
ALBUMIN	4.0gm%	3.2-4.4 gm%
GLOBULINS	3.3gm%	2.3-3.5 gm%
ALB/GLO RATIO	1.2	
G.G.T.P	25	upto50IU
SR.URIC ACID	5.2	3.5-7.0 mg %\$sruric-

Dr.S R. SARDA

M.D Reg. No.56462

CENTRE FOR DIABETES & SELF CARE

4, Vyanktesh Nagar, Jalna Road, Aurangabad

Ph. 2333851, 2334858

Dr.Sampat Sarda

M.D.(Pathology)

SARDA

CENTRE FOR DIABETES & SELF CARE

NAME: MR. DINESH PATIL

SEX : Male

REF. BY : MEDIWHEEL

DATE:12/02/2022

LIPID PROFILE

Serum Cholesterol :	167 mg/dl	130 - 250 mg/dl
HDL Cholesterol:	38 mg/dl	30 - 95 mg/dl
Serum Triglyceride:	146 mg/dl	up to 165 mg/dl
LDL Cholesterol:	99.8 mg/dl	up to 165 mg/dl
VLDL Cholesterol:	29.2 mg/dl	up to 40 mg/dl
LDL / HDL Cholesterol Ratio:	2.63	Low risk : 0.5 - 3.0 Moderate risk: 3.0 - 6.0 High risk: > 6.0
CHOL./HDL Cholesterol Ratio:	4.39	Low risk : 3.3 - 4.4 Average risk: 4.4 - 7.1 Moderate risk: 7.0 - 11.0 High risk: > 11

Dr.S R. SARDA
Dr.Sampat Sarda
M.D.(Pathology)
Reg. No.59462
CENTRE FOR DIABETES & SELF CARE
Jalna Road, Aurangabad
Phone No.2333851, 2334858

SARDA

CENTRE FOR DIABETES & SELF CARE

NAME: MR. DINESH PATIL

SEX : Male

REF. BY : MEDIWHEEL

DATE:12/02/2022

Urine Routine Examination

Physical Examination


Colour:	Pale Yellow
Appearance:	Clear
Reaction:	Acidic
Deposit	Absent

Chemical Examination:

Specific Gravity	1.010
Albumin	Absent
Sugar:	Absent
Acetone:	----
Bile Salts	----
Bile Pigment:	----

Microscopic Examination

RBC :	Absent
Pus Cells:	OCASSIONAL/HPF
Epihtelial cells:	Absent
Crystals:	Absent
Casts:	Absent


Dr. Sampat Sarda No. 56462
M.D. (Pathology)
SARDA CENTRE FOR DIABETES & SELF CARE
4, Vyanktesh Nagar, Jalna Road, Aurangabad
Phone No. 2333851, 2334858

SARDA

CENTRE FOR DIABETES & SELF CARE

NAME: MR. DINESH PATIL


SEX : Male

REF. BY : MEDIWHEEL

DATE:12/02/2022

THYROID FUCTION TEST

TEST	RESULT	NORMAL RANGE
Total T 3 :	118.2 ng/ml	60-181 ng/ml
Total T 4 :	9.8 ug/dl	4.87 - 11.72 ug/dl
TSH Ultrasensitive :	2.88 uIU/ml	0.35 -5.5uIU/ml

 Dr.S.P. SARDA
M.D. Reg. No.56462
SARDA CENTRE FOR DIABETES & SELF CARE
4, Vyanktesh Nagar, Jalna Road, Aurangabad
M.D.(Pathology)
PHONE NO. 2333851, 2334858

Mr. Dinesh Patil

12/02/22

30 yrs / Male mediwheel

Ophthalmic Exam Report.

	(RE)	(LE)
<u>Vision</u>	6/6 - 1.25 D sph	6/6 - 0.75 D sph / -0.5 D cyl 130°
<u>Antseg</u>	MAD	MAD.
<u>Lens</u>	clear	clear
<u>Fundus</u>	Disc - WM C1003 CRT	Disc - WM C1003 CRT
<u>Color vision</u>	Normal	Normal.

Imp:- (BE) myopia ++

Rest within normal limits

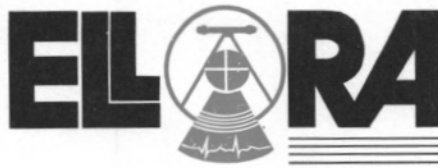

Dr. Ajay Loniya

DR. AJAY LONIYA
M.B.P.S., D.O., (B.C.M.) D.N.B.F.C.P.S.
REG. NO. 86436

TIRUPATI NETRALAYA & DENTAL CLINIC
AURANGABAD

DIGITAL X-RAY
INTERVENTIONAL RADIOLOGY
3D/4D SONOGRAPHY & COLOR DOPPLER
2-D ECHOCARDIOGRAPHY
PERIPHERAL COLOR DOPPLER
HI-SPEED HELICAL C.T. SCAN
C.T. ANGIOGRAPHY
PATHOLOGY LAB. SERVICES



DIAGNOSTIC CENTRE
X-RAY, IMAGING & PATHOLOGY

1, VYANKATESH NAGAR, OPP. SFS
HIGH SCHOOL, JALNA ROAD,
AURANGABAD - 431005
☎ : 0240-2353182, 2325282, 8446100111

Dinesh Patil

12-02-2022

Ref. by:

CHEST PA VIEW

Trachea central.

Apices are clear.

Both lung fields appeared well pneuamtised and appeared normal.

Both cp angles are clear.

Cardiac silhoutte appeared normal.

IMPRESSION :

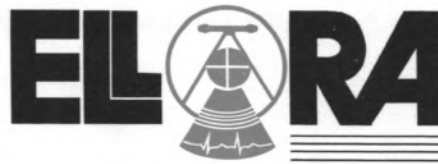NORMAL CHEST.



DR. P. A. BARJATYA
M.B.B.S., M.D.
9823344449

DR. G. S. LAHOTI
M.B.B.S., D.M.R.D.
9850171587

DIGITAL X-RAY
INTERVENTIONAL RADIOLOGY
3D/4D SONOGRAPHY & COLOR DOPPLER
2-D ECHOCARDIOGRAPHY
PERIPHERAL COLOR DOPPLER
HI-SPEED HELICAL C.T. SCAN
C.T. ANGIOGRAPHY
PATHOLOGY LAB. SERVICES



DIAGNOSTIC CENTRE
X-RAY, IMAGING & PATHOLOGY

1, VYANKATESH NAGAR, OPP. SFS
HIGH SCHOOL, JALNA ROAD,
AURANGABAD - 431005
☎ : 0240-2353182, 2325282, 8446100111

12-02-2022

Mr. DINESH PATIL
39 YRS

USG ABDOMEN

Liver is normal in size,shape and echotexture.
Intrahepatic biliary radicles and portovenous echocomplex appeared normal.
No e/o any solid,cystic,diffuse parenchymal pathology seen.
Normal cbd and portal vein.

Gallbladder is well distended and appeared normal,no e/o any gallbladder calculus. Normal gb wall thickness.
Pancreas is normal in size,shape and echotexture.
Normal peripancreatic fat planes.
Spleen is normal in size,shape and echotexture.
Both kidneys are normal in size,shape and echotexture.No e/o any calculus seen ,No e/o hydropnephrosis.

Urinary bladder is well distended and appeared normal, no e/o any intravesical pathology. No e/o ascitis / paraaortic adenopathy.
Prostate measures 39 x 31 x 28mm with approximate weight of 17CC.

IMPRESSION

**NORMAL LIVER,SPLEEN,PANCREAS,GALLBLADDER,BOTH KIDNEYS,
URINARY BLADDER , PROSTATE.**

**Note : SCANNING DONE IN COVID 19 PANDEMIC PERIOD , PATIENT DID NOT
GIVE ANY OBVIOUS HISTORY PERTAINING TO COVID 19 INFECTION.**



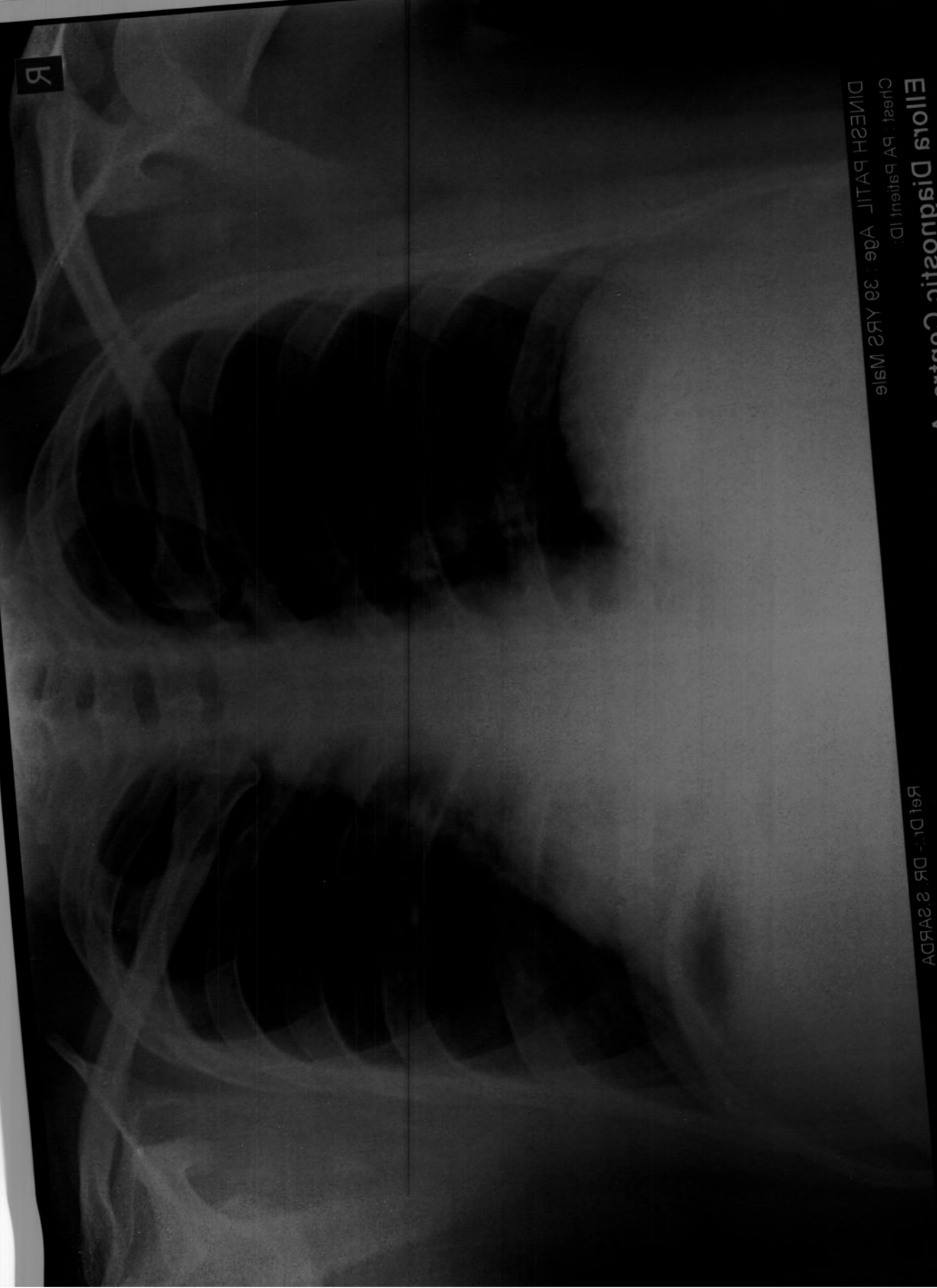DR. P. A. BARJATYA
M.B.B.S., M.D.
9823344449

DR. G. S. LAHOTI
M.B.B.S., D.M.R.D.
9850171587

Ellora Diagnostic Centre, Aurangabad (0540) 3323185
Chief: PA Patient ID:
DINESH PATIL Age: 39 YRS Male

Date: 15-05-2025 AM 10:30:34
Ref Dr: DR. SARDAR

R



Ellora Diagnostic Centre, Aurangabad (0540) 5323185

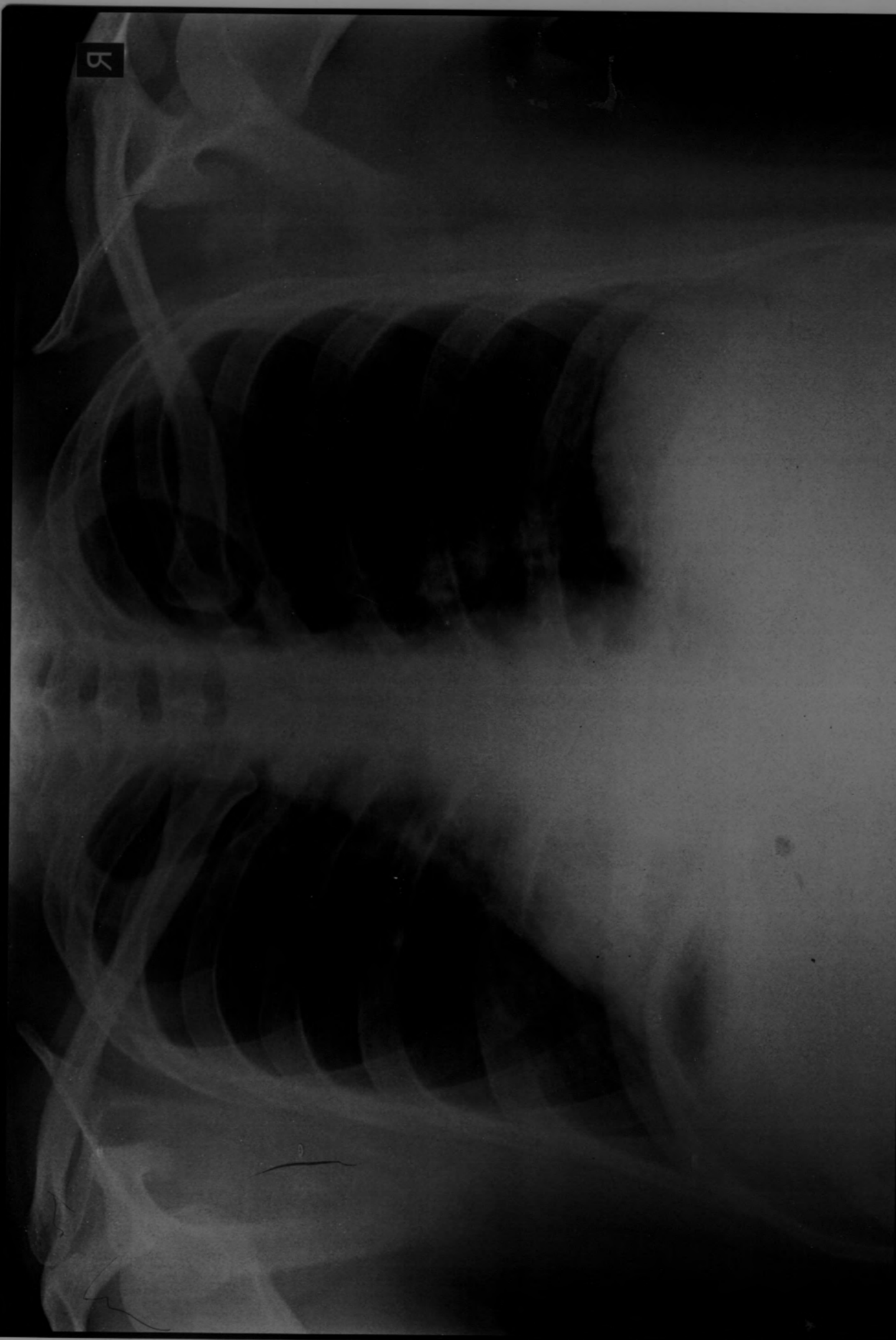
Chief : PA Patient ID :

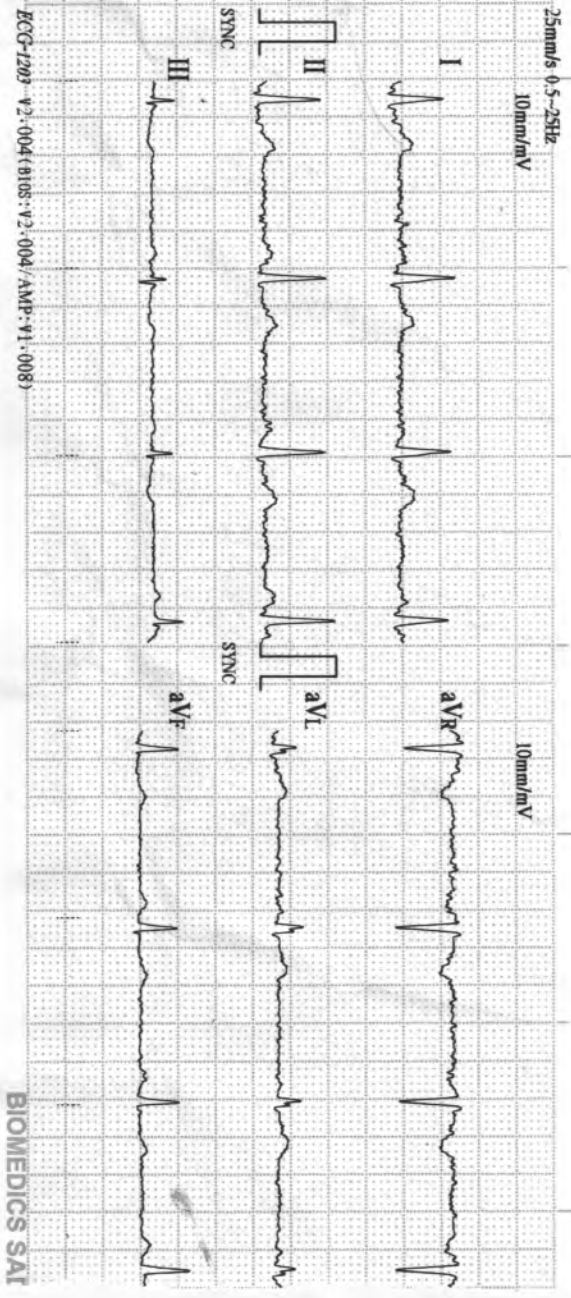
DINESH PATIL Age : 38 YRS Male

Ref. Dr. : DR. S. SARDAR

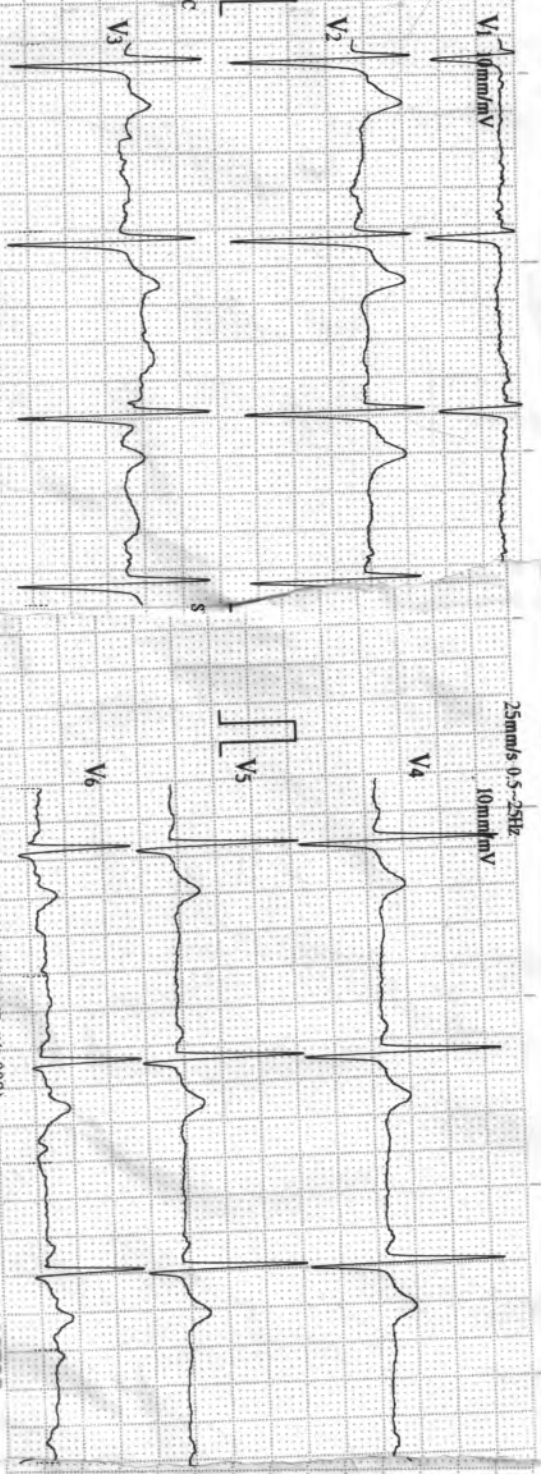
Date : 15-05-2025 AM 10:30:34

R





BIOMEDICS SAT



ASHV PETH PUNE-30 CELL-9822198798

BIOMEDICS SAT PETH PUNE-30 CELL-9822198798

02/12/2022 08:48
 ID : 5234
 Name:
 Sex:
 Age:

HR : 61 bpm
 R-R : 976 ms
 P-R : 222 ms
 QRS : 115 ms
 QT/QTc : 364/368 ms
 P/QRST : 68/41/43 ms
 RV5/SV1 : 1.660/0.940 mV
 RV5-SV1 : 2.600 mV

dim
 Machine Interpretation Only

Confirm with Physician
 Physician:

SARDA

CENTRE FOR DIABETES & SELF CARE

4, Vyankatesh Nagar, Jalna Road, Aurangabad, Ph. : (0240) 2333851, 2334858.

Name : MR. Dimesh Podil Age : 39y1m

CLINICAL SUMMARY :

Weight : _____ Height (Cms) : _____ Blood Pressure : _____

ECG FINDINGS :

Rate : 61/min ORS. Complex : N

Rhythm : N ST Segment : N

Mechanism : N T. Wave : N

Axis : N QT Interval : N

P. Wave : N PR Interval : N

Recommendation : WM

Dr. A. S. SARDA

M.D. Reg. No. 73570

CARDIA CENTER FOR DIABETES & SELF CARE
Dr. Dimesh Podil, Jalna Road, Aurangabad
Phone No. 2333851, 2334858

Date : 12.02.22