




9992292712


 भारतीय प्रिंस्ट पहचान प्राधिकरण
Unique Identification Authority of India


पता:
आत्मज: ओम प्रकाश, 1965/08,
चिंताला मोहल्ला, महम, रोहतक,
महम, रोहतक,
हरियाणा - 124112


Address:
S/O: Om Parkash, 1965/08,
Chintala Mohalla, Meham,
Rohtak, Maham, Rohtak,
Haryana - 124112

3534 6731 9071

1947  help@uidai.gov.in 

 भारत सरकार
Government of India

 लोकेश कुमार
Lokesh Kumar
जन्म तिथि/DOB: 29/12/1987
पुरुष / MALE



3534 6731 9071

मेरा आधार, मेरी पहचान

Handwritten notes:
Lokesh
29/12/1987
Fah. Harkh
Check up.



Aravali Hospital

332, Ambamata Scheme, Udaipur - 313 004
T: 91 294 2430222, 2431222
email : aravalihospital@yahoo.com



गुणवत्ता पूर्ण चिकित्सा सेवाओं के लिये
भारत सरकार की
क्वालिटी काउंसिल ऑफ इण्डिया (QCI-NABH)
द्वारा प्रमाणित

Date : 23/03/2024			
Patient's Name :	MR. LOKESH	Age: yrs	Sex: Male
Ref. By :	C/O BOB		

ULTRA SONOGRAPHY REPORT - UPPER AND LOWER ABDOMEN

Liver	Liver is normal in size, shape, position & contour with normal homogenous echopattern. No evidence of any focal lesion is seen. IHBR are not dilated. Portal vein measures 11 mm. IVC is normal.
Gall bladder	GB is normal in size & shape. Its wall thickness is normal. No evidence of any calculi is seen. No pericholecystic fluid collection is seen.
Pancreas	Pancreas is normal in size, shape, position & contour with normal homogenous echo pattern. Pancreatic duct is not dilated.
Spleen	Spleen is normal in size, shape, position and contour with normal homogenous echo pattern. Splenic vein is not dilated.
Kidneys	Both kidneys are normal in size, shape, position & contour with well differentiated corticomedullary junction and normal cortical thickness. Pelvicalyceal system is not dilated. No evidence of any calculi is seen. Visualized portion of ureters appears normal. Right kidney measures 95x36 mm. Left kidney measures 97x40 mm
Urinary Bladder	Urinary bladder is well distended with urine & is normal in size, shape & contour with normal & smooth walls.
Prostate	Prostate is normal in size, shape, position & contour with normal homogenous echo pattern. It reveals normal & smooth capsule. Seminal vesicles are normal.

IMPRESSION NORMAL STUDY

Dr. SURESH CHANDRA BASER

MBBS,MD
Consultant Radiologist
(RMC-7219)

Dr. ANAND GUPTA

MBBS,DMRE
Consultant Radiologist
(RMC-17548)

Note: The foetal gender has not been detected nor disclosed to the patient.
This report is not valid for medico legal purpose.
Every report needs to be correlated and interpreted clinically.
In case of any query, investigation may be repeated.



Helpline : 9352 108 108

www.aravalihospital.in

R

MR. LOKESH KUMAR 36YRS BOD M CHEST PA 23-Mar-24
ARAVALI HOSPITAL, 332 AMBAMATA SCHEME, UDAIPUR

BOB

LOKESH KUMAR 36YR

Male

3/23/2024 9:40:36 AM

Rate 60 . Age not entered, assumed to be 50 years old for purpose of ECG interpretation
 PR 143 . Sinus rhythm.....normal P axis, V-rate 50-99
 QRS 87 . Abnormal R-wave progression, early transition.....QRS area>0 in V2
 QT 377 . Baseline wander in lead(s) V2,V4
 QTc 377

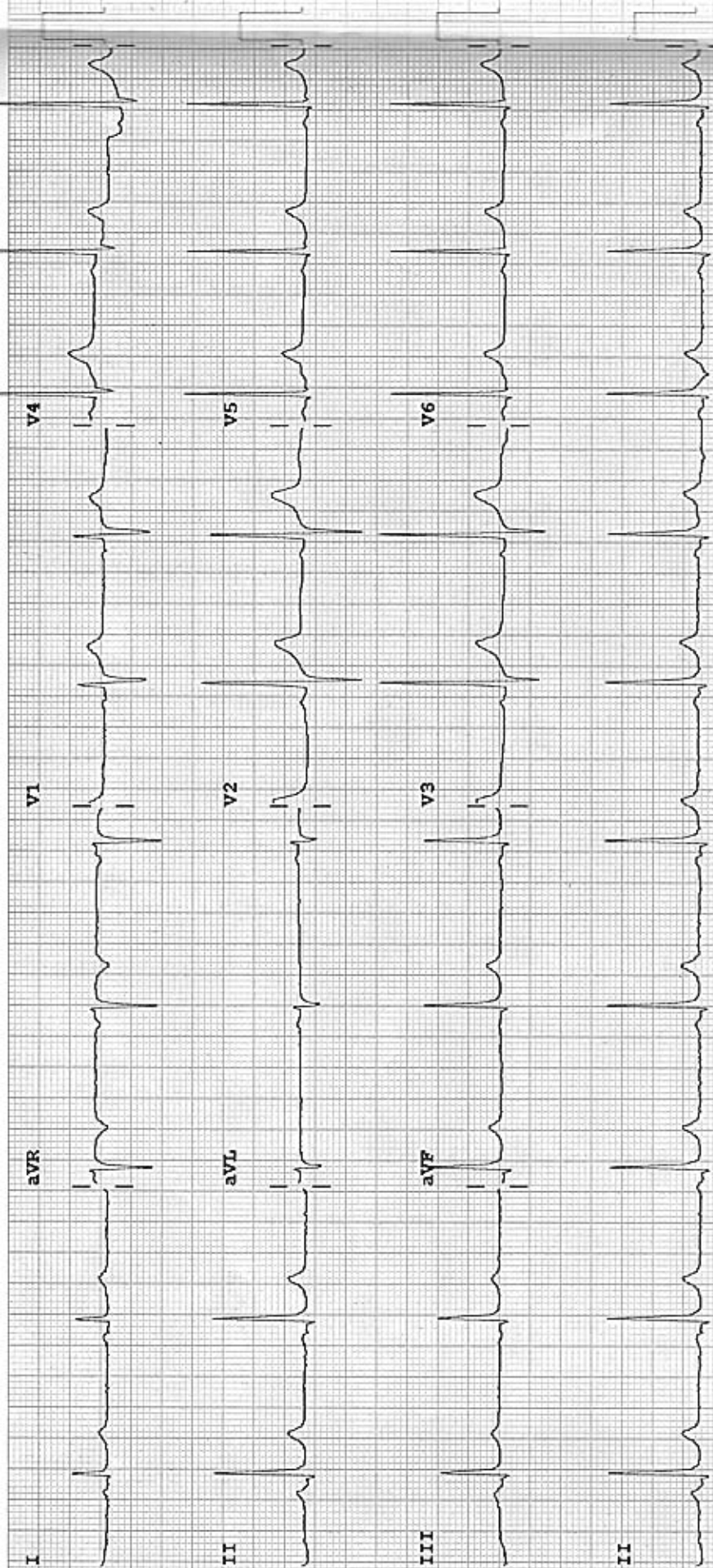
--AXIS--

P 22
 QRS 70
 T 60

- OTHERWISE NORMAL ECG -

12 Lead; Standard Placement

Unconfirmed Diagnosis



Device:

Speed: 25 mm/sec

Limb: 10 mm/mV

Chest: 10.0 mm/mV

F 60~ 0.15-100 Hz

100B CL

P?

ARAVALI HOSPITAL

332, AMBAMATA SCHEME, UDAIPUR 313004

Report



566 / LOKESH KUMAR / 36 Yrs / M / 0 Kgs / 0 Kg - Date: 23-Mar-2024

Non-Cardiac Pain Angina / Non-Hypercholesterolemia / Non-Diabetic / Negative Estrogen / Non-Athlete

Stage	Time	Duration	Speed (mph)	Elevation	METs	Rate	% THR	BP	RPP	PVC	Comments
Supine	03:39	3:39	00.0	00.0	01.0	081	44 %	130/80	105	00	
Standing	04:25	0:46	00.0	00.0	01.0	079	43 %	130/80	102	00	
HV	04:59	0:34	00.0	00.0	01.0	102	55 %	130/80	132	00	
ExStart	05:12	0:13	00.0	00.0	01.0	109	59 %	130/80	141	00	
BRUCE Stage 1	08:12	3:00	01.7	10.0	04.7	128	70 %	130/80	166	00	
BRUCE Stage 2	11:12	3:00	02.5	12.0	07.1	153	83 %	140/85	214	00	
BRUCE Stage 3	14:12	3:00	03.4	14.0	10.2	191	104 %	150/90	286	00	
PeakEx	14:20	0:08	04.2	16.0	10.4	192	104 %	150/90	288	00	
Recovery	15:20	1:00	00.0	00.0	04.3	156	85 %	150/90	233	00	
Recovery	16:20	2:00	00.0	00.0	01.0	127	69 %	150/90	190	00	
Recovery	17:20	3:00	00.0	00.0	01.0	123	67 %	150/90	184	00	
Recovery	18:20	4:00	00.0	00.0	01.0	122	66 %	140/80	170	00	
Recovery	19:20	5:00	00.0	00.0	01.0	120	65 %	140/80	168	00	
Recovery	19:37	5:17	00.0	00.0	01.0	121	66 %	130/80	157	00	

FINDINGS :

- Exercise Time : 09:08
- Max HR Attained : 192 bpm 104% of Target 184
- Max BP Attained : 150/90
- Max WorkLoad Attained : 10.4 Good response to induced stress
- Test Objective : RULED OUT IHD
- History : None
- Test End Reasons : Test Complete

REPORT :


Stress test is Negative for exercise induced ischemia.



BRUCE:Supine(3:39)

ARAVALI HOSPITAL

566 / LOKESH KUMAR / 36 Yrs / M / 0 Cms / 0 Kg / HR : 81






566 / LOKESH KUMAR / 36 Yrs / M / 0 Cms / 0 Kg / HR : 79

Date: 23-Mar-2024 02:39:47 PM

METS: 1.0/79 bpm 43% of THR BP: 130/80 mmHg

ExTime: 00:00 0.0 mph, 0.0%
25 mm/Sec. 1.0 Cm/mV

4X 80 mS Post J



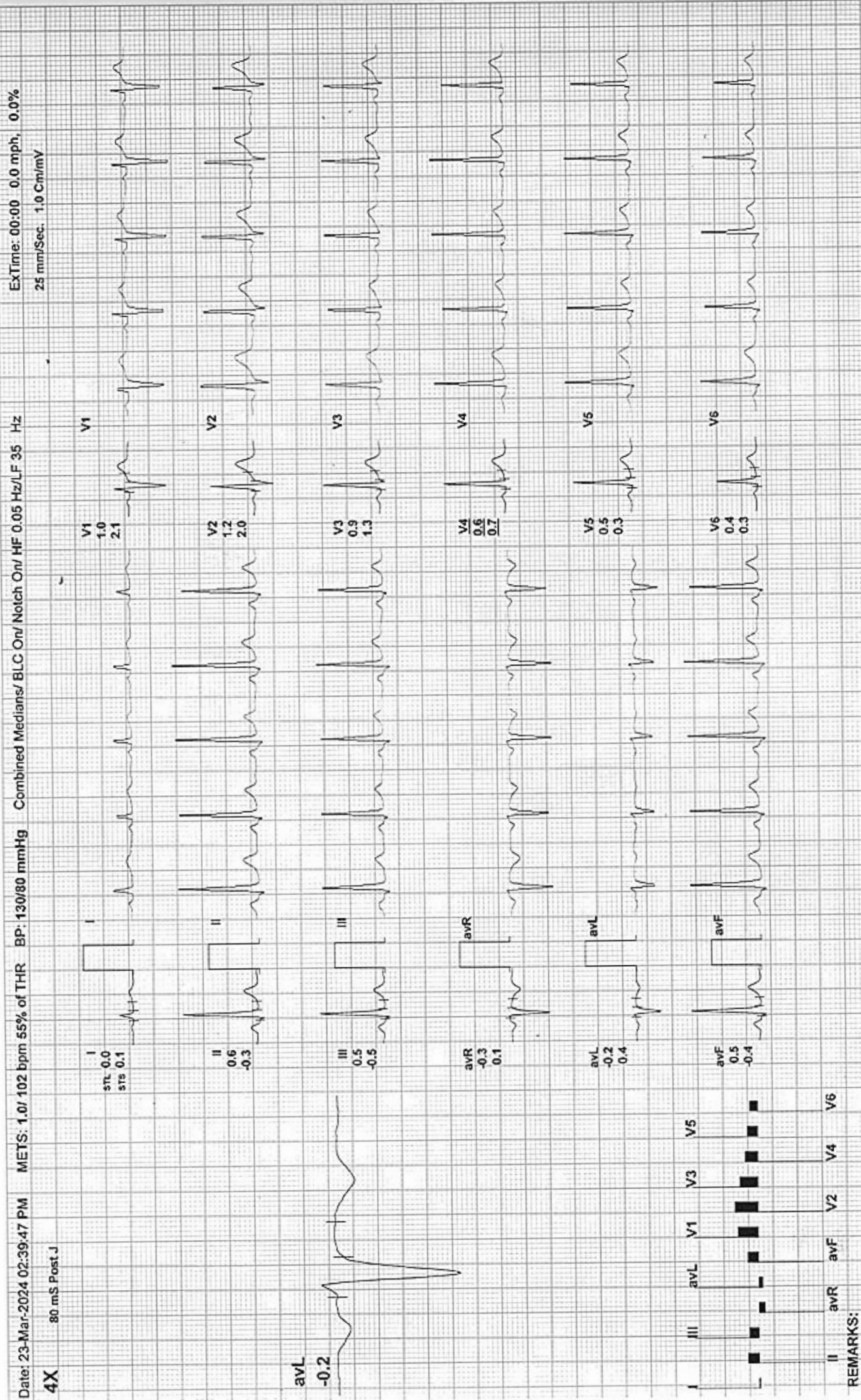
REMARKS:



BRUCE:HV(0:34)

ARAVALI HOSPITAL

566 / LOKESH KUMAR / 36 Yrs / M / 0 Cms / 0 Kg / HR : 102





ExStart

RAVALI HOSPITAL

66 / LOKESH KUMAR / 36 Yrs / M / 0 Cms / 0 Kg / HR : 109

ExTime: 00:00 0.0 mph, 0.0%

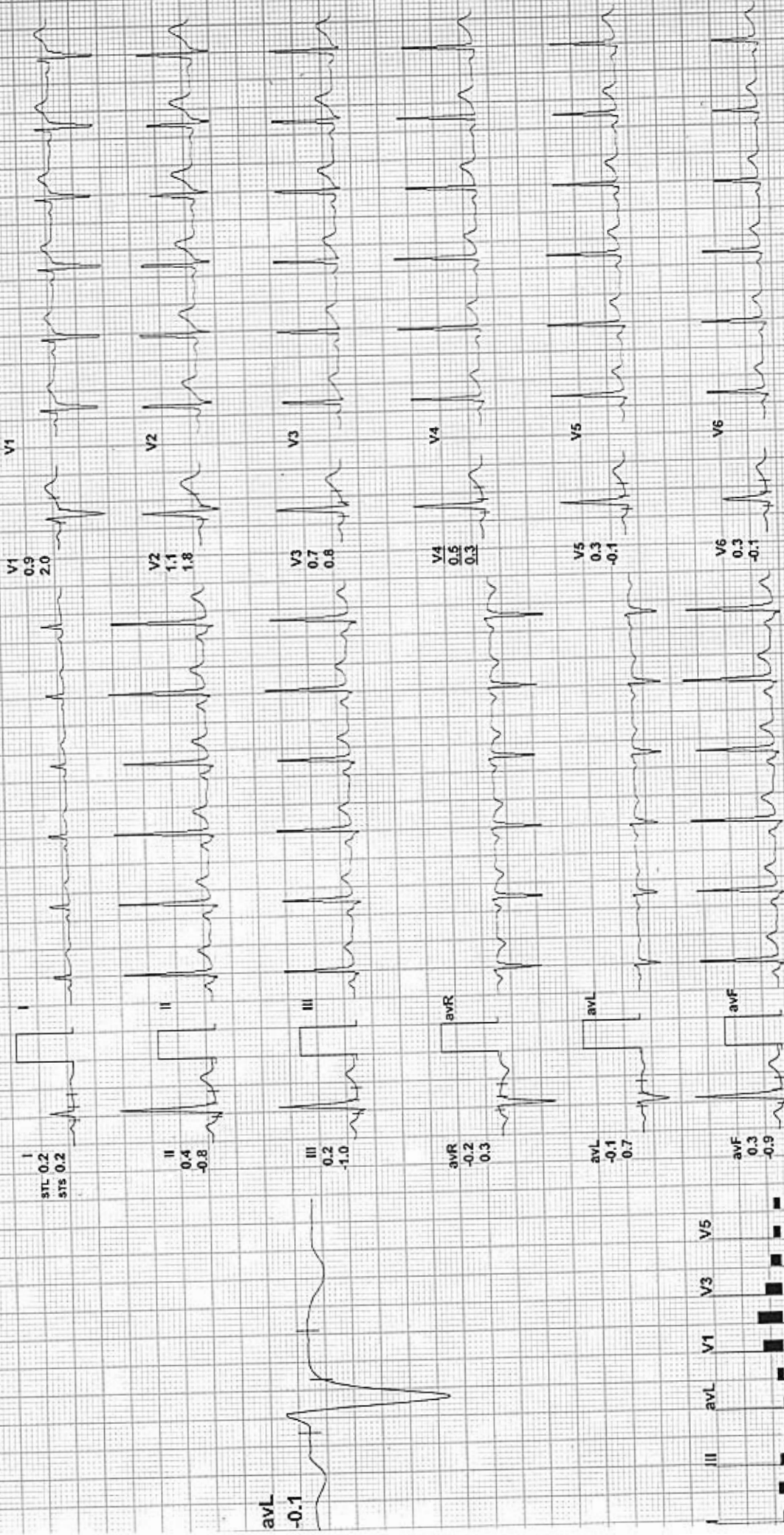
25 mm/Sec. 1.0 Cm/mV

Combined Medians/ BLC On/ Notch On/ HF 0.05 Hz/LF 35 Hz

METS: 1.0/ 109 bpm 59% of THR BP: 130/80 mmHg

Date: 23-Mar-2024 02:39:47 PM

IX 80 mS Post J




REMARKS:



BRUCE: Stage 1 (3:00)

ARAVALI HOSPITAL

566 / LOKESH KUMAR / 36 Yrs / M / 0 Cms / 0 Kg / HR : 128





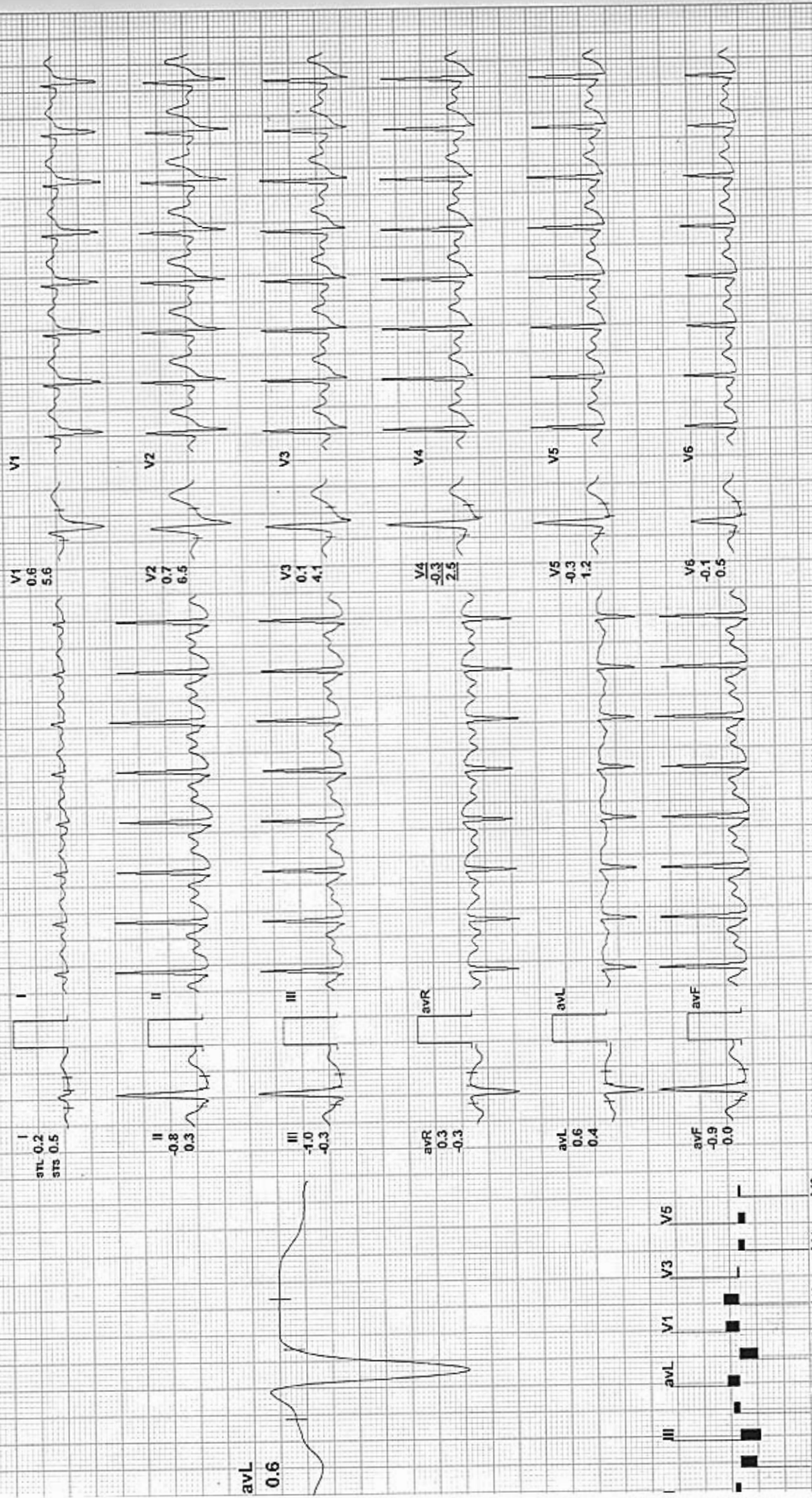
BRUCE: Stage 2(3:00)

RAVALI HOSPITAL

66 / LOKESH KUMAR / 36 Yrs / M / 0 Cms / 0 Kg / HR : 153

date: 23-Mar-2024 02:39:47 PM METS: 7.1/ 153 bpm 83% of THR BP: 140/85 mmHg Combined Medians/ BLC On/ Notch On/ HF 0.05 Hz/LF 35 Hz ExTime: 06:00 2.5 mph, 12.0%
25 mm/Sec. 1.0 Cm/mV

60 mS Post J



REMARKS:



566 / LOKESH KUMAR / 36 Yrs / M / 0 Cms / 0 Kg / HR : 191

Date: 23-Mar-2024 02:39:47 PM

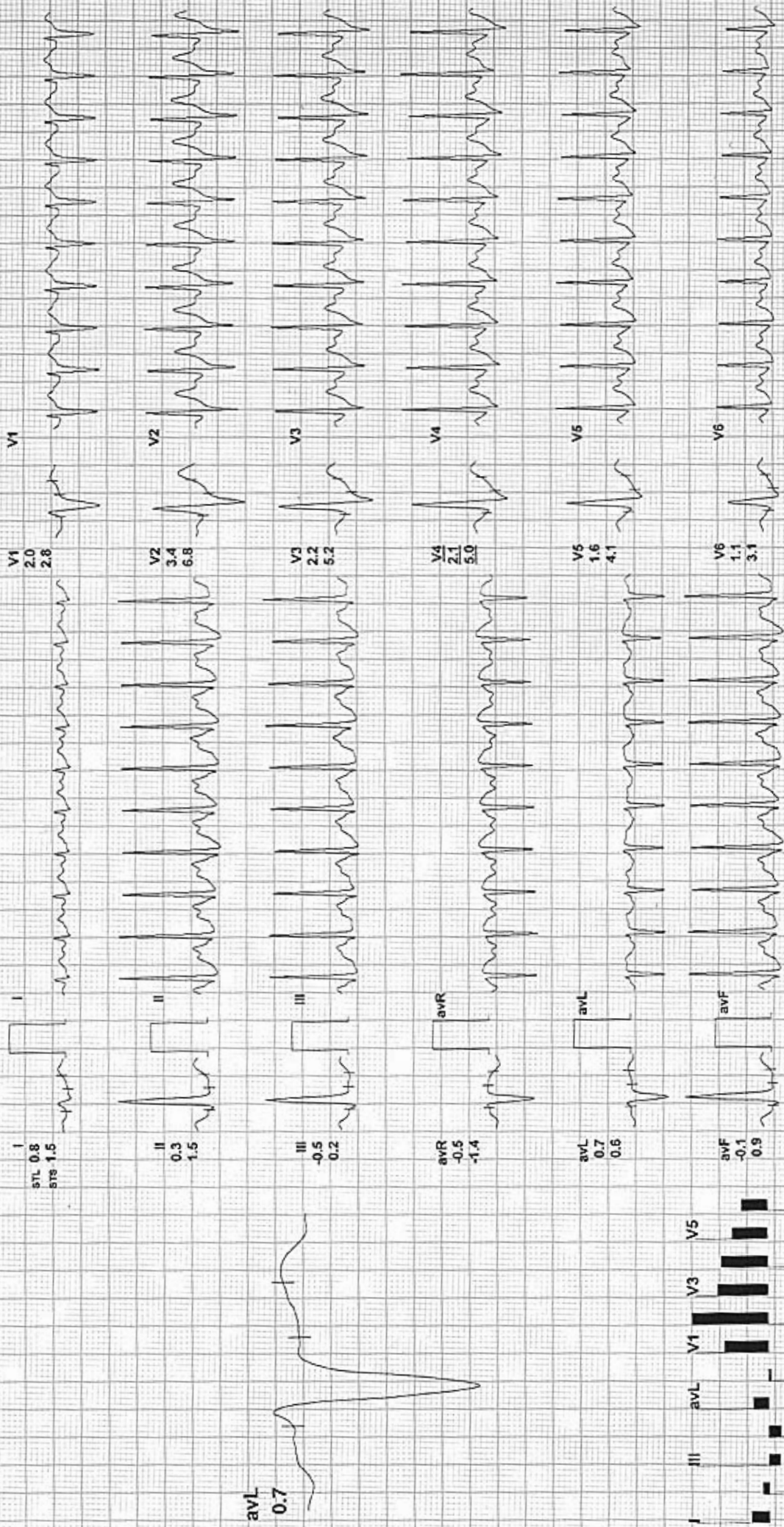
METS: 10.2/191 bpm 104% of THR

BP: 160/90 mmHg


Combined Medians/ BLC On/ Notch On/ HF 0.05 Hz/LF 35 Hz

ExTime: 09:00 3.4 mph, 14.0%
25 mm/Sec. 1.0 Cm/mV

4X 60 mS Post J



REMARKS:





Recovery(1:00)

ARAVALI HOSPITAL

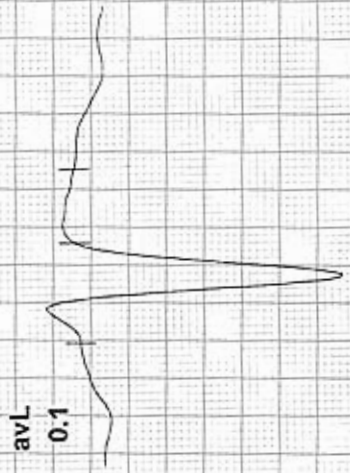
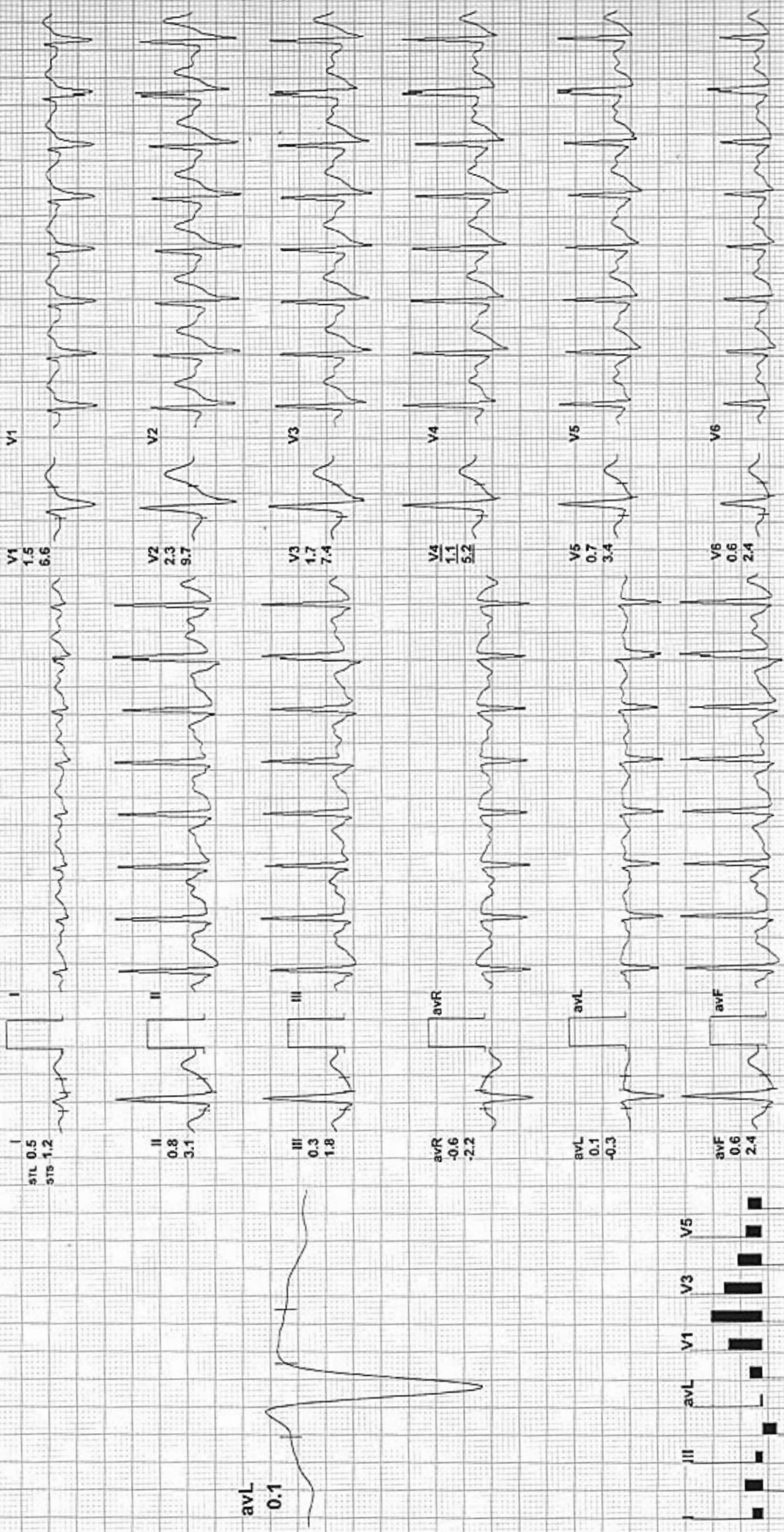
566 / LOKESH KUMAR / 36 Yrs / M / 0 Cms / 0 Kg / HR : 156

Date: 23-Mar-2024 02:39:47 PM

METS: 4.3/ 156 bpm 85% of THR BP: 160/90 mmHg Combined Medians/ BLC On/ Notch On/ HF 0.05 Hz/LF 35 Hz

ExTime: 09:08 0.0 mph, 0.0%
25 mm/Sec. 1.0 Cm/mV

4X 60 mS Post J




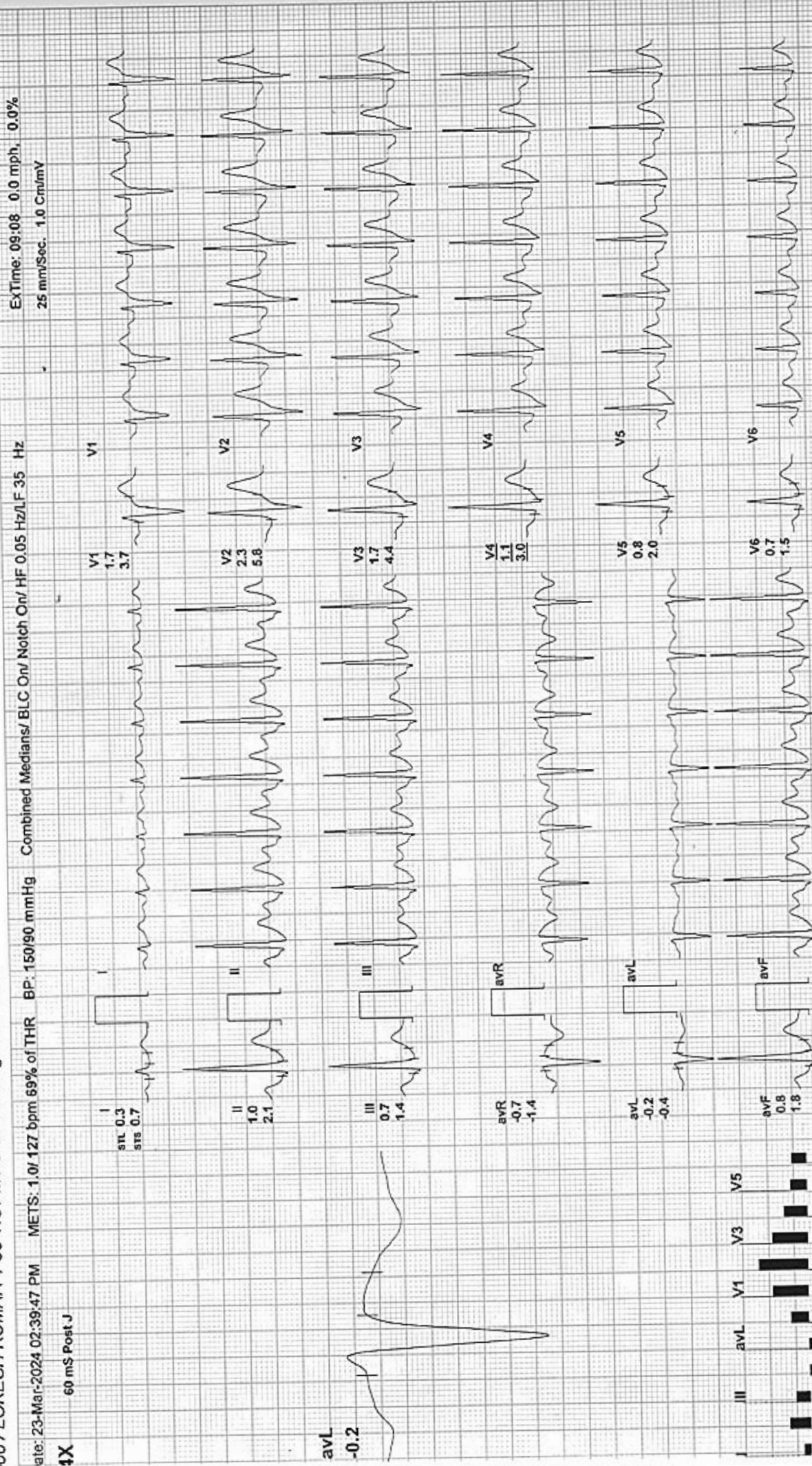
REMARKS:



Recovery(2:00)

RAVALI HOSPITAL

66 / LOKESH KUMAR / 36 Yrs / M / 0 Cms / 0 Kg / HR : 127



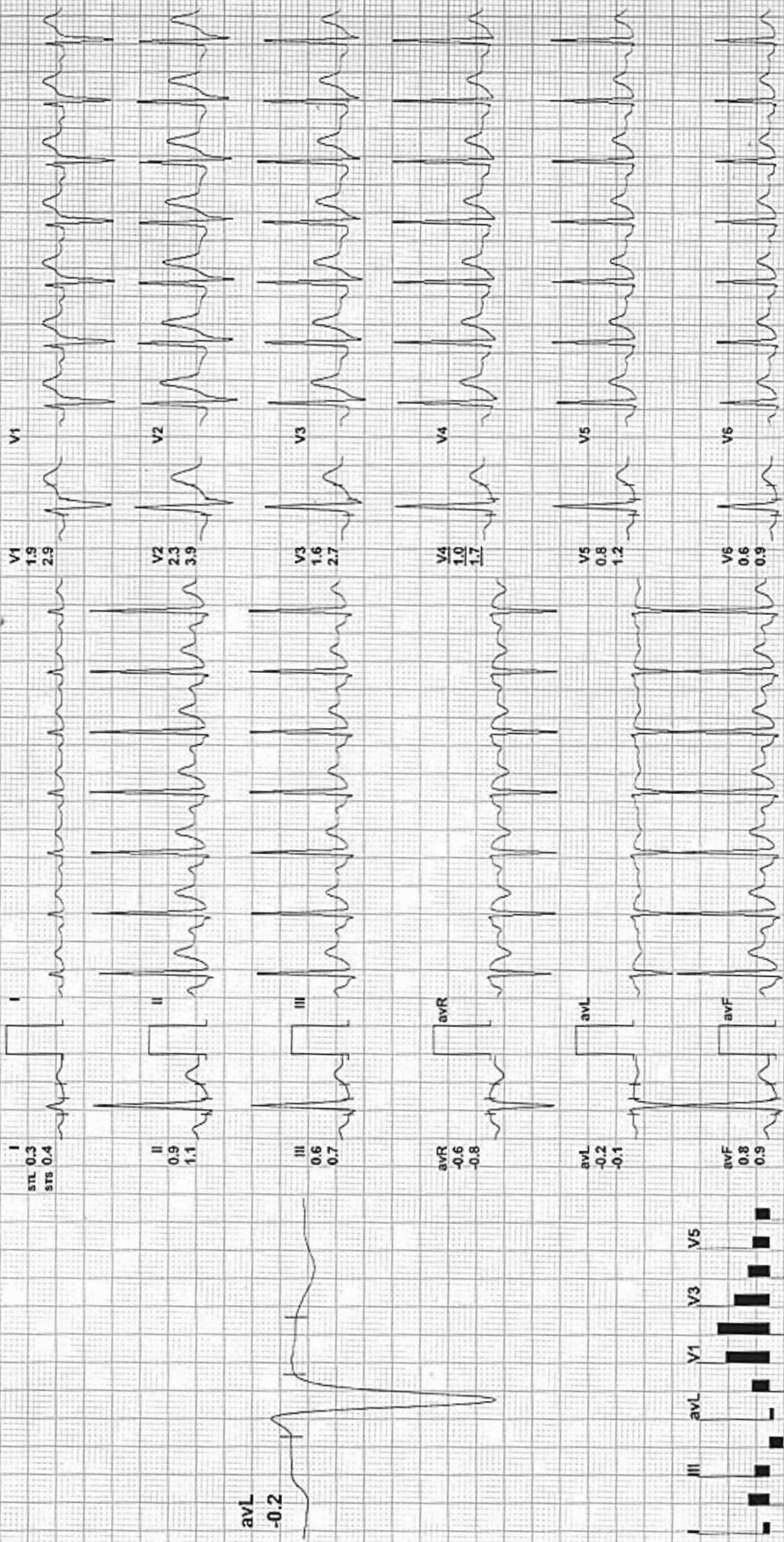
REMARKS:



Date: 23-Mar-2024 02:39:47 PM METS: 1.0/ 123 bpm 67% of THR BP: 150/90 mmHg Combined Medians/ BLC On/ Notch On/ HF 0.05 Hz/LF 35 Hz

ExTime: 09:08 0.0 mph, 0.0%
25 mm/Sec. 1.0 Cm/mV

4X 80 mS Post J



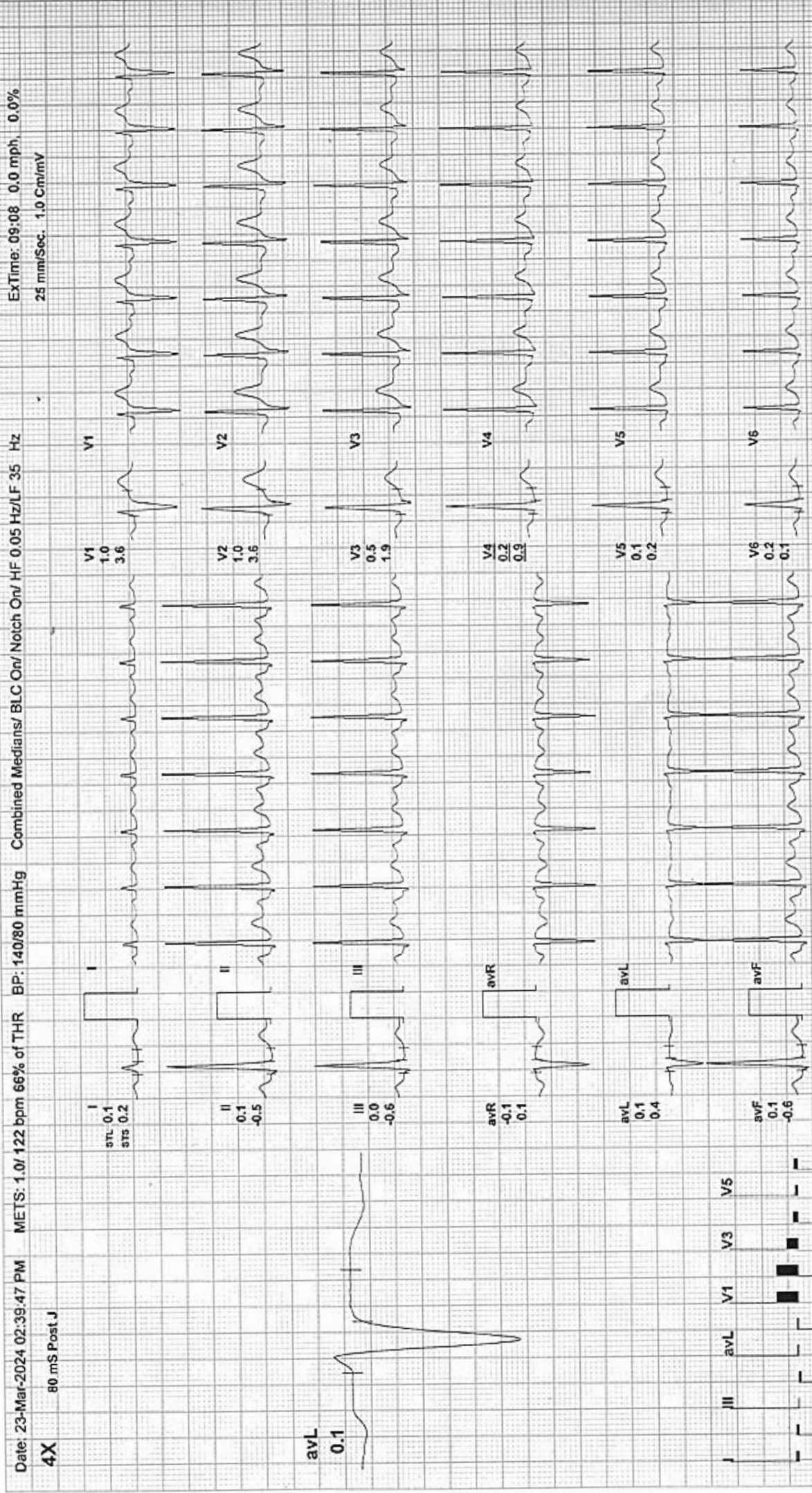
REMARKS:



Recovery(4:00)

ARAVALI HOSPITAL

566 / LOKESH KUMAR / 36 Yrs / M / 0 Cms / 0 Kg / HR : 122



ExTime: 09:08 0.0 mph, 0.0%
25 mm/Sec. 1.0 Cm/mV

Date: 23-Mar-2024 02:39:47 PM METS: 1.0/ 122 bpm 66% of THR BP: 140/80 mmHg Combined Medians/ BLC On/ Notch On/ HF 0.05 Hz/LF 35 Hz

4X 80 mS Post J

REMARKS:

