

--

Name : **Ms. SAKSHI SONKER** Age : **25Yr 2Mth 0Days** Gender : **Female**
UHID : ASHB.0000055898 /BPLAH11741 W/BNo/RefNo: AHC
SIN \ LRN : 201094 \ 201095 \ 201096 \ 201097 \ 80002
Specimen : Blood
Ref Doctor : Dr. Akhil Kumar Tiwari



ASHB.0000055898

Collected on : 09-NOV-2024 11:39:37 AM Received on : 09-NOV-2024 12:17:23 PM Reported on : 09-NOV-2024 01:47:12 PM

MEDIWHEEL FULL BODY HEALTH ANNUAL PLUS CHECK FEMALE

TEST NAME	RESULT	BIOLOGICAL REFERENCE INTERVALS	UNITS
GLUCOSE - SERUM / PLASMA (FASTING)			
GLUCOSE - PLASMA (FASTING)	94	70-100	mg/dL
GLUCOSE - SERUM / PLASMA (POST PRANDIAL)			
GLUCOSE - PLASMA - (POST PRANDIAL)	84	70-140	mg/dL
GLYCOSYLATED HEMOGLOBIN (HBA1C) - WHOLE BLOOD	5.3	4.0-5.6	%
CHOLESTEROL - SERUM / PLASMA	165	Desirable: <200 Borderline High: 200-239 High >240	mg/dL
HDL CHOLESTEROL - SERUM / PLASMA	44	>40	mg/dL
LDL CHOLESTEROL - SERUM / PLASMA	112 *	Optimal: <100 Above optimal: 100-129 Borderline high: 130-159 High: 160-189 Very high: >190	mg/dL
TRIGLYCERIDES - SERUM / PLASMA	103	Normal<150 Borderline high 150-199 High 200-499 Very high: ≥ 500	mg/dL
VLDL CHOLESTEROL - SERUM	21	15-30	

Name : **Ms. SAKSHI SONKER** Age : **25Yr 2Mth 0Days** Gender : **Female**
 UHID : ASHB.0000055898 / BPLAH11741 W/BNo/RefNo : AHC
 SIN \LRN : 201093 \ 201100 \ 80002
 Specimen : Urine
 Ref Doctor : Dr. Akhil Kumar Tiwari



Collected on : 09-NOV-2024 05:12:41 PM Received on : 09-NOV-2024 05:43:44 PM Reported on : 09-NOV-2024 06:06:56 PM

MEDIWHEEL FULL BODY HEALTH ANNUAL PLUS CHECK FEMALE

<u>TEST NAME</u>	<u>RESULT</u>	<u>BIOLOGICAL REFERENCE INTERVALS</u>	<u>UNITS</u>
URINE ROUTINE (CUE)			
MACROSCOPIC EXAMINATION			
Specific Gravity(Automated – Reflectance Spectrometer)	1.005	1.005 - 1.025	
Colour:(Naked Eye Examination)	Pale-Yellow		
Transparency:(Naked Eye Examination)	Clear		
pH(Automated – Reflectance Spectrometer)	Acidic		
Protein :(Automated – Reflectance Spectrometer/Sulpho salicylic acid method)	Nil		
Sugar:(Automated - Reflectance Spectrometer/ Benedict's Test)	Nil		
Ketone(Automated – Reflectance Spectrometer/Rothera's test)	Nil		
Bilirubin: (Automated – Reflectance Spectrometer/Fouchet's method)	Nil		
Cells:			
RBC(Automated - Reflectance spectrometer/Microscopy/Flow cytometric)	Nil		
Pus Cells(Automated – Reflectance spectrometer/Microscopy/Flow	4-6	0.0 - 5.0/HPF	/hpf

Name : **Ms. SAKSHI SONKER** Age : **25Yr 2Mth 0Days** Gender : **Female**
UHID : ASHB.0000055898 / BPLAH11741 **W/BNo/RefNo** : AHC
SIN \LRN : 201093 \ 201100 \ 80002
Specimen : Urine
Ref Doctor : Dr. Akhil Kumar Tiwari



Collected on : 09-NOV-2024 05:12:41 PM **Received on** : 09-NOV-2024 05:43:44 PM **Reported on** : 09-NOV-2024 06:06:56 PM

cytometric)			
Epithelial Cells(Microscopic /Flow cytometric)	1-2	<20	/hpf
Yeast Cells	Absent		
Bacteria:	Absent		
Casts:(Microscopic /Flow cytometric)	Absent	ABSENT	
Crystals:(Microscopic /Flow cytometric)	Absent		
CBC			
HAEMOGLOBIN	12.1	12.0 to 15.1	g/dL
Packed cell volume (Calculated)	37.1	35.5 to 44.9	%
RBC COUNT(Impedance)	4.40	4.00-5.20	Million/ul
MCV-	84.3	80-100	fl
MCH-	27.6	27-32	pg
MCHC-	32.8	32-36	g/dL
RDW (Derived from RBC histogram)	15.5	12.2 - 16.1	%
TLC COUNT	6.05	4.0-11.0	10 ³ /mm ³
DIFFERENTIAL COUNT			
Neutrophils	62	40-80	%
Lymphocytes	27	20-40	%
Monocytes	8	2-10	%
Eosinophils	3	1-6	%
Basophils	0	0-2	%
Platelet Count(Impedance)	296.9	150-450	10 ³ /mm ³
Mean Platelet Volume	8.1	6.5-12.0	fl
ERYTHROCYTE SEDIMENTATION RATE (ESR)	47 *	0-20	mm/1st hr

Name : **Ms. SAKSHI SONKER** Age : **25Yr 2Mth 0Days** Gender : **Female**
UHID : ASHB.0000055898 / BPLAH11741 W/BNo/RefNo : AHC
SIN \LRN : 201093 \ 201100 \ 80002
Specimen : Urine
Ref Doctor : Dr. Akhil Kumar Tiwari



Collected on : 09-NOV-2024 05:12:41 PM Received on : 09-NOV-2024 05:43:44 PM Reported on : 09-NOV-2024 06:06:56 PM

Report Status:Final

* END OF REPORT *

CHECKED BY : 154234
727938

A handwritten signature in black ink, appearing to read 'Dr. Shubhra Prasad', located in the bottom right area of the report.

Dr. Shubhra Prasad
Consultant Pathologist

Printed On : 12-NOV-2024 10:51:41 AM

Name : **Ms. SAKSHI SONKER** Age : **25Yr 2Mth 0Days** Gender : **Female**
UHID : ASHB.0000055898 / BPLAH11741 W/BNo/RefNo : AHC
SIN \LRN : 201098 \ 80002
Specimen : Blood
Ref Doctor : Dr. Akhil Kumar Tiwari



Collected on : 09-NOV-2024 11:39:38 AM Received on : 09-NOV-2024 12:26:38 PM Reported on : 09-NOV-2024 12:28:18 PM

MEDIWHEEL FULL BODY HEALTH ANNUAL PLUS CHECK FEMALE

TEST NAME **RESULT**

BLOOD GROUPING AND TYPING (ABO and Rh)

ABO Group: **B**
Rh (D) Type: **Positive**

Report Status:Final

* END OF REPORT *

CHECKED BY : 154612
725449

A handwritten signature in blue ink, appearing to read 'Dr. Samir Singh'.

Dr. Samir Singh
Consultant Blood Bank

Printed On : 12-NOV-2024 10:52:28 AM

Dr. ARPITA AGARWAL

MBBS, MS, FLPPEI (GLAUCOMA AND CATARACT.)

CATARACT, GLAUCOMA AND REFRACTIVE SURGEON
EX FELLOW AND CONSULTANT LV PRASAD EYE INSTITUTE, HYDERABAD
EX CONSULTANT PEOPLES'S HOSPITAL, BHOPAL
EX CONSULTANT ASG EYE HOSPITAL, BHOPAL

NAME Mr. Seekshi AGE 25/F DATE 9/11/24
C/O.

VN	UNAIDED	WITH GLASS	PINHOLE
RE	<u>6/18</u>		
LE	<u>6/12(P)</u>		

REFRACTION;

SUB	SPH	CYL	AXIS	VN
RE	-	<u>-1.5</u>	<u>180</u>	<u>6/10</u>
LE	-	<u>-1.25</u>	<u>180</u>	<u>6/8</u>
NV				

NAME
09_NOV_2024 PM 03:05
NO. 1382
SN: 4783993
REF. DATA
VD: 12.00
CYL: MIX
A
1
1
1
1
S. E. - 1.25
C
A
+ 0.75 - 1.50 172
+ 0.75 - 1.50 172
+ 0.75 - 1.50 172
+ 0.75 - 1.50 172
S. E. - 0.00
PD: 51.5
TOPCON



APOLLO SAGE HOSPITAL
BAWADIYAN KALAN
BHOPAL

Station
Telephone:

EXERCISE STRESS TEST REPORT

Patient Name: SONKER, SAKSHI
Patient ID: HC-55898
Height: 165 cm
Weight: 64.4 kg

DOB: 11.08.1999
Age: 25 yrs
Gender: Female
Race: Indian

Study Date: 09.11.2024
Test Type: Treadmill Stress Test
Protocol: BRUCE

Referring Physician: --
Attending Physician: Dr.Akhilshwar Rathore
Technician: Radha Prajapati

Medications:

Medical History:
NONE

Reason for Exercise Test:
Screening for CAD

Exercise Test Summary

Phase Name	Stage Name	Time in Stage	Speed [km/h]	Grade [%]	HR [bpm]	BP [mmHg]	Comment
PRETEST	SUPINE	00:29	0.00	0.00	99	110/70	
	STANDING	00:09	0.00	0.00	96	110/70	
	HYPERV	00:03	0.00	0.00	97	110/70	
	WARM-UP	00:16	1.60	0.00	93		
EXERCISE	STAGE 1	03:00	2.70	10.00	133	110/70	
	STAGE 2	03:00	4.00	12.00	157		
	STAGE 3	00:44	5.40	14.00	169	120/70	
RECOVERY		03:04	0.00	0.00	96	110/70	

The patient exercised according to the BRUCE for 6:43 min:s, achieving a work level of Max. METS: 9.10. The resting heart rate of 97 bpm rose to a maximal heart rate of 169 bpm. This value represents 86 % of the maximal, age-predicted heart rate. The resting blood pressure of 110/70 mmHg, rose to a maximum blood pressure of 120/70 mmHg. The exercise test was stopped due to Target heart rate achieved.

Interpretation

Summary: Resting ECG: normal.
Functional Capacity: normal.
HR Response to Exercise: appropriate.
BP Response to Exercise: normal resting BP - appropriate response.
Chest Pain: none.
Arrhythmias: none.
ST Changes: none.
Overall impression: Normal stress test.

Conclusions

No ST-T Changes Noted During Exercise & Recovery Stages,
Negative Stress Test,
Physician _____ Technician _____

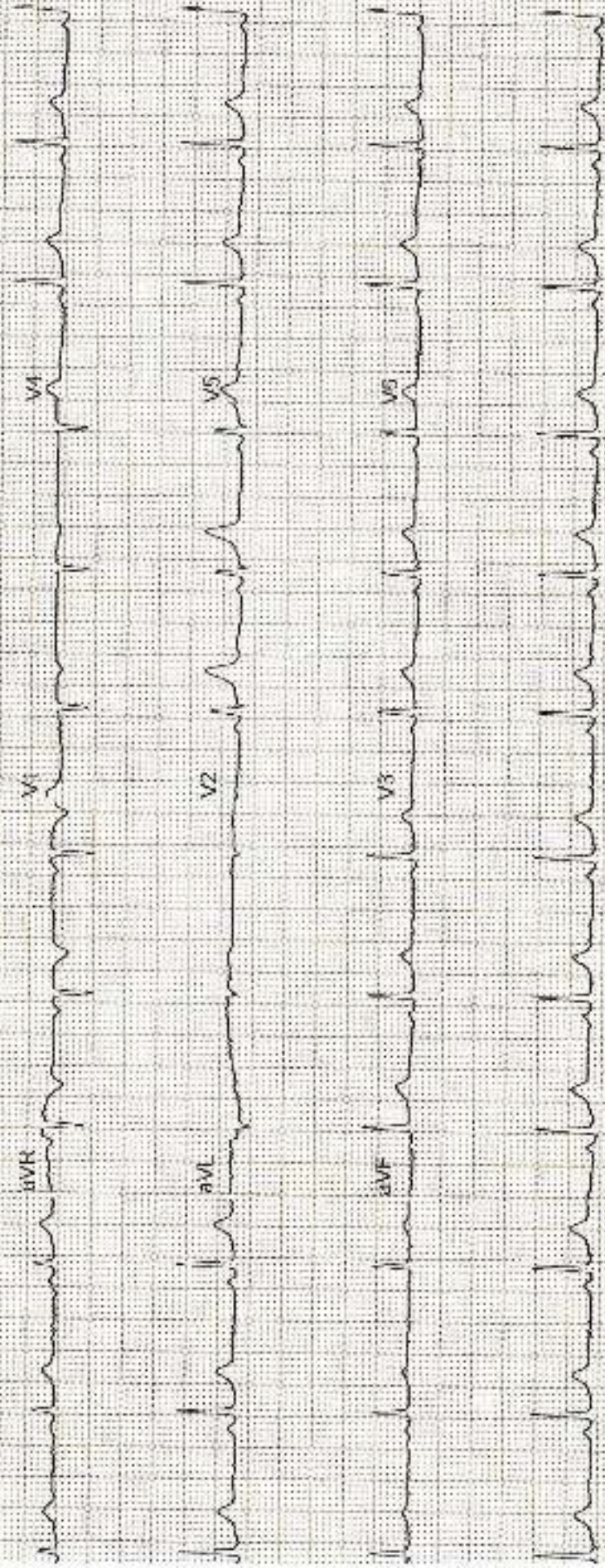
Patient

Order Num:
indical
Miscation 1:
Miscation 2:
Miscation 3:

Technical
Creating the
Recording on
Storage

Normal sinus rhythm
Normal ECG

OT / QTcBaz	372 / 393 ms	QRS	88 ms
PR	114 ms		
P	90 ms		
RR / PP	890 / 895 ms		
P / QRS / T	49 / 67 / 49 degrees		



ULTRA SONOGRAPHY ABDOMEN

Patient Name:	SAKSHI SONKER	Patient ID:	ASHR.0000055898
Age:	25 Years	Sex:	F
Accession Number:	17101.224013205	Modality:	US
Referring Physician:	Akhil Kumar Tiwari	Study:	ULTRASOUND - WHOLE ABDOMEN
Study Date:	09-Nov-2024		

Liver:- is normal in size and echotexture. Portal and hepatic venous system appears normal. Intra and extra hepatic biliary radicals are not dilated.

Gall Bladder:- is normal in size and shape. Its lumen is echofree.

Pancreas is normal in size outline and echopattern.

Spleen is normal in size and echopattern.

Both kidneys are normal in size, shape and echogenicity. Central pelvicalyceal sinus and corticomedullary ratio are normal.

Right kidney measures:- 10.4 x 3.9 cm

Left kidney measures:- 10.0 x 4.1 cm

No evidence of ascites is seen.


Urinary bladder is normal in shape and contour. Its wall is normal.

Uterus and ovaries:- are normal in size and echopattern. Cervix shows normal echopattern. No adnexal mass. No free fluid in POD.

IMPRESSION:- Sonography Study Reveals:-

- **No significant abnormality detected.**

ADV:- Clinical Correlation.



DR. HARI SANTOSH
CONSULTANT RADIOLOGIST



Patient Name:	SAKSHI SONKER	Patient ID:	ASHB.0000055888
Age:	25 Years	Sex:	F
Accession Number:	17101 124019619	Modality:	DX
Referring Physician:	Akhil Kumar Twari	Study:	CHEST
Study Date:	09-Nov-2024		

X-RAY CHEST (PA VIEW)

Both lung fields are clear. No active pleural or parenchymal lesion is seen.

The hila, mediastinum, bony thoracic cage and the diaphragmatic domes are normal.


The costophrenic and cardiophrenic angles are clear.

The cardiac silhouette is unremarkable.

IMP:- RADIOGRAPHIC IMAGE REVEALS:-

Normal findings are seen.

Thanks for Ref



DR. HARI SANTOSH
CONSULTANT RADIOLOGIST

Date: 09-Nov-2024 16:20:53

