

CERTIFICATE OF MEDICAL FITNESS

This is to certify that I have conducted the clinical examination

of Mrs. Abhaya Vinit Awaghade on 13/02/2024

After reviewing the medical history and on clinical examination it has been found that he/she is

	Tick
<ul style="list-style-type: none"> • Medically Fit 	✓
<ul style="list-style-type: none"> • Fit with restrictions/recommendations <p>Though following restrictions have been revealed, in my opinion, these are Impediments to the job.</p> <p>1.....</p> <p>2.....</p> <p>3.....</p> <p>However the employee should follow the advice/medication that has been Communicated to him/her.</p> <p>Review after _____</p>	
<ul style="list-style-type: none"> • Currently Unfit. <p>Review after _____ recommended</p>	
<ul style="list-style-type: none"> • Unfit 	

Dr. Anam A. Inamdar
Medical Officer
Apollo Clinic, (NIGDI)

Dr. Anam A. Inamdar
MBBS
Reg. No. 2021/06/6236

This certificate is not meant for medico-legal purposes

Apollo Health and Lifestyle Limited

(CIN - U05110TG2000PLC115619)

Regd. Office: 1-10-60/62, Ashoka Rajgopalni Chambers, 6th Floor, Begumpet, Hyderabad, Telangana

- 500 016. Ph No: 040-4904 7777, Fax No: 4904 7744 | Email: hr@apollohl.com |

www.apollohl.com

APOLLO CLINICS NETWORK MAHARASHTRA

Pune (Aundh) | Kharadi | Nigdi (Pradhikaran) | Viman Nagar | Wanowrie



Certificate No: MC-5637

Patient Name : Mrs.ABHAYA VINIT AWAGHADE	Collected : 10/Feb/2024 11:55AM
Age/Gender : 30 Y 3 M 1R D/F	Received : 10/Feb/2024 04:33PM
UHID/MR No : CPIM.0000116505	Reported : 10/Feb/2024 05:27PM
Visit ID : CPIMOPV156778	Status : Final Report
Ref Doctor : Dr.SELF	Sponsor Name : ARCOFEMI HEALTHCARE LIMITED
Emp/Auth/TPA ID : bobE5249	

DEPARTMENT OF BIOCHEMISTRY

ARCOFEMI - MEDIWHEEL - FULL BODY HEALTH ANNUAL PLUS CHECK - FEMALE - 2D ECHO - PAN INDIA - FY2324

Test Name	Result	Unit	Bio. Ref. Range	Method
GLUCOSE, FASTING , NAF PLASMA	77	mg/dL	70-100	HEXOKINASE

Comment:

As per American Diabetes Guidelines, 2023

Fasting Glucose Values in mg/dL.

Fasting Glucose Values in mg/dL.	Interpretation
70-100 mg/dL.	Normal
100-125 mg/dL.	Prediabetes
≥126 mg/dL.	Diabetes
<70 mg/dL.	Hypoglycemia

Note:

- The diagnosis of Diabetes requires a fasting plasma glucose of $>$ or $=$ 126 mg/dL, and/or a random / 2 hr post glucose value of $>$ or $=$ 200 mg/dL on at least 2 occasions.
- Very high glucose levels ($>$ 450 mg/dL, in adults) may result in Diabetic Ketoacidosis & is considered critical.

DR. Sanjay Ingle
M.B.B.S, M.D (Pathology)
Consultant Pathologist

SIN No: PT.F02104200

This test has been performed at Apollo Health and Lifestyle Ltd- Sadashiv Peth Pune, Diagnostics Lab

Apollo Health and Lifestyle Limited (CIN - URS1107G2000PLC115819)

Regd. Office: 1-10 66/62, Ashoka Bhagupathi Chambers, 5th Floor, Begumpet, Hyderabad, Telangana - 500 016 |
www.apolloclinic.com | Email ID: enquiry@apolloclinic.com, Ph No: 040-4504 7277, Fax No: 4504 7744

APOLLO CLINICS NETWORK

Telangana: Hyderabad (AS Rao Nagar) | Chanda Nagar | Kanchana | Nizampet | Nizampet | Marathahalli | Uppal | Andhra Pradesh: Vijay | Guntur | Karnataka: Bangalore (Banashankari, 2-Phase) | Electronic City | Hosur Town (RGS Layout) | India
Other: Pune (Khadambad) | Hyderabad (Gajanan) | Ahmedabad (Gandhinagar) | Panaji | Amritsar (Court Road) | Mysore | Tirunelveli (Railway Station Road)

Shop No: 14 to 20, City Plaza Building,
Sector - 25, Near to BHEL Chowk, Noida (Phase II),
Pune, Maharashtra, India - 411004

1860 500 7788
www.apolloclinic.com




CONCENT FORM

Name of the patient : Mrs. Abhaya Vinit Acaaghade

Company Name: Bank of Baroda

Test name : X-Ray

Reason: May be pregnant.


Signature & date

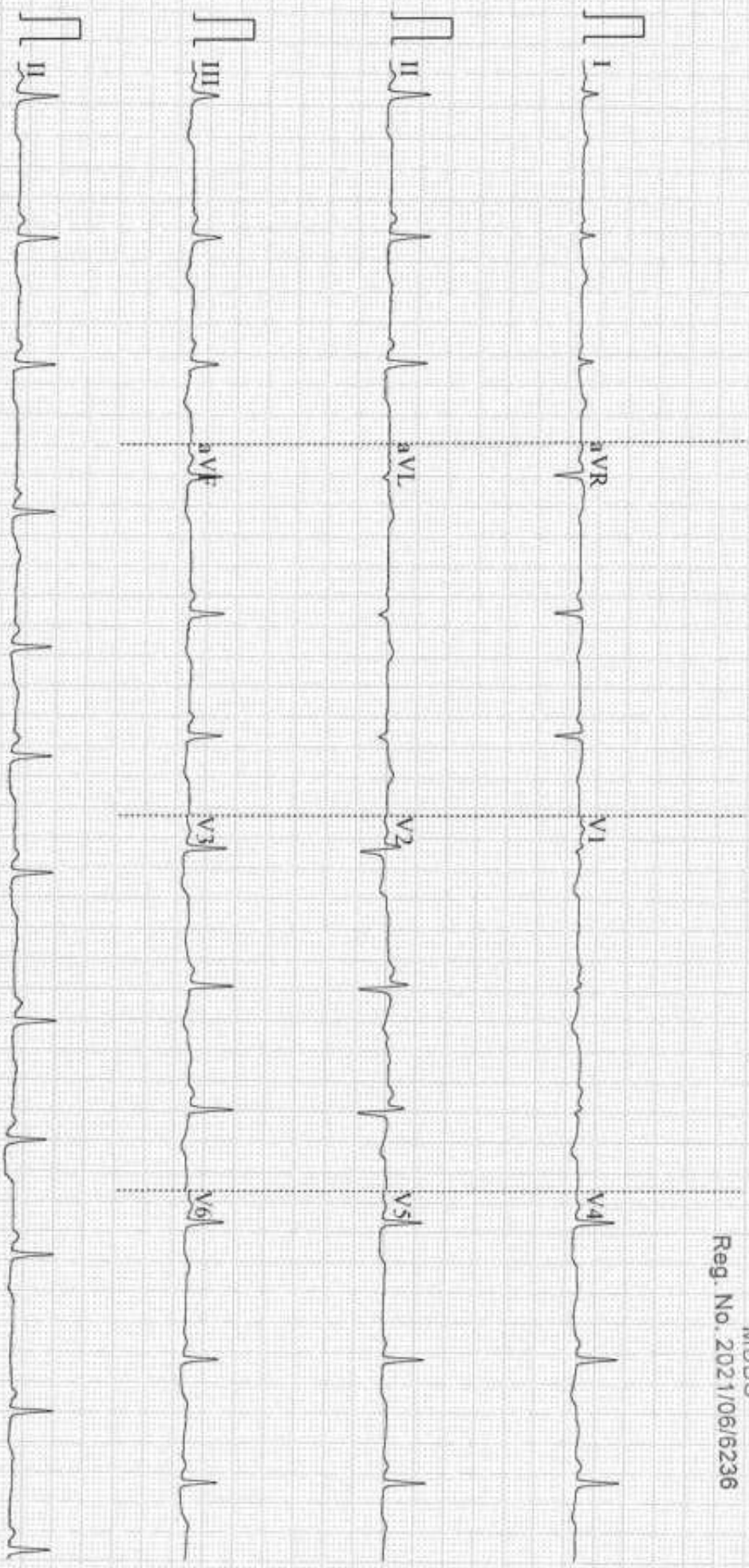
ABHAYA AWAGHADE
Female 30Years

HR : 69 bpm
P : 101 ms
PR : 129 ms
QRS : 88 ms
QT/QTc : 389/418 ms
P/QRS/T : 67/78/-25 °
RV5/SV1 : 0.654/0.062 mV

Diagnosis Information:
Sinus Arrhythmia
ST-T Abnormality(V3)
Low Voltage(Chest Leads)

Report Confirmed by:

Dr. Anam A. Inamdar
MBBS
Reg. No. 2021/06/6236



Patient Name	: Mrs. ABHAYA VINIT AWAGHADE	Age	: 30 Y F
UHID	: CPIM.0000116505	OP Visit No	: CPIMOPV156778
Reported on	: 10-02-2024 12:46	Printed on	: 10-02-2024 12:50
Adm/Consult Doctor	:	Ref Doctor	: SELF

DEPARTMENT OF RADIOLOGY

ULTRASOUND - WHOLE ABDOMEN

Liver appears normal in size and echotexture. No focal lesion is seen. PV and CBD normal. No dilatation of the intrahepatic biliary radicals.

Gall bladder is well distended. No evidence of calculus. Wall thickness appears normal. No evidence of periGB collection. No evidence of focal lesion is seen.

Spleen appears normal. No focal lesion seen. Splenic vein appears normal.

Pancreas appears normal in echopattern. No focal/mass lesion/calcification. No evidence of peripancreatic free fluid or collection. Pancreatic duct appears normal.

Both the kidneys appear normal in size, shape and echopattern. Cortical thickness and CM differentiation are maintained. No calculus / hydronephrosis seen on either side.

Urinary Bladder is well distended and appears normal. No evidence of any wall thickening or abnormality. No evidence of any intrinsic or extrinsic bladder abnormality detected.

Uterus appears normal in size. It shows normal shape & echo pattern. Endometrial echo-complex appears normal and measures 3.2 mm. No intra/extra uterine gestational sac seen.

Both ovaries appear normal in size, shape and echotexture.

Patient Name	: Mrs. ABHAYA VINT AWAGHADE	Age	: 30 Y F
UHID	: CPIM.0000116505	OP Visit No	: CPIMOPV156778
Reported on	: 10-02-2024 12:46	Printed on	: 10-02-2024 12:50
Adm/Consult Doctor	:	Ref Doctor	: SELF

No evidence of any adnexal pathology noted.

IMPRESSION:-

No significant abnormality detected.

Suggest – clinical correlation.

(The sonography findings should always be considered in correlation with the clinical and other investigation finding where applicable.) It is only a professional opinion, Not valid for medico legal purpose.

Printed on:10-02-2024 12:46

---End of the Report---



Dr. KUNDAN MEHTA
MBBS, DMRE (RADIOLOGY)
Radiology

2 D ECHOCARDIOGRAPHY & COLOUR DOPPLER STUDY

Patient's Name: MRS. ABHAYA AWAGHADE	Age/Sex: 30 / F
Ref: ARCOFEMI	Date: 10.02.2024

2 DIMENSIONAL ECHOCARDIOGRAPHY:

1. All cardiac chambers are normal in dimensions
2. No LV regional wall motion abnormalities at rest
3. LVEF = 60 %
4. Good RV function
5. All cardiac valves structurally normal
6. IAS / IVS intact
7. No clots / vegetation/ pericardial effusion seen on TTE
8. Great arteries are normally related & appear normal
9. IVC is normal in size & collapsing well with respiration

DOPPLER STUDIES (CONTINUOUS WAVE, PULSED WAVE, COLOR DOPPLER):

1. Normal transvalvular pressure gradients, No AR/MR, Trivial TR
2. No LV diastolic dysfunction
3. No pulmonary hypertension
4. No intracardiac or extracardiac shunt noted

DIMENSIONS (M-MODE) :

Left Atrium	27.0 mm	Aortic Root	24.0 mm
IVS (d)	08.0 mm	IVS (s)	12.0 mm
LVID (d)	34.0 mm	LVID (s)	20.0 mm
LVPW(d)	08.0 mm	LVPW(s)	12.0 mm

IMPRESSION :

NORMAL CARDIAC CHAMBER DIMENSIONS

GOOD BIVENTRICULAR FUNCTION

LVEF = 60%

NO LV DIASTOLIC DYSFUNCTION

NORMAL CARDIAC VALVES

NO PULMONARY HYPERTENSION

IAS/IVS INTACT

NO CLOT/VEGETATION/PERICARDIAL EFFUSION



DR. RAJENDRA V. CHAVAN

MD (MEDICINE), DM (CARDIOLOGY)

CONSULTANT CARDIOLOGIST

Apollo Health and Lifestyle Limited

(CIN - U85110TG2000PLC115819)

Regd. Office: 1-10-60/62, Ashoka Raghupathi Chambers, 5th Floor, Begumpet, Hyderabad, Telangana - 500 016.

Ph No: 040-4904 7777, Fax No: 4904 7744 | Email ID: enquiry@apollohl.com | www.apollohl.com

APOLLO CLINICS NETWORK MAHARASHTRA

Pune (Aundh) | Kharadi | Nigdi Pradhikaran | Viman Nagar (Wanowrie)

Online appointments: www.apollohl.com

TO BOOK AN APPOINTMENT

1860 500 7788

Abhayn Awagade

30 ym

10/2/24

Height :	Weight :	BMI :	Waist Circum :
Temp :	Pulse :	Resp :	B.P :

General Examination / Allergies History

Comp: 14/1/24
DMC: 4 days RPR

MIC - 4 yrs

Dxtr:

H/O - Hypertension,
2 yrs

P/O - SOB

M/S: LFT - NG (M)

Di: on letyhd, as

10/2/24

(A to) then WNL

Clinical Diagnosis & Management Plan

No acute cardiac
problems now

Follow up date:

TAC NIGDI
Dr. Archana Chaudhary
MBBS, MD
Reg. No. 3083

Doctor Signature

Apollo Clinic,
Nigdi, Pune - 411044.

Date - 10.10.2024

Patient Name

Abhayee Awaghade

UHID:

Age / Sex:

3042 1F

EYE CHECK UP

COMPLETE

PREMEDICAL/OTHER

	RIGHT EYE	LEFT EYE
Far Vision	6/6 NB 7cspet	6/6 NB 7cspet
Near Vision		
Anterior Segment Pupil	WNL	WNL
Color Vision	Normal	Normal
Family History/Medical History	—	—

IMPRESSION:-

Same Rx


OPTOMETRIST

Mrs. Abhaya Awaghade

30 yrs / F

Wt - 52-7 kg

Ht - 153 cm

Apollo Clinic
Expertise. Closer to you.

10th Feb 2024.

A - Clo Hypothyroidism On Reg. Rx
clo hard stool.Daily DietMorning - 1 glass luke warm water
+ 1 spoon घाले, जिरे, बसिरीय, कालिंदी,
मिठ पांजरMorning Exercise - SuryanamskarMorning Breakfast - Sprouts
OR - Ragi or Mug dasa / dhrode

+ 1 glass Curd [Freshly prepared]

11 am - Buttermilk + Sabja / chia Seeds
OR Raygeera Ladoo1-2 pm Lunch - Salad / Dalw raita
+ Sabji + Chapati + Dal / sprouts / Boiled egg
(whole)
+ 1/2 katori rice

4 pm - fruit any seasonal

6 pm - Buttermilk + Sabja seeds

8 pm - Dinner - Salad + Chapati + Sabji +
Dal / 2-3 pcs chicken / fish

P. T. O →

Apollo Health and Lifestyle Limited

(CIN - U85110TG2000PLC115819)

Regd. Office: 1-10-60/62, Ashoka Raghupathi Chambers, 5th Floor, Begumpet, Hyderabad, Telangana - 500 016.

Ph No: 040-4904 7777, Fax No: 4904 7744 | Email ID: enquiry@apollohl.com | www.apollohl.com

APOLLO CLINICS NETWORK MAHARASHTRA

Pune (Aundh | Kharadi | Nigdi Pradhikaran) | Viman Nagar | Wanowrie

Online appointments: www.apolloclinic.com

TO BOOK AN APPOINTMENT

1860 500 7788

Date : 10-02-2024

Department : GENERAL

MR NO : CPIM.0000116505

Doctor :

Name : Mrs. ABHAYA VINIT AWAGHADE

Registration No : H+ 153

Age/ Gender : 30 Y / Female

Qualification : Wd 52-7

BP 110/90

Consultation Timing: 10:56

~~MA~~

TSH
Thylenom 75
S/E

CVS: S, S₂ ⊕

RS: AEBE

CNS: NAD.

PA: NAD.

Diet Mix


No known allergy.
No past Sx

Anam

Dr. Anam A. A. Inamdar
MBBS
Reg. No. 2021/06/6236

44

Name : Mrs. ABHAYA VINIT AWAGHADE
 Age: 30 Y
 Sex: F
 Address : F2 - 04, GANGA SKIES SOCIETY, VALLABH NAGAR,
 Plan : ARCOFEMI MEDIWHEEL FEMALE AHC CREDIT PAN
 INDIA OP AGREEMENT

UHID:CPIM.0000116505

 OP Number:CPIMOPV156778
 Bill No :CPIM-OCR-75983
 Date : 10.02.2024 10:57

Sno	Service Type/ServiceName	Department
1	ARCOFEMI - MEDIWHEEL - FULL BODY HEALTH ANNUAL PLUS CHECK - FEMALE - 2D ECHO - PAN INDIA - FY2324	
✓ 1	GAMMA GLUTAMYL TRANSFERASE (GGT)	
✓ 2	2D ECHO	
✓ 3	LIVER FUNCTION TEST (LFT)	
✓ 4	GLUCOSE, FASTING	
✓ 5	HEMOGRAM + PERIPHERAL SMEAR	
✓ 6	GYNÆCOLOGY CONSULTATION	
7	DIET CONSULTATION	
✓ 8	COMPLETE URINE EXAMINATION	
9	URINE GLUCOSE(POST PRANDIAL)	
✓ 10	PERIPHERAL SMEAR	
✓ 11	ECG	
✓ 12	LBC PAP TEST- PAPSURE	
✓ 13	RENAL PROFILE/RENAL FUNCTION TEST (RFT/KFT)	
✓ 14	DENTAL CONSULTATION	
✓ 15	GLUCOSE, POST PRANDIAL (PP), 2 HOURS (POST MEAL) 11:30.	
✓ 16	URINE GLUCOSE(FASTING)	
✓ 17	HbA1c, GLYCATED HEMOGLOBIN	
✓ 18	X-RAY CHEST PA \leftrightarrow Not Done -	
✓ 19	ENT CONSULTATION	
20	FITNESS BY GENERAL PHYSICIAN	
✓ 21	BLOOD GROUP ABO AND RH FACTOR	
✓ 22	LIPID PROFILE	
23	BODY MASS INDEX (BMI)	
✓ 24	OPHTHAL BY GENERAL PHYSICIAN	
✓ 25	ULTRASOUND - WHOLE ABDOMEN	
✓ 26	THYROID PROFILE: (TOTAL T3, TOTAL T4, TSH)	

Radio
 Completed

52.7
 153