

HEALTH CHECK UP

Name : Arvind Kumar Singh

Date : 9/3/2014

Age : 53

Sex : Male / Female

Marital status : Married / Single

PERSONAL HISTORY

Habits : Smoking / Tobacco & Snuff / Alcohol no

Drug allergy if any :

Medical : all

Surgical :

Height 172 cm Weight 90 Kg. BP 120/80 Pulse 73

Vision : Rt 6/12 Lt 6/12 With Spectacles Rt. Lt.

Colour Vision : Normal / Abnormal Near Vision NG/BF

FAMILY HISTORY

Father Mother Siblings

CVS : Heart Sound Normal Murmurs Absent Thrills Absent

RS : Rate /mt Breath sounds Normal Adventitious Absent

ABDOMEN : Tenderness Absent Rigidity Absent Bowel sound Normal

Liver NAD Kidney NAD Hernia Absent

CNS : Cranial Nerves NAD Sensory System NAD Motor System NAD

ENT NAD

Remarks

Dr. Bharti Jeswani
MBBS

Dr. Seema Kale
MBBS, MD

Dr. S. K. Suri
MBBS

Dr. Meenakshi
MBBS

HOME SAMPLE COLLECTION FACILITY AVAILABLE

Licensee : Bharti Medicare Pvt. Ltd. The Apollo Clinic, C-70, Major Sudesh Kumar Marg, Opp. Madhav Park, Near Main Market, Rajouri Garden, New Delhi-110 027
Phone : (011) 2591 8222 / 8333 / 8444, 9811061009, E-mail : rajourigarden@theapolloclinic.com, Website : www.apolloclinicrajourigarden.com

MSME UAM NO. : DL11E0021531


Health Check up Booking Request(bobE14352), Beneficiary Code-96490



Mediwheel
to nra. customercare

Fri, Mar 8, 10:31 AM (22 hours ago)

Reply



011-41195959

Dear Apollo Bharti Apollo Bharti Medicare Pvt. Ltd.

We have received a booking request with the following details. Provide your confirmation by clicking on the Yes button.

You confirm this booking?

Name : MR. SINGH ARVINDER PAL

Contact Details : 9650973421

Hospital Package Name : Mediwheel Full Body Health Checkup Male Above 40

Location : C70, Opp. Madhav Park, Major Sudesh Kumar Marg
-110027

Appointment Date : 09-03-2024

Member Information		
Booked Member Name	Age	Gender
MR. SINGH ARVINDER PAL	53 year	Male

Tests included in this Package -

- Stool Test
- Thyroid Profile
- ESR
- Blood Glucose (Fasting)
- General Physician Consultation
- TMT OR 2D ECHO
- Blood Group
- Blood Glucose (Post Prandial)
- Chest X-ray
- ECG
- USG Whole Abdomen
- Eye Check-up consultation
- Urine Sugar Fasting
- Urine Sugar PP
- Dental Consultation
- Urine analysis
- CBC
- HbA1c
- Lipid Profile
- Kidney Profile
- Liver profile
- Prostate Specific Antigen (PSA Male)

ID: 50

arvinder pal singh

Male 53Years

173cm 90kg 120/80 mmHg

Req. No. :

Room No. :

09-03-2024 15:11:01

HR : 73 bpm

P : 98 ms

PR : 148 ms

QRS : 74 ms

QT/QTcBz : 368/406 ms

P/QRS/T : 43/38/16 °

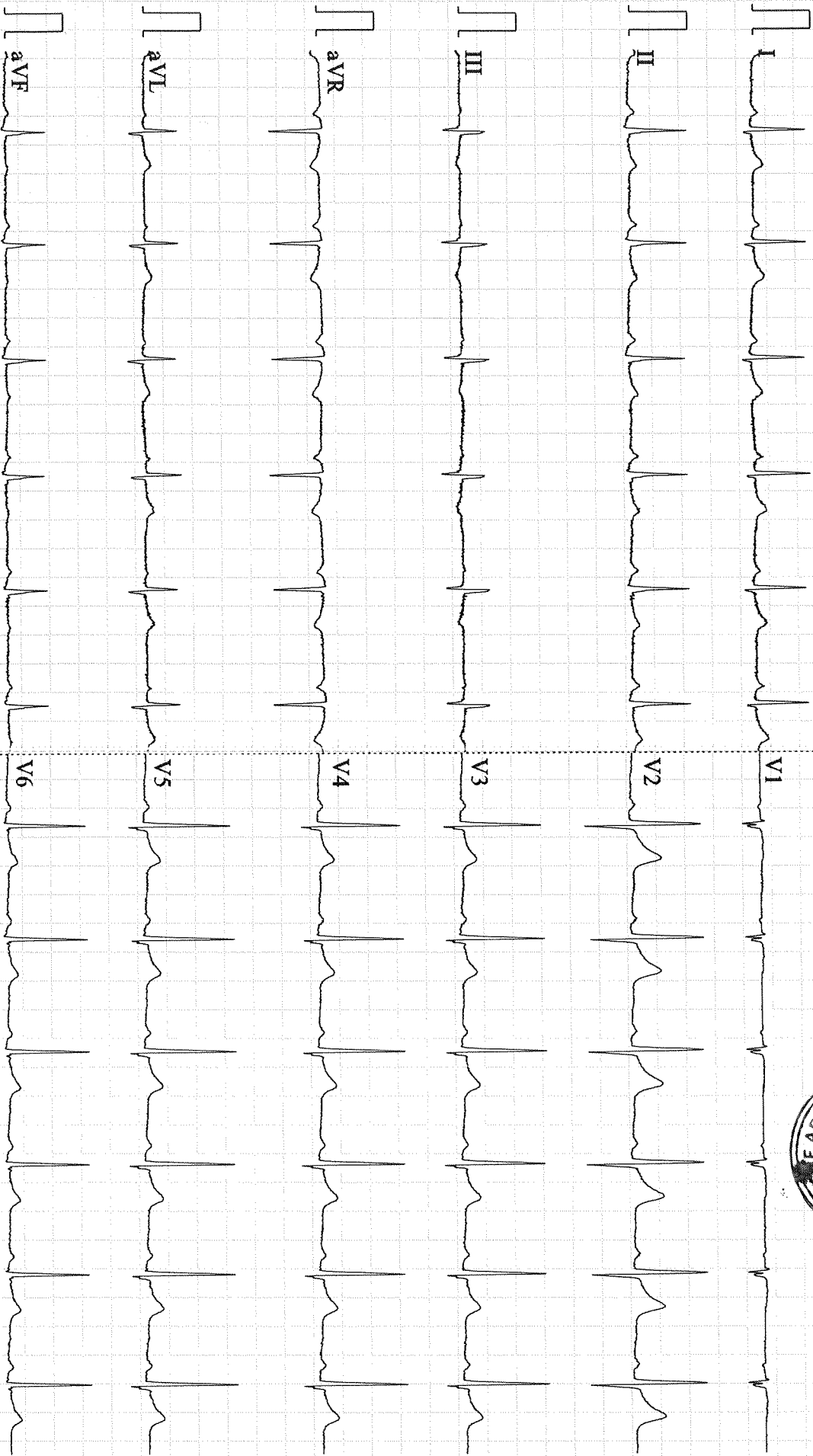

RV5/SV1 : 1.507/0.293 mV

Diagnosis Information:

Sinus rhythm

Normal ECG

Report Confirmed by:



NAME: MR ARVINDER PAL SINGH
REF

AGE: 53 / Sex / M
DATE 09/03/2024

ECHO ADULT (COLOUR DOPPLER)

DIMENSIONS			NORMAL			DIMENSIONS			NORMAL		
Ao (ed)	35.0 mm			(1.5 cm/m ²)		IVS (Ed)	11.0 mm			(0.6-1.2cm)	
LA (es)	37.0 mm			(1.5 cm/m ²)		LVPW (Ed)	10.0 mm			(.6-1.1cm)	
RVID (ed)	Normal			(0.9cm/m ²)		EF	60.0 %			(0.62-0.85)	
LVID (ed)	44.0 mm			(2.6-3.4 cm/m ²)		FS	30.0				
LVID (es)	27.0 mm										

MORPHOLOGICAL DATA

Mitral Valve	Normal	Interatrial Septum	Normal
Aortic Valve	Normal	Interventricular Septum	Normal
Tricuspid Valve	Normal	Pulmonary Artery	Normal
Pulmonary Valve	Normal	Aorta	Normal
Right Ventricle	Normal	Right Atrium	Normal
Left Ventricle	Normal	Left Atrium	Normal
Pericardium	Normal		
Colour Doppler	TRACE MR, MILD AR, TRACE TR, NO PAH, IVC NORMAL.		
Wall motion	Normal		

IMPRESSION : TRACE MR, MILD LV DIASTOLIC DYSFUNCTION, NO RWMA, LVEF ~60 %,
MILD AR, AV NORMAL,
TRACE TR, NO PAH, IVC NORMAL, RVFUNCTION NORMAL.


DR SEEMA KALE MD
SEN. (PHYSICIAN)

• CLINICAL CORRELATION IS ESSENTIAL FOR FINAL DIAGNOSIS. • IF THE TESTS RESULTS ARE UNEXPECTED PLEASE CONTACT THE LABORATORY.
• ALL THE CONGENITAL ANAMOLIES IN THE FETUS MAY NOT BE DIAGNOSED IN ULTRASONOGRAPHY. • THIS REPORT IS NOT VALID FOR MEDICOLEGAL PURPOSE.

Licensee : Bharti Medicare Pvt. Ltd. The Apollo Clinic, C-70, Major Sudesh Kumar Marg, Opp. Madhav Park, Near Main Market, Rajouri Garden, New Delhi-110 027
Phone : (011) 2591 8222 / 8333 / 8444, 9811061009, E-mail : rajourigarden@theapolloclicin.com, Website : www.apolloclicinrajourigarden.com

MSME UAM NO. : DL11E0021531

Patient Name : Arvinder	MR No	: FRAJ0000
Age/Sex : 53 Y/M	Visit No	: FRAJOPV
Pres Doctor :	Bill Date	: 09.03.2024
Ref.by :	Report Date	: 09.03.2024

ULTRASOUND WHOLE ABDOMEN

LIVER: Liver is normal in size with increased echogenicity s/o grade I fatty liver. No focal intra-hepatic lesion detected. Intra-hepatic biliary radicals are not dilated. Portal vein is normal in calibre.

GALL BLADDER: Gall bladder is well visualized. Its wall thickness is normal. No calculus or mass lesion is seen in gall bladder. Common bile duct is normal (not dilated).

PANCREAS: Pancreas appears normal in size and echopattern.

SPLEEN: Spleen appears normal in size and echopattern.

KIDNEYS: Both kidneys are normal in position, size and outline. Cortico-medullary differentiation of both kidneys is maintained. Central sinus echoes are compact. No calculus / hydronephrosis seen. Visualised parts of retroperitoneum do not show any lymphadenopathy.

PROSTATE: Prostate is normal in shape, size and echotexture.

No free fluid detected.

IMPRESSION: - GRADE I FATTY LIVER

Dr. Shailza Minocha 
Consultant Radiologist.

To be correlate clinically.

• CLINICAL CORRELATION IS ESSENTIAL FOR FINAL DIAGNOSIS. • IF THE TESTS RESULTS ARE UNEXPECTED PLEASE CONTACT THE LABORATORY.
• ALL THE CONGENITAL ANAMOLIES IN THE FETUS MAY NOT BE DIAGNOSED IN ULTRASONOGRAPHY. • THIS REPORT IS NOT VALID FOR MEDICOLEGAL PURPOSE.

Licensee : Bharti Medicare Pvt. Ltd. The Apollo Clinic, C-70, Major Sudesh Kumar Marg, Opp. Madhav Park, Near Main Market, Rajouri Garden, New Delhi-110 027
Phone : (011) 2591 8222 / 8333 / 8444, 9811061009, E-mail : rajourigarden@theapolloclinic.com, Website : www.apolloclinicrajourigarden.com

MSME UAM NO. : DL11E0021531

Patient Name : Mr. Arvinder Pal Singh
UHID/MR No. : FRAJ.0000243507
Visit Date : 09-03-2024 12:35
Sample Collected on : 09-03-2024 12:38
Ref Doctor : SELF
Emp/Auth/TPA ID : 659789+drt
Sponsor Name : MEDIWHEELS HEALTH CARE

Age / Gender : 53Y/Male
OP Visit No : FRAJOPV119062
Reported on : 09-03-2024 15:58
Specimen : Whole Blood (Edta)
Pres Doctor: :


DEPARTMENT OF LABORATORY MEDICINE

TEST NAME	RESULT	BIOLOGICAL REFERENCE INTERVALS	UNITS
COMPLETE BLOOD COUNT			
Hb (Haemoglobin) Method: Non Cyanide	14.4	13 - 18	gm/dl
PCV/Haematocrit Method: RBC pulse height detect	43.6	40 - 50	%
ESR. Method: Westergren's Method	10	0 - 20	mm/1st Hr
TLC Method: DC Detection Method	5900	4000 - 10000	/cumm.
RBC COUNT. Method: DC Detection Method	4.8*	5 - 6	Million/cmm
PLATELET COUNT Method: DC Detection Method	2.22	1.5 - 4.1	lakh/cumm.
MCV Method: Derived	89.3	77 - 98	fl
MCH Method: Derived	29.6	27 - 32	pg
MCHC Method: Derived	33.1	31.5 - 34.5	gm/dl
NEUTROPHIL Method: Microscopy	62	40 - 70	%
LYMPHOCYTE Method: Microscopy	28	20 - 40	%
EOSINOPHIL Method: Microscopy	06	1.0 - 6.0	%
MONOCYTE Method: Microscopy	04	2.0 - 10.0	%
BLOOD GROUP AND RH TYPE			
ABO Group	B		
RH	Negative		

End of the report

Results are to be correlated clinically

Lab Technician / Technologist
Yogita


 Dr. Prashant Purwar
 MBBS, DCP
 Consultant Pathologist

• CLINICAL CORRELATION IS ESSENTIAL FOR FINAL DIAGNOSIS. • IF THE TESTS RESULTS ARE UNEXPECTED PLEASE CONTACT THE LABORATORY.
 • ALL THE CONGENITAL ANOMOLIES IN THE FETUS MAY NOT BE DIAGNOSED IN ULTRASONOGRAPHY. • THIS REPORT IS NOT VALID FOR MEDICOLEGAL PURPOSE.

Licensee : Bharti Medicare Pvt. Ltd. The Apollo Clinic, C-70, Major Sudesh Kumar Marg, Opp. Madhav Park, Near Main Market, Rajouri Garden, New Delhi-110 027
 Phone : (011) 2591 8222 / 8333 / 8444, 9811061009, E-mail : rajourigarden@theapolloclinic.com, Website : www.apolloclinicrajourigarden.com

MSME UAM NO. : DL11E0021531

Patient Name : Mr. Arvinder Pal Singh
 UHID/MR No. : FRAJ.0000243507
 Visit Date : 09-03-2024 12:35
 Sample Collected on : 09-03-2024 12:38
 Ref Doctor : SELF
 Emp/Auth/TPA ID : 659789+drt
 Sponsor Name : MEDIWHEELS HEALTH CARE

Age / Gender : 53Y/Male
 OP Visit No : FRAJOPV119062
 Reported on : 10-03-2024 12:35
 Specimen : Plasma(Fluoride)
 Pres Doctor: :


DEPARTMENT OF LABORATORY MEDICINE

TEST NAME	RESULT	BIOLOGICAL REFERENCE INTERVALS	UNITS
GLUCOSE - (FASTING)			
GLUCOSE - (FASTING) Method: (GOD-POD).	112*	70 - 110	mg/dL
GLUCOSE - (POST PRANDIAL)			
GLUCOSE - (POST PRANDIAL) Method: (GOD-POD)	140	70-140	mg/dl
GLYCOSYLATED HEMOGLOBIN (HBA1C)			
GLYCOSYLATED HEMOGLOBIN (HBA1C) - WHOLE BLOOD Method: BORONATE AFFINITY	6.0	4.2 - 6.0	%
LIPID PROFILE TEST (PACKAGE)			
CHOLESTEROL Method: CHOD - PAP	176	Desirable < 200 Borderline High : 200-239 High : > 240	mg/dl
Triglyceride Method: GPO-PAP	193	50-200	mg/dl
HDL Method: DIRECT	59.6*	30 - 50	mg/dl
LDL Method: DIRECT	77.8	60 - 100	mg/dl
VLDL Method: Calculated	38.6	<40	mg/dl
CHOLESTEROL / HDL RATIO Method: Calculated.	2.9	0 - 4.5	

End of the report

Results are to be correlated clinically

Lab Technician / Technologist
 Dr_Prashant


 Dr. Prashant Purwar
 MBBS, DCP
 Consultant Pathologist

• CLINICAL CORRELATION IS ESSENTIAL FOR FINAL DIAGNOSIS. • IF THE TESTS RESULTS ARE UNEXPECTED PLEASE CONTACT THE LABORATORY.
 • ALL THE CONGENITAL ANOMALIES IN THE FETUS MAY NOT BE DIAGNOSED IN ULTRASONOGRAPHY. • THIS REPORT IS NOT VALID FOR MEDICOLEGAL PURPOSE

Licensee : Bharti Medicare Pvt. Ltd. The Apollo Clinic, C-70, Major Sudesh Kumar Marg, Opp. Madhav Park, Near Main Market, Rajouri Garden, New Delhi-110 027
 Phone : (011) 2591 8222 / 8333 / 8444, 9811061009, E-mail : rajourigarden@theapolloclicin.com, Website : www.apolloclicinrajourigarden.com

MSME UAM NO. : DL11E0021531

Patient Name : Mr. Arvinder Pal Singh
 UHID/MR No. : FRAJ.0000243507
 Visit Date : 09-03-2024 12:35
 Sample Collected on : 09-03-2024 12:38
 Ref Doctor : SELF
 Emp/Auth/TPA ID : 659789+drt
 Sponsor Name : MEDIWHEELS HEALTH CARE

Age / Gender : 53Y/Male
 OP Visit No : FRAJOPV119062
 Reported on : 10-03-2024 12:49
 Specimen : Serum
 Pres Doctor: :


DEPARTMENT OF LABORATORY MEDICINE

TEST NAME	RESULT	BIOLOGICAL REFERENCE INTERVALS	UNITS
LIVER FUNCTION TEST (PACKAGE)			
BILIRUBIN - TOTAL. Method: Jendrassik	0.53	0.1 - 1.3	mg/dl
Bilirubin (Direct)-Serum Method: Diazo.	0.15	0 - 0.3	mg/dl
A/G Method: Calculated	1.3	1.0 - 2.0	
BILIRUBIN - INDIRECT. Method: Calculated.	0.38	<1.1	
SGOT /AST Method: IFCC (With P5P)	33.0	0 - 35	U/L
SGPT/ALT Method: IFCC (With P5P)	26.9	0 - 45	U/L
ALKALINE PHOSPHATE Method: AMP BUFFER	57.0	30 - 117	U/L
GGT. Method: SZAZ	36.8	10 - 50	U/L
TOTAL PROTEIN Method: Biuret	7.3	5.8-8.0	g/dl
ALBUMIN Method: BCG	4.2	3.7-5.2	g/dl
GLOBULIN Method: Calculated	3.1	2.5 - 3.5	mg/dL
Thyroid Profile 2(Free T4, Free T3 And TSH)			
Serum FT3	4.2	3.2 - 5.9	pmol/l
Serum FT4	14.9	10.6 - 21.0	pmol/l
Serum TSH	3.7	0.38 - 5.0	uIU/ml

End of the report

Results are to be correlated clinically

Lab Technician / Technologist
Dr_Prashant


Dr. Prashant Purwar
MBBS, DCP
Consultant Pathologist

• CLINICAL CORRELATION IS ESSENTIAL FOR FINAL DIAGNOSIS. • IF THE TESTS RESULTS ARE UNEXPECTED PLEASE CONTACT THE LABORATORY.
 • ALL THE CONGENITAL ANAMOLIES IN THE FETUS MAY NOT BE DIAGNOSED IN ULTRASONOGRAPHY. • THIS REPORT IS NOT VALID FOR MEDICOLEGAL PURPOSE.

Licensee : Bharti Medicare Pvt. Ltd. The Apollo Clinic, C-70, Major Sudesh Kumar Marg, Opp. Madhav Park, Near Main Market, Rajouri Garden, New Delhi-110 027
 Phone : (011) 2591 8222 / 8333 / 8444, 9811061009, E-mail : rajourigarden@theapolloclinic.com, Website : www.apolloclinicrajourigarden.com


MSME UAM NO. : DL11E0021531

Patient Name : Mr. Arvinder Pal Singh
UHID/MR No. : FRAJ.0000243507
Visit Date : 09-03-2024 12:35
Sample Collected on : 09-03-2024 12:38
Ref Doctor : SELF
Emp/Auth/TPA ID : 659789+drt
Sponsor Name : MEDIWHEELS HEALTH CARE

Age / Gender : 53Y/Male
OP Visit No : FRAJOPV119062
Reported on : 10-03-2024 12:51
Specimen : Serum
Pres Doctor: :

Results are to be correlated clinically

Lab Technician / Technologist
Dr_Prashant


Dr. Prashant Purwar
MBBS, DCP
Consultant Pathologist

• CLINICAL CORRELATION IS ESSENTIAL FOR FINAL DIAGNOSIS. • IF THE TESTS RESULTS ARE UNEXPECTED PLEASE CONTACT THE LABORATORY.
• ALL THE CONGENITAL ANAMOLIES IN THE FETUS MAY NOT BE DIAGNOSED IN ULTRASONOGRAPHY. • THIS REPORT IS NOT VALID FOR MEDICOLEGAL PURPOSE.

Licensee : Bharti Medicare Pvt. Ltd. The Apollo Clinic, C-70, Major Sudesh Kumar Marg, Opp. Madhav Park, Near Main Market, Rajouri Garden, New Delhi-110 027
Phone : (011) 2591 8222 / 8333 / 8444, 9811061009, E-mail : rajourigarden@theapolloclinik.com, Website : www.apolloclinikrajourigarden.com

MSME UAM NO. : DL11E0021531

Patient Name : Mr. Arvinder Pal Singh
UHID/MR No. : FRAJ.0000243507
Visit Date : 09-03-2024 12:35
Sample Collected on : 09-03-2024 12:38
Ref Doctor : SELF
Emp/Auth/TPA ID : 659789+drt
Sponsor Name : MEDIWHEELS HEALTH CARE

Age / Gender : 53Y/Male
OP Visit No : FRAJOPV119062
Reported on : 09-03-2024 16:16
Specimen : Urine
Pres Doctor: :

DEPARTMENT OF LABORATORY MEDICINE

URINE ROUTINE EXAMINATION


URINE EXAMINATION TEST REPORT

Test Name	Observed Value	Unit	Reference Range
Urine R/M Examination			
Quantity	30	ml.	
Colour	Pale Yellow		Pale Yellow
Transparency	Clear		Clear
Urine Specific Gravity	1.020		1.005 - 1.030
Dipstick			
pH	6.0		5.5 - 7.5
Dipstick / pH paper			
Chemical Examination			
Protein	Nil		Nil
Dipstick/Heat & acetic acid			
Sugar	Nil		Nil
Dipstick/Benedicts reagent			
Microscopic Examination			
Pus Cells	2-4	/HPF	1-2
RBC'S	Nil	/HPF	Nil
Casts	Nil	/HPF	Nil
Crystals	Nil		Nil
Epithelial Cells	2-4	/HPF	1-2
Bacteria	Nil	/HPF	Nil

End of the report

Results are to be correlated clinically

Lab Technician / Technologist
Dr. Prashant


Dr. Prashant Purwar
MBBS, DCP
Consultant Pathologist

• CLINICAL CORRELATION IS ESSENTIAL FOR FINAL DIAGNOSIS. • IF THE TESTS RESULTS ARE UNEXPECTED PLEASE CONTACT THE LABORATORY.
 • ALL THE CONGENITAL ANAMOLIES IN THE FETUS MAY NOT BE DIAGNOSED IN ULTRASONOGRAPHY. • THIS REPORT IS NOT VALID FOR MEDICOLEGAL PURPOSE.

Licensee : Bharti Medicare Pvt. Ltd. The Apollo Clinic, C-70, Major Sudesh Kumar Marg, Opp. Madhav Park, Near Main Market, Rajouri Garden, New Delhi-110 027
 Phone : (011) 2591 8222 / 8333 / 8444, 9811061009, E-mail : rajourigarden@theapolloclinic.com, Website : www.apolloclinicrajourigarden.com

MSME UAM NO. : DL11E0021531

Patient Name	: Mr. Arvinder Pal Singh	MR No	: FRAJ.0000243507
Age/Sex	: 53 Y/M	Visit No	: FRAJOPV119062
Pres Doctor	:	Bill Date	: 09-03-2024 12:36
Ref.by	: SELF	Report Date	: 10-03-2024 11:53

X-RAY CHEST PA VIEW

- Both lungs fields do not show any active parenchymal lesion.
- Both costophrenic angles are normal.
- B/L hila appear normal in size & density.
- Both domes of diaphragm are normal.
- Cardiac silhouette appears normal.
- Visualised soft tissues and bony cage appear normal.

IMPRESSION:- NORMAL STUDY.

To be correlate clinically.


Dr. Rahul Gera
Consultant Radiologist.