



YASHFEEN CARDIAC HOSPITAL™


At. & Po. Viraval, Navsari. 396 445. Phone (H) (02637) 235725
Website : www.yashfeenhospital.in E-mail : info@yashfeenhospital.in
(For Laboratory Reports Only)



Patient Name : KAJALBEN NATUBHAI PATEL+ Age : 30 Years Sex : F
Ref By Dr. : - Area : Valsad Date : 10/08/2024
Sample Time : 10/08/2024 09:38 No : 19 Time : 1:06PM

HAEMOGRAM

Test	Findings	UOM	Normal Range
HAEMOGLOBIN	13.6	g/dl	M-13.5-17.0 gm/dl F-11.5-15.5 gm/dl
HAEMOGRAM			
RED BLOOD CELL	4.27	10 ⁶ /μL	3.76-5.70
TOTAL LEUCOCYTE COUNT	6600	10 ³ /μL	4,000-11,000cells/cumm
Differential Count			
Neutrophil	58	%	40-75 %
Lymphocytes	38	%	20-40 %
Eosinophil	1	%	01-06 %
Monocytes	3	%	02-10 %
Basophils	0	%	00-00 %
PLATELET COUNT	235000	10 ³ /μL	1.5-5.5 Lacs/cumm
RBC INDICES			
P.C.V.	38.6	%	Male-40-56%, Female-37-47%
M.C.V.	90.4	fL	76.0-94.0
M.C.H.	31.8	pg	27.0-30.0
M.C.H.C.	35.2	g/dl	30.0-35.0
BLOOD GROUP	" B "	-	-
RH FACTOR	POSITIVE	-	-
E.S.R.(1 hour)	2	mm/hr.	Male-5-10 mm/hr, Female-5-20 mm/hr



P. Chaudhari
Dr. PIYUSH B. CHAUDHARI
M.D. Medicine
Reg. No. G-21518

Remarks

Designed By : Sarita Infotech Pvt. Ltd., Navsari

Yashfeen Cardiac Hospital

Signature
signature

Thanks for Reference

Technician



YASHFEEN CARDIAC HOSPITAL™


At. & Po. Viraval, Navsari. 396 445. Phone (H) (02637) 235725
Website : www.yashfeenhospital.in E-mail : info@yashfeenhospital.in
(For Laboratory Reports Only)



Patient Name : KAJALBEN NATUBHAI PATEL+ Age : 30 Years Sex : F
Ref By Dr. : - Area : Valsad Date : 10/08/2024
Sample Time : 10/08/2024 09:38 No : 19 Time : 1:06PM

HAEMOGLOBIN A1 C ESTIMATION

Test	Findings	UOM	Normal Range
Hb A1C	5.1	%	>8 :Action Suggested, 7-8 :Good Control, <7 :Goal, 6-7 :Near Normal Glycemia, <6 :Non-diabetic Level
Technique METHOD - HPLC		-	
Mean Blood Glucose	100.2	mg/dL	



P. Chaudhari
Dr. PIYUSH B. CHAUDHARI
M.D. Medicine
Reg. No. G-21518

Remarks

Designed By : Santa Infotech Pvt. Ltd., Navsari

Yashfeen Cardiac Hospital

H. Patel
signature

Thanks for Reference

Technician



YASHFEEN CARDIAC HOSPITAL™

At. & Po. Viraval, Navsari. 396 445. Phone (H) (02637) 235725

Website : www.yashfeenhospital.in E-mail : info@yashfeenhospital.in
(For Laboratory Reports Only)



Patient Name : KAJALBEN NATUBHAI PATEL+

Age : 30 Years Sex : F

Ref By Dr. : -

Area : Valsad Date : 10/08/2024

Sample Time : 10/08/2024 09:38 No : 19

Time : 1:06PM

LIPID PROFILE TEST REPORT

Test	Findings	UOM	Normal Range
S.CHOLESTEROL	143.3	mg/dL	<200:Desirable, 200-239:Borderline High, >=240:High
HDL CHOLESTEROL	41.7	mg/dL	<40:Low(High Risk), >=60:High(Low Risk)
LDL CHOLESTEROL	99.8	mg/dL	<100.0: Optimal, 100.0-129.0: Nearoptimal/ Aboveoptimal, 130.0-159.0:Borderline High, 160.0-189.0:High, >=190.0:Very High
VLDL CHOLESTEROL	15.1	mg/dL	Upto 40.0 mg/dL
S.TRIGLYCERIDES	75.7	mg/dL	<150.0:Normal, 150.0-199.0:Borderline high, 200.0-499.0:High, >=500.0:Very High
CHOL/ HDL RATIO	3.4	mg/dL	LESS THAN 5.0
LDL/ HDL RATIO	2.4	mg/dL	LESS THAN 5.0



f. deee
Dr. PIYUSH B. CHAUDHARI
M. D. Medicine
Reg. No. G-21518

Remarks

Designed By : Sarita Infotech Pvt. Ltd., Navsari

Yashfeen Cardiac Hospital

Signature
signature

Thanks for Reference

Technician



YASHFEEN CARDIAC HOSPITAL™

At. & Po. Viraval, Navsari. 396 445. Phone (H) (02637) 235725

Website : www.yashfeenhospital.in E-mail : info@yashfeenhospital.in
(For Laboratory Reports Only)



Patient Name : KAJALBEN NATUBHAI PATEL+
Ref By Dr. : -
Sample Time : 10/08/2024 09:38 No : 19

Age : 30 Years Sex : F
Area : Valsad Date : 10/08/2024
Time : 1:06PM

LIVER FUNCTION TEST REPORT

Test	Findings	UOM	Normal Range
TOTAL BILIRUBIN	0.8	mg/dL	0-1.0 mg/dL
DIRECT BILIRUBIN	0.3	mg/dL	0-0.8 mg/dL
INDIRECT BILIRUBIN	0.5	mg/dL	0-0.2 mg/dL
SGPT	10.9	U/L	Below 40.0 U/L
S.ALKALINE PHOSPHATASE	56.4	U/L	Child-170.0-515.0 U/L, Adults-37.0-147.0 U/L
TOTAL PROTEIN	6.9	g/dl	6.0-8.0 g/dl
ALBUMIN	4.5	g/dl	3.0-5.0 g/dl
GLOBULIN	2.4	g/dl	3.0-3.5 g/dl
A/G	1.9	g/dl	
SGOT	11.3	U/L	Below 40.0 U/L



P. Chaudhary
Dr. PIYUSH B. CHAUDHARI
M.D. Medicine
Reg. No. G-21518

Remarks

Designed By : Sarita Infotech Pvt. Ltd., Navsari

Yashfeen Cardiac Hospital

Signature
Signature

Thanks for Reference

Technician



YASHFEEN CARDIAC HOSPITAL™

At. & Po. Viraval, Navsari. 396 445. Phone (H) (02637) 235725
Website : www.yashfeenhospital.in E-mail : info@yashfeenhospital.in
(For Laboratory Reports Only)



Patient Name : KAJALBEN NATUBHAI PATEL+
Ref By Dr. : -
Sample Time : 10/08/2024 09:39 No : 19

Age : 30 Years Sex : F
Area : Valsad Date : 10/08/2024
Time : 1:07PM

BIOCHEMICAL TEST REPORT

Test	Findings	UOM	Normal Range
S.CREATININE	0.5	mg/dL	Male-0.9-1.4 mg/dL, Female-0.8-1.2 mg/dL
S.URIC ACID	2.9	mg/dL	Male:3.5-7.2 mg/dL, Female:2.6-6.0 mg/dL
BLOOD UREA NITROGEN	3.2	mg/dL	4.7-23.0 mg/dL



P. Chaudhari
Dr. PIYUSH B. CHAUDHARI
M.D. Medicine
Reg. No. G-21518

Remarks

Designed By : Sarita Infotech Pvt. Ltd., Navsari

Yashfeen Cardiac Hospital

Signature
Signature

Thanks for Reference

Technician



YASHFEEN CARDIAC HOSPITAL™

At. & Po. Viraval, Navsari. 396 445. Phone (H) (02637) 235725
Website : www.yashfeenhospital.in E-mail : info@yashfeenhospital.in
(For Laboratory Reports Only)



Patient Name : KAJALBEN NATUBHAI PATEL+ Age : 30 Years Sex : F
Ref By Dr. : - Area : Valsad Date : 10/08/2024
Sample Time : 10/08/2024 09:39 No : 19 Time : 1:07PM

BLOOD SUGAR TEST REPORT

Test	Findings	UOM	Normal Range
FASTING BLOOD SUGAR	93.1	mg/dl.	70-110 mg/dL
FASTING URINE SUGAR	NIL	-	NIL
POSTPANDRIAL BLOOD SUGAR	118.0	mg/dL	70-140 mg/dL
POSTPANDRIAL URINE SUGAR	NIL	-	NIL



P. Chaudhary
Dr. PIYUSH B. CHAUDHARI
M.D. Medicine
Reg. No. G-21513

Remarks

Designed By : Sarita Infotech Pvt. Ltd., Navsari

Yashfeen Cardiac Hospital

[Signature]
signature

Thanks for Reference

Technician



YASHFEEN CARDIAC HOSPITAL™

At. & Po. Viraval, Navsari. 396 445. Phone (H) (02637) 235725

Website : www.yashfeenhospital.in E-mail : info@yashfeenhospital.in
(For Laboratory Reports Only)



Patient Name : KAJALBEN NATUBHAI PATEL+
Ref By Dr. : -
Sample Time : 10/08/2024 09:40 No : 19


Age : 30 Years Sex : F
Area : Valsad Date : 10/08/2024
Time : 1:07PM

THYROID FUNCTION TEST REPORT

Test	Findings	UOM	Normal Range
T3 (TRIODOXYRONE)	1.25	ng/ml	Newborns:0.73-2.88, 6 Days-3 Months:0.80-2.75, 4-12Months:0.86-2.65, 1-6 Years:0.92-2.48, 7-11 Years:0.93-2.31, 12-20Years:0.91-2.18, Adults:0.80-2.00
T4(THYROXINE)	8.59	µg/dl	Newborns:5.04-18.5, 6 Days-3 Months:5.41-17.0, 4-12 Months:5.67-16.0, 1-6 Years:5.95-14.7, 7-11 Years:5.99-13.8, 12-20 Years:5.91-13.2, Adults:5.10-14.1
TSH	3.34	µIU/ml	Newborns:0.70-15.2, 6 Days-3 Months:0.72-11.0, 4-12 Months:0.73-8.35, 1-6 Years:0.70-5.97, 7-11 Years:0.60-4.84, 12-20 Years:0.51-4.30, Adults:0.27-4.20

TECHNIQUE

ELECTROCHEMILUMINESCENCE



P. Chaudhari
Dr. PIYUSH B. CHAUDHARI
M.D. Medicine
Reg. No. G-21518

Remarks

Designed By : Sarita Infotech Pvt. Ltd., Navsari

Yashfeen Cardiac Hospital

Signature
signature

Thanks for Reference

Technician



YASHFEEN CARDIAC HOSPITAL™

At. & Po. Viraval, Navsari. 396 445. Phone (H) (02637) 235725

Website : www.yashfeenhospital.in E-mail : info@yashfeenhospital.in
(For Laboratory Reports Only)



Patient Name : KAJALBEN NATUBHAI PATEL+

Age : 30 Years Sex : F

Ref By Dr. : -

Area : Valsad Date : 10/08/2024

Sample Time : 10/08/2024 09:40 No : 19

Time : 1:07PM

GGT TEST REPORT

Test	Findings	UOM	Normal Range
SERUM GGT	38.0	U/L	10.0-71.0 U/L



P. Chaudhari
Dr. PIYUSH B. CHAUDHARI
M.D. Medicine
Reg. No. G-21518

Remarks

Designed By : Sarita Infotech Pvt. Ltd., Navsari

Yashfeen Cardiac Hospital

[Signature]
signature

Thanks for Reference

Technician



YASHFEEN CARDIAC HOSPITAL™

At. & Po. Viraval, Navsari. 396 445. Phone (H) (02637) 235725

Website : www.yashfeenhospital.in E-mail : info@yashfeenhospital.in
(For Laboratory Reports Only)



Patient Name : KAJALBEN NATUBHAI PATEL+
Ref By Dr. : -
Sample Time : 10/08/2024 09:40 No : 19

Age : 30 Years Sex : F
Area : Valsad Date : 10/08/2024
Time : 1:07PM

ROUTINE URINE ANALYSIS

Test	Findings	UOM	Normal Range
<u>PHYSICAL EXAMINATION</u>			
Quantity	-	-	
Colour	YELLOW	-	
Appearance	CLEAR	-	
Reaction	ALKALINE	-	
Sp. Gravity	1.005	-	
<u>CHEMICAL EXAMINATION</u>			
U.Albumin	NIL	-	
Sugar	NIL	-	
Acetone	NIL	-	
Bile Salt	NIL	-	
Bile Pigment	NIL	-	
Occult Blood	NIL	-	
<u>MICROSCOPIC EXAMINATION</u>			
Pus Cells	1-2	/hpf	
Epithelial cells	1-2	/hpf	
Red cells	ABSENT	/hpf	
Casts	-	/hpf	
Crystals	AMORPHOUS SEEN	/hpf	
Others	-	/hpf	



P. Chaudhari
Dr. PIYUSH B. CHAUDHARI
M.D. Medicine
Reg. No. G-21513

Remarks

Designed By : Sarita Infotech Pvt. Ltd., Navsari

Yashfeen Cardiac Hospital

Signature
Signature

Thanks for Reference

Technician

YASHFEEN IMAGING & RADIOLOGY DEPARTMENT

MANAGED BY :- YASHFEEN FOUNDATION

VIRAVAL, NAVSARI. 396 445. PHONE : (H) (02637) 235725

Website : www.yashfeenhospital.in E-mail : info@yashfeenhospital.in

Name	KAJALBEN NATUBHAI PATEL	Age	30Y/F
Ref by Dr	SELF	Date	10/08/2024

USG ABDOMEN & PELVIS (SCREENING)(TVS)

Liver appears normal in size & shape with normal echopattern.
No e/o focal or diffuse lesion. IHBR appear normal.
PV and CBD appear normal.

Gall bladder appears distended & normal in shape & size. No e/o calculus or mass seen.
Walls appear normal.

Pancreas appears normal in size and echogenicity. No e/o focal or diffuse lesion.

Spleen appears normal in size and shows normal echopattern. No e/o focal lesion.

Both Kidneys appear normal in size and echopattern. CM Differentiation is preserved.
No e/o calculus or hydronephrosis on either side.
Perirenal spaces appear normal on either side.
Suprarenal regions appear normal on either side. No e/o mass lesion.

Bladder is empty (due to non-compliance of patient). Adv: Follow up USG with normally distended bladder.

Uterus appears anteverted, normal in size & shows 6 x 11 mm in size heterogeneously hypo echoic rounded lesion involving posterior wall.
Endometrial cavity is empty. ET- 10 mm.

Both ovaries appear normal in size & echopattern.
No e/o adnexal mass on either side.

RIF region appears normal.

No e/o ascites.

IMPRESSION:
Uterine fibroid.



Dr. DHARMESH DESAI
(M.D. Radiology)
Reg. No. G - 45284
Dr. Dharmesh Desai
YASHFEEN GROUP OF HOSPITAL

Please contact immediately for any typographical error.

This is only professional opinion, not a final diagnosis. Kindly correlate clinically. Not valid for medicolegal purpose.

KAJALBEN
 ID:
 DOB:
 Female, Unknown
 Med.:
 Location:
 Referring Physician:
 Notes:

10-08-2024 12:27:26

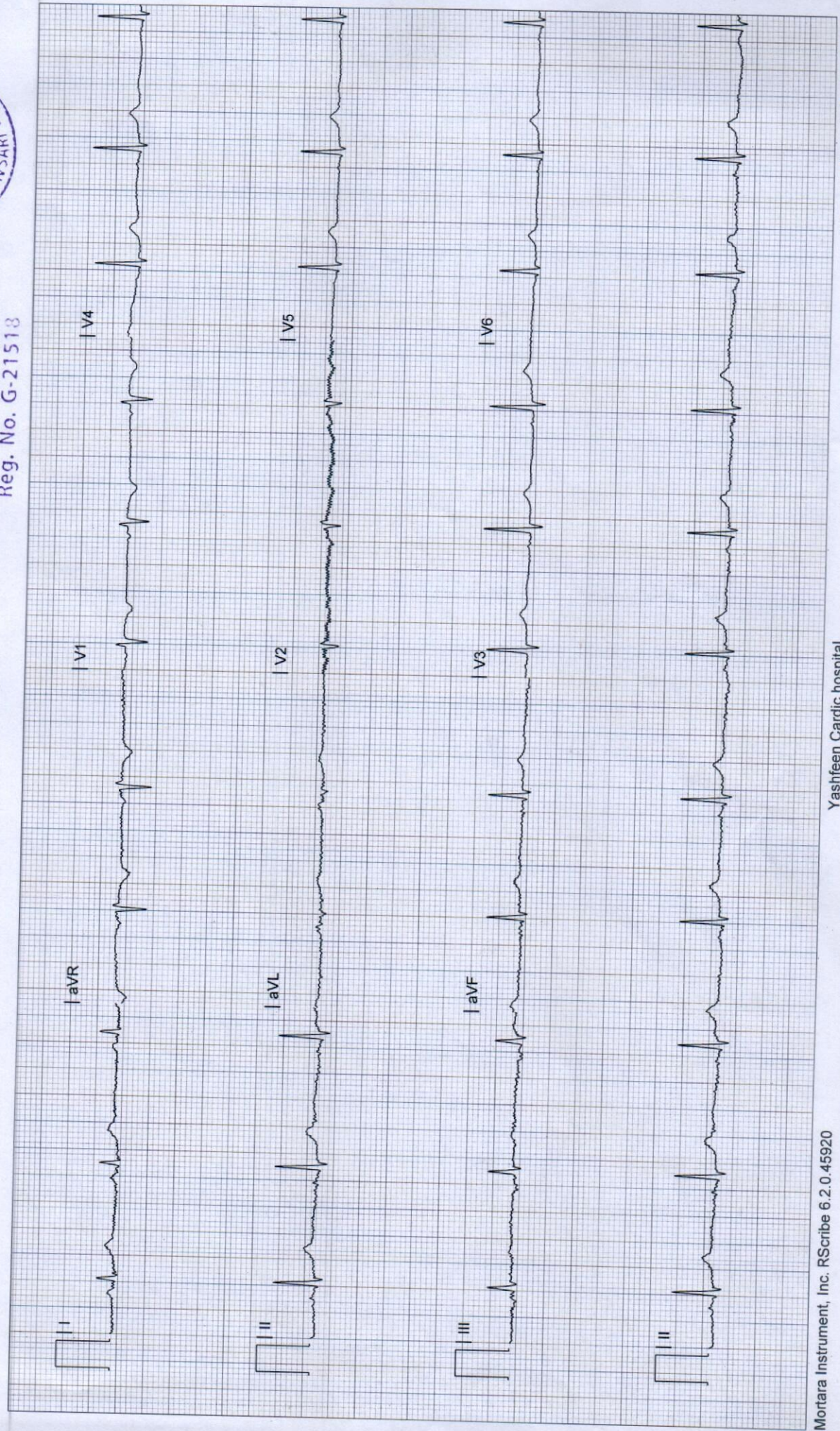
Vent. Rate: 63 BPM
 PR int: 117 ms
 QRS dur: 79 ms
 QT/QTc: 368/376 ms
 P-R-T axes: -5 71 47
 Avg. RR: 944 ms
 QTcB: 378 ms
 QTcf: 375 ms

SINUS RHYTHM WITH SINUS AR
 THMIA WITH SHORT PR INTERVAL
 POSSIBLE RIGHT VENTRICULAR
 CONDUCTION DELAY
 BORDERLINE ECG
 INTERPRETATION BASED ON A DEFAULT AGE OF 40 YEARS

UNCONFIRMED REPORT
 Reviewed by: *Asad*
Dr. PIYUSH B. CHAUDHARI
 M.D. Medicine
 Reg. No. G-21518



Signed by:
 Date:





(Regd. No. E / 1390 / Navsari)

YASHFEEN CARDIAC HOSPITAL™

MANAGED BY :- YASHFEEN FOUNDATION

VIRAVAL, NAVSARI. 396 445. PHONE : (H) (02637) 235725

Website : www.yashfeenhospital.in E-mail : info@yashfeenhospital.in

(Stationary For Report Only)

2D ECHO CARDIOGRAPHY COLOUR DOPPLER REPORT

Patient Name & No	: KAJALBEN NATUBHAI PATEL+ CH24017877	Age/Sex	UHID :	: 2274
Doctor	: Mohil Nagad	30/ F	No :	: 2209
Referred By	:		Date :	: 10/08/2024

M-Mode findings

LVIDd : 35mm
 LVIDs : 23mm
 IVSd : 09mm
 PWd : 09mm
 EF : 60%
 Aorta : 21mm
 LA : 28mm

2D Imaging

Aortic Valve : Trileaflet, Peak Gradient 7mmof Hg.
 Mitral Valve : Thin, Pliable, Normal Mobility, Normal function
 Tricuspid Valve : Mild TR
 Pulmonary Valve : Normal

=> : All cardiac chambers are normal sized.
 => : All cardiac valves are normal.
 => : No regional wall motion abnormality.
 => : Normal LV systolic function.
 => : Normal LV diastolic function.
 => : IAS/IVS intact.
 => : No obvious clots/ vegetations/ or effusion.
 => : IVC Normal size.

Doppler Findings

=> : No MS/MR, No TS/Mild TR, No AS/AR & No PS/PR
 Mitral inflow Pattern : E > A
 Tissue Doppler Findings : E' > A'

Impression : Normal LVEF:60%, No RWMA.



Report Prepared By

DR. Mobin Sheikh
 M.D. (Med) Senior Consultant
 M.D. (Phy) Dip. Cardiology
 Non-Invasive Cardiologist
 YASHFEEN HOSPITAL, NAVSARI

Designed By : Sarita Infotech Pvt. Ltd., Navsari

YASHFEEN IMAGING & RADIOLOGY DEPARTMENT

MANAGED BY :- YASHFEEN FOUNDATION

VIRAVAL, NAVSARI. 396 445. PHONE : (H) (02637) 235725

Website : www.yashfeenhospital.in E-mail : info@yashfeenhospital.in

Patient's Name:	KAJALBEN N. PATEL	Age & Sex:	30Yrs/F
Ref. by Dr.	SELF	Date:	10-08-2024

X RAY CHEST (PA VIEW)

Both lung fields appear normal.

Both hila appear normal.

Both CP angles appear clear.

Cardiac size appears within normal limit.


Both domes of diaphragm appear normal.

Bony thoracic cage appears normal.

IMPRESSION:

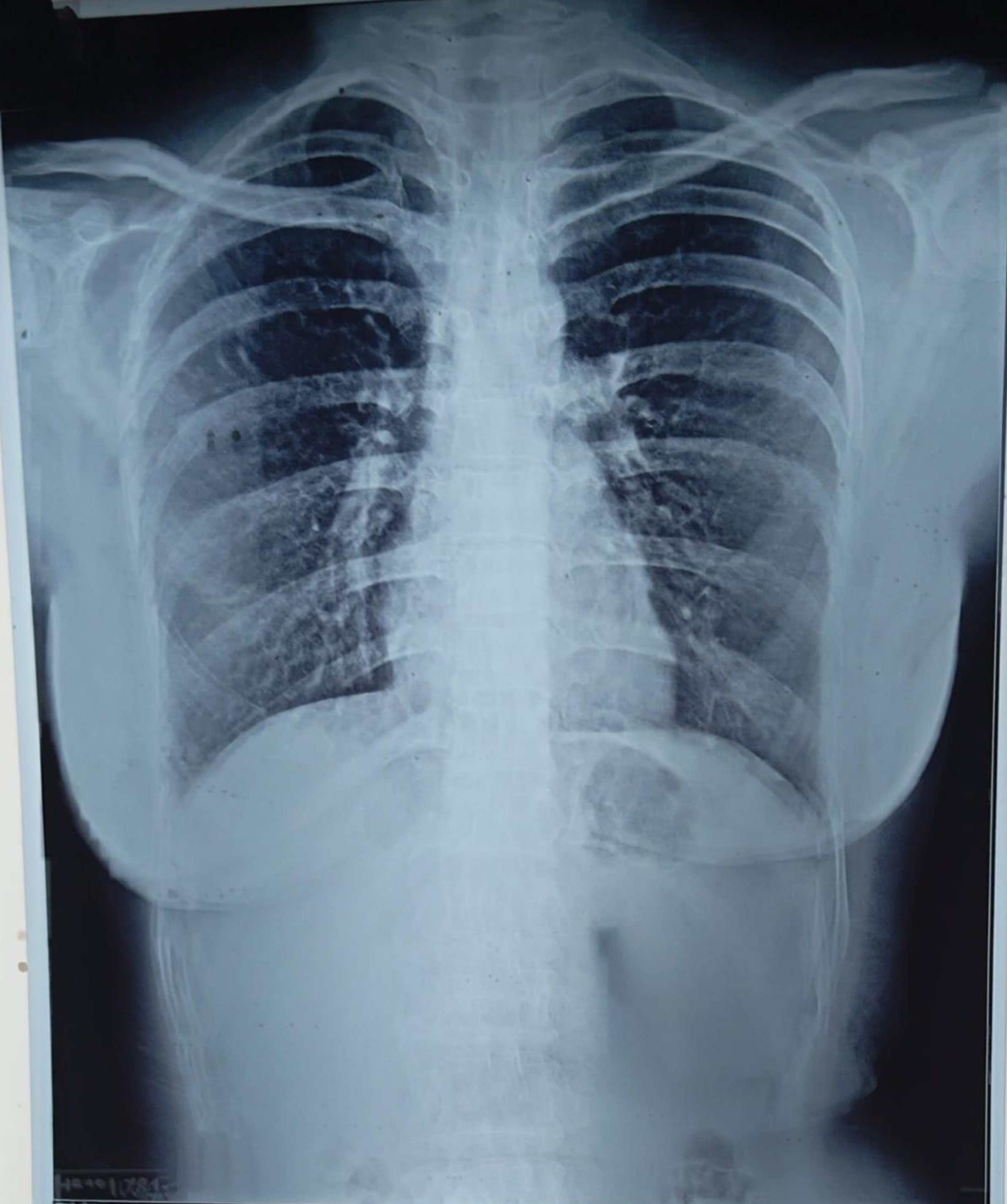
- Normal X-ray chest (PA view).




Dr. Dharmesh Desai
(M.D. Radiology)
MD
Reg. No. G - 45284
YASHFEEN GROUP OF HOSPITAL

Please contact immediately for any typographical error.

This is only professional opinion, not a final diagnosis. Kindly correlate clinically. Not valid for medicolegal purpose.



H24017877

H24017877 KAJALBEN N PATEL 30Y 100824242 ChestErect PA 10/08/2024

YASHFEEN GROUP OF HOSPITALS NAVSARI PH:9924047789