



CARE DIAGNOSTIC AND IMAGING CENTER

A- 7, Hanuman Nagar, Near HDFC Bank, Main Khatipura Road, Jaipur - 302021
Ph.: 0141-4025102 • E-mail : carecenterjaipur@gmail.com

General Physical Examination

Date of Examination: 10/08/2024

Name: LEKHA KVSHWAH Age: 36 year DOB: 11/06/1988 Sex: Female

Referred By:

Photo ID: UID Card ID# 1298

HT: (cm) 156 cm Wt: (Kg) 70 kg

Chest (Expiration): 97(cm) Abdomen Circumference: 94(cm)

Blood Pressure: 120/80 mm Hg PR: 78/min RR: 18/min Temp: Afebrile

BMI 28.8

Eye Examination: Lt eye -0.75 & Rt eye -1.0

Other: No-

On examination he/she appears physically and mentally fit: Yes / No

Signature Of Examine:

Name of Examiner
Dr. VIKRAM SINGH
M.B.B.S.
RMC Reg. No.-25097

Signature Medical Examiner:





CARE DIAGNOSTIC AND IMAGING CENTER

A- 7, Hanuman Nagar, Near HDFC Bank, Main Khatipura Road, Jaipur - 302021
Ph.: 0141-4025102 • E-mail : carecenterjaipur@gmail.com

Patient Name	Lekha Kushwah	Age/Sex	36 Yrs/F
Patient ID	05597	Date	10/8/2024
Referred By	Mediwheel		

SONOGRAPHY OF WHOLE ABDOMEN (FEMALE)

- LIVER** : Measures 152 mms. Is borderline enlarged in size and shows bright echotexture. No focal lesion seen.
Hepatic and portal venous systems are normal.
IHBR are not dilated.
Portal vein & CBD normal in caliber.
- GALL BLADDER** : Distended. Lumen is echofree.
- PANCREAS** : Is normal in size, shape and echotexture. Pancreatic duct is not dilated.
- SPLEEN** : Normal in size (97 mms), shape and echotexture.
- BOTH KIDNEYS** : Both kidneys are normal in size, shape ,position, outline and show normal corticomedullary differentiation.
Tiny 2-3 mm echogenic foci seen in middle and lower calyx of left kidney.
No evidence of hydronephrosis on either side or calculus on right side.
- U. BLADDER** Partially distended.
- UTERUS** Is normal in size and echotexture. No focal lesion seen.
ET – 5.6 mms
- OVARIES** Are normal in size, shape and echotexture.
No free fluid is seen in peritoneal cavity
- IMPRESSION:** **Borderline hepatomegaly with fatty liver.**
Left renal concretions.


Dr. Vikram Singh M.D.
Consultant Radiologist
RMC-No-25097/11212

DR. VIKRAM SINGH
M.D. (RADIODIAGNOSIS)
R.M.C. REG.-11212



CARE DIAGNOSTIC AND IMAGING CENTER

A- 7, Hanuman Nagar, Near HDFC Bank, Main Khatipura Road, Jaipur - 302021
Ph.: 0141-4025102 • E-mail : carecenterjaipur@gmail.com

Patient Name **Mrs LEKHA KUSHWAH**
Age & Sex **36 Years , Female**
Referred by **MEDIWHEEL**

Lab Regn No **05597**
Registration Date **10/08/2024 12:54**
Reporting Date **10/08/2024 15:22**

HAEMATOLOGY

Complete Blood Count With ESR

TEST NAME	RESULT	UNIT	NORMAL RANGE
Hb%	12.1	gms/dl	12 - 16 gms/dl
TLC	7.3	Th/mm ³	4.5 - 11 Th/mm ³
DLC			
Neutrophils	70	%	40 - 75 %
Lymphocytes	25	%	20 - 40 %
Eosinophils	03	%	01 - 06 %
Monocytes	02	%	02 - 10 %
Basophils	00	%	00 - 01 %
TRBC	4.09	mil/cu-mm	4.5 - 5.5 mil/cu-mm
Platelet Count APC	2.38	lakh/mm ³	1.5 - 4.5 lakh/mm ³
PCV	36.1	%	42 - 52 %
MCV	88.3	fl	82 - 94 fl
MCH	29.6	pg	27 - 32 pg
MCHC	33.5	g/lt	32 - 36 g/lt
ESR	15	mm/1Hr	4 - 20 mm/1Hr

-- End of Report --

Technologist

Dr. Nirish Agarwal
Pathologist
RMC No 12512

Dr. Nirish Agarwal
Pathologist
Reg. No. 12512

This is radiological / Pathological Impression & not the final Diagnosis. It should be Correlated with relevant clinical data & Investigations.
Not Valid for Medico-Legal Purpose • Subject to Jaipur Jurisdiction only.



CARE DIAGNOSTIC AND IMAGING CENTER

A- 7, Hanuman Nagar, Near HDFC Bank, Main Khatipura Road, Jaipur - 302021
Ph.: 0141-4025102 • E-mail : carecenterjaipur@gmail.com

Patient Name **Mrs LEKHA KUSHWAH**
Age & Sex **36 Years , Female**
Referred by **MEDIWHEEL**

Lab Regn No **05597**
Registration Date **10/08/2024 12:54**
Reporting Date **10/08/2024 15:22**

BIOCHEMISTRY

Lipid Profile Panel

TEST NAME	RESULT	UNIT	NORMAL RANGE
Triglycerides	110	mg/dl	Upto -160 mg/dl
Serum Cholesterol	155.0	mg/dl	Upto - 200 mg/dl
HDL Cholesterol	39.0	mg/dl	35 - 70 mg/dl
LDL Cholesterol	94.0	mg/dl	Upto - 130 mg/dl
VLDL Cholesterol	22.0	mg/dl	Upto - 60 mg/dl
CHOL/HDL RATIO	3.9	mg/dl	3.3-4.4 Low Risk 4.5-7.0 Avg.Risk 7.1-11.0 Mod.Risk >11.0 High Risk
LDL/HDL RATIO	2.41	mg/dl	0.5-3.0 Low Risk 3.1-6.0 Mod.Risk > 6.0 High Risk -- End of Report --

Technologist

Dr. Nirish Agarwal
Pathologist
RMC No 12512

Dr. Nirish Agarwal
Pathologist
Reg. No. 12512

This is radiological / Pathological Impression & not the final Diagnosis. It should be Correlated with relevant clinical data & Investigations.
Not Valid for Medico-Legal Purpose • Subject to Jaipur Jurisdiction only.



CARE DIAGNOSTIC AND IMAGING CENTER

A- 7, Hanuman Nagar, Near HDFC Bank, Main Khatipura Road, Jaipur - 302021

Ph.: 0141-4025102 • E-mail : carecenterjaipur@gmail.com

Patient Name	Mrs LEKHA KUSHWAH	Lab Regn No	05597
Age & Sex	36 Years , Female	Registration Date	10/08/2024 12:54
Referred by	MEDIWHEEL	Reporting Date	10/08/2024 15:22

BIOCHEMISTRY

Renal/Kidney Function Test

TEST NAME	RESULT	UNIT	NORMAL RANGE
Blood Urea	23.0	mg/dl	10 - 40 mg/dl
Creatinine	0.79	mg/dl	0.5 - 1.4 mg/dl
Calcium	9.45	mg/dl	8.5 - 11.0 mg/dl
Uric Acid	3.56	mg/dl	2.5 - 5.7 mg/dl
Sodium	140.0	mmoI/L	137 - 145 mmoI/L
Potassium	4.52	mmoI/L	3.5 - 5.5 mmoI/L
Choloride	102.0	mmoI/L	98 - 107 mmoI/L

BIOCHEMISTRY

Blood Glucose PP (2 Hours)

TEST NAME	RESULT	UNIT	NORMAL RANGE
Blood Sugar PP 2.00 Hr	228.0	mg/dl	80 - 145 mg/dl

BIOCHEMISTRY

Blood Glucose Fasting

TEST NAME	RESULT	UNIT	NORMAL RANGE
Blood Sugar Fasting	155.0	mg/dl	65 - 110 mg/dl

-- End of Report --

Technologist

Dr. Nirish Agarwal
Pathologist
RMC No 12512

Dr. Nirish Agarwal
Pathologist
Reg. No. 12512



CARE DIAGNOSTIC AND IMAGING CENTER

A- 7, Hanuman Nagar, Near HDFC Bank, Main Khatipura Road, Jaipur - 302021
Ph.: 0141-4025102 • E-mail : carecenterjaipur@gmail.com

Patient Name	Mrs LEKHA KUSHWAH	Lab Regn No	05597
Age & Sex	36 Years , Female	Registration Date	10/08/2024 12:54
Referred by	MEDIWHEEL	Reporting Date	10/08/2024 15:22

BIOCHEMISTRY

Liver Function Test

TEST NAME	RESULT	UNIT	NORMAL RANGE
Bilirubin			
Total	0.87	mg/dl	0.20 - 1.2 mg/dl
Direct	0.30	md/dl	0.1 - 0.3 md/dl
Indirect	0.57	mg/dl	0.2 - 0.9 mg/dl
SGOT	74.0	U/L	5 - 45 U/L
SGPT	86.63	U/L	6 - 45 U/L
Total Protein	7.0	gm/dl	6.0 - 8.3 gm/dl
Albumin	4.1	gm/dl	3.0 - 5.0 gm/dl
Globulin	2.9	gm/dl	2.0 - 3.0 gm/dl
A/G Ratio	1.41	mg/dl	1.0:1 - 2.5:1 mg/dl
Alkaline Phosphatase	266.0	IU/L	100 - 300 IU/L
Gamma GT	23.0	U/L	5 - 32 U/L

-- End of Report --

Technologist

Dr. Nirish Agarwal
Pathologist
RMC No 12512

Dr. Nirish Agarwal
Pathologist
Reg. No. 12512

This is radiological / Pathological Impression & not the final Diagnosis. It should be Correlated with relevant clinical data & Investigations.
Not Valid for Medico-Legal Purpose • Subject to Jaipur Jurisdiction only.



CARE DIAGNOSTIC AND IMAGING CENTER

A- 7, Hanuman Nagar, Near HDFC Bank, Main Khatipura Road, Jaipur - 302021
Ph.: 0141-4025102 • E-mail : carecenterjaipur@gmail.com

Patient Name	Mrs LEKHA KUSHWAH	Lab Regn No	05597
Age & Sex	36 Years , Female	Registration Date	10/08/2024 12:54
Referred by	MEDIWHEEL	Reporting Date	10/08/2024 17:02

HORMONES & MARKERS

Thyroid Profile

TEST NAME	RESULT	UNIT	NORMAL RANGE
T3	1.02	ng/ml	0.60 - 1.78 ng/ml
T4	8.24	µg/dl	4.50 - 12.23 µg/dl
TSH	4.12	µIU/ml	0.35 - 4.94 µIU/ml
-- End of Report --			

Technologist

Dr. Nirish Agarwal
Pathologist

RMC No 12512

Dr. Nirish Agarwal
Pathologist
Reg. No. 12512

This is radiological / Pathological Impression & not the final Diagnosis. It should be Correlated with relevant clinical data & Investigations.
Not Valid for Medico-Legal Purpose • Subject to Jaipur Jurisdiction only.



CARE DIAGNOSTIC AND IMAGING CENTER

A- 7, Hanuman Nagar, Near HDFC Bank, Main Khatipura Road, Jaipur - 302021

Ph.: 0141-4025102 • E-mail : carecenterjaipur@gmail.com

Patient Name	Mrs LEKHA KUSHWAH	Lab Regn No	05597
Age & Sex	36 Years , Female	Registration Date	10/08/2024 12:54
Referred by	MEDIWHEEL	Reporting Date	10/08/2024 15:22

CLINICAL PATHOLOGY

Clinical Pathology Tests

TEST NAME	RESULT	UNIT	NORMAL RANGE
Urine Sugar (Fasting)	TRACE		
Urine sugar PP 2.00 Hr	++		
-- End of Report --			

Technologist

Dr. Nirish Agarwal
Pathologist
RMC No 12512

Dr. Nirish Agarwal
Pathologist
Reg. No. 12512

This is radiological / Pathological Impression & not the final Diagnosis. It should be Correlated with relevant clinical data & Investigations.
Not Valid for Medico-Legal Purpose • Subject to Jaipur Jurisdiction only.



CARE DIAGNOSTIC AND IMAGING CENTER

A- 7, Hanuman Nagar, Near HDFC Bank, Main Khatipura Road, Jaipur - 302021
Ph.: 0141-4025102 • E-mail : carecenterjaipur@gmail.com

Patient Name **Mrs LEKHA KUSHWAH**
Age & Sex **36 Years , Female**
Referred by **MEDIWHEEL**

Lab Regn No **05597**
Registration Date **10/08/2024 12:54**
Reporting Date **10/08/2024 15:22**

CLINICAL PATHOLOGY

Urine Routine Examination

TEST NAME	RESULT	UNIT
Physical		
Colour	Pale Yellow	
Clarity	Clear	
Chemical		
Specific Gravity	1.010	
pH	5.0	
Albumin	NIL	
Sugar	TRACE	
Microscopic		
RBC /HPF	NIL	
WBC /HPF	2-3/HPF	
Epithelial Cells /HPF	2-4/HPF	
Casts	NIL	
Crystal	NIL	
Bacteria	NIL	
Others	NIL	

-- End of Report --

Technologist

Dr. Nirish Agarwal
Pathologist

Dr. Nirish Agarwal
Pathologist
Reg. No. 12512

This is radiological / Pathological Impression & not the final Diagnosis. It should be Correlated with relevant clinical data & Investigation
Not Valid for Medico-Legal Purpose • Subject to Jaipur Jurisdiction only.



CARE DIAGNOSTIC AND IMAGING CENTER

A- 7, Hanuman Nagar, Near HDFC Bank, Main Khatipura Road, Jaipur - 302021

Ph.: 0141-4025102 • E-mail : carecenterjaipur@gmail.com

Patient Name **Mrs LEKHA KUSHWAH**

Age & Sex **36 Years , Female**

Referred by **MEDIWHEEL**

Lab Regn No **05597**

Registration Date **10/08/2024 12:54**

Reporting Date **10/08/2024 17:02**

CYTOLOGY

Cytology Pap Smear

PAP SMEAR FOR CYTOLOGY EXAMINATION

Specimen - Conventional smear.
(Two unstained smears received)

Clinical history -

Adequacy - Satisfactory for opinion.

Microscopy:

H/E stained smear show predominantly superficial & intermediate squamous epithelial cells in the background of mild acute inflammation.

Endocervical cells- Not seen.

Epithelial cells abnormality -Not seen

IMPRESSION :Negative for intraepithelial lesion or malignancy (NILM).

Note: Please note papanicolaou smear study is a screening procedure for cervical cancer with inherent false negative result, hence should be interpreted with caution.

-- End of Report --

Technologist

Dr. Nirish Agarwal

Pathologist

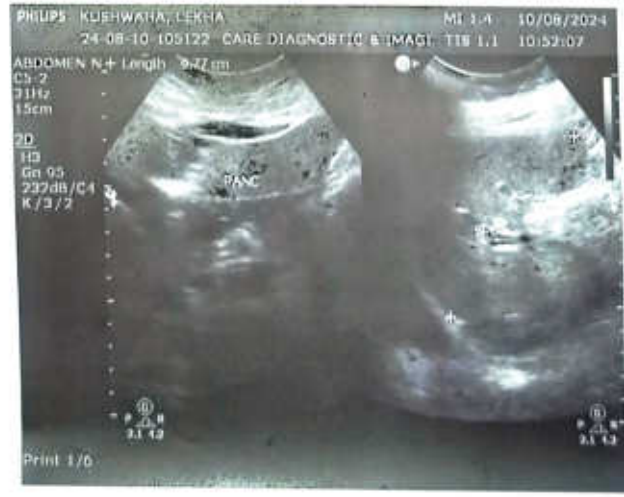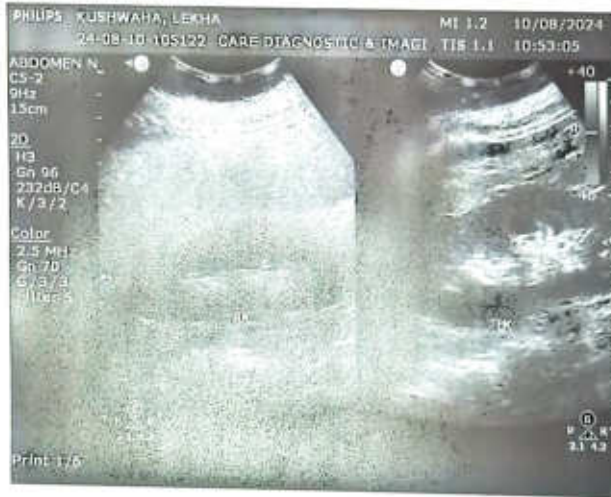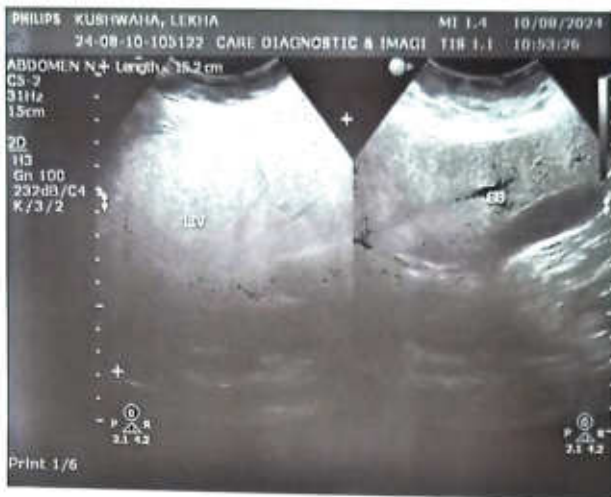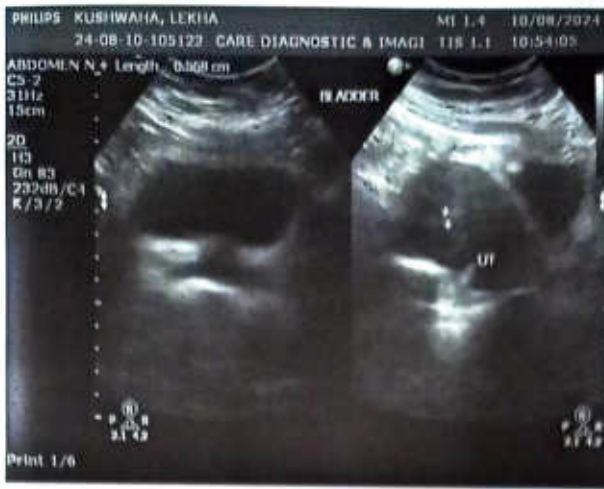RMC No 12512

Dr. Nirish Agarwal

Pathologist

Reg. No. 12512

This is radiological / Pathological Impression & not the final Diagnosis. It should be Correlated with relevant clinical data & Investigation.
Not Valid for Medico-Legal Purpose • Subject to Jaipur Jurisdiction only.





भारत सरकार

GOVERNMENT OF INDIA



लेखा कुशवाह

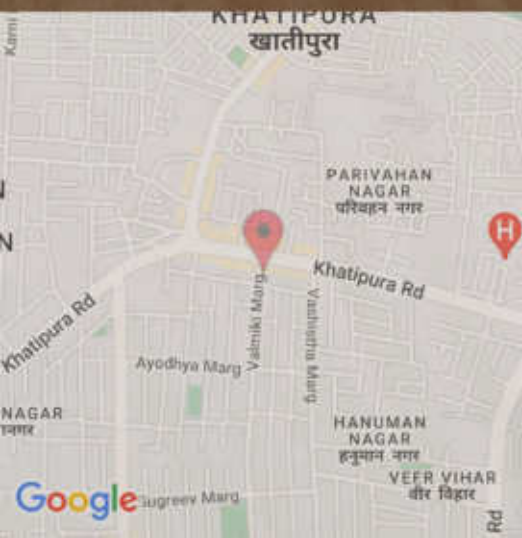Lekha Kushwah

जन्म तिथि/ DOB: 11/06/1988

महिला / FEMALE

1248

आधार - आम आदमी का अधिकार



A-7, 1st Floor, Hanuman Nagar, Main Khatipura Road, Vaishali Nagar, Jaipur, Rajasthan 302021, India

Jaipur
Rajasthan
India



26°C
79°F

2024-08-10(Sat) 11:49(am)



भारतीय विशिष्ट पहचान प्राधिकरण
UNIQUE IDENTIFICATION AUTHORITY OF INDIA

पता:

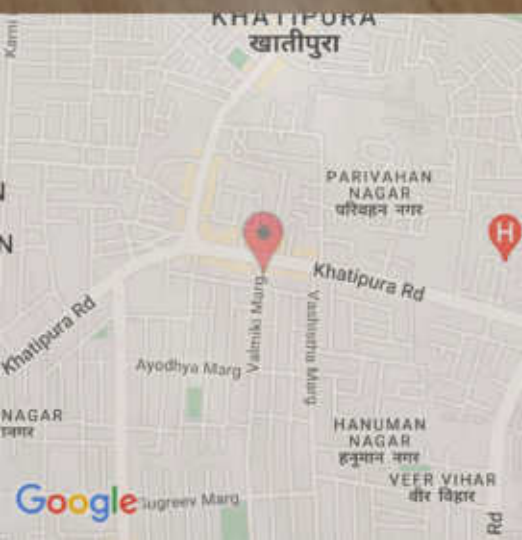W/O पवन कुमार कुशवाहा,
163, गली न 2, राज गुरु
मार्ग ,तीजा नगर , सिरसी
रोड, पंझ्यावाला, जयपुर,
राजस्थान - 302034

Address:

W/O Pawan Kumar Kushwaha, 163,
Gali No 2, Raj Guru Marg ,Teeja
Nagar , Sirsi Road, Panchyawala,
Jaipur,
Rajasthan - 302034

1248

Aadhaar-Aam Admi ka Adhikar



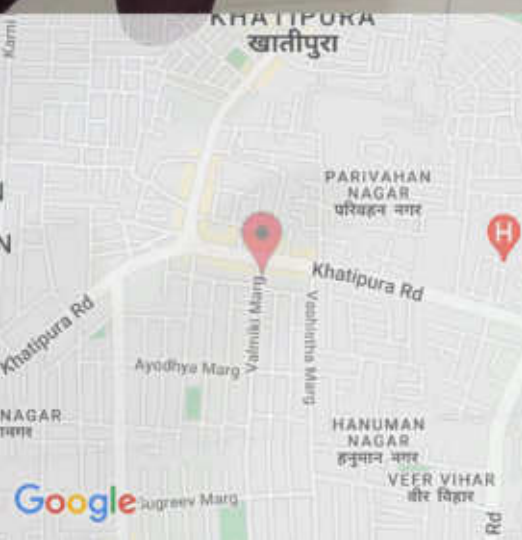
A-7, 1st Floor, Hanuman Nagar, Main Khatipura Road, Vaishali Nagar, Jaipur, Rajasthan 302021, India

Jaipur
Rajasthan
India



26°C
79°F

2024-08-10(Sat) 11:49(am)



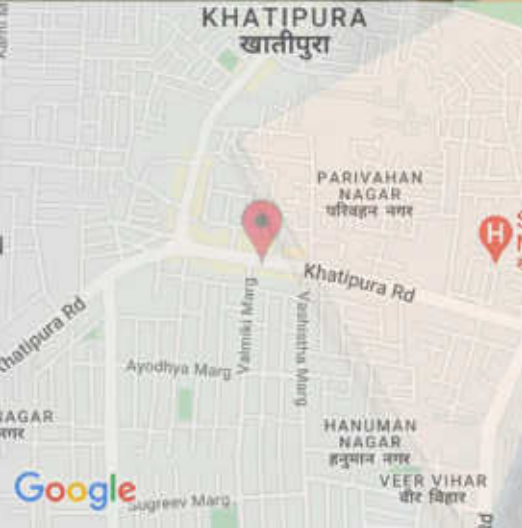A-7, 1st Floor, Hanuman Nagar, Main Khatipura Road, Vaishali Nagar, Jaipur, Rajasthan 302021, India

Jaipur
Rajasthan
India



26°C
79°F

2024-08-10(Sat) 11:49(am)



Hanuman Nagar eisrl road Khatipura, Hanuman Nagar, Jaipur, Rajasthan 302021, India

Jaipur
Rajasthan
India



26°C
79°F

2024-08-10(Sat) 11:49(am)



CARE DIAGNOSTIC AND IMAGING CENTER

A- 7, Hanuman Nagar, Near HDFC Bank, Main Khatipura Road, Jaipur - 302021

Ph.: 0141-4025102 • E-mail : carecenterjaipur@gmail.com

Patient Name **Mrs LEKHA KUSHWAH**
Age & Sex **36 Years , Female**
Referred by **MEDIWHEEL**

Lab Regn No **05597**
Registration Date **10/08/2024 12:54**
Reporting Date **10/08/2024 17:19**

GENERAL

HBA1c

TEST NAME	RESULT	UNIT	NORMAL RANGE
HBA1c	8.60	%	

REFERENCE RANGE

Normal Value	:	<	06.0 %
Good Control	:	6.0 % -	07.0 %
Fair Control	:	7.0 % -	08.0 %
Unsatisfactory Control	:	8.0 % -	10.0 %
Poor Control	:	>	10.0 %

-- End of Report --

Technologist

Dr. Nirish Agarwal
Pathologist
RMC No 12512

Dr. Nirish Agarwal
Pathologist
Reg. No. 12512

This is radiological / Pathological Impression & not the final Diagnosis. It should be Correlated with relevant clinical data & Investigation.
Not Valid for Medico-Legal Purpose • Subject to Jaipur Jurisdiction only.