



Dear **RAJESH KUMAR SAHU**,

We are pleased to confirm your health checkup booking request with the following details.

Hospital Package Name : Mediwheel Full Body Annual Plus

Patient Package Name : Mediwheel Full Body Health Checkup Male Below 40

Name of Diagnostic/Hospital : Shree Ram multispeciality Hospital

Address of Diagnostic/Hospital : Gate No.1, Basant Vihar, near Railway Under Bridge, Gondwara Chowk, Gudhiyari, Raipur, Chhattisgarh- 492001

City : Raipur

State : Chhattisgarh

Pincode : 492001

Appointment Date : 01-04-2024

Confirmation Status : Booking Confirmed

Preferred Time : 8:30am

Booking Status : Booking Confirmed

Member Information		
Booked Member Name	Age	Gender
MR. SAHU RAJESH KUMAR	36 year	Male

Note - Please note to not pay any amount at the center.

Instructions to undergo Health Check:





भारत सरकार
Government of India

भारतीय विशिष्ट ओजभाऊ प्राधिकरण
Unique Identification Authority of India

Enrollment ID/ Enrollment No.: 0548/00254/60213

To
राजेश कुमार सहा
Rajesh Kumar Saha
Kumarpal
Aurb
Delangah Odisha - 758109
943386885



आपका आधाअर नंअर / Your Aadhaar No. :

4819 0717 7685

VID : 9147 9667 1952 4960

आपका आधाअर, आपका ओजभाऊ



भारत सरकार
Government of India



राजेश कुमार सहा
Rajesh Kumar Saha
DOB: 04/05/1987
गण / GALE

4819 0717 7685

VID : 9147 9667 1952 4960

आपका आधाअर, आपका ओजभाऊ



सूचना

- आधाअर ओजभाऊअरनु प्रमाणु है. कनडीकतानु नई.
- ओजभाऊ प्रमाणुअर अडे सुसुडल ऑन कोड / ओडऑन ऑन XML / ऑनलाइन प्रमाणीकतानु के प्रयोग करणे.
- अड ऑनलाइन प्रमाणीकतानु के प्रयोग करणे.

INFORMATION

- Aadhaar is a proof of identity, not of citizenship.
- Verify identity using Secure Off Code/ Offline XML/ Online Authentication.
- This is electronically generated letter.

- आधाअर कनडीकतानु प्रमाणु है.
- आधाअर कनडीकतानु प्रमाणुअर अडे सुसुडल ऑन कोड / ऑनलाइन प्रमाणीकतानु के प्रयोग करणे.
- आधाअर ओजभाऊअर नंअर अडे ऑनलाइन प्रमाणीकतानु के प्रयोग करणे.
- आधाअर कनडीकतानु प्रमाणुअर अडे ऑनलाइन प्रमाणीकतानु के प्रयोग करणे.

- Aadhaar is valid throughout the country.
- Aadhaar helps you avail various Government and non-Government services easily.
- Keep your mobile number & email ID updated in Aadhaar.
- Carry Aadhaar in your smart phone - use mAadhaar App.




भारतीय विशिष्ट ओजभाऊ प्राधिकरण
Unique Identification Authority of India



राजेश कुमार सहा
Rajesh Kumar Saha
DOB: 04/05/1987
गण / GALE

Address:
Kumarpal, Aurb, Delangah,
Odisha - 758109



4819 0717 7685

VID : 9147 9667 1952 4960

आपका आधाअर, आपका ओजभाऊ

Rajesh
8455886885



Shree Ram Multispeciality Hospital (SRMH)

L o k a h S a m a s t a S u k h i n o B h a v a n t u

OPD-ID :020240000766 PT.TYPE :NEWREGISTRATION
UH-ID :SRMH-24042295 PRINTDATE :01-04-2024/09:37:39 TOKENNO. :1

PATIENTNAME	: RAJESHKUMARSAHU	DEPARTMENT	: ENT
AGE/SEX	: 36-Y8-M29-D/MALE	CONSULT-DATE	: 01-Apr-2024-09:22AM
DOB	: 04-07-1987	COMPANYNAME	: MEDIWHEELFULLBODYANNUALPLUS
MOB-NO	: 8455086885	OPDPAIDFEE	: 0.00
GUARDIANNAME	: S/oKUMJEAVIHARISAHU		
ADDRESS	: NOWARAIPUR,CG		

Weight: Temp : B.P. : Pulse : SPO2 :

Please indicate whether you are presently suffering from anyone of the following symptoms:

Ears, Nose, Mouth, Throat

	Yes	No
Ear pain	0	0
Ear itch	0	0
Ear drainage	0	0
Dizziness/ Loss of balance	0	0
Loss of Hearing	0	0
Popping Noise	0	0
Tinnitus	0	0
Nosebleeds	0	0
Post-nasal Drip	0	0
Sinus pain	0	0
Sinus pressure	0	0
Nasal congestion	0	0
Loss of smell/taste	0	0
Hoarseness	0	0
Sore Throat	0	0
Throat tickle	0	0
Dry Mouth / Throat	0	0
Throat clearing	0	0
Snoring	0	0

Present chief complaints:- No Any new fresh complaints

Dr. Signature



Shree Ram Multispeciality Hospital (SRMH)

L o k a h S a m a s t a S u k h i n o B h a v a n t u

OPD-ID :020240000766 PT.TYPE :NEWREGISTRATION
 UH-ID :SRMH-24042295 PRINTDATE :01-04-2024/09:37:39 TOKENNO. :1

PATIENTNAME	: RAJESHKUMARSAHU	DEPARTMENT	: DENTAL
AGE/SEX	: 36-Y8-M29-D/MALE	CONSULT-DATE	: 01-Apr-2024-09:22AM
DOB	: 04-07-1987	COMPANYNAME	: MEDIWHEELFULLBODYANNUALPLUS
MOB-NO	: 8455886885	OPDPAIDFEE	: 0.00
GUARDIANNAME	: S/oKUNDEAVIHARISAHU		
ADDRESS	: MOWA,RAIPUR,CG		

Weight: Temp : B.P. : Pulse : SPO2 :

Please indicate whether you are presently suffering from anyone of the following symptoms:

Oral Health Status:

- Yes No Dental Sealants Present on Permanent Molars
- Yes No Caries Experience / Restoration History : A filling (Temporary / Permanent) OR a Tooth that is missing because it was extracted as a result of caries .
- Yes No Untreated Caries/ Open Treatment Plan
- Yes No Urgent Treatment: abscess, Nerve Exposure, Advanced Disease State, Signs of Symptoms that include pain/ infection / swelling

Treatment Needs:

- Restorative Care- Fillings, crowns, etc.
- Preventative Care-prophylaxis, sealants, fluoride Treatment
- Sedation / Surgery Needs to Complete Treatment

Present chief complaints:-

NO Any new fresh complaints

Dr. Signature:



● Near Railway Under Bridge, Basant Vihar Gate No. 1, Gondwara Chowk, Gudhiyari, Raipur (Chhattisgarh)

☎ 0771-43 43 161, 0771-43 40 162, 📞 8404 8404 79

✉ shreeramhospital.op@gmail.com 🌐 www.srmhraipur.com

24x7
Emergency





Shree Ram Multispeciality Hospital (SRMH)

L o k a h S a m a s t a S u k h i n o B h a v a n t u

EXAMINATION OF EYES:- (BY OPHTHALMOLOGIST)

Patient Name Mr. Rakesh Kumar Sahu

Date 02/04/2024

Sex/ Age 36/09

UHID.....

EXTERNAL EXAMINATION				
SQUINT		No		
NYSTAGMUS				
COLOUR VISION <u>Normal</u>				
FUNDUS : (RE):-		<u>Ww</u>	(LE):-	<u>Ww</u>
INDIVIDUAL COLOUR IDENTIFICATION <u>Good</u>				
DISTANT VISION:(RE):-		<u>6/6</u>	(LE):-	<u>6/6</u>
NEAR VISION:(RE):-		<u>N6</u>	(LE):-	<u>N6</u>
NIGHT BLINDNESS <u>NAD</u>				
	SPH	CYL	AXIS	ADD
RIGHT	—————			
LEFT	—————			
REMARKS:-				



● Near Railway Under Bridge, Basant Vihar Gate No. 1, Gondwara Chowk, Gudhiyari, Raipur (Chhattisgarh)

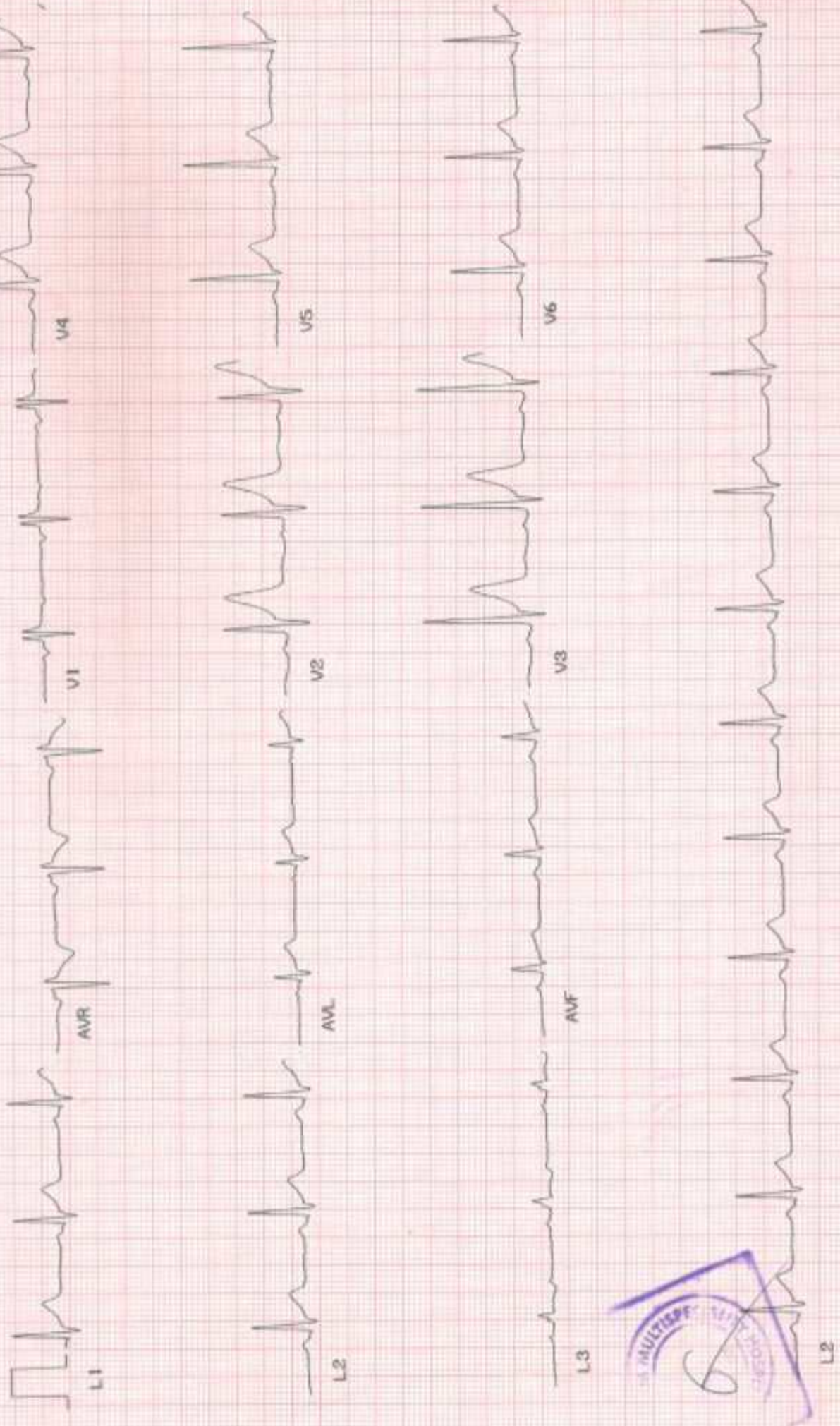
☎ 0771-43 43 161, 0771-43 40 162, 📠 8404 8404 79

✉ shreeramhospital.op@gmail.com 🌐 www.srmhraipur.com



25 mm/s P = 95 ms QT/QTc = 92% To be clinically correlated: HR = 71bpm
 10mm/mv RS = 82 ms QT/RR = 38% Stry Rhythm
 0.1 - 35Hz PR = 142 ms QRS ax15 = 42° Non-rot ECG
 50Hz ReJ-V QT = 322 ms P ax15 = 45°
 QTc = 350 ms T ax15 = 25°
 AUTO 12L-S BLC-V

Mr. rajesh sahu
 M 36Y 099Kg
 09:49 AM
 01/04/2024



Ref By Dr. Dr. ajit kumar



Shree Ram Multispeciality Hospital (SRMH)

Lokah Samasta Sukhino Bhavantu

Department of Radiology

NAME :- MR. RAJESH KUMAR SAHU	AGE - 36 YEAR / MALE
REF. BY :- SHREE RAM MULTI SPECIALITY HOSPITAL	DATE - 17/02/2024

X - RAY CHEST PA VIEW.

FINDINGS:

- Bilateral lung parenchyma is clear.
- Both apices free.
- Trachea in mid line.
- C T ratio within normal limits.
- Both hila are normal.
- Both costo & cardiophrenic angles are clear.
- Bony cage normal.
- Soft tissue appears normal.

IMPRESSION : No significant abnormality detected.



DR ANAND BANSAL

MD DNB RADIODIAGNOSIS

CONSULTANT RADIOLOGIST

CGMC 2015/6359

Near Railway Under Bridge, Basant Vihar Gate No. 1, Gondwara Chowk,
Gudhiyari, Raipur (Chhattisgarh)

☎ 0771-43 43 161, 0771-43 40 162, 📞 8404 8404 79

✉ shreeramhospital.op@gmail.com 🌐 www.srmhraipur.com





Shree Ram Multispeciality Hospital

Lokah Samasta Sukhino Bhavantu



PT. NAME : RAJESH KUMAR SAHU
MOBILE NO : 8455886885
DOCTOR : DR. AJIT KUMAR
REFERRED BY : SELF

AGE / SEX : 36/MALE
UH ID NO. : SRMH-24042295
COLLECTION : 01-04-2024
REPORTING : 01-Apr-2024

TEST NO
444

HAEMATOLOGY

TEST NAME	RESULT	UNIT	NORMAL VALUES
CBC (COMPLETE BLOOD COUNT)			
HAEMOGLOBIN (Hb)	11.3	gm/dL	13.5 - 17.5
TOTAL RBC COUNT	4.74	Million/cumm	4.5 - 5.9
HAEMATOCRIT (PCV)	33.9	%	41.5 - 50.4
RBC INDICES			
MCV	71.9	f l	78 - 96
MCH	23.8	pg	27 - 32
MCHC	33.1	%	33 - 37
RDW	15.0	%	11 - 16
TOTAL WBC COUNT (TLC)	6500	/cumm	4000 - 11000
DIFFERENTIAL COUNT			
Neutrophils	69	%	40 - 70
Lymphocytes	26	%	22 - 48
Eosinophils	02	%	0 - 6
Monocytes	03	%	0 - 8
Basophils	00	%	00 -
PLATELET COUNT			
PCT	0.16	%	0.10 - 0.28
MPV(MEAN PLATELET VOLUME)	10.2	fL	8 - 11
PDW	14.2	%	11 - 18

-- End Of Report --

LAB TECHNICIAN

Note : This Report is not for medicolegal purpose

Dr. Dhananjay Prasad
(MD PATHOLOGY)

📍 Near Railway Under Bridge, Basant Vihar Gate No. 1, Gondwara Chowk,
Gudhiyari, Raipur (Chhattisgarh)

☎ 0771 - 4343161, 0771-4340162 📧 shreeramhospital.op@gmail.com



Shree Ram Multispeciality Hospital (SRMH)

L o k a h S a m a s t a S u k h i n o B h a v a n t u

PT. NAME : RAJESH KUMAR SAHU
MOBILE NO : 8455886885
DOCTOR : DR. AJIT KUMAR
REFERRED BY : SELF

AGE / SEX : 36/MALE
UH ID NO. : SRMH-24042295
COLLECTION : 01-04-2024
REPORTING : 01-Apr-2024

TEST NO
444

HAEMATOLOGY

TEST NAME	RESULT	UNIT	NORMAL VALUES
-----------	--------	------	---------------

ESR (ERYTHROCYTE SEDIMENTATION RATE)

ESR	15	mm after 1 hrr	0 - 20
-----	----	----------------	--------

-- End Of Report --

LAB TECHNICIAN

Note : This Report is not for medicolegal purpose

Dr. Dhananjay Prasad
(MD PATHOLOGY)

📍 Near Railway Under Bridge, Basant Vihar Gate No. 1, Gondwara Chowk,
Gudhiyari, Raipur (Chhattisgarh)

☎ 0771-43 43 161, 0771-43 40 162, 📞 8404 8404 79

✉ shreeramhospital.op@gmail.com 🌐 www.srmhraipur.com





Shree Ram Multispeciality Hospital (SRMH)

Lokah Samasta Sukhino Bhavantu

PT. NAME : RAJESH KUMAR SAHU
MOBILE NO : 8455886885
DOCTOR : DR. AJIT KUMAR
REFERRED BY : SELF

AGE / SEX : 36/MALE
UH ID NO. : SRMH-24042295
COLLECTION : 01-04-2024
REPORTING : 01-Apr-2024

TEST NO
444

HAEMATOLOGY

TEST NAME	RESULT	UNIT	NORMAL VALUES
-----------	--------	------	---------------


BLOOD GROUPING AND RH TYPING

BLOOD GROUP	"A"	-	-
RH FACTOR	POSITIVE	-	-

-- End Of Report --


LAB TECHNICIAN

Note : This Report is not for medicolegal purpose


Dr. Dhananjay Prasad
(MD PATHOLOGY)

📍 Near Railway Under Bridge, Basant Vihar Gate No. 1, Gondwara Chowk,
Gudhiyari, Raipur (Chhattisgarh)

☎ 0771-43 43 161, 0771-43 40 162, 📞 8404 8404 79

✉ shreeramhospital.op@gmail.com 🌐 www.srmhraipur.com

247
Emergency
Service





Shree Ram Multispeciality Hospital (SRMH)

Lokah Samasta Sukhino Bhavantu

PT. NAME : RAJESH KUMAR SAHU
MOBILE NO : 8455886885
DOCTOR : DR. AJIT KUMAR
REFERRED BY : SELF

AGE / SEX : 36/MALE
UH ID NO. : SRMH-24042295
COLLECTION : 01-04-2024
REPORTING : 01-Apr-2024

TEST NO
444


CLINICAL PATHOLOGY

TEST NAME	RESULT	UNIT	NORMAL VALUES
URINE SUGAR FASTING AND PP			
URINE SUGAR - FASTING	Absent		Absent -
URINE SUGAR - PP	Absent		Absent -

-- End Of Report --


LAB TECHNICIAN

Note: This Report is not for medicolegal purpose


Dr. Dhananjay Prasad
(MD PATHOLOGY)

📍 Near Railway Under Bridge, Basant Vihar Gate No. 1, Gondwara Chowk,
Gudhiyari, Raipur (Chhattisgarh)

☎ 0771-43 43 161, 0771-43 40 162, 📞 8404 8404 79

📧 shreeramhospital.op@gmail.com 🌐 www.srmhraipur.com





Shree Ram Multispeciality Hospital (SRMH)

Lokah Samasta Sukhino Bhavantu

PT. NAME : RAJESH KUMAR SAHU
MOBILE NO : 8455886885
DOCTOR : DR. AJIT KUMAR
REFERRED BY : SELF

AGE / SEX : 36/MALE
UH ID NO : SRMH-24042295
COLLECTION : 01-04-2024
REPORTING : 01-Apr-2024

TEST NO
444


BIOCHEMISTRY

TEST NAME	RESULT	UNIT	NORMAL VALUES
BLOOD SUGAR - FASTING AND PP			
BLOOD SUGAR FASTING	85.6	mg/dL	60 - 120
BLOOD SUGAR PP	106.3	mg/dL	80 - 140

-- End Of Report --


LAB TECHNICIAN

Note : This Report is not for medicolegal purpose


Dr. Dhananjay Prasad
(MD PATHOLOGY)

📍 Near Railway Under Bridge, Basant Vihar Gate No. 1, Gondwara Chowk,
Gudhiyari, Raipur (Chhattisgarh)

☎ 0771-43 43 161, 0771-43 40 162, 📞 8404 8404 79

✉ shreeramhospital.op@gmail.com 🌐 www.srmhraipur.com



Shree Ram Multispeciality Hospital



Lokah Samasta Sukhino Bhavantu

PT. NAME : RAJESH KUMAR SAHU
MOBILE NO : 8455886885
DOCTOR : DR. AJIT KUMAR
REFERRED BY : SELF

AGE / SEX : 36/MALE
UH ID NO. : SRMH-24042295
COLLECTION : 01-04-2024
REPORTING : 01-Apr-2024
TEST NO
444


BIOCHEMISTRY

TEST NAME	RESULT	UNIT	NORMAL VALUES
	CREATININE		
CREATININE	0.95	mg / dl	0.6 - 1.2

-- End Of Report --


LAB TECHNICIAN

Note : This Report is not for medicolegal purpose


Dr. Dhananjay Prasad
(MD PATHOLOGY)

📍 Near Railway Under Bridge, Basant Vihar Gate No. 1, Gondwara Chowk,
Gudhiyari, Raipur (Chhattisgarh)

☎ 0771 - 4343161, 0771-4340162 📧 shreeramhospital.op@gmail.com



Shree Ram Multispeciality Hospital

Lokah Samasta Sukhino Bhavantu



PT. NAME : RAJESH KUMAR SAHU
MOBILE NO : 8455886885
DOCTOR : DR. AJIT KUMAR
REFERED BY : SELF

AGE / SEX : 36/MALE
UH ID NO. : SRMH-24042295
COLLECTION : 01-04-2024
REPORTING : 01-Apr-2024

TEST NO
444

TEST NAME


BIOCHEMISTRY

TEST NAME	RESULT	UNIT	NORMAL VALUES
CREATININE	0.95	mg / dl	0.6 - 1.2

-- End Of Report --


LAB TECHNICIAN

Note : This Report is not for medicolegal purpose


Dr. Dhananjay Prasad
(MD PATHOLOGY)

📍 Near Railway Under Bridge, Basant Vihar Gate No. 1, Gondwara Chowk,
Gudhiyari, Raipur (Chhattisgarh)

☎ 0771 - 4343161, 0771-4340162 📧 shreeramhospital.op@gmail.com



Shree Ram Multispeciality Hospital (SRMH)

Lokah Samasta Sukhino Bhavantu

PT. NAME : RAJESH KUMAR SAHU
MOBILE NO : 8455886885
DOCTOR : DR. AJIT KUMAR
REFERRED BY : SELF

AGE / SEX : 36/MALE
UH ID NO : SRMH-24042295
COLLECTION : 01-04-2024
REPORTING : 01-Apr-2024
TEST NO : 444

BIOCHEMISTRY

TEST NAME

RESULT

UNIT

NORMAL VALUES

URIC ACID

URIC ACID

5.69

mg/dL

3.6 - 7.7

-- End Of Report --

LAB TECHNICIAN

Note : This Report is not for medicolegal purpose

Dr. Dhananjay Prasad
(MD PATHOLOGY)

Near Railway Under Bridge, Basant Vihar Gate No. 1, Gondwara Chowk,
Gudhiyari, Raipur (Chhattisgarh)

☎ 0771-43 43 161, 0771-43 40 162, 📞 8404 8404 79
✉ shreeramhospital.op@gmail.com 🌐 www.srmhrai.com





Shree Ram Multispeciality Hospital (SRMH)

Lokah Samasta Sukhino Bhavantu

PT. NAME : RAJESH KUMAR SAHU
 MOBILE NO : 8455886885
 DOCTOR : DR. AJIT KUMAR
 REFERED BY : SELF

AGE / SEX : 36/MALE
 UH ID NO. : SRMH-24042295
 COLLECTION : 01-04-2024
 REPORTING : 01-Apr-2024

TEST NO
444

BIOCHEMISTRY

TEST NAME

RESULT

UNIT

NORMAL VALUES

HbA1c (GLYCOSYLATED HEAMOGLOBIN)

HbA1c

4.35

%

Normal Range : <6% -
 Good Control : 6 - 7% -
 Fair Control : 7 - 8% -
 Unsatisfactory Control :
 8-10% -
 Poor Control : >10% -
 80 - 120

Estimated average plasma glucose

77.56

mg/dl

Interpretation: As per American Diabetes Association(ADA)

Non diabetic adults >= 18 years	<5.7
At risk (prediabetes)	5.7 - 6.4
Diagnosing Diabetes	>= 6.5
Therapeutic goals for glycemic control	Good of Therapy
	> 19 years - <7.0
	<19 years - <7.5

NOTE:

- HbA1c reflects long term fluctuations in the blood glucose concentration
- A diabetic patient who is recently under good control may still have a high concentration of HbA1c. Converse is true for a diabetic previously under good control but now poorly controlled.

Significance of Test:

HbA1c provides an index of average blood glucose levels over the past 8-12 weeks and is a much better indicator of long term glycemic control as compared to blood and urinary glucose determinations.

-- End Of Report --

LAB TECHNICIAN

Note : This Report is not for medicolegal purpose

Dr. Dhananjay Prasad
(MD PATHOLOGY)

Near Railway Under Bridge, Basant Vihar Gate No. 1, Gondwara Chowk,
 Gudhiyari, Raipur (Chhattisgarh)

0771-43 43 161, 0771-43 40 162, 8404 8404 79

shreeramhospital.op@gmail.com www.srmhraipur.com





Shree Ram Multispeciality Hospital (SRMH)

Lokah Samasta Sukhino Bhavantu

PT. NAME : RAJESH KUMAR SAHU
 MOBILE NO : 8455886885
 DOCTOR : DR. AJIT KUMAR
 REFERED BY : SELF

AGE / SEX : 36/MALE
 UH ID NO. : SRMH-24042295
 COLLECTION : 01-04-2024
 REPORTING : 01-Apr-2024

TEST NO
444

BIOCHEMISTRY

TEST NAME

RESULT

UNIT

NORMAL VALUES

LIVER FUNCTION TEST (LFT)

TEST NAME	RESULT	UNIT	NORMAL VALUES
BILIRUBIN TOTAL	0.59	mg/dL	0.2 - 1
BILIRUBIN DIRECT	0.32	mg / dl	0.1 - 0.6
BILIRUBIN INDIRECT	0.27	mg / dl	0.1 - 0.4
SGOT	36.6	U / L	10 - 55
SGPT	41.3	U / L	0 - 40
ALKALINE PHOSPHATASE	182.4	U / L	0 - 270
TOTAL PROTEIN	6.76	g / dl	6 - 8
ALBUMIN	3.84	g/dl	3.5 - 5.0
GLOBULIN	2.92	g / dl	2 - 3.5
A/G RATIO	0.92	g/dl	1 - 2.5

Clinical Significance:

Alanine transaminase (ALT)

ALT is an enzyme found in the liver that helps your body metabolize protein. When the liver is damaged, ALT is released into the bloodstream and levels increase.

Aspartate transaminase (AST)

AST is an enzyme that helps metabolize alanine, an amino acid. Like ALT, AST is normally present in blood at low levels. An increase in AST levels may indicate liver damage or disease or muscle damage.

Alkaline phosphatase (ALP)

ALP is an enzyme in the liver, bile ducts and bone. Higher-than-normal levels of ALP may indicate liver damage or disease, such as a blocked bile duct, or certain bone diseases.

Albumin and total protein

Albumin is one of several proteins made in the liver. Your body needs these proteins to fight infections and to perform other functions. Lower-than-normal levels of albumin and total protein might indicate liver damage or disease.


Bilirubin

Bilirubin is a substance produced during the normal breakdown of red blood cells. Bilirubin passes through the liver and is excreted in stool. Elevated levels of bilirubin (jaundice) might indicate liver damage or disease or certain types of anemia.

-- End Of Report --


LAB TECHNICIAN

Note : This Report is not for medicolegal purpose


Dr. Dhananjay Prasad
(MD PATHOLOGY)

📍 Near Railway Under Bridge, Basant Vihar Gate No. 1, Gondwara Chowk,
Gudhiyari, Raipur (Chhattisgarh)

☎ 0771-43 43 161, 0771-43 40 162, 📞 8404 8404 79

✉ shreeramhospital.op@gmail.com 🌐 www.srmhraipur.com

24x7
EMERGENCY
Services





Shree Ram Multispeciality Hospital (SRMH)

Lokah Samasta Sukhino Bhavantu

PT. NAME : RAJESH KUMAR SAHU
 MOBILE NO : 8455886885
 DOCTOR : DR. AJIT KUMAR
 REFERED BY : SELF

AGE / SEX : 36/MALE
 UH ID NO : SRMH-24042295
 COLLECTION : 01-04-2024
 REPORTING : 01-Apr-2024

TEST NO
444


BIOCHEMISTRY

TEST NAME	RESULT	UNIT	NORMAL VALUES
LIPID PROFILE			
CHOLESTEROL	203.8	mg / dl	150 - 220
SERUM TRIGLYCERIDE	293.2	mg / dl	60 - 165
HDL	35.2	mg / dl	35 - 80
LDL	168.6	mg/dL	90 - 160
VLDL	58.64	mg/dl	20 - 50
CHOLESTEROL / HDL RATIO	5.78	mg/dl	3.5 - 5.5
LDL/HDL Ratio	4.78	mg/dl	2.5 - 3.5
TRIGLYCERIDES/HDL RATIO	8.32	mg/dl	2.0 - 4.0

-- End Of Report --


 LAB TECHNICIAN

Note : This Report is not for medicolegal purpose


 Dr. Dhananjay Prasad
 (MD PATHOLOGY)

📍 Near Railway Under Bridge, Basant Vihar Gate No. 1, Gondwara Chowk,
 Gudhiyari, Raipur (Chhattisgarh)

☎ 0771-43 43 161, 0771-43 40 162. 📞 8404 8404 79

✉ shreeramhospital.op@gmail.com 🌐 www.srmhraipur.com





Shree Ram Multispeciality Hospital (SRMH)

L o k a h S a m a s t a S u k h i n o B h a v a n t u

MR. RAKESH KUMAR SAHU
Age: 36 Years
Sex: Male

Sample Collected At:
Ref. By: Dr.AJIT KUMAR

Registered: 01 Apr, 24 10:30 AM
Collected: 01 Apr, 24 10:35 AM
Reported: 02 Apr, 24 12:30 PM

BUN / Creatinine Ratio PANAL

Investigation	Observed Value	Unit	Biological Reference Interval
BUN			
BUN	16.9	mg/dL	7.00 - 20.00
Serum Creatinine	0.95	mg/dL	0.55 - 1.20
BUN / Creatinine Ratio	17.78		10.1 - 20.1

Blood urea nitrogen (BUN) is a waste product produced when the liver breaks down protein. The kidneys then filter it out of the blood and eliminate it through urine. Creatinine is a waste product created by the breakdown of phosphocreatine, a molecule stored in muscle tissue. The kidneys filter creatinine from the blood, and its levels in the body reflect the efficiency of the kidney's excretory function. therefore, BUN and creatinine are useful markers in assessing kidney health because they help doctors evaluate the kidney's filtration rate.

Dr. D. Prasad
M.D. (Pathologist)

END OF REPORT
Near Railway Under Bridge, Basant Vihar Gate No. 1, Gondwara Chowk,
Gudhiyari, Raipur (Chhattisgarh)

☎ 0771-43 43 161, 0771-43 40 162, 📞 8404 8404 79

✉ shreeramhospital.op@gmail.com 🌐 www.srmhraipur.com





Shree Ram Multispeciality Hospital (SRMH)

L o k a h S a m a s t a S u k h i n o B h a v a n t u

MR. RAKESH KUMAR SAHU

Age: 36 Years

Sex: Male

Sample Collected At:

Ref. By: Dr.AJIT KUMAR

Registered: 01 Apr, 24 10:30: AM

Collected: 01 Apr, 24 10:35 AM

Reported: 02 Apr, 24 12:30 PM

TFT

Thyroid Function Test (TFT)

Investigation	Observed Value	Unit	Biological Reference Interval
THYROID SERUM HORMONS			
Serum Triiodothyronine (T3)	1.33	ng/mL	0.89 - 1.87
Serum thyroxine (T4)	11.27	ug/dL	5.1 - 14.28
Thyroid Stimulating Hormone (TSH)	1.93	μIU/mL	0.66 - 5.67

Comments:-

(i) Ethnicity, iodine intake, gender, age, body mass index and Exercise influences the reference range of Thyroid hormones and serum TSH concentrations.

(ii) Changes in Thyroid Hormones (especially T3) and TSH may be seen as early as 24 hours after the onset of non-thyroid illness. (Poor nutrition/starvation, sepsis, burns, malignancy, myocardial infarction, post-surgery, and with chronic liver and renal disease)

(iii) Serum total T4 and T3 concentrations increase to approximately 150% of non-pregnant values – this occurs during the first half of pregnancy and is maintained thereafter until parturition. Free T4 concentrations also change during pregnancy: in the first trimester a transient rise is often observed.

(iv) Measurement of FT4 and FT3 is best avoided in patients receiving heparin therapy. (When indicated, blood sample should be taken 10 hours after the last injection of heparin, and analyzing it without delay, can reduce the risk of artifactual hyperthyroxaemia.)

(v) Phenytoin, carbamazepine and furosemide cause artifactual increase in free T4 (FT4) and decrease in total T4.

Dr. D. Prasad
M.D. (Pathologist)

© Near Railway Under Bridge, Basant Vihar Gate No. 1, Gondwara Chowk, Gudhiyari, Raipur (Chhattisgarh)

© 0771-43 43 161, 0771-43 40 162, 8404 8404 79

© shreeramhospital.op@gmail.com www.srmhraipur.com





Shree Ram Multispeciality Hospital (SRMH)

L o k a h S a m a s t a S u k h i n o B h a v a n t u

Mr. RAKESH KUMAR

Sample Collected At :

Registered : 01 Apr,24 12:40PM

Age: 36 Years

Ref By : Dr. AJIT KUMAR

Collected : 01 Apr,24 12:49 PM

Sex:-Male

Reported : 02 Apr,24 3:12 PM

GAMAMA GLUTAMYL TRANSFERASE (GGT)

INVESTIGATION	RESULT	REFERENCE VALUE	UNIT
GAMMA – GLUTAMYL TRANSFERASE (GGT) , SERUM	16.9	12.00-18.00	U/L

GENDER	-	NORMAL RANGE(U/L)
MALE	-	12.00-18.00
FEMALE	-	6.00-29.00

COMMENTS:-

Gamma – Glutamyl Transferase (Ggt) Is An Enzyme That Is Found In Many Organs Throughtout The Body , With The Highest Concentrations Found In The Liver .Ggt Is Elevated In The Blood In Most Diseases That Cause Damage To The Liver Or Bile Ducts ,This Test Measures The Level Of Ggt In A Blood Samle.

DR. DHANANJAY PRASAD

(MD Pathology)

📍 Near Railway Under Bridge, Basant Vihar Gate No. 1, Gondwara Chowk, Gudhiyari, Raipur (Chhattisgarh)

☎ 0771-43 43 161, 0771-43 40 162, 📠 8404 8404 79

✉ shreeramhospital.op@gmail.com 🌐 www.srmhraipur.com





Shree Ram Multispeciality Hospital (SRMH)

Lokah Samasta Sukhino Bhavantu

PT. NAME : RAJESH KUMAR SAHU
MOBILE NO : 8455886885
DOCTOR : DR. AJIT KUMAR
REFERRED BY : SELF

AGE / SEX : 36/MALE
UH ID NO. : SRMH-24042295
COLLECTION : 01-04-2024
REPORTING : 01-Apr-2024

TEST NO
444

CLINICAL PATHOLOGY

TEST NAME	RESULT	UNIT	NORMAL VALUES
URINE ROUTINE AND MICROSCOPY			
PHYSICAL EXAMINATION			
QUANTITY	20	ml	-
COLOUR	Pale Yellow		-
APPEARANCE	Clear		Pale Yellow -
REACTION	Acitic		Clear -
CHEMICAL EXAMINATION			
ALBUMIN	Absent		Acitic -
SUGAR	Absent		-
KETONE	Absent		Absent -
BILE SALT	Absent		Absent -
BILE PIGMENT	Absent		Absent -
MICROSCOPIC EXAMINATION			
PUS CELLS	2-3	/hpf	-
EPITHELIAL CELLS	3-4	/hpf	2 - 5
RBC	Nil	/hpf	1 - 5
CAST	Nil	/hpf	0 - 3
YEAST	Nil	/lpf	Nil -
CRYSTAL	Nil		Nil -
Bacteria	Nil	/lpf	Nil -
OTHERS	-		Nil -

-- End Of Report --

LAB TECHNICIAN

Note : This Report is not for medicolegal purpose

Dr. Dhananjay Prasad
(MD PATHOLOGY)

📍 Near Railway Under Bridge, Basant Vihar Gate No. 1, Gondwara Chowk,
Gudhiyari, Raipur (Chhattisgarh)

☎ 0771-43 43 161, 0771-43 40 162, 📞 8404 8404 79

✉ shreeramhospital.op@gmail.com 🌐 www.srmhraipur.com





SHRI RAM IMAGING & DIAGNOSTIC CENTER

Ground Floor, Raheja Towers, Jail Road, Raipur
Ph. : 0771-4099090, Mo. : 9294870000

DR ANAND BANSAL
MBBS MD DNB(Radiodiagnosis)
(IMS BHU) (Gold Medalist)
Ex Senior Resident (AIIMS Raipur)
Ex Assistant Professor (Pt JNMC Raipur)
Reg. No. - CGMC 6359/2015

5D SONOGRAPHY -16 SLICE CT SCAN - DIGITAL X RAY - PATHOLOGY - BIOPSY

PATIENT NAME: RAJESH KUMAR SAHU	DATE: 01/04/2024
REF PHY: SHRIRAM MULTISPECIALITY HOSPITAL GUDHIYARI (SRMS), PATIENT ID: 46831	AGE/SEX: 37 Years/MALE

USG WHOLE ABDOMEN

Liver: Liver is normal in size (14.5), smooth in outline & raised echotexture.

Biliary system: IHBR's are not dilated. CBD is not dilated.

Liver vessels: Portal vein and hepatic veins are normal.

Gall bladder: Distended with anechoic lumen and normal wall thickness.

Pancreas & Paraaortic Region: Normal. Pancreatic duct not dilated.

Spleen: Is normal in size measures (13.1 cm) with normal echotexture.

Kidneys	RIGHT	LEFT
SIZE	10.4 x 4.8 cm	10.9 x 6.2 cm
CORTICAL ECHOGENICITY	Normal	Normal
CORTICOMEDULLARY DIFFERENTIATION	Maintained	Maintained
PELVICALYCEAL SYSTEM	Not dilated	Not dilated
URETER	Not dilated	Not dilated
CALCULUS	No	No

Urinary bladder: The urinary bladder shows physiological distention. It shows normal wall thickness.

Prostate: is normal in size measures 3.0 x 3.7 x 3.3 cm (weight 18.8 gm) with normal shape & echotexture.

Fluid: There is no free or loculated fluid collection in abdomen or pelvis.

Bowel loops are grossly normal.

No significant lymphadenopathy is noted.



SHRI RAM IMAGING & DIAGNOSTIC CENTER

Ground Floor, Raheja Towers, Jail Road, Raipur
Ph. : 0771-4099090, Mo. : 9294870000

DR ANAND BANSAL

MBBS MD DNB(Radiodiagnosis)
(IMS BHU) (Gold Medalist)
Ex Senior Resident (AIIMS Raipur)
Ex Assistant Professor (Pt JNMC Raipur)
Reg. No. - CGMC 6359/2015

SONOGRAPHY - 16 SLICE CT SCAN - DIGITAL X RAY - PATHOLOGY - BIOPSY

PATIENT NAME: RAJESH KUMAR SAHU	DATE: 01/04/2024
REF PHY: SHRIRAM MULTISPECIALITY HOSPITAL GUDHIYARI (SRMS), PATIENT ID: 46831	AGE/SEX: 37 Years/MALE

IMPRESSION:

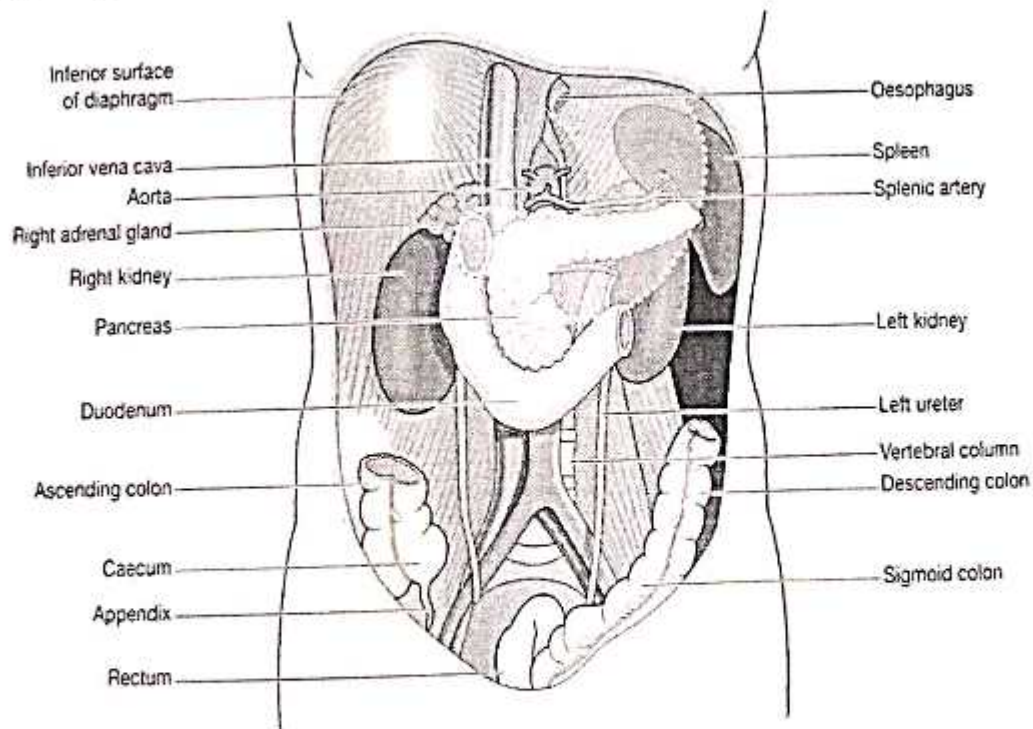
- GRADE – III FATTY LIVER CHANGES.

Advised clinical correlation/further evaluation if clinically indicated.



Typist: DEKUMAR SAHU

This report is for perusal of the doctor only not the definitive diagnosis; findings have to be clinically correlated. Ultrasound has its limitations in obese patients and in retroperitoneal organs. All congenital abnormalities cannot be detected on ultrasound. This report is not for medico-legal purposes.



SHRI RAM IMAGING & DIAGNOSTIC CENTRE

Name: RAJESH KUMAR SAHU Age: 37 Y Sex: Male Ref: Dr. Shriram Multispeciality Hospital Gudhiyari (Srms) Date: 01-Apr-2024

