



NABH



NABL



No.1



UNITED HOSPITAL

Care Par Excellence
Jayanagar, Bangalore

Out Patient Record

Patient Name : Mr.HULLURAPPA SREEVATHSA UHID : UHJA23018084
 Age / Sex : 50 Years / Male OP NO/Reg Dt : 10-02-2024 08:47 AM
 Spouse / Father Name : HULLURAPPA Department :
 Address : # 697,BDA Layout BSK 6th Stage 3rd Block Chikkegowdana Palya Thalaghattapura Referred By :
 Consultant : Dr.Preventive Health Check Up
 KMC No. :

Complaints / Findings / Observations :

regular health check up

Ht - 170cm
 Wt - 58.9kg
 PR - 76/100
 SpO2 - 99%
 BP - 118/92

Investigations:

high protein
 Dry fruits

Treatment / Care of Plan / Provisional Diagnosis :

add

walking 1/2 hour

Follow Up Advice :

① PROHANCE - 1P 3 keeps 2 water/milk
 - daily one

② PRO CHEMICAL - as per x1 month
 (A/C)

medically fit

Signature of the Doctor

UNITED HOSPITAL (A Unit of United Brothers Healthcare Services Private Limited)

United Hospital

No.110 (30), Madhavan Park Circle, 10th Main Rd,
3rd Block Jayanagar, Bangalore - 560 011

T: 080 4566 6666

E: appointments@unitedhospital.in
W: www.unitedhospitals.com

DEPARTMENT OF RADIODIAGNOSIS

Name	Hulluruappa Sreevasthva	Date	10/02/24
Age	50 years	Hospital ID	UHJA23018084
Sex	Male	Ref.	Health check

RADIOGRAPH OF THE CHEST (PA - VIEW)

FINDINGS:

- Bilateral lung fields are normal.
- Bilateral costo-phrenic angles are normal.
- Cardia and mediastinal contours are normal.
- The bony thorax is grossly normal.

IMPRESSION:

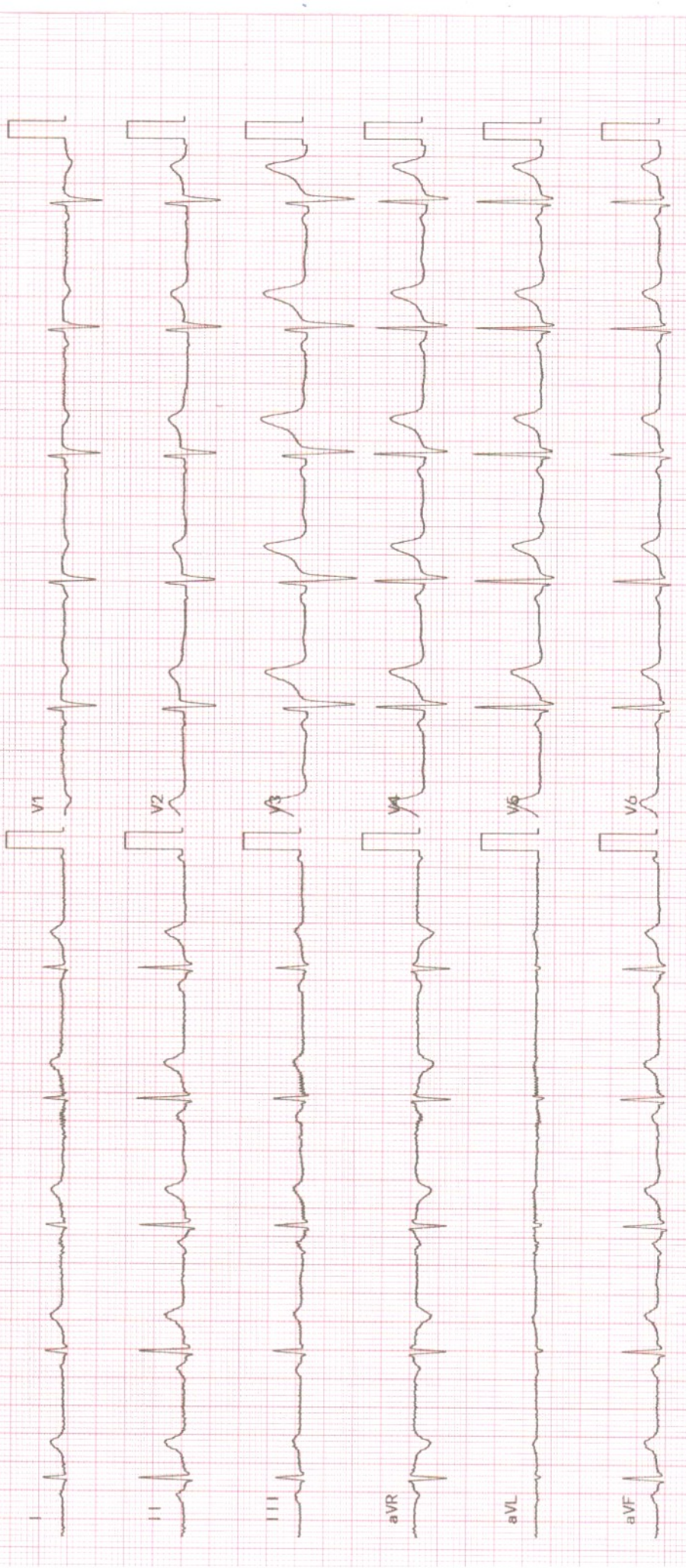
- No radiographic abnormality.



Dr. Elluru Santosh Kumar
Consultant Radiologist

ID: 23018084
 Name: Mr. Hallurappa S
 Birth date: /
 Sex: M
 Weight: kg
 Height: mmHg
 Age: 50 years
 Heart rate: 66 bpm
 R int: 142 ms
 RS dur: 86 ms
 T/QTc(E) int: 378/392 ms
 I/QRS/T axis: 72/67/53 °
 IV5/SV1 amp: 1.37/0.72 mV
 IV5+SV1 amp: 2.10 mV

10 mm/mV 25 mm/s Filter: H50 D 35 Hz
 10 mm/mV
 Unconfirmed Report
 Reviewed by:





NABH



NABL



No.1

Care Par Excellence
Jayanagar, Bangalore

Patient name :	Mr. HULLURAPPA SREEVATHSA	Date :	10/02/24
Age :	50 years GENDER: MALE	Patient ID :	18084
Ref by :	DR.CMO	OP/IP :	HEALTH CHECK

2D- ECHOCARDIOGRAPHY**M - MODE AND DOPPLER MEASUREMENTS**

(c.m)	(c.m)	(cm/sec)		
AO : 2.9 (2.5-3.7)	LVIDD : 4.2 (3.5-5.5)	MV EV : 72.4	AV : 63.4	MR : NORMAL
LA : 3.2 (1.9-4.0)	LVIDS : 2.6 (2.4-4.2)	AV : 84.7		AR : NORMAL
RA : 2.0 (<4.4)	IVSD : 0.8 (0.6-1.1)	PV : 62.9		PR : NORMAL
RV : 2.2 (<3.5)	IVSS : 1.0 (0.9-1.2)	TV EV : -----	AV : -----	TR : NORMAL
TAPSE: 1.7 (>1.6)	LVPWD : 1.1 (0.6-1.1)	Diastolic Function : NO LVDD		
	LVPWS : 1.1 (0.9-1.2)			
	EF : 60%			

DESCRIPTIVE FINDINGS

Left Ventricle	: NORMAL
Right Ventricle	: NORMAL
Left Atrium	: NORMAL
Right Atrium	: NORMAL
Wall motion analysis:	NO RWMA
Mitral Valve	: NORMAL
Aortic Valve	: NORMAL
Tricuspid Valve	: NORMAL
Pulmonary Valve	: NORMAL
IAS	: INTACT
IVS	: INTACT
Pericardium	: NORMAL
Other Findings	: IVC NORMAL

IMPRESSION :

NORMAL CHAMBER DIMENSIONS
 NORMAL LV SYSTOLIC FUNCTION EF : 60%
 NORMAL LV DIASTOLIC FUNCTION
 NO PULMONARY HYPERTENSION
 NO REGIONAL WALL MOTION ABNORMALITIES
 NO CLOTS/ PERICARDIAL EFFUSION /VEGETATION

DR. RAHUL PATIL
 CONSULTANT CARDIOLOGIST

UNITED HOSPITAL (A Unit of United Brothers Healthcare Services Private Limited)

United Hospital

No.110 (30), Madhavan Park Circle, 10th Main Rd,
 3rd Block Jayanagar, Bangalore - 560 011

T: 080 4566 6666

E: appointments@unitedhospital.in
 W: www.unitedhospitals.com

NUC + 2.00 - (B) - m

sol

lucky games

Q

12/2/24

DEPARTMENT OF RADIODIAGNOSIS

Name	Hulluruappa Sreevasthva	Date	10/02/24
Age	50 years	Hospital ID	UHJA23018084
Sex	Male	Ref.	Health check

ULTRASOUND ABDOMEN AND PELVIS

FINDINGS:

Liver is normal in size and *shows mildly increased echopattern*. No intra or extra hepatic biliary duct dilatation. No focal lesions. **Portal vein** is normal in size, course and caliber. **CBD** is not dilated.

Gall bladder is normal without evidence of calculi, wall thickening or pericholecystic fluid.

Pancreas - Visualized part of the pancreatic head and body appears normal in size, contour and echogenicity. Rest of the pancreas is obscured by bowel gas.

Spleen is normal in size, shape, contour and echopattern. No focal lesion.

Right Kidney is normal in size (10.1 x 3.4 cms), position, shape and echopattern. Corticomedullary differentiation is maintained. No calculus or hydronephrosis.

Left Kidney is normal in size (9.1 x 4.4 cms), position, shape and echopattern. Corticomedullary differentiation is maintained. No calculus or hydronephrosis.

Retroperitoneum - Visualized aorta appeared normal. No obvious enlarged para-aortic nodes.

Urinary Bladder is distended, normal in contour and wall thickness. No evidence of calculi, mass or mural lesion.

Prostate is normal in echopattern and size, measures ~ 16 cc.

No ascites or pleural effusion. Appendix could not be localized. No RIF probe tenderness.

IMPRESSION:

- **Mild fatty infiltration of liver (Grade I).**
- **No other definite sonological abnormality detected.**



Dr. Elluru Santosh Kumar
Consultant Radiologist

Please bring this report during your visit to the Hospital / ಅಸ್ವತೆಗೆ ಬರುವಾಗ ಈ ರಿಪೋರ್ಟನ್ನು ತನ್ನಿ