

बी.एम.शरणागत
एम.डी.(मेडिसिन)



रजि.क्र.-NHA/REG./BGT/2012/21

क्रिटिकल केयर युनिट I.C.C.U. सुविधायुक्त

आयुष्मान हॉस्पिटल
एंड हायमोनैटिक रिसर्च सेंटर

रजि.क्र. - 4612
कार्डियो - डायबेटोलॉजिस्ट
एवं परामर्श चिकित्सक

सर्किट हाउस रोड, बालाघाट 07632-241070 | समय-सुबह 10 बजे से संध्या 8.00 बजे तक

Name

R/O

Date

General Physical Examination

Date of Examination 04.04.23

Name Mrs. DHARNA YEDE Age 32y DOB 27/09/1990 Sex F

Referred by MEDIWHEEL

Photo Id AADHAAR CARD ID 3191

Ht 152 (CM)

Wt 62 (kg)

Chest (Expiration): 88 (cm)

Abdomen Circumference 90 (cm)

Blood Pressure 110/70 mm Hg

PR 82 /min

RR 20 /min

Temp 98°F

BMI 25.9

Eye Examination RE LE
6/6 6/6

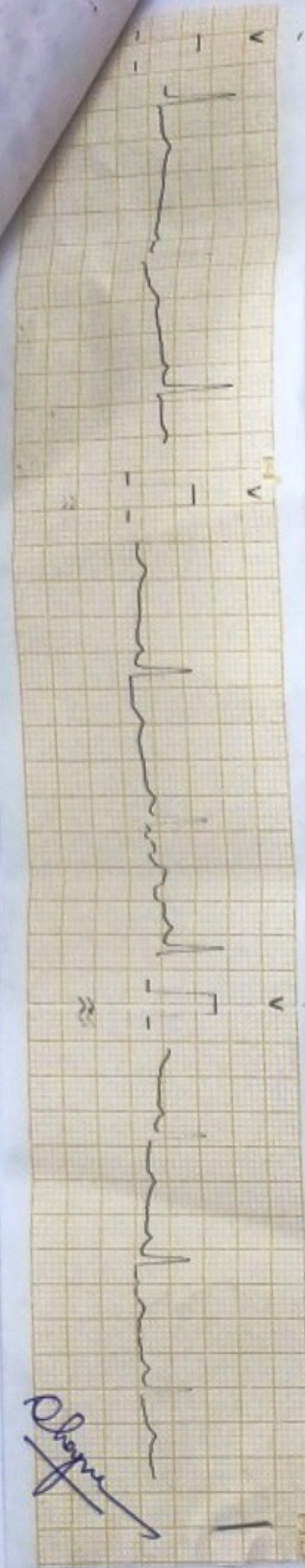
Other: NIL
On examination he/she appears physically and mentally fit: Yes/No

Signature of Examinee: [Signature] Name of Examinee Mrs. DHARNA YEDE

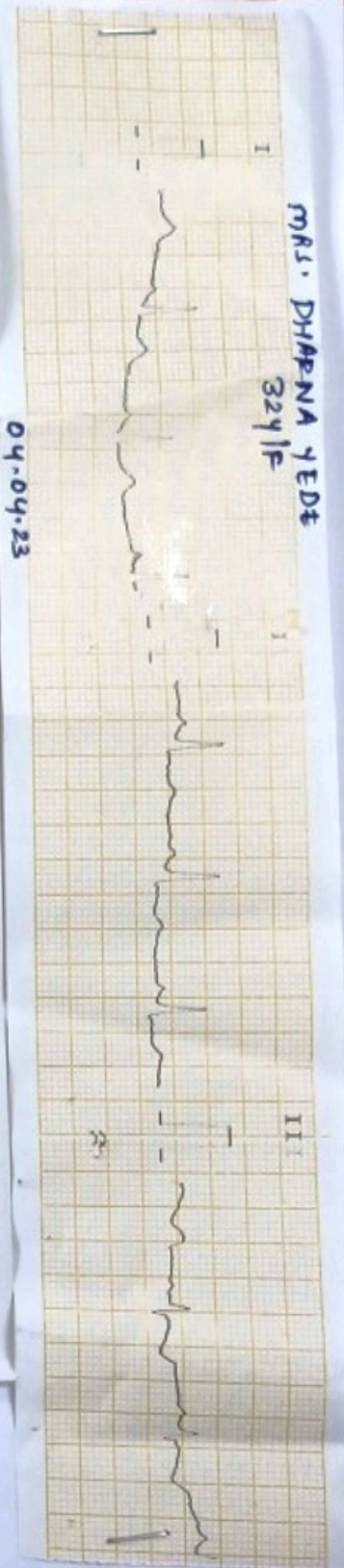
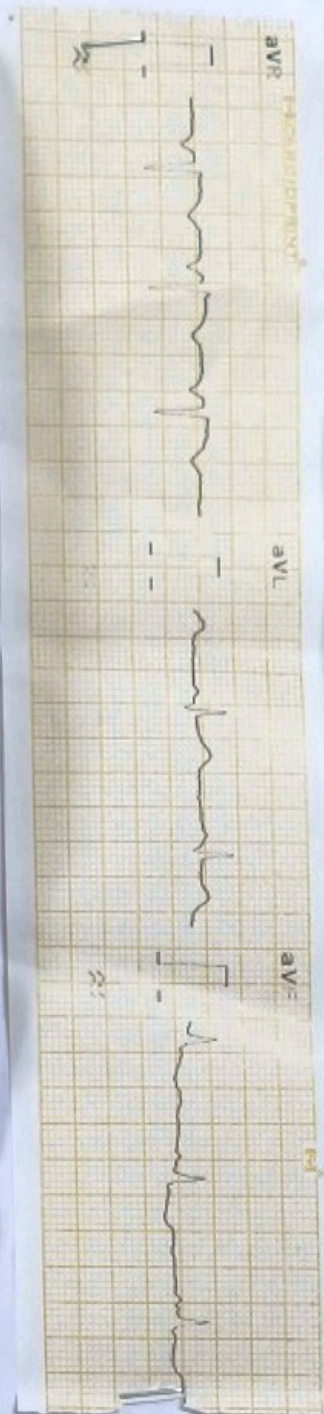
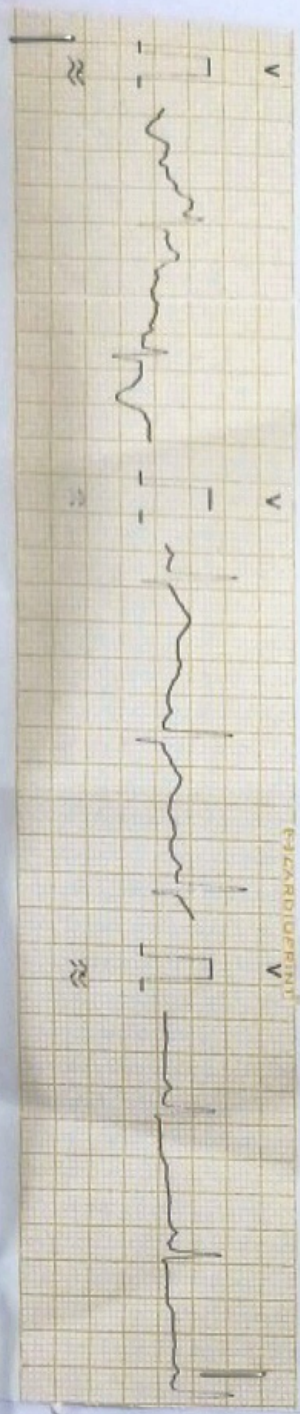
Signature Medical Examiner: [Signature] Name Medical Examiner Dr. B. M. SHARNAGAT
M.D. (Medical) Regd No 4612
AYUS HOSPITAL
& Diagnostic Research CL
BALAGHAT (P.O.) 481001

|| उपलब्ध सुविधाएं ||

- क्रिटिकल केयर युनिट/आई.सी.सी.यू., सेंट्रल ऑक्सीजन पाइप लाईन युक्त ● फेफड़ों के कार्य क्षमता की कम्प्यूटराईज्ड जांच (P.F.T.)
- मल्टीपैरा, पल्स ऑक्स, डीप्रिब्रीलेटर एवं इन्टीलेटर सुविधाएं ● फिजियोथेरेपी युनिट एवं डायटिशियन परामर्श।
- कम्प्यूटराईज्ड ई.सी.जी., टी.एम.टी., होल्टर मॉनिटरिंग व अल्ट्रासोनो नेबुलाईजेशन ● डायबीटिज, अस्थमा एवं किडनी क्लिनिक।
- एक्सरे, पैथालॉजी, मेडिकल स्टोर्स व कैंटीन सुविधा ● मनोचिकित्सक, चर्मरोग, कैंसर एवं किडनी विशेषज्ञ द्वारा परामर्श - प्रति रविवार
- सेंट्रली एयर कूल्ड एवं ए.सी.युक्त प्राइवेट एवं कनरल वार्ड ● 24 घंटे इमरजेंसी सेवा, एम्बुलेन्स एवं विद्युत जनरेटर व्यवस्था।



Chopra



MRS. DHARNA YEDT
32y/f

04.04.23

[Signature]
Dr. B. M. SHARNI, M.D.
MD (Internal Medicine) Reg. No. 12
SRI SANKARAN HOSPITAL
& Research Center
BANGALURU (M.P.)

2D ECHOCARDIOGRAPHY AND DOPPLER REPORT

Name – MRS. DHARNA YEDE

Age – 32 Yrs/F

Refd. By - SELF

Date - 04.04.2023

M-Mode & Essential Measurements :-

Heart Rate : 82 Bpm	LVID(D) : 42 mm	MV Annulus : 24mm	RVID(d) : 34mm
Aortic Root : 31 mm	LVID(S) : 25 mm	TV Annulus : 22mm	IVC : 18 mm
Left Atrium : 33 mm	IVSd (D) : 10 mm	AO Annulus : 19mm	Mitral-Epss : 06 mm
LVEF : 60 %	LVPWd(D):09 mm	PV Annulus : 20mm	TAPSE : 16 mm

2D Echo Findings :-


- RWM(LV) : **NORMAL**
- VALVES : **NORMAL**
- CHAMBERS : **NORMAL SIZED**
- IAS/IVS : **INTACT**
- CLOT/VEGETATION : **NIL**
- PERICARDIAL EFFUSION : **NIL**
- PLEURAL EFFUSION : **NIL**

Doppler Study :-

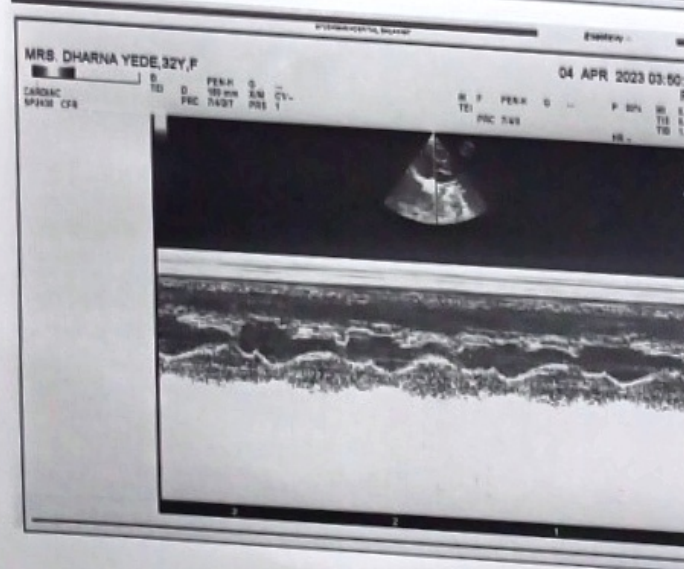
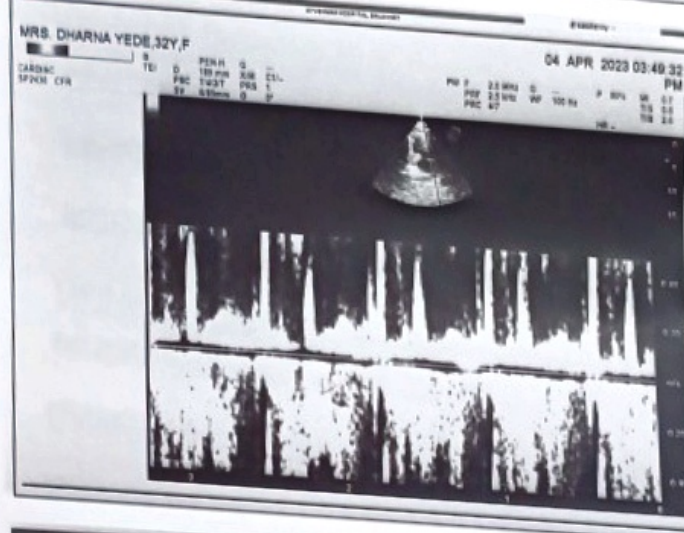
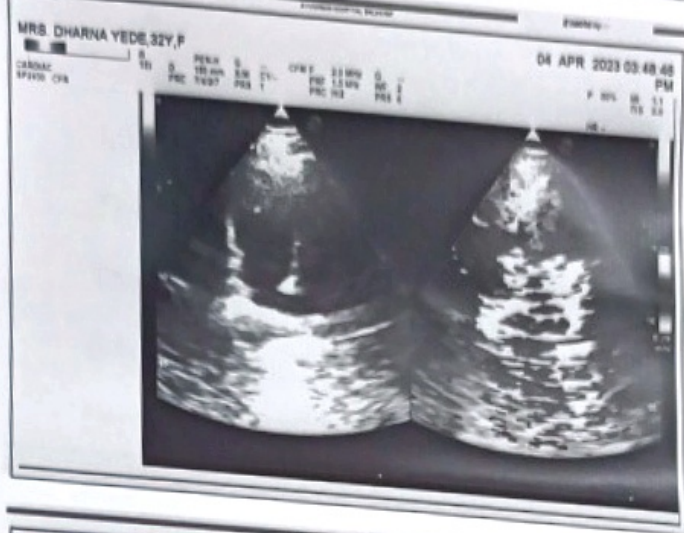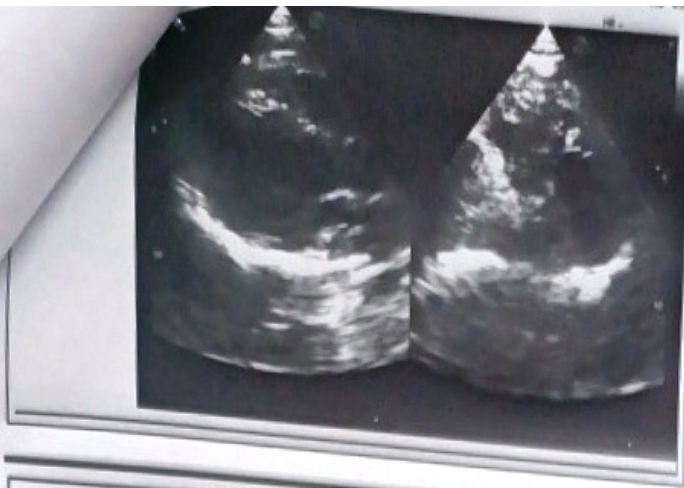	Peak Gradient (mm of Hg)	Mean Gradient (mm of Hg)	Valve area (Normal Range)	Grade of Regurgitation
Mitral Valve	--	--	4.0-6.0	NIL
Aortic Valve	--	--	2.5-4.0	NIL
Tricuspid Valve	--	--	7.0-9.0	NIL
Pulmonary Valve	--	--	2.0-3.0	NIL


Estimated PASP by TR jet = 25 mm of Hg.

FINAL DIAGNOSIS :- NO RWMA , NO LVDD , NORMAL VALVES , NORMAL - BIVENTRICULAR FUNCTION.



Dr. B.M. SHARNAGAT
 Dr. B.M. Sharnagat (MD Medicine)
 AYUSHMAN HOSPITAL
 & Diagnostic Research Center
 BALAGHAT (M P) 481001





ULTRASOUND REPORT

Name - MRS . DHARNA YEDE

Age - 32 Yrs/F

Refd. By - SELF

Date - 04.04.2023

LIVER: The liver is normal in size and shape . it shows normal parenchymal echotexture.

The IHBR, IHPR and porta hepatis appear normal.

There is no e/o any lesion.

GALLBLADDER: Normal there is no e/o evidence of calculi.

PANCREAS: Normal in size and shows normal echotexture.

SPLEEN : Spleen is normal in size and shows homogenous echotexture.

KIDNEYS : Both Kidneys are normal in size, shape, contour and in position . There is no renal calculi and no pelvicalyceal dilatation .

LEFT KIDNEY MEASURES : 8.4 X 3.2 CM

RIGHT KIDNEY MEASURES : 8.0 X 3.0 CM

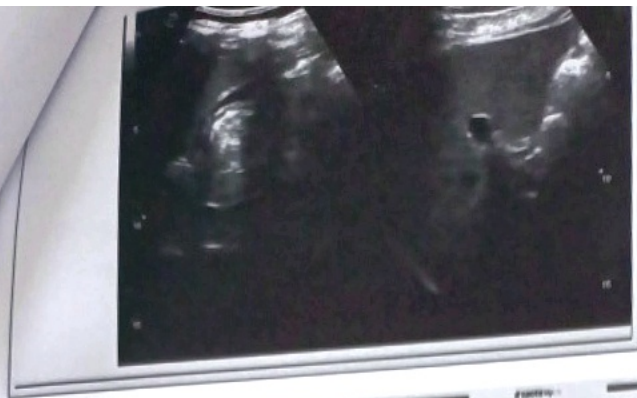URINARY BLADDER : Bladder is normal in shape . There is no intravesical calculi . There is no evidence of any residual urine.

OVARIES & UTERUS : Both ovaries & uterus are normal in size , contour & echogenicity.

There is no e/o free Fluid in pelvis .

IMPRESSION : NORMAL STUDY OF ABDOMEN .

Dr. B.M. SHARNAGAT
M.D.(Medicine) Regd No 4612
Dr. B.M. SHARNAGAT (MD Medicine)
& Diagnostic Research Center
BALAGHAT (M.P) 481001



04 APR 2023 03:52:12 PM
P 80% M 1.1

MRS DHARNA YEDE, 32Y, F
TEI 0 REFL 0
12.0MHz 2.0M C/L
PAC 0004 PLS 1

ABDOMINAL
AC2041 ASD

This is the second ultrasound image from the top. It shows a cross-section of the abdomen with some internal structures visible. The image is somewhat dark and blurry.

04 APR 2023 03:52:57 PM
P 80% M 1.1

MRS DHARNA YEDE, 32Y, F
TEI 0 REFL 0
12.0MHz 2.0M C/L
PAC 0004 PLS 1

ABDOMINAL
AC2041 ASD

This is the third ultrasound image from the top. It shows a cross-section of the abdomen with some internal structures visible. The image is somewhat dark and blurry.

04 APR 2023 03:53:25 PM
P 80% M 1.1

MRS DHARNA YEDE, 32Y, F
TEI 0 REFL 0
12.0MHz 2.0M C/L
PAC 0004 PLS 1

ABDOMINAL
AC2041 ASD

This is the bottom-most ultrasound image on the page. It shows a cross-section of the abdomen with some internal structures visible. The image is somewhat dark and blurry.



क्रिटिकल केयर युनिट I.C.C.U. सुविधा युक्त

आयुष्मान हॉस्पिटल

एण्ड डॉयग्नोस्टिक रिसर्च सेन्टर

सर्किट हाऊस रोड, बालाघाट ☎ 07632:241070

REGD.No. : NHA/REG/BGT/2012/21

PATHOLOGY REPORT

• Auto Analyzer • Hematology Analyzer A.B.G. • Computerised Lab

NAME : MRS. DHARNA YEDE

AGE : 30Yrs.

SEX : F

REF. BY : Dr. B. M. SHARNAGAT (M.D.)

DATE : 04/04/2023

BIOCHEMISTRY

TESTS	RESULTS	UNITS	REF. RANGE
LIPID PROFILE			
S. Cholesterol	:148	mg/dl	UP TO <200
S. Triglycerides	:120	mg/dl	UP TO <150
HDL Cholesterol	:34	mg/dl	32 -60
LDL Cholesterol	:89	mg/dl	UP TO <100
VLDL Cholesterol	:22	mg/dl	7 - 35
LDL / HDL Ratio	:3.6	%	2.5 - 5.0
S. Cholesterol / HDL Ratio	:4.3	%	3.5 - 5.0
KFT			
Serum CREATININE	:0.96	mg/dl	0.8-1.2
BUN	:15	mg/dl	8-20
BUN Creatinine Ratio	:15.9		
LFT			
Bilirubin-Total	:0.8	mg%	0-1.2
Direct	:0.4	mg%	0-0.6
Indirect	:0.4	mg%	0-0.5
SGPT(ALT)	:13	IU/L	7-35
SGOT(AST)	:18	IU/L	8-40
Alk.Phosphatase	:75	U/L	86-306 Adult
TOTAL PROTEINS	6.8	gm/dl	6.2-8.2
Albumin	4.3	g/dl	3.5-5.5
Globulin	2.5	g/dl	2.5-3.2
A/G Ratio	2.0		1.5-2.5
GGT	28	U/L	9-48
S.URIC ACID	4.8	mg/dl	3.4- 7.2

Dr. B. M. SHARNAGAT
M.D. (Medicine) Regd No. 4612
AYUSHMAN HOSPITAL
& Diagnostic Research Center
(Ayushman Hospital, Balaghat)

This Report is not valid for MLC purpose.

This Report is only for Physician's help to confirm the diagnosis.



क्रिटिकल केयर युनिट I.C.C.U.सुविधायुक्त

आयुष्मान हॉस्पिटल

एण्ड डॉयग्नोस्टिक रिसर्च सेन्टर

सर्किट हाऊस रोड, बालाघाट ☎ 07632:241070

REGD.No. : NHA/REG/BGT/2012/21

PATHOLOGY REPORT

• Auto Analyzer • Hematology Analyzer A.B.G. Computerised Lab

NAME : MRS. DHARNA YEDE

AGE : 30Yrs.

SEX : F

REF. BY : Dr. B. M. SHARNAGAT (M.D.)

DATE : 04/04/2023

TESTS	RESULTS	UNITS	REF. RANGE
-------	---------	-------	------------

BLOOD SUGAR

B.SUGAR (f)	:89	mg/ dl	60-100
(p.p)	:129	mg/dl	120-160
METHOD : GOD-POD			

HbA1C 5.4 %

Nondiabetic :4.5 -6.2

Good Control:6.0 -7.0%

Fair Control: 7.0 -8%

Poor Control: >8%

(Action Suggested)

Blood group	B		
Rh Type	Positive		
ESR	:08 1st Hr	0-10	
Method	westerangreen		

STOOL EXAMINATION

Stool for Routine& Microscopic Examination	: Normal
Stool for Occult blood	:Negative

THYROID HORMONE

TSH	3.2	uIU/ml	0.3 - 5.0
T3	0.74	ng/ml	0.6-1.8
T4	6.2	ug/dl	5.0-12.5

REPOT ON SEROLOGY

V.D.R.L : NON-REACTIVE

Dr. B. M. SHARNAGAT
M.D. (Medicine) Reg. No. 4812
(Ayushman Hospital Balaghat)
& Diagnostic Research Ceter
BALAGHAT (M P) 481001

• This Report is not valid for MLC purpose.

• This Report is only for Physician's help to confirm the diagnosis.

क्रिटिकल केयर युनिट I.C.C.U. सुविधायुक्त

आयुष्मान हॉस्पिटल

एण्ड डायग्नोस्टिक रिसर्च सेन्टर

सर्किट हाऊस रोड, बालाघाट 07632:241070

REGD.No. : NHA/REG/BGT/2012/24

PATHOLOGY REPORT

• Auto Analyzer • Hematology Analyzer • A.B.G. • Computerised Lab

NAME : MRS. DHARNA YEDE

AGE : 30Yrs.

SEX : F

REF. BY : Dr. B. M. SHARNAGAT (M.D.)

DATE : 04/04/2023

URINE ANALYSIS REPORT (By urometer120 analyzer)

PHYSICAL EXAMINATION


Colour : pale Yellow
Quantity : 10ml
Apperance : clear

CHEMICAL EXAMINATION

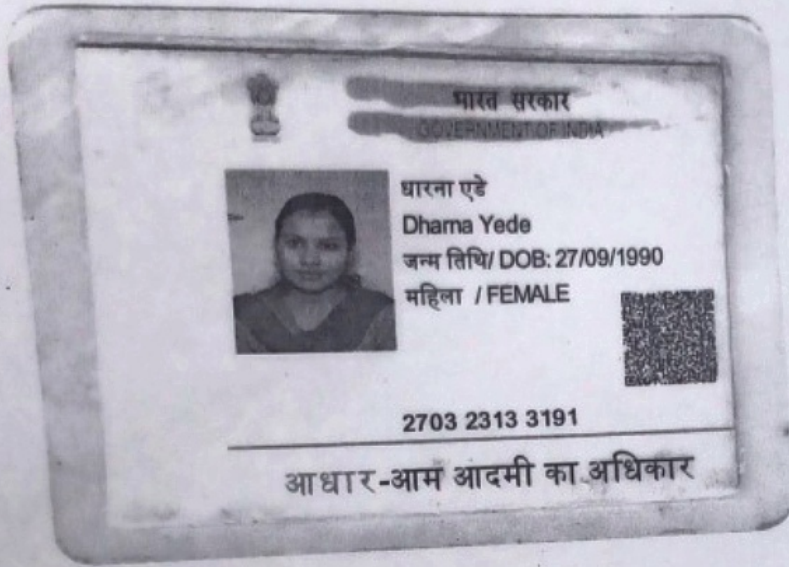Sugar : nil
Bile Pigment : nil
Bile Salt : nil
Nitrite : nil
Protein : nil
Bilirubin : nil
Ketone : nil
Albumin : nil
Urobilinogen : Normal 0.01 mg/ml
Specific gravity : 1.010 1.010-1.030
Reaction(pH) : 6.0 (Acidic3-6, Alkaline8-10)

MICROSOPIC EXAMINATION

Pus(WBCs) Cells : NIL/ hpf
RBC : nil/hpf
Crystals : Absent
Spermatozoa : Absent
Epithelial Cells : Absent
Bacteria : Absent


Dr. B.M. SHARNAGAT
M.D. (Medicine) Regd No. 4612
A/C Pathologist/Technician
& Director (Hospital Balaghat)
BALAGHAT (M.P.) 481001

- This Report is not valid for MLC purpose.
- This Report is only for Physician's help to confirm the diagnosis.



[Handwritten signature]

[Handwritten signature]

Dr. B.M. SHARNAGAT
M D. (Medicine) Regd No.4612
AYUSHMAN HOSPITAL
& Diagnostic Research Ceter
BALAGHAT (M.P) 481001