



**LAB REPORT**

Patient Name : Mr. CHOKKAULA RAMAKRISHNA  
Age / Gender : 48-Years / Male  
UHID ID : MH20220040349  
Doctor Name : Dr. ARUN PRAKASH  
OP Report No. : INVA2107196  
Bill No. : INV2204208  
Sample Date : 28/09/2022 - 09:59 AM  
Report Date : 28/09/2022 - 07:55 PM

Test Name	Result	Units	Reference Interval
<b>HAEMATOLOGY</b>			
<b>Complete Blood Cell Count(CBC)</b>			
HAEMOGLOBIN	16.2	gms/dl	male :13.0 - 17.0 female :12.0 - 15.0
PACKED CELL VOLUME	<u>50.6</u>	%	male : 40 - 50 female : 36 - 46
RBC COUNT	<u>5.62</u>	millions cells/cu.mm	female: 3.8 - 4.8 male : 4.5 - 5.5
TOTAL WBC	5,800	Cells/Cumm	4,000 - 11,000
<b>Differential Count</b>			
NEUTROPHILS	60	%	40 - 65
LYMPHOCYTES	35	%	30-50
EOSINOPHILS	05	%	01-06
MONOCYTES	<u>00</u>	%	1-10
BASOPHILS	00	%	0-2
ESR 60 MTS	05	mm	5 - 20
PLATELET COUNT	<u>1.42</u>	Lakhs/cumm	1.5 - 4.5
MCV	90.1	fL	76 - 96
MCH	28.8	pg	27 - 32
MCHC	32.0	gms/dl	30 - 36

*INTERPRETATION: Test done on automated three part cell counter, all abnormal results are reviewed and confirmed microscopically.*

**BLOOD GROUPING & RH TYPING** \* O \* POSITIVE

**Healing Hearts and Lives**

264/125, Kilpauk Garden Road, Kilpauk, Chennai - 600 010.  
Phone : +91 44 4644 8989 / 75500 53335 | Email : muruganhosp@gmail.com  
Website : www.muruganhospitals.in



**LAB REPORT**

Patient Name : Mr. CHOKKAULA RAMAKRISHNA  
Age / Gender : 48-Years / Male  
UHID ID : MH20220040349  
Doctor Name : Dr. ARUN PRAKASH

OP Report No. : INVA2107196  
Bill No. : INV2204208  
Sample Date : 28/09/2022 - 09:59 AM  
Report Date : 28/09/2022 - 07:55 PM

Test Name	Result	Units	Reference Interval
<b>BIO CHEMISTRY</b>			
BLOOD SUGAR FASTING	86	mgs/dl	70-110
BLOOD SUGAR POST PRANDIAL	100	mgs/dl	80- 160
SERUM CREATININE	1.1	mg/dl	0.6-1.4
SERUM URIC ACID	5.0	mg/dl	male 3.1-7.0 , female 2.5-5.6
<b>LIPID PROFILE</b>			
TOTALCHOLESTEROL	194	mg/dl	< 200
TRIGLYCERIDE	88	mg/dl	< 150
HDL	40	mg/dl	35 - 80
VLDL	18	mg/dl	2 to 30
LDL	136	mg/dl	<130
CHOLESTEROL/ HDL RATIO	4.8	mg/dl	



### LAB REPORT

Patient Name : Mr. CHOKKAULA RAMAKRISHNA  
 Age / Gender : 48-Years / Male  
 UHID ID : MH20220040349  
 Doctor Name : Dr. ARUN PRAKASH

OP Report No. : INVA2107196  
 Bill No. : INV2204208  
 Sample Date : 28/09/2022 - 09:59 AM  
 Report Date : 28/09/2022 - 07:55 PM

Test Name	Result	Units	Reference Interval
<b>LIVER FUNCTION TEST</b>			
BILLIRUBIN(TOTAL)	1.0	mg/dl	0.0 -1.0
BILLIRUBIN(DIRECT)	0.2	mg/dl	0.1- 0.30
BILLIRUBIN(INDIRECT)	0.8	mg/dl	0.2-0.8
SGOT	32	IU/L	0-38
SGPT	27	IU/L	0.0-40
ALKALINE PHOSPHATASE	85	IU/L	40-140 4-6Years 93-309 13-15Years 74-390
TOTAL PROTEIN	7.3	gm/dl	6.6-8.7
ALBUMIN	4.3	gm/dl	3.5 - 5.5
GLOBULIN	3.0	gm/dl	2.0-3.5
AG RATIO	1.4		
GAMMA G T	20	U/L	male<49 female<32
BLOOD UREA NITROGEN	11	mg/dl	7-21
HBA1C	5.3	%	normal: <6.0 good control: 6.1-7.0 fair control: 7.1- 8.0 poor control:8.1 -10.0 unsatisfactory: >10.0



**LAB REPORT**

Patient Name : Mr. CHOKKAULA RAMAKRISHNA  
Age / Gender : 48-Years / Male  
UHID ID : MH20220040349  
Doctor Name : Dr. ARUN PRAKASH

OP Report No. : INVA2107196  
Bill No. : INV2204208  
Sample Date : 28/09/2022 - 09:59 AM  
Report Date : 28/09/2022 - 07:55 PM

Test Name	Result	Units	Reference Interval
<b>CLINICAL PATHOLOGY</b>			
URINE SUGAR (F)	NIL		
URINE SUGAR (PP)	NIL		
<b>URINE ROUTINE</b>			
COLOUR	YELLOW		
APPEARANCE	CLEAR		
REACTION	ACIDIC		
SUGAR	NIL		
ALBUMIN	NIL		
<b>DEPOSITES</b>			
PUS CELLS	2 - 3	/ HPF	
EPI CELLS	1 - 2	/ HPF	
RBC COUNT	NIL	/ HPF	
CAST	NIL		
CRYSTALS	NIL		
OTHERS	NIL		

SHENBAGAVALLI

Verified by

\*\*\* End of Report \*\*\*

**PAVITHRA**  
Pathologist  
Reg. No.: 78288





**LAB REPORT**

NAME	: MR. CHOKKAKULA RAMAKRISHNA	SAMPLE NO	: 382289412
PIN	: AND22380135076	COLLECTED ON	: 28/09/2022 03:56 PM
AGE/GENDER	: 48 Year(s)/Male	RECEIVED ON	: 28/09/2022 03:57 PM
REFERRED BY	: Dr.ARUN PRAKASH	REPORTED ON	: 28/09/2022 05:55 PM
CLIENT NAME	: MURUGAN HOSPITAL	REPRINT DATE	: 28/09/2022 05:55 PM

Test	Obtained Value	Units	Bio.Ref.Intervals
<b>CLINICAL PATHOLOGY</b>			
<b>Stool Routine</b>			
<b>General Examination (Stool)</b>			
Colour	Yellow		Yellow to Brown
Form & Consistency	Semi solid		Semi solid
Mucus	Absent		Absent
Blood	Absent		Absent
<b>Chemical Examination (Stool)</b>			
pH( pH strip test)	ACIDIC		Variable depending on food
<b>Microscopy (Saline and Iodine mount) (Stool)</b>			
Cyst	Not Present		Absent
Ova	Not Present		Absent
Trophozoites	Not Present		
Red Blood Cells	Not Present	/hpf	Absent
Pus Cells	2-3	/hpf	0-5
Epithelial Cells	Not Present	/hpf	0-4
OTHER	Not present		

-- End of Report --

*Dr Sarangan*  
Dr Sarangan A MD Pathology  
Consultant Pathology  
Reg. No. 04981

**Healing Hearts and Lives**

264/125, Kilpauk Garden Road, Kilpauk, Chennai - 600 010.  
Phone : +91 44 4644 8989 / 75500 53335 | Email : muruganhosp@gmail.com  
Website : www.muruganhospitals.in



# MURUGAN HOSPITALS

HEALING HANDS




## LAB REPORT

NAME	: MR. CHOKKAKULA RAMAKRISHNA	SAMPLE NO	: 382289412
PIN	: AND22380135076	COLLECTED ON	: 28/09/2022 03:56 PM
AGE/GENDER	: 48 Year(s)/Male	RECEIVED ON	: 28/09/2022 03:57 PM
REFERRED BY	: Dr.ARUN PRAKASH	REPORTED ON	: 28/09/2022 05:55 PM
CLIENT NAME	: MURUGAN HOSPITAL	REPRINT DATE	: 28/09/2022 05:55 PM

Test	Obtained Value	Units	Bio.Ref.Intervals
<b>IMMUNOASSAY</b>			
PSA(Prostate Specific Antigen) - Total, Serum (SERUM,ECLIA)	0.430	ng/mL	<= 2.0



  
Dr. T. Uma MD, DCP  
Consultant Biochemist

**Healing Hearts and Lives**

264/125, Kilpauk Garden Road, Kilpauk, Chennai - 600 010.  
Phone : +91 44 4644 8989 / 75500 53335 | Email : muruganhosp@gmail.com  
Website : www.muruganhospitals.in



# MURUGAN HOSPITALS

HEALING HANDS



## LAB REPORT

Patient Name : Mr. CHOKKAULA RAMAKRISHNA  
Age / Gender : 48-Years / Male  
UHID ID : MH20220040349  
Doctor Name : Dr. ARUN PRAKASH

OP Report No. : INVA2107196  
Bill No. : INV2204208  
Sample Date : 28/09/2022 - 09:59 AM  
Report Date : 29/09/2022 - 09:52 AM

Test Name	Result	Units	Reference Interval
<b>ENDOCRINOLOGY</b>			
T3	1.523	ng/ml	0.52-1.85
T4	8.724	ug/dl	5.0 -13.0 ug/dl
TSH	1.859	uIU/ml	0.39 - 6.16 uIU/ml

SHENBAGAVALLI

Verified by

\*\*\* End of Report \*\*\*

Authorized Signature

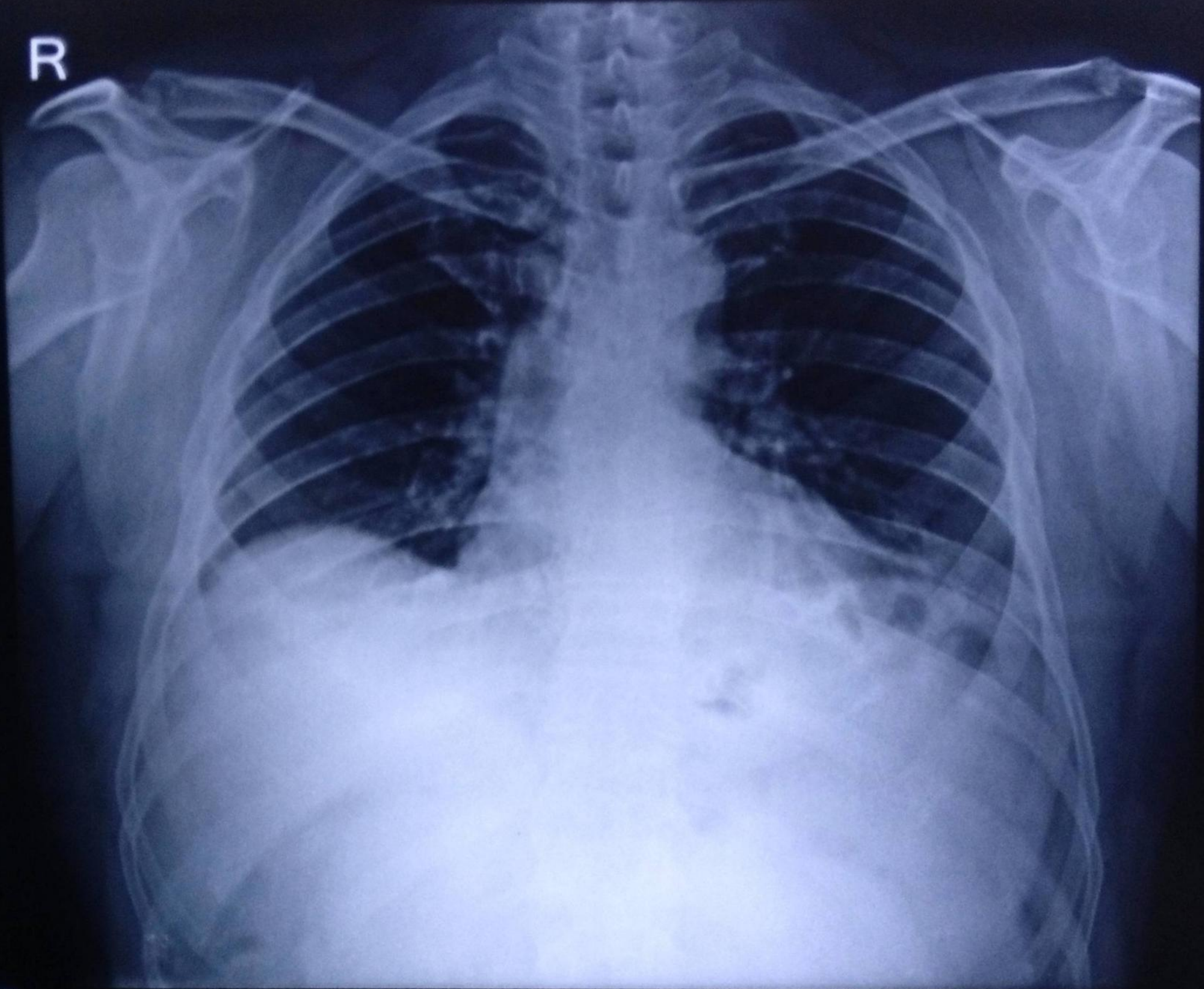


PAVITHRA  
Pathologist  
Reg. No.: 78256

Healing Hearts and Lives

264/125, Kilpauk Garden Road, Kilpauk, Chennai - 600 010.  
Phone : +91 44 4644 8989 / 75500 53335 | Email : muruganhosp@gmail.com  
Website : www.muruganhospitals.in

R



MR.CHOK KAULA RAMAKRISHNA 48YRS 40349 CHEST-PA 28-09-2022



*Scanned by TapScanner*





**MURUGAN HOSPITALS**  
HEALING HANDS



**SCAN REPORT**

NAME : CHOKKAULA RAMAKRISHNA  
AGE / GENDER : 48 YEARS / MALE  
CONSULTANT : DR. ARUNPRAKASH

UHID : MH20220040349  
IP/OP : OP  
DATE : 28.09.2022

**X-RAY CHEST (PA VIEW)**

- The cardio thoracic ratio is normal
- The heart size and configuration are within normal limits
- The aortic arch is normal
- The lung fields show normal broncho-vascular markings
- Both the pulmonary hila are normal in size
- The costophrenic and cardiophrenic recesses and the domes of diaphragm are normal
- The bones and soft tissues of the chest wall show no abnormality

**IMPRESSION:**

Normal Study



**Healing Hearts and Lives**

264/125, Kilpauk Garden Road, Kilpauk, Chennai - 600 010. Phone : +91 44 4644 8989 / 75500 53335  
Email : muruganhosp@gmail.com | Website : www.muruganhospitals.in



**MURUGAN HOSPITALS**  
HEALING HANDS

NAME: MR.CHOKKAULA RAMAKRISHNA  
AGE / SEX : 48Y/MALE  
CONSULTAN: DR.ARUN PRAKASH

UHID : MH20220040349  
OP/IP : OP  
DATE :28.09.2022

ENT

**Bilateral Ear :**

Normal; no obvious reduction in conduction of sound or any other pathology.

**Bilateral Nose :**

No nasal deviation / septal defect.

**Throat :**

Clear and malampati class I.

  
**CONSULTANT ENT**

264/125, Kilpauk Garden Road, Kilpauk, Chennai - 600 010.

☎ : +91 44 4644 8989 / 75500 53335 email : muruganhosp@gmail.com

Website : www.muruganhospitals.in



**MURUGAN HOSPITALS**  
HEALING HANDS

NAME: MR. CHOKKAULA RAMAKRISHNA  
AGE / SEX : 48 Y/MALE  
CONSULTAN: DR.ARUN PRAKASH

UHID : MH20220040349  
OP/IP : OP  
DATE :28.09.2022

**DENTAL**

- Maxilla – No abnormal defecit.
- Sinus – No abnormal defecit.
- Nasal Cavity – No abnormal defecit.
- Air spaces not included in the limited volume.
- Otherwise normal.



**CONSULTANT DENTISIT**

264/125, Kilpauk Garden Road, Kilpauk, Chennai - 600 010.

© : +91 44 4644 8989 / 75500 53335 email : muruganhosp@gmail.com

Website : www.muruganhospitals.in



**ECHO CARDIOGRAM REPORT**

NAME : MR.CHOKKAULA RAMAKRISHNA UHID NO: MH20220040349  
 AGE&SEX :48 Y/MALE IP/OP :OUTPATIENT  
 CONSULTANT: DR. ARUN PRAKASH DATE : 28-09-2022

**2D PLAX (mm)**

RV - 33 mm  
 AO - 30 mm  
 LA - 38 mm

**COLOR DOPPLER**

Normal

**M-Mode (mm)**

IVS - 06 mm  
 PW - 08 mm  
 LVD - 47 mm  
 LVS - 34 mm  
 EF - 65 %  
 FS - 35 %

**DOPPLER (m/sec)**

MITRAL E - 0.4 m/s  
 MITRAL A - 0.5 m/s  
 PULMONARY - 0.9 m/s  
 AORTIC - 1.2 m/s  
 TRICUSPID - 0.4 m/s

**IMPRESSION:**

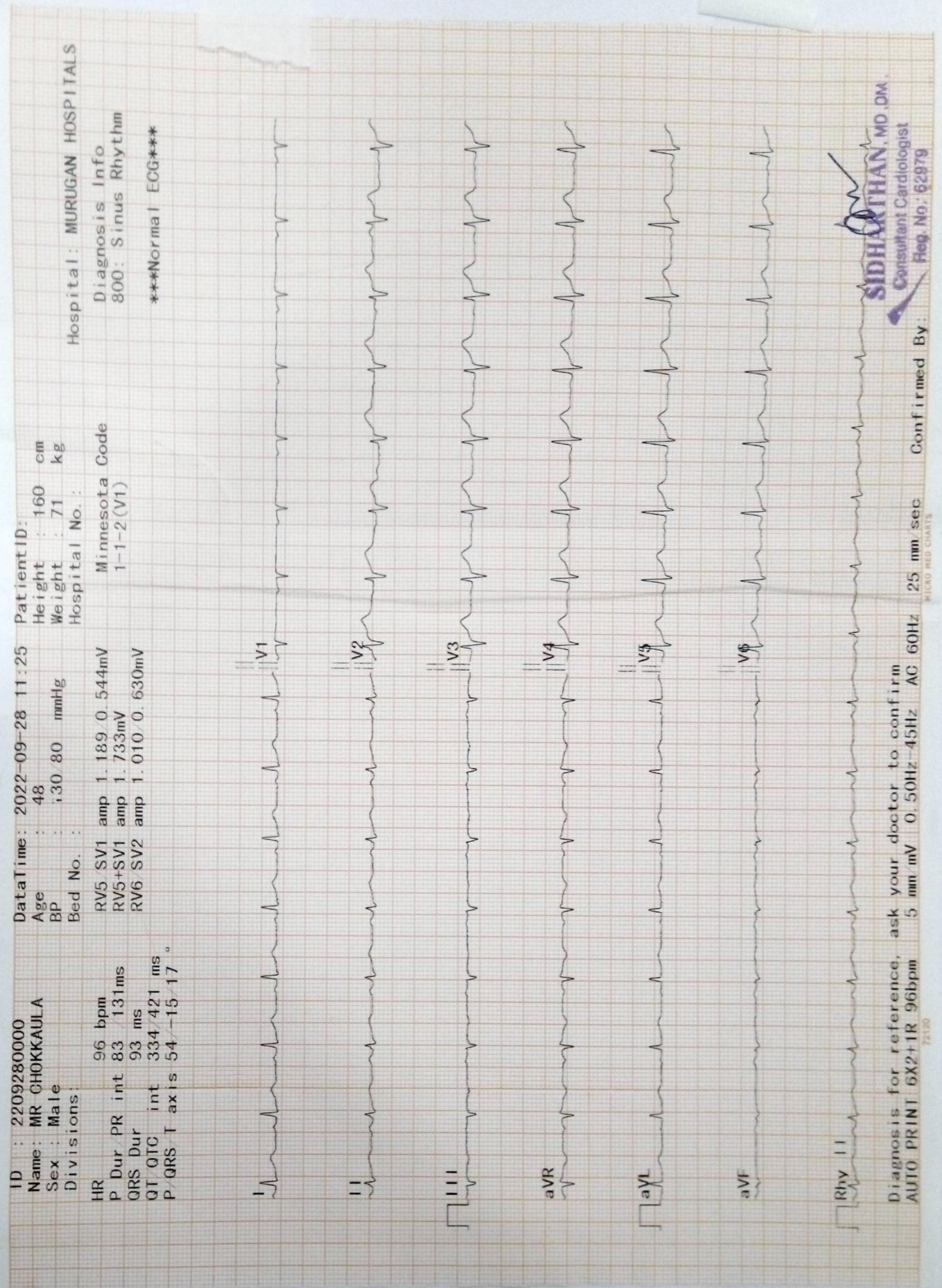
Tachycardia noted during study  
 No RWMA  
 Normal LV Systolic function  
 Grade I left ventricular diastolic dysfunction  
 Normal RV function  
 No pulmonary hypertension  
 No pericardial effusion  
 No clot/ Vegetation.



DR.SIDHARTHAN MD.,DM.,  
CONSULTANT CARDIOLOGIST

Healing Hearts and Lives

264/125, Kilpauk Garden Road, Kilpauk, Chennai - 600 010.  
 Phone : +91 44 4644 8989 / 75500 53335 | Email : muruganhosp@gmail.com  
 Website : www.muruganhospitals.in





# MURUGAN HOSPITALS

HEALING HANDS



## SCAN REPORT

NAME	:MR.CHOKKAULA RAMAKRISHNA	PATIENT ID	:MH20220040349
AGE/SEX	:48 Years /MALE	IP / OP NO	:OP21031555
CONSULTANT	:DR.ARUN PRAKASH	DATE	:28/09/2022

### ULTRA SOUND SCAN OF ABDOMEN

**LIVER:** Normal in size and normal in echotexture. No focal lesions are seen. No dilatation of intra-hepatic biliary radicals present. Hepatic veins and IVC appear normal. Portal vein is normal in caliber. Common bile duct is normal in caliber.

**GALL BLADDER:** Contracted.

**PANCREAS:** Normal in size and echotexture. No focal lesions are seen. No evidence of calculi or calcifications. No evidence of pancreatic duct dilation.

**PARA AORTIC AREAS:** Aorta and IVC appear normal. No evidence of para aortic lymphadenopathy.

**SPLEEN:** Normal in size and measures-11.2 cm. Normal in echotexture. No evidence of focal lesions.

**RIGHT KIDNEY:** Measures 10.6 X 4.5 cm and is normal in size and echotexture. Cortico medullary differentiation is well maintained. There is no hydronephrosis or mass.

**LEFT KIDNEY:** Measures 10.9 x 5.2 cm and is normal in size and echotexture. Cortico medullary differentiation is well maintained. There is no calculus or hydronephrosis or mass.

Healing Hearts and Lives

264/125, Kilpauk Garden Road, Kilpauk, Chennai - 600 010. Phone : +91 44 4644 8989 / 75500 53335  
Email : muruganhosp@gmail.com | Website : www.muruganhospitals.in

**URINARY BLADDER:** Normal in size, contour and wall thickness. There is no evidence of calculus or mass. No vesical diverticulum present.

**PROSTATE:** Normal in size and measures- 2.4 x 3.1 x 2.6 cm echotexture. Volume- 10.8 cc.

Seminal vesicles appear normal

No ascites present. No retroperitoneal lymphadenopathy present.

**IMPRESSION:**

*No significant abnormality detected in the visualized abdominal organs.*



**DR.SAKTHI MDRD.,**

**CONSULTANT RADIOLOGIST.,**