

बैंक ऑफ बरोडा
Bank of Baroda



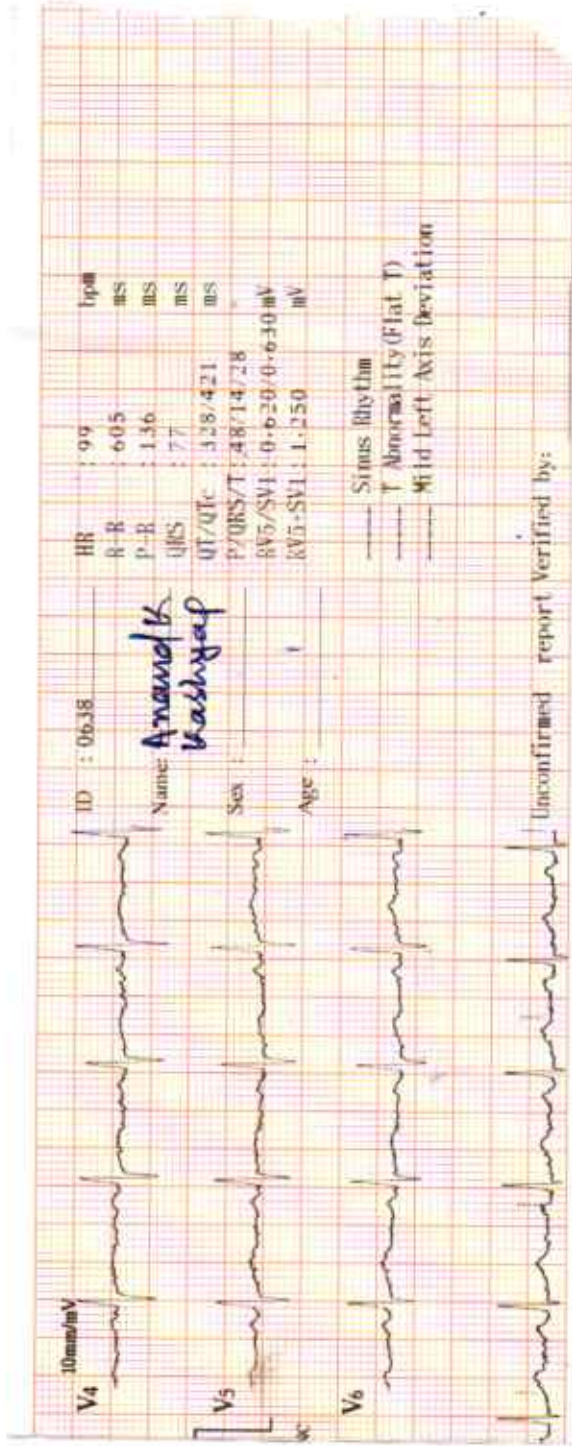
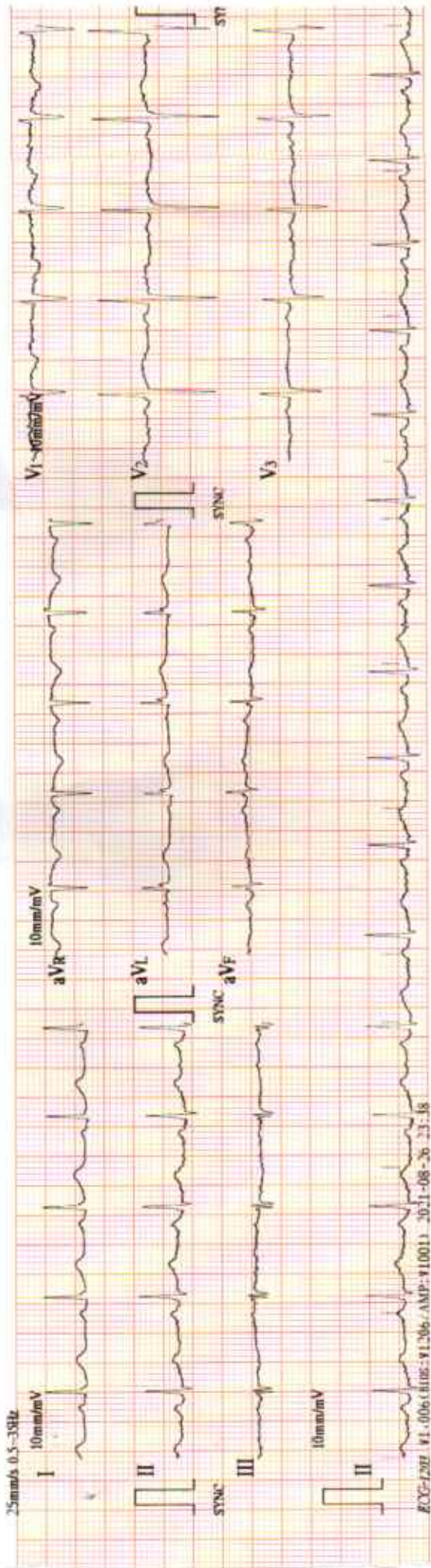
नाम
Name ANAND KUMAR KASHYAP

कार्यकारी कूट क्र.
E.C. No. 116199

आधिकारित अधिकारी (आ. अ. अ.)
Issuing Authority (A. A. A.)



कार्यकारी के हस्ताक्षर
Signature of Holder



HR : 99 bpm
R-R : 605 ms
P-R : 156 ms
QRS : 77 ms
QT/QTc : 328/421 ms
P/ORS/T : 48/14/28
RV5/SV1 : 0.620/0.630 mV
RV5-SV1 : 1.250 mV

- Sinus Rhythm
- T Abnormality (Flat T)
- Mild Left Axis Deviation

ID : 0638
Name: Anand K. Kashyap
Sex :
Age :

Unconfirmed report Verified by:

R

R

MR. ANAND KASHYAP 31Y Male

Chest PA

3

27/08/2021

BOB

BHARTI HOSPITAL SONKH ROAD, KRISHNA NAGAR, MATHURA



Bharti Hospital

AN ISO 9001-2008 (QMS) Certified Hospital

Date.....

Patient Name:	MR.ANAND KASHYAP	Patient ID:	0000
Age:	Years	Sex:	M
Referring Physician:	BOB	Study Date:	27-Aug-2021

DIGITAL RADIOGRAPH CHEST PA VIEW

Prominent bronchovascular markings noted in bilateral lung fields.

Bilateral hilar prominence noted.

Both domes of diaphragm and CP angles are normal.

No evidence of mediastinal shift is seen.

Cardiac size is normal.

All bony cage are normal.

AD:- Kindly Review with clinical findings.

Dr. Maulik Patel
MD Radiodiagnosis
Reg. No. - G-31268

PLEASE CALL ON: 0522- 4233465, 7499161306, 7084352784 For more details about patient. (Only Doctors)

The science of radiology is based upon interpretation of shadows of normal and abnormal tissue. This is neither complete nor accurate; hence, findings should always be interpreted in to the light of clinico-pathological correlation. This is a professional opinion, not a diagnosis. Not meant for medico legal purposes.

Facilities

ICU, Facility for Medical & Cardiac Emergency, ECG, Nebulizer, Centralized Oxygen, Monitor
BIPAP, Defibrillator, Echo Cardiography, TMT, X-ray, PFT, Computerised Pathology

यहाँ पूर्ण-सिख परीक्षण नहीं किया जाता है। यह एक दृष्टिकोण अपराम है।

This Report is Only A Professional Opinion & Should Be Clinically Co-related

NOT VALID FOR MEDICO-LEGAL PURPOSE

सभी प्रकार के हेल्थ चेकअप पैकेज उपलब्ध



Bharti Hospital

AN ISO 9001-2008 (QMS) Certified Hospital

REG...NO : 2021-802703

DATE ~~Date~~ 27/08/2021.....

NAME : MR. ANAND KUMAR

REF...BY: B O B

AGE /SEX: 38 Y/M

2D REAL TIME GENERAL SONOLOGICAL STUDY OF WHOLE ABDOMEN

LIVER: Is normal in size with mildly increased parenchymal echogenicity. Margins are regular. Intra hepatic bile ducts (IHD) are not dilated. No focal mass seen. Portal Vein & C.B.D. is normal in caliber.

GALL BLADDER: Multiple small echogenic foci with acoustic shadowing is seen in GB lumen. No pericholecystic collection is seen.

SPLEEN: is normal in size and shape. Echotexture appears normal.

PANCREAS: Shows normal size and echotexture. No focal mass / peripancreatic collection is seen.

RIGHT KIDNEY: Shows normal position, size, shape and contour. Cortical echotexture is normal. CMD is maintained. No calculus /hydronephrosis is seen.

LEFT KIDNEY: Shows normal position, size, shape and contour. Cortical echotexture is normal. CMD is maintained. No hydronephrosis, No free fluid/ retroperitoneal adenopathy is seen.

U.BLADDER: is normal in distension and in wall thickness. Lumen is clear. No calculus or mass lesion is seen.

PROSTATE: is normal in size (35.2x29.6x28.9mm), shape and echotexture. Weight 15.8 cm³.

NOTE- Excessive Gas is Present in Abdomen.

IMPRESSION: Fatty Liver with Cholelithiasis.

ADVICE: Clinical Correlation.


SONOLOGIST

Best efforts were made during investigation, however in case of any Confusion/ Confirmation review can be done, free of cost. Not valid for medico-legal purpose.

Facilities

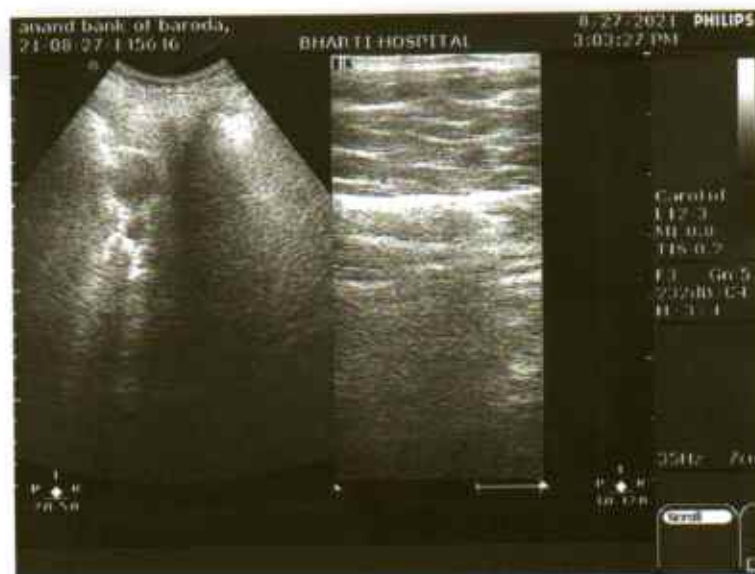
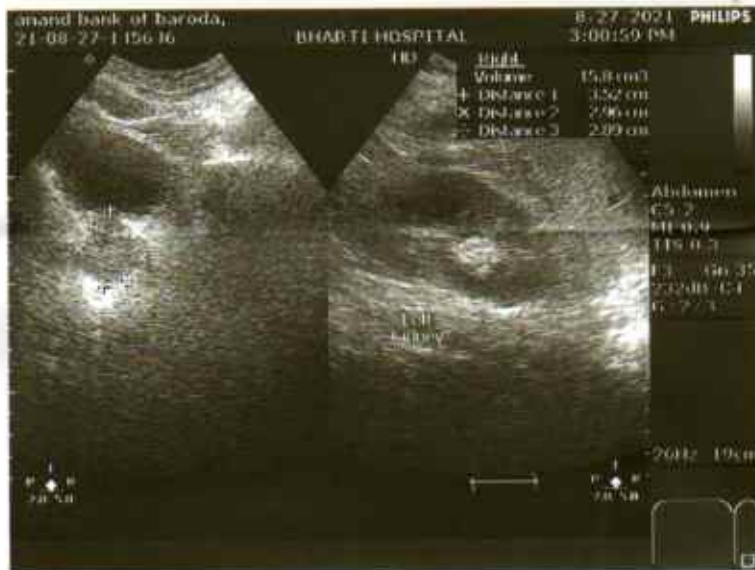
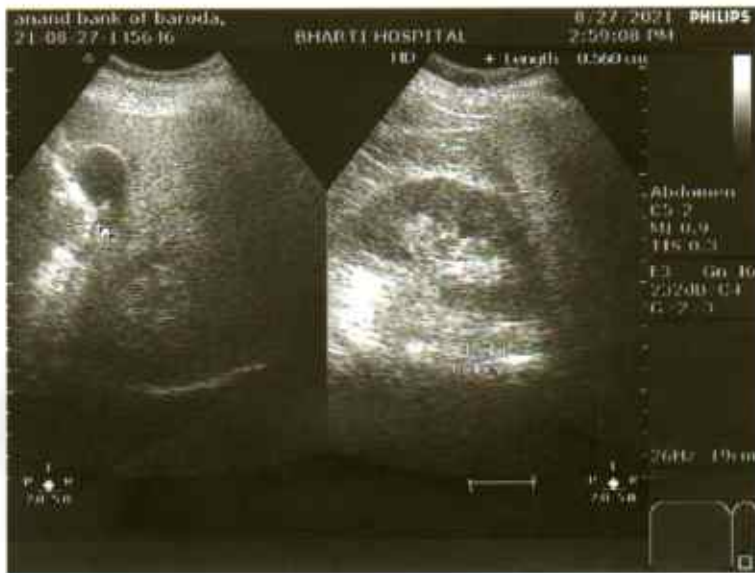
ICU, Facility for Medical & Cardiac Emergency, ECG, Nebulizer, Centralized Oxygen, Monitor BIPAP, Defibrillator, Echo Cardiography, TMT, X-ray, PFT, Computerised Pathology

यहाँ धूम-लिंग परीक्षण नहीं किया जाता है। यह एक दृष्टिकोण अपराध है।

This Report is Only A Professional Opinion & Should Be Clinically Co-related

NOT VALID FOR MEDICO-LEGAL PURPOSE

सभी प्रकार के हेल्थ चेकअप पैकेज उपलब्ध





Bharti Hospital

Ph. : 0565 - 2422090

SONKH ROAD, KRISHNA NAGAR, MATHURA

NAME : MR. ANAND

AGE : 38 Yrs.

SEX : M

REF. BY : BOB

DATE : 27/08/2021

LAB NO : 2005

Test Name	Value	Unit	Normal Value
<u>HAEMATOLOGY</u>			
<u>COMPLETE HAEMOGRAM</u>			
HAEMOGLOBIN (HB)	15.7	gm %	13.0 - 17.0
T L C (TOTAL LEUCOCYTE COUNT)	11,200	/cmm	4000 - 10000
DIFFERENTIAL LEUCOCYTE COUNT			
NEUTROPHILS	68	%	40 - 80
LYMPHOCYTES	26	%	20 - 40
MONOCYTES	02	%	02 - 10
EOSINOPHILS	04	%	01 - 06
BASOPHILS	00	%	01 - 02
E S R (WESTERGREN) (Vesmatic Easy Method)	03	mm 1st Hr	0 - 10
R B C (RED BLOOD CORP COUNT)	5.60	Millions/cmm	4.5 - 5.5
P C V / HCT (HAEMATOCRIT)	44.9	%	40 - 50
M C V (MEAN CORP VOLUME)	80.2	fL	76.0 - 96.0
M C H (MEAN CORP Hb)	28.0	pg	27.0 - 32.0
M C H C (MEAN CORP Hb CONC)	35.0	gm %	32.0 - 36.0
R D W	13.5	%	12.2 - 14.6
PLATELET COUNT	2,73,000	/cmm	150000 - 400000

*** End of Report ***

DR. PRADEEP PARASHAR
M.D. (PATH.)
Consultant Pathologist

NOT VALID FOR MEDICO LEGAL PURPOSE

All test have technical limitations collaborative clinico-athological interpretation is mandatory.
in case of disparity may be repeated immediately.

Consultation Time - Morning 9 A.M. to 9 P.M.



Bharti Hospital

Ph. : 0565 - 2422090

SONKH ROAD, KRISHNA NAGAR, MATHURA

NAME : MR. ANAND

AGE: 38 Yrs.

SEX : M

REF. BY : BOB

DATE: 27/08/2021

LAB NO: 2005

Test Name	Value	Unit	Normal Value
-----------	-------	------	--------------

BIOCHEMISTRY

BLOOD GLUCOSE (RANDOM)	97.3	mg %	70.0 - 160.0
------------------------	------	------	--------------

RENAL PROFILE

SERUM CREATININE	0.7	mg%	0.5 - 1.4
S. URIC ACID	4.7	mg%	2.0 - 7.2
BUN	14.5	mg%	6 - 21
BLOOD UREA	22.4	mg%	15.0 - 45.0
S.CALCIUM	8.5	mg%	8.5 - 11.0
S. SODIUM	140.8	mEq/L	135.0 - 155.0
S. POTASSIUM	4.2	mEq/L	3.5 - 5.5

LIVER PROFILE

SERUM BILIRUBIN (TOTAL)	0.7	mg%	0.2 - 1.0
CONJUGATED (Direct)	0.2	mg%	0.0 - 0.2
UNCONJUGATED (Indirect)	0.5	mg%	0.1 - 1.0
SGOT /AST	48.2	mg%	4.0 - 35.0
SGPT /ALT	41.9	mg%	4.0 - 40.0
Gamma GT	26.8	mg%	4.0 - 40.0
TOTAL PROTEIN	6.8	mg%	6.0 - 8.5
ALBUMIN	4.3	mg%	3.5 - 5.0
GLOBULIN	2.5	mg%	1.8 - 3.5
A/G RATIO	1.72	mg%	1.0 - 2.3
ALKALINE PHOSPHATE	87.6	mg%	37 - 126

****END OF REPORT****

DR. PRADEEP PARASHAR

M.D. (PATH)

Consultant Pathologist

NOT VALID FOR MEDICO LEGAL PURPOSE

All test have technical limitations collaborative clinico-athological interpretation is mandatory.
in case of disparity may be repeated immediately.
Consultation Time - Morning 9 A.M. to 9 P.M.



Bharti Hospital

Ph. : 0565 - 2422090

SONKH ROAD, KRISHNA NAGAR, MATHURA

NAME : MR. ANAND

AGE: 38 Yrs.

SEX : M

REF. BY : BOB

DATE: 27/08/2021

LAB NO: 2005

Test Name	Value	Unit	Normal Value
-----------	-------	------	--------------

HAEMATOLOGY

GLYCOSYLATED HAEMOGLOBIN (HbA1c)

HbA1c	5.3	%	
-------	-----	---	--

EXPECTED VALUES:

HEALTHY PATIENT = 4.8 – 6.0 % HbA1c

GOOD CONTROL = 6.0 – 7.0 % HbA1c

FAIR CONTROL = 7.0 – 8.0 % HbA1c

POOR CONTROL = > 8.0 % HbA1c

LIPID PROFILE

SERUM CHOLESTEROL	167.6	mg%	140.0 - 250.0
SERUM TRIGLYCERIDES	125.8	mg%	25.0 - 200.0
HDL CHOLESTEROL (DIRECT)	45.0	mg%	
LDL CHOLESTEROL (DIRECT)	104.2	mg%	50 – 190
VLDL CHOLESTEROL	31.3	mg%	5.0 – 40.0
TOTAL/HDL CHOLESTEROL RATIO	3.72		0.0 – 4.9
LDL/HDL CHOLESTEROL RATIO	2.31		0.0 – 3.5

IMMUNOLOGY – SEROLOGY

BLOOD GROUP

(Recheck after 6months in NB)

A B O	-	"B"
R h (Anti - D)	-	POSITIVE

****END OF REPORT****


DR. PRADEEP PARASHAR
M.D. (PATH)
Consultant Pathologist

NOT VALID FOR MEDICO LEGAL PURPOSE

All test have technical limitations collaborative clinico-athological interpretation is mandatory.
in case of disparity may be repeated immediately.
Consultation Time - Morning 9 A.M. to 9 P.M.



Bharti Hospital

Ph. : 0565 - 2422090

SONKH ROAD, KRISHNA NAGAR, MATHURA

NAME : MR. ANAND

AGE: 38 Yrs.

SEX : M

REF. BY : BOB

DATE: 27/08/2021

LAB NO: 2005

Test Name

Value

Unit

Normal Value


ENDOCRINOLOGY

THYROID PROFILE

T3+T4+TSH

THYROID THYRONINE (T3)	104.56	ng/dl	60.0 – 181.0
THYROXINE (T4)	4.43	ng/dl	3.20 – 12.6
THYROID STIMULATING HORMONE (TSH)	3.83	ng/dl	0.25 – 5.5

****END OF REPORT****


DR. PRADEEP PARASHAR
M.D. (PATH)
Consultant Pathologist

NOT VALID FOR MEDICO LEGAL PURPOSE

All test have technical limitations collaborative clinico-athological interpretation is mandatory.
in case of disparity may be repeated immediately.
Consultation Time - Morning 9 A.M. to 9 P.M.



Bharti Hospital

Ph. : 0565 - 2422090

SONKH ROAD, KRISHNA NAGAR, MATHURA

NAME : MR. ANAND

AGE: 38 Yrs.

SEX : M

REF. BY : BOB

DATE: 27/08/2021

LAB NO: 2005

Test Name	Value	Unit	Normal Value
-----------	-------	------	--------------

URINE EXAMINATION REPORT

MACROSCOPIC

COLOUR	YELLOW		
TRANSPARENCY	CLEAR		
SPECIFIC GRAVITY	1.021		1.003 -1.030
PH	ACIDIC		

BIOCHEMICAL

ALBUMIN	NIL
SUGAR	NIL

MICROSCOPIC (ON DEPOSIT)

PUS CELLS	1-2	/HPF
EPITHELIAL CELLS	1-2	/HPF
RBC'S	NIL	/HPF
CASTS	ABSENT	
CRYSTALS	ABSENT	
BACTERIA	ABSENT	

****END OF REPORT****

DR. PRADEEP PARASHAR
M.D. (PATH)
Consultant Pathologist

NOT VALID FOR MEDICO LEGAL PURPOSE

All test have technical limitations collaborative clinico-athological interpretation is mandatory.
in case of disparity may be repeated immediately.
Consultation Time - Morning 9 A.M. to 9 P.M.