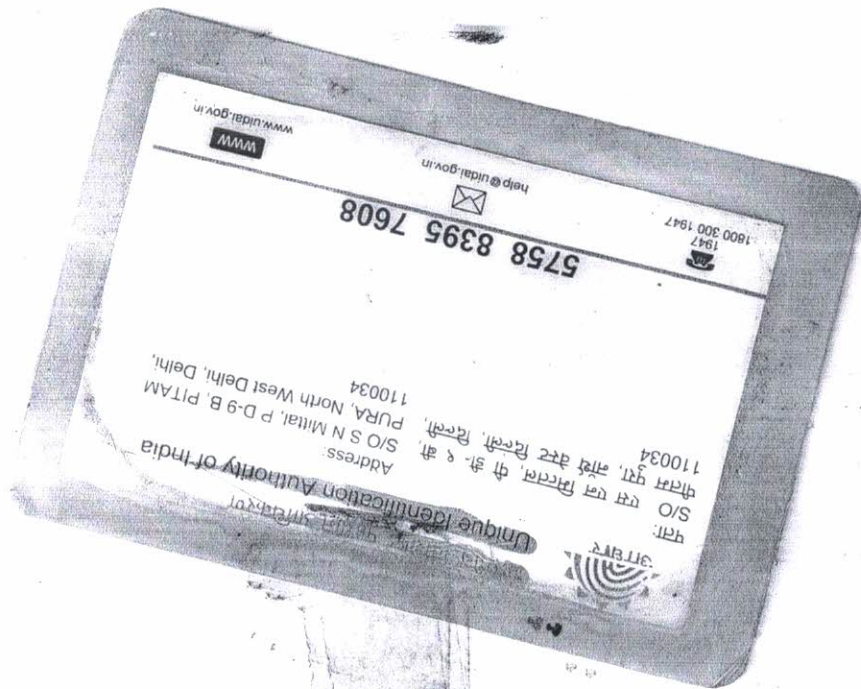

Mittal

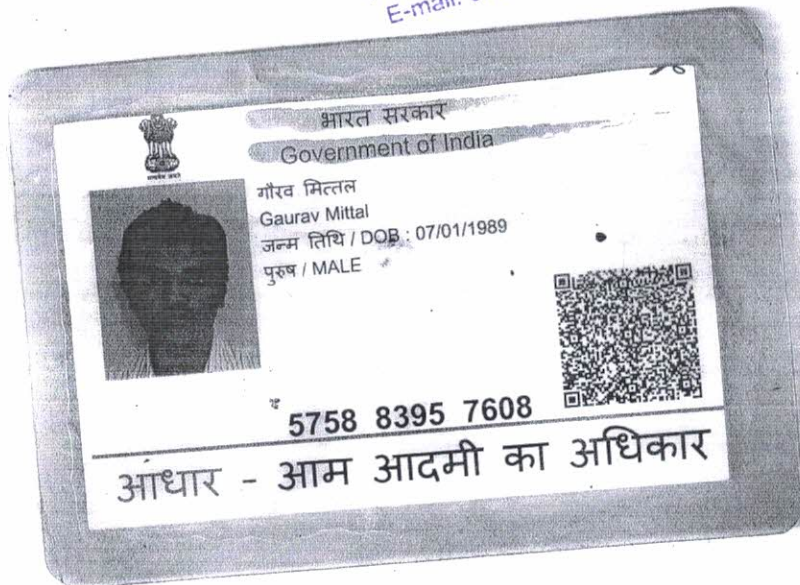
[Signature]
Dr. NITIN AGARWAL

MBBS, MD

Regn. No. DMC-R-1436

ONEPLUS ULTRASOUND LAB
47, Harsh Vihar, Pitam Pura,
Delhi-110034

Ph. 011-42480101, 9599913051
E-mail: onepusul@gmail.com





Oneplus

Dr. NITIN AGARWAL
MBBS, MD
Regn. No. DMC-R-1436

ONEPLUS ULTRASOUND LAB
47, Harsh Vihar, Pitam Pura,
Delhi-110034
Ph. 011-42480101, 9599913051
E-mail: oneplusu!@gmail.com

ONEPLUS ULTRASOUND LAB

47, HARSH VIHAR, PITAMPURA, DELHI- 110034

Mr. GAURAV MITTAL
Age : 32M
Ref. by : MEDIWHEEL
Indication 1 :
Indication 2 :
Indication 3 :
COMMENTS : Normal ECG.

ID : 1807
HWT : 175/75
Recorded : 1-11-2021 9:46
Medication 1 :
Medication 2 :
Medication 3 :

BPM : 80
BP : 124/76
P Axis : 65 deg
QRS Axis : 51 deg
T Axis : 23 deg

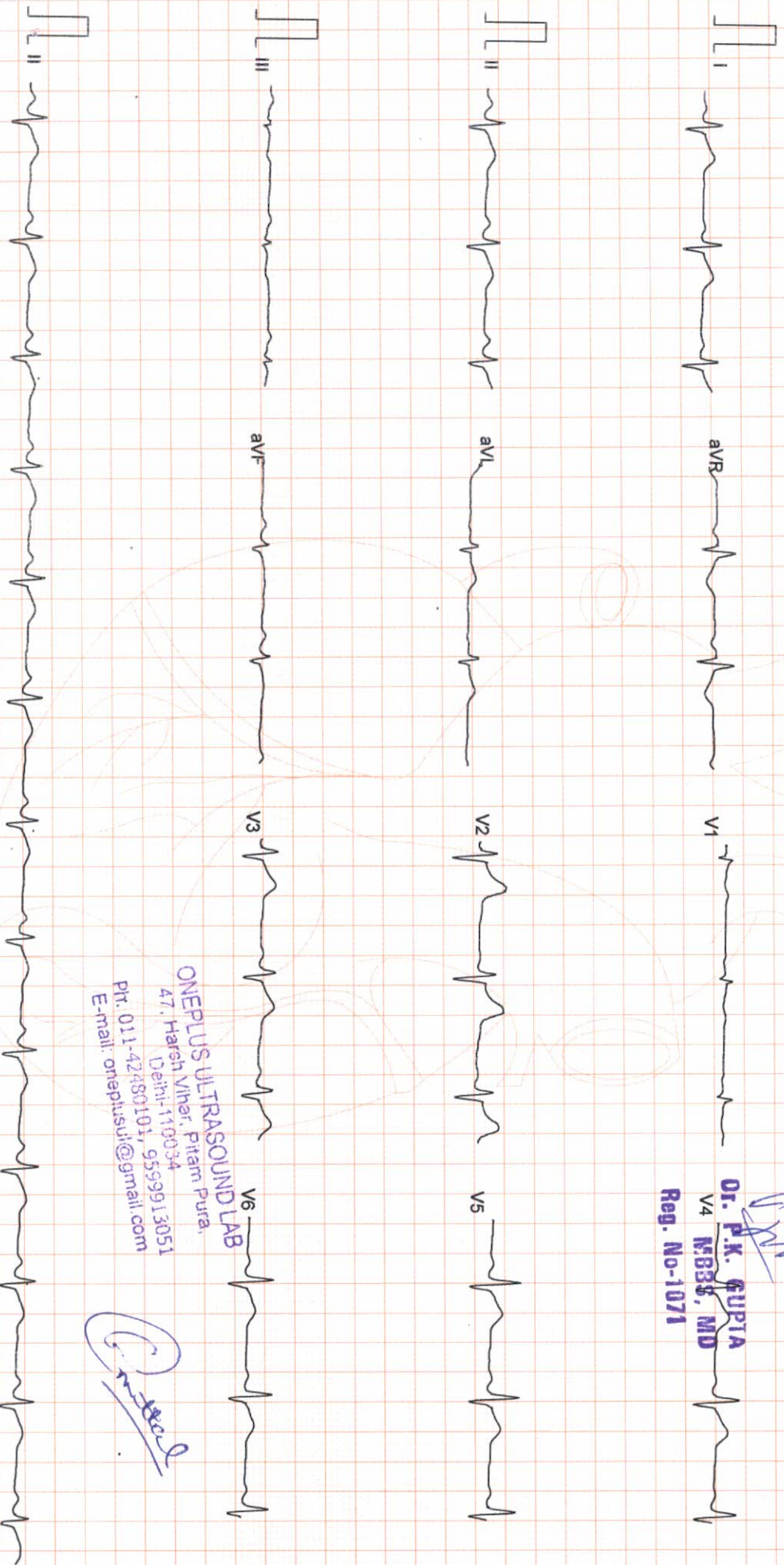
P duration : 133 msec
PR duration : 146 msec
QRS duration : 93 msec
QT interval : 316 msec
QTc interval : 351 msec

Raw E.C.G.(Seq)

Unconfirmed Report Reviewed By:

Cardiologist

[Signature]
Dr. P.K. GUPTA
V4
MBBS, MD
Reg. No-1071



ONEPLUS ULTRASOUND LAB
47, Harsh Vihar, Pitam Pura,
Delhi-110034
Ph: 011-42480101, 9599913051
E-mail: oneplusul@gmail.com

[Signature]

Filtered

25mm/sec 10mm/mV

AIUM

CardiCom, INDIA

ONEPLUS ULTRASOUND LAB

47, HARSH VIHAR PITAMPURA DELHI 110034

ID : 999
 HWWT : 175/75
 Recorded : 1-11-2021 9:51


TREADMILL TEST SUMMARY REPORT
 Protocol: BRUCE
 History:
 Medication1 :
 Medication2 :
 Medication3 :

Mr. GAURAV MITTAL
 Age/Sex : 32/M
 Ref. by : MEDIWHEEL
 Indication1 :
 Indication2 :
 Indication3 :

PHASE	PHASE TIME	STAGE TIME	SPEED (km./hr.)	GRADE (%)	H.R. (BPM)	B.P. (mmHg)	RPP X100	II	ST LEVEL (mm) V2	V5	METS
STANDING SUPINE					87	124/76	107	1.0	1.8	1.3	
STAGE 1	2:59	2:59	2.70	10.00	83	124/76	102	1.0	1.9	1.3	
STAGE 2	5:59	2:59	4.00	12.00	101	136/80	137	1.1	1.5	1.5	4.80
STAGE 3	8:59	2:59	5.40	14.00	121	146/82	176	1.1	1.7	1.6	7.10
STAGE 4	9:29	0:29	6.70	16.00	176	154/86	271	1.3	1.4	2.1	10.00
PEAK EXER	9:42	0:42			141	170/90	239	1.3	0.9	1.6	10.65
RECOVERY	2:59	2:59	0.00	0.00	173	170/90	294	0.6	0.5	1.0	10.94
					125	126/80	157	2.2	2.7	2.7	

RESULTS
 Exercise Duration : 9:42 Minutes
 Max Heart Rate : 176 bpm 93 % of target heart rate 188 bpm
 Max Blood Pressure : 170/90 mmHg
 Max Work Load : 10.94 METS
 Reason of Termination :
IMPRESSIONS : Negative for ischaemic cd




Dr. N.B.B.S. UPPIA
 M.B.B.S, MD
 Reg. No-1071

ONEPLUS ULTRASOUND LAB
 47, Harsh Vihar Pitampura,
 Delhi-110034
 Ph. 011-42480101, 9599913051
 E-mail: oneplusul@gmail.com

ONEPLUS ULTRASOUND LAB

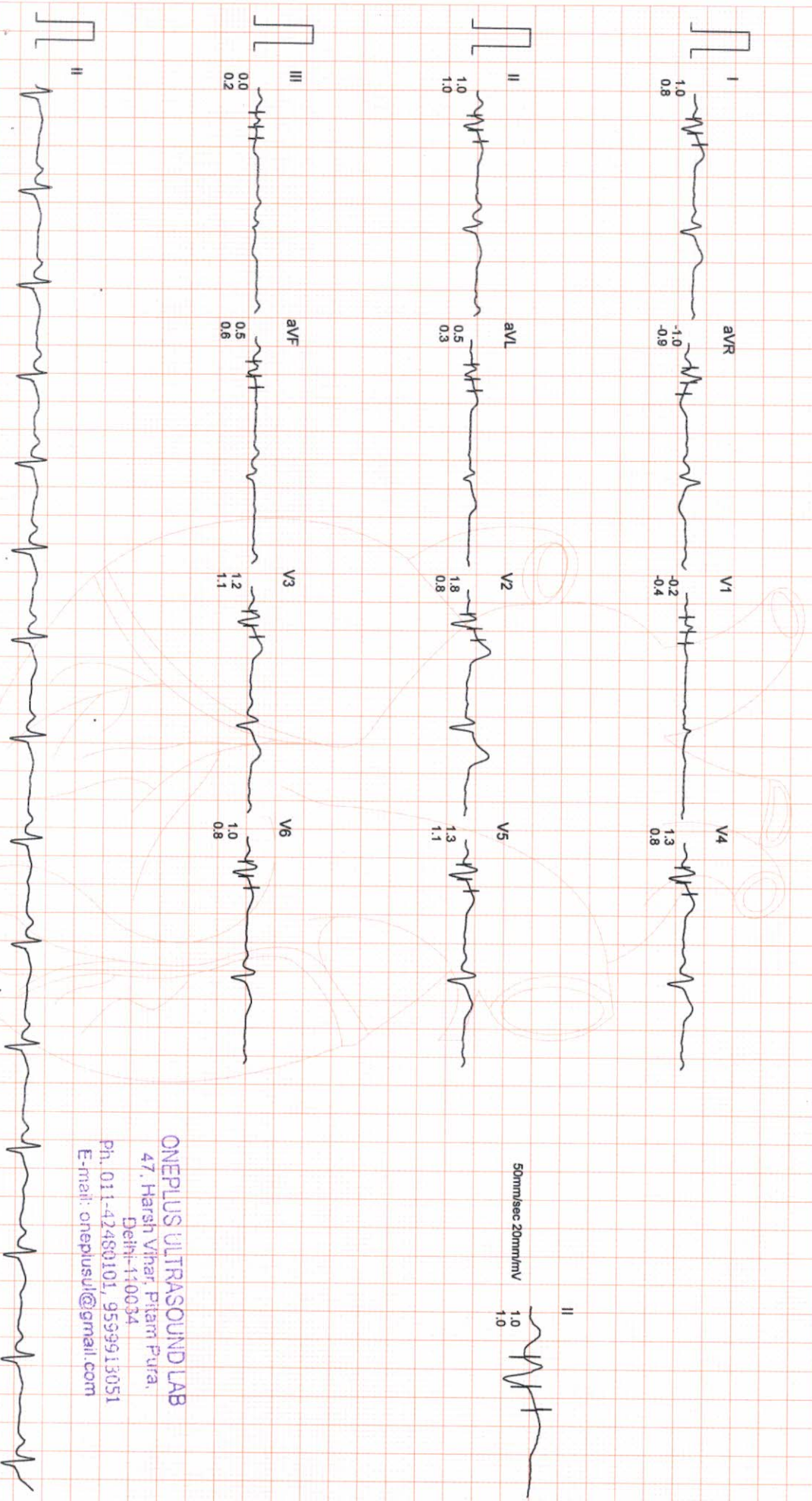
STANDING
PRETEST

ST @ 10mm/mV
80ms PostJ

Mr. GAURAV MITTAL
I.D. : 999
AGE/SEX : 32/M
RECORDED : 1-11-2021 9:51

RATE : 87 BPM
B.P. : 124/76 mmHg

LINKED MEDIAN



ONEPLUS ULTRASOUND LAB
47, Harsh Vihar, Pitam Pura,
Delhi-110034
Ph. 011-42480101, 9599913051
E-mail: oneplusul@gmail.com

ONEPLUS ULTRASOUND LAB

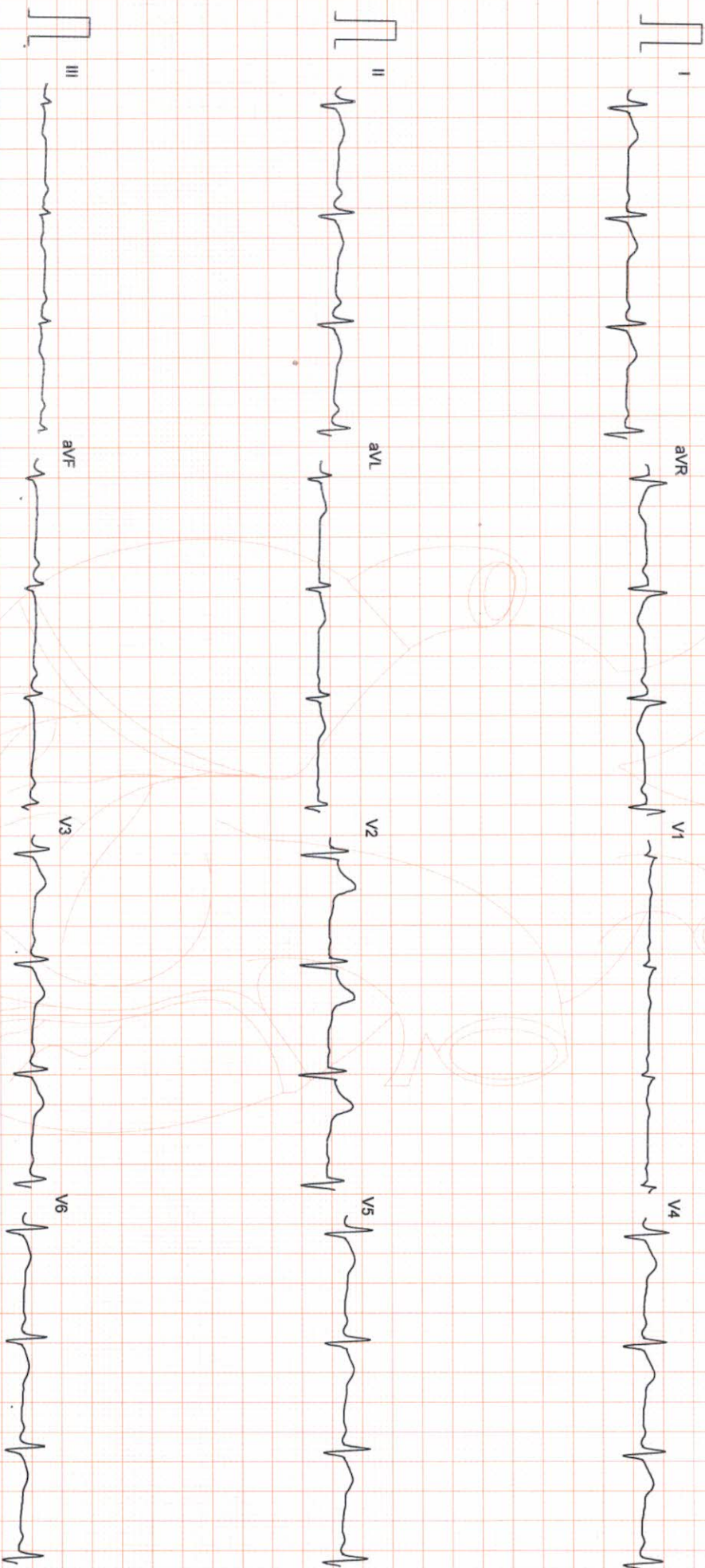
SUPINE
PRETEST

ST @ 10mm/mV
80ms PostJ

Mr. GAURAV MITTAL
I.D. : 999
AGE/SEX : 32/M
RECORDED : 1-11-2021 9:51

RATE : 83 BPM
B.P. : 124/76 mmHg

RAW E.C.G.



Filtered

25mm/sec 10mm/mV

Arrow

CardiCom, INDIA Ph.:091-731-2620740 Tele/Fax:091-731-2431214

ONEPLUS ULTRASOUND LAB

47, Harsh Vihar, Pitam Pura,

Delhi-110034

Ph. 011-261001, 9599913051

E-mail: oneplusul@gmail.com

ONEPLUS ULTRASOUND LAB

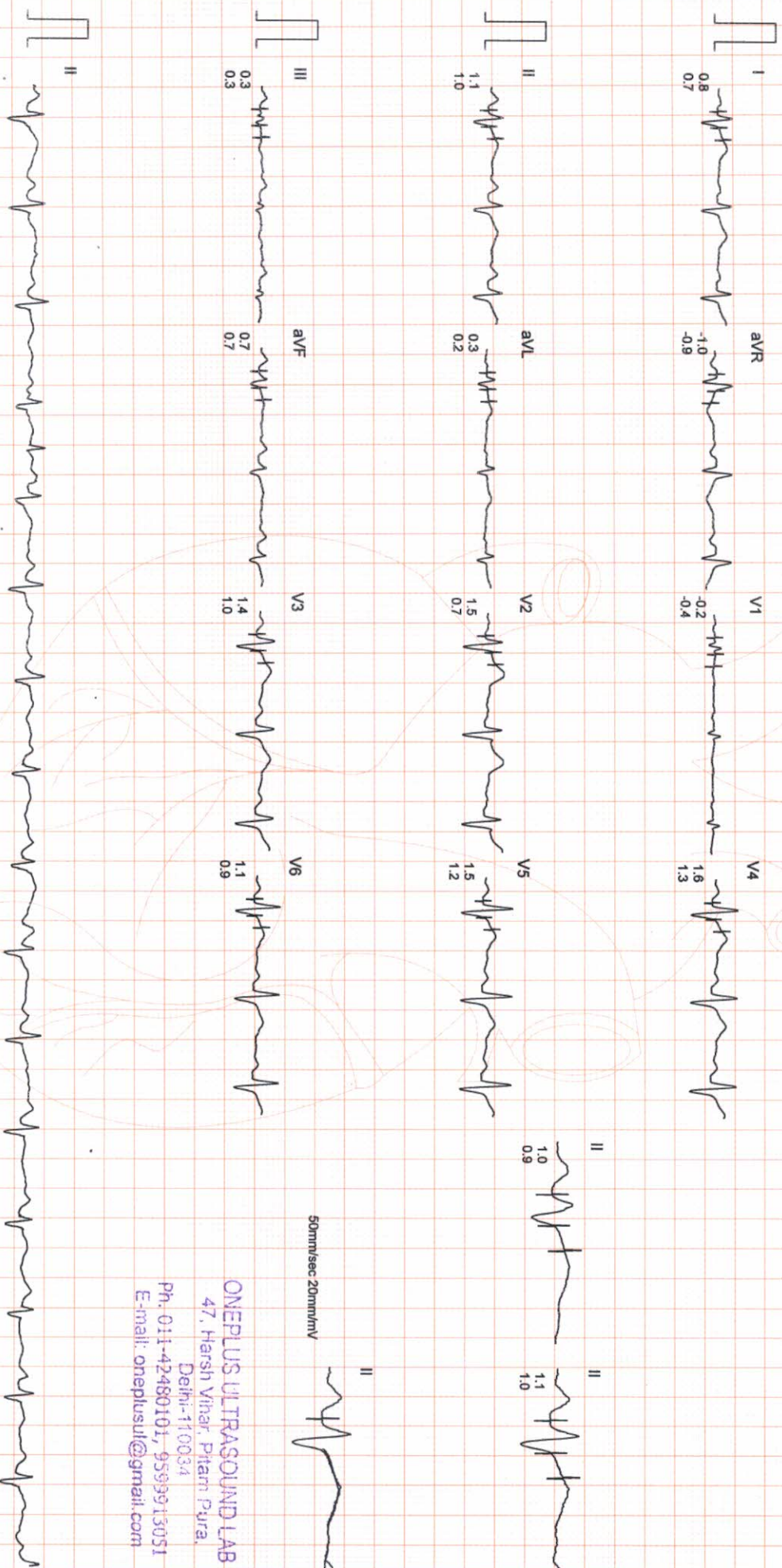
Mr. GAURAV MITTAL
I.D. : 999
AGE/SEX : 32/M
RECORDED : 1-11-2021 9:51

RATE : 101 BPM
B.P. : 136/80 mmHg

BRUCE
EXERCISE 1
PHASE TIME : 2:59
STAGE TIME : 2:59

ST @ 10mm/mV
80ms PostJ
SPEED : 2.7 Km./Hr.
GRADE : 10.0 %

LINKED MEDIAN



Filtered

Computer Corrected Baseline

25mm/sec 10mm/mV

CardiCom, INDIA Ph.:091-731-2620740, TeleFax:091-731-2431214

ONEPLUS ULTRASOUND LAB
47, Harsh Vihar, Pitam Pura,
Delhi-110034
Ph. 011-42480101, 9593913051
E-mail: onepplusul@gmail.com

ONEPLUS ULTRASOUND LAB

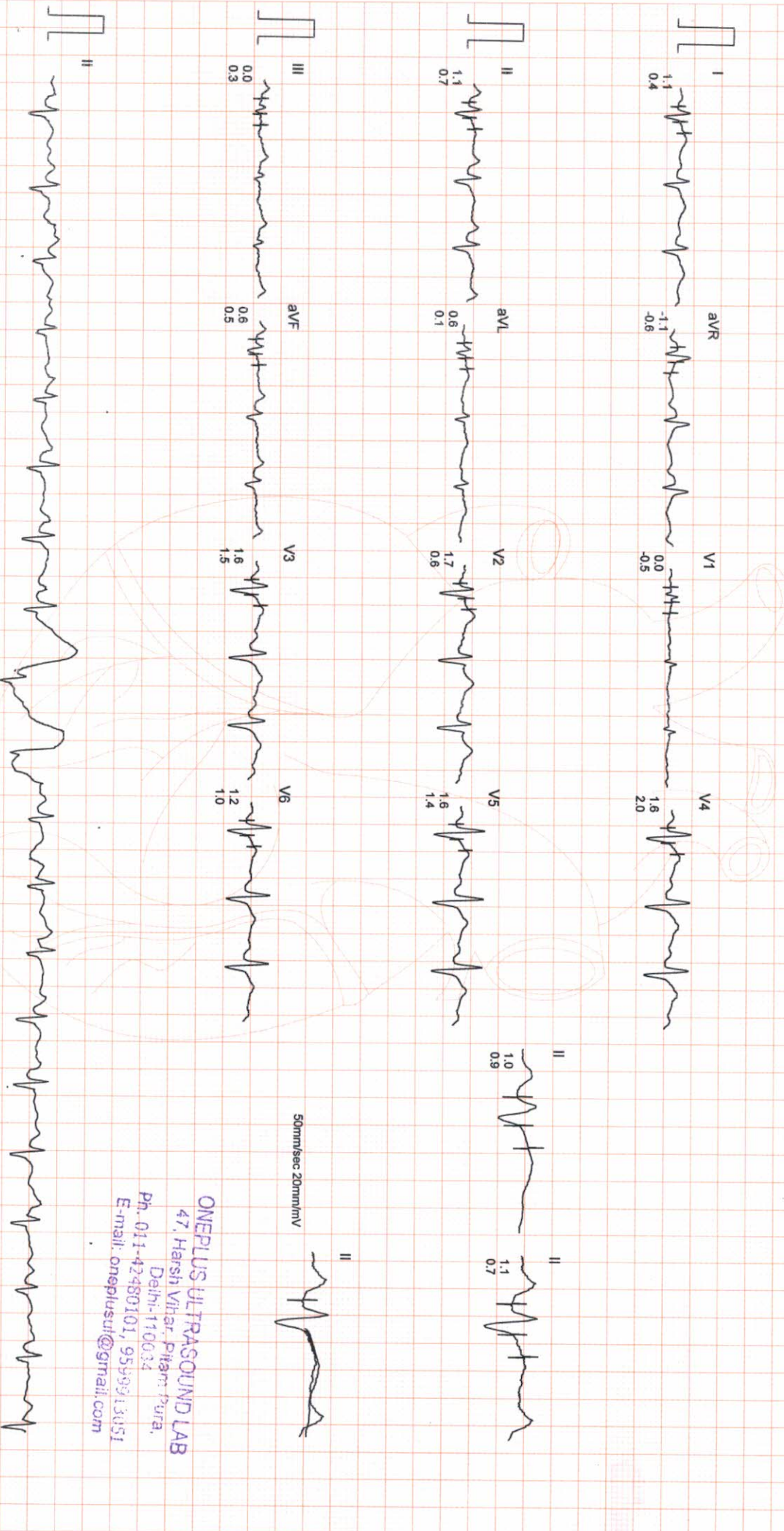
Mr. GAURAV MITTAL
I.D. : 999
AGE/SEX : 32/M
RECORDED : 1-11-2021 9:51

RATE : 121 BPM
B.P. : 146/82 mmHg

BRUCE
EXERCISE 2
PHASE TIME : 5:59
STAGE TIME : 2:59

ST @ 10mm/mV
80ms PostJ
SPEED : 4.0 Km./Hr.
GRADE : 12.0 %

LINKED MEDIAN



50mm/sec 20mm/mV

ONEPLUS ULTRASOUND LAB
47, Harsh Vihar, Pitam Pura,
Delhi-110034
Ph. 011-42480101, 9599913051
E-mail: onepiusul@gmail.com

Filtered

Computer Corrected Baseline

25mm/sec 10mm/mV

AKO

CardiCom, INDIA Ph.:091-731-2620740, TeleFax:091-731-2431214

ONEPLUS ULTRASOUND LAB

Mr. GAURAV MITTAL

ID. : 999

AGE/SEX : 32/M

RECORDED : 1-11-2021 9:51

RATE : 176 BPM

B.P. : 154/86 mmHg

BRUCE

EXERCISE 3

PHASE TIME : 8:59

STAGE TIME : 2:59

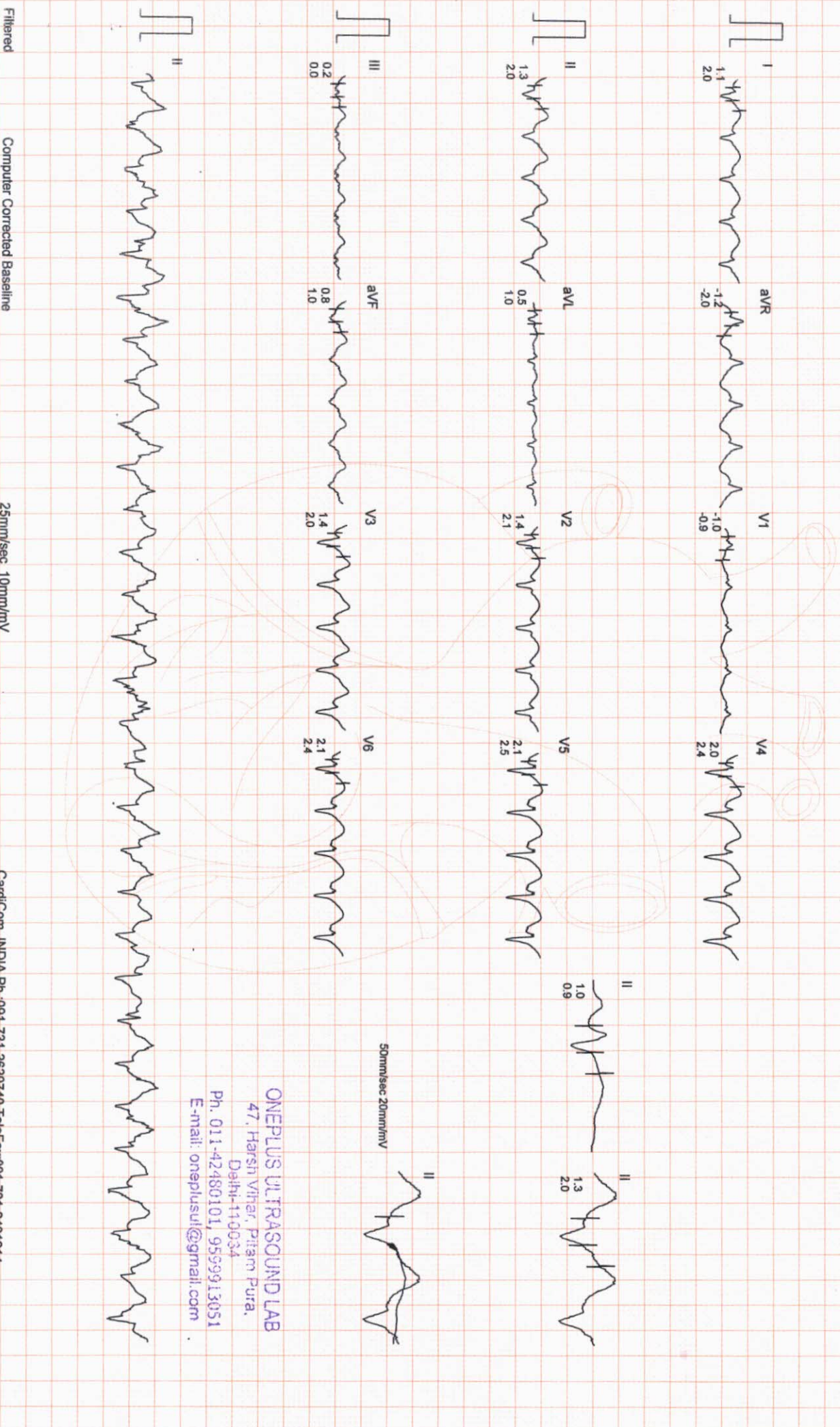
ST @ 10mm/mV

80ms PostJ

SPEED : 5.4 Km./Hr.

GRADE : 14.0 %

LINKED MEDIAN



50mm/sec 20mm/mV

ONEPLUS ULTRASOUND LAB
47, Harsh Vihar, Pitam Pura,
Delhi-110034
Ph. 011-42480101, 9599913051
E-mail: oneplusul@gmail.com

Filtered

Computer Corrected Baseline

25mm/sec 10mm/mV

ACQUW

CardiCom, INDIA Ph.:091-731-2620740, TeleFax:091-731-2431214

ONEPLUS ULTRASOUND LAB

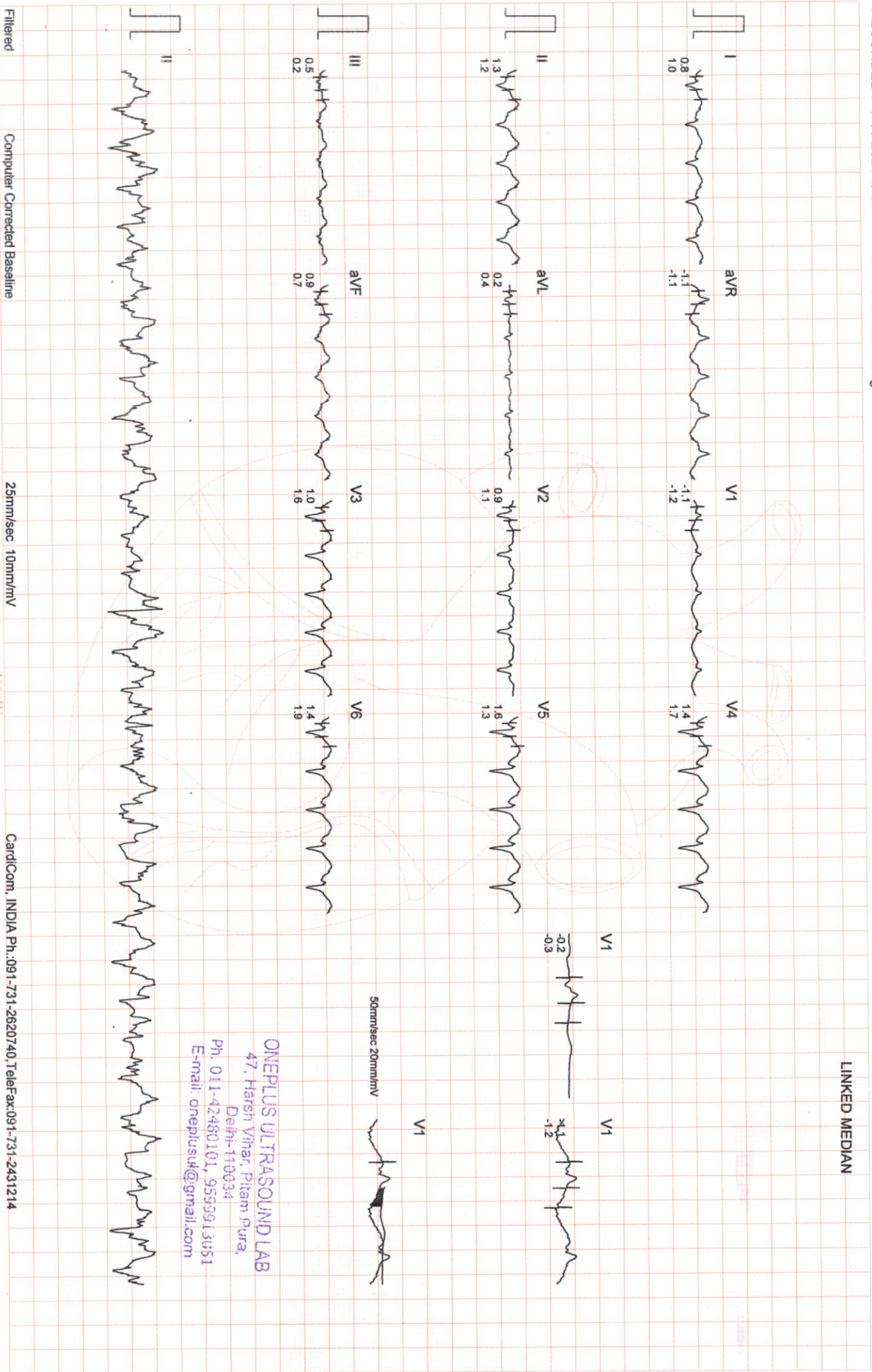Mr. GAURAV MITTAL
I.D. : 999
AGE/SEX : 32/M
RECORDED : 1-11-2021 9:51

RATE : 141 BPM
B.P. : 170/90 mmHg

BRUCE
EXERCISE 4
PHASE TIME : 9:29
STAGE TIME : 0:29

ST @ 10mm/mV
80ms PostJ
SPEED : 6.7 Km/Hr.
GRADE : 16.0 %

LINKED MEDIAN



ONEPLUS ULTRASOUND LAB
47, Harsh Vihar, Pitam Pura,
Delhi-110034
Ph, 011-42480101, 9599913051
E-mail: onepplusuf@gmail.com

ONEPLUS ULTRASOUND LAB

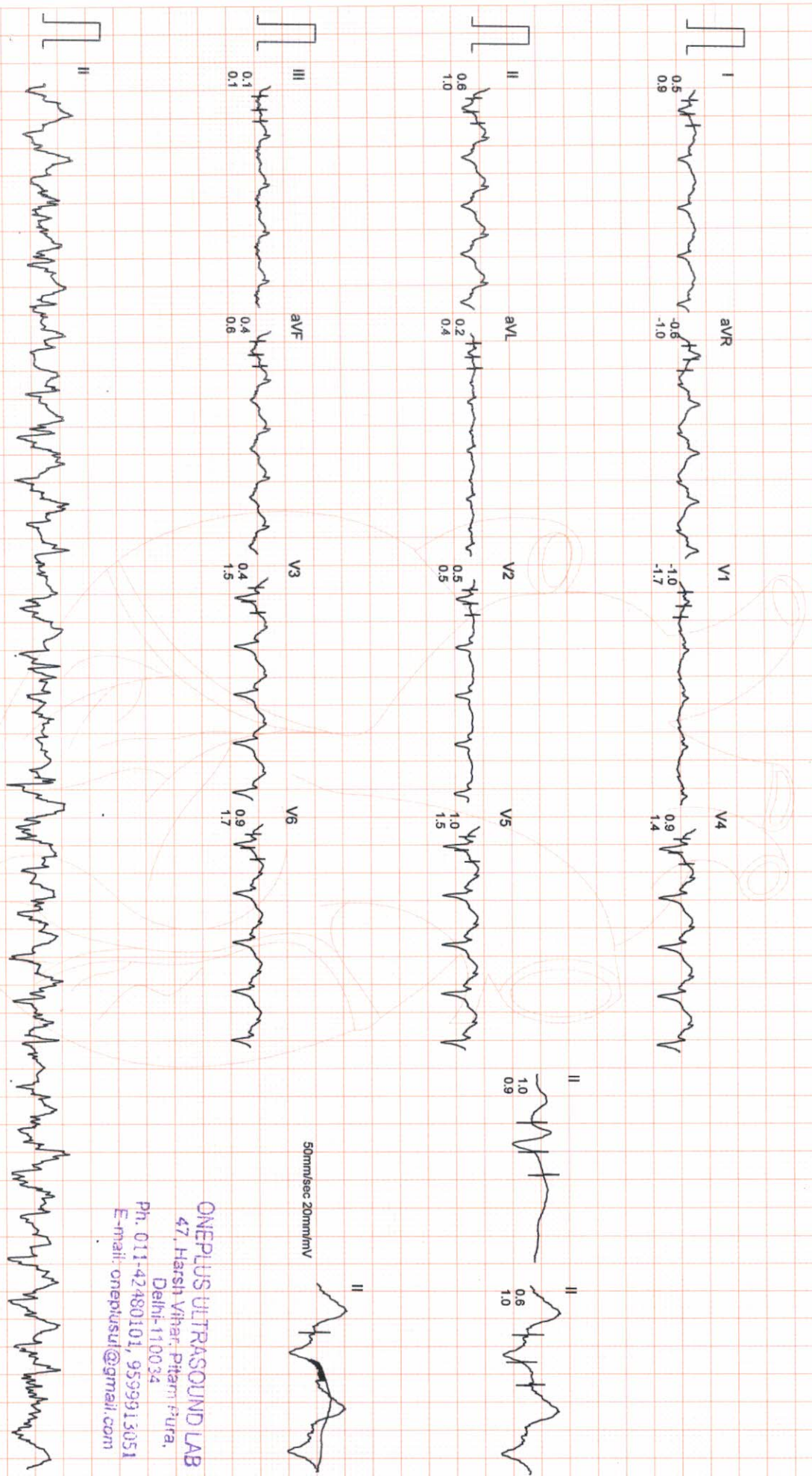
Mr. GAURAV MITTAL
I.D. : 999
AGE/SEX : 32/M
RECORDED : 1-11-2021 9:51

RATE : 173 BPM
B.P. : 170/90 mmHg

BRUCE
PEAK EXER
PHASE TIME : 9:42
STAGE TIME : 0:42

ST @ 10mm/mV
80ms PostJ
SPEED : 6.7 Km./Hr.
GRADE : 16.0 %

LINKED MEDIAN



ONEPLUS ULTRASOUND LAB
47, Harsh Vihar, Pitambara, Faridkot,
Delhi-110034
Ph. 011-42480101, 9599913051
E-mail: onepplusul@gmail.com

ONEPLUS ULTRASOUND LAB

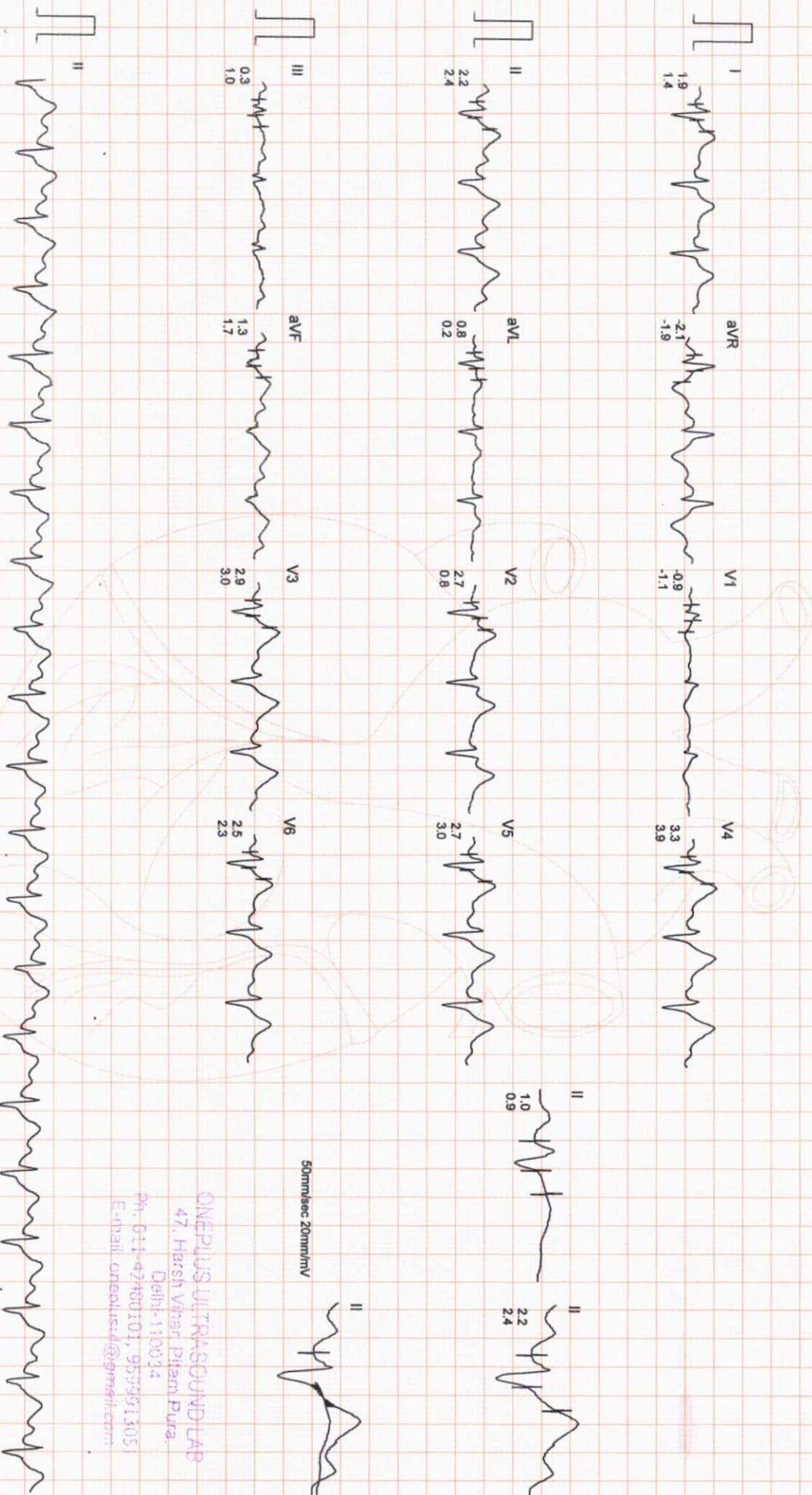
Mr. GAURAV MITTAL
 I.D. : 999
 AGE/SEX : 32/M
 RECORDED : 1-11-2021 9:51

RATE : 125 BPM
 B.P. : 126/80 mmHg

BRUCE
 RECOVERY
 PHASE TIME : 2:59

ST @ 10mm/mV
 80ms PostJ
 SPEED : 0.0 Km./Hr.
 GRADE : 0.0 %

LINKED MEDIAN



50mmsec 20mm/mV

ONEPLUS ULTRASOUND LAB
 47, Harsh Vihar Piliam Pura,
 Delhi-110034
 Ph. 011-47460101, 9539913051
 E-mail: oneplusul@ymail.com

Filtered

Computer Corrected Baseline



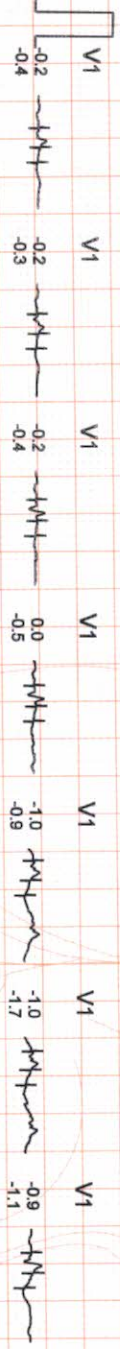
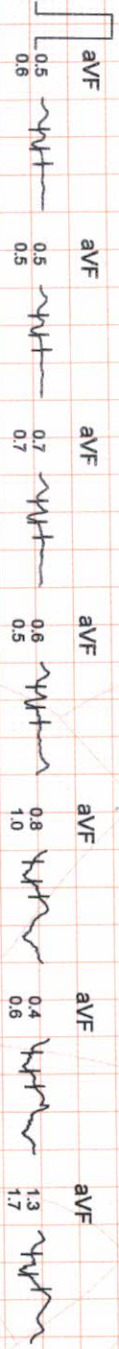
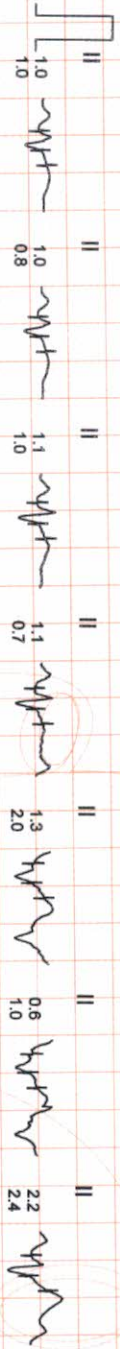

25mm/sec 10mm/mV

Arrow

CardiCom, INDIA Ph.:091-731-2620740, TeleFax:091-731-2431214

ONEPLUS ULTRASOUND LAB

STANDING	SUPINE	STAGE 1	STAGE 2	STAGE 3	PEAK EXERCISE	RECOVERY
0.0Kmph 0.0% 87 bpm B.P. 124/76 80ms PostU	0.0Kmph 0.0% 83 bpm B.P. 124/76 80ms PostU	2.59 2.59 2.7Kmph 10.0% 101 bpm B.P. 136/80 80ms PostU	5:59 2:59 4.0Kmph 12.0% 121 bpm B.P. 146/82 80ms PostU	8:59 2:59 5.4Kmph 14.0% 176 bpm B.P. 154/86 80ms PostU	9:42 0:42 6.7Kmph 16.0% 173 bpm B.P. 170/90 80ms PostU	2:39 0:0Kmph 0.0% 125 bpm B.P. 126/80 80ms PostU



ONEPLUS ULTRASOUND LAB
47, Hazratganj, Lucknow, India.

Ph. : 2480101, 9559915651
Dial: 110034
E-mail: oneplusul@gmail.com

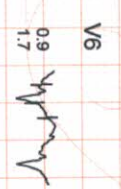


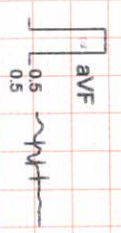



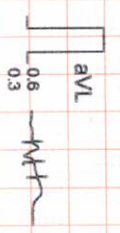
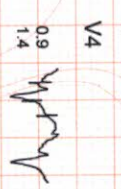





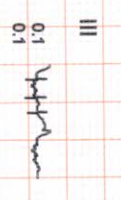
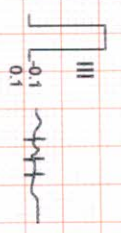








ONEPLUS ULTRASOUND LAB

SUPINE
0.0Kmph
0.0%
83 bpm
B.P. 124/76
80ms PostJ

PEAK EXERCISE
9:42
0:42
6.7Kmph
16.0%
173 bpm
B.P. 170/90
80ms PostJ

SUPINE
0.0Kmph
0.0%
83 bpm
B.P. 124/76
80ms PostJ

PEAK EXERCISE
9:42
0:42
6.7Kmph
16.0%
173 bpm
B.P. 170/90
80ms PostJ



ONEPLUS ULTRASOUND LAB
47, Harsh Vihar, Pitam Pura,
Delhi-110034
Ph. 011-42480101, 9399913051
E-mail: onepiusul@gmail.com



OnePLUS
Ultrasound Lab

— QUALITY FIRST... ALWAYS! —

Dr. Nitin Agarwal
Pathologist & Director
Ex. Sr. Res. MAMC
& Lok Nayak Hospital
Ex. Chief of Lab Dr. Lal Path Labs.

Dr. Pooja (Garg) Agarwal
Radiologist & Director
MAMC & Lok Nayak Hospital

Name	: Mr. GAURAV MITTAL	Age/Sex	: 32 YRS/Male
Ref. By	: Dr. MEDIWHEEL	Lab No	: 012111010005
Date	: 01-Nov-2021	Patient ID	: LSHHI86547

ULTRASOUND EXAMINATION----WHOLE ABDOMEN

Liver is normal in size and outline with normal echopattern. No abscess or mass lesion seen. Hepatic veins, portal vein, IVC and aorta are normal. Intrahepatic biliary radicles are not dilated. CBD is normal in caliber.

Gall bladder is well distended with anechoic lumen. Wall thickness is normal.

Both kidneys are normal in size, shape, position, outline and echopattern. Corticomedullary differentiation is maintained. No pelvicalyceal dilation or calculus or mass lesion is seen.

Spleen is normal in size and echotexture. No mass lesion seen.

Pancreas is normal in size, outline and echotexture.

Urinary bladder is normal in shape and position. No evidence of intravesical stone or mass seen.


Prostate is normal in size, shape and echopattern.

Prostate measures 2.7 x 2.6 x 2.4 cm. **Weight of prostate is 9.4 grams.**

No abnormal bowel wall thickening seen in right iliac fossa.

No mass or free fluid seen anywhere in abdomen.

IMPRESSION: Normal Study.


DR. POOJA GARG
RADIOLOGIST
REG NO- DMC/R/03398

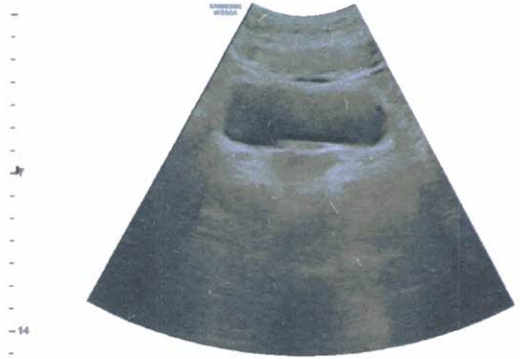Dr. POOJA GARG
M.B.B.S., D.M.R.D
Reg No. DMC/R/03398
F

Type By : darshita

47, Harsh Vihar, Pitampura, New Delhi-110034 | Ph.: 011-42480101, 9599913051
E-mail: oneplusul@gmail.com | Web.: www.oneplusul.in

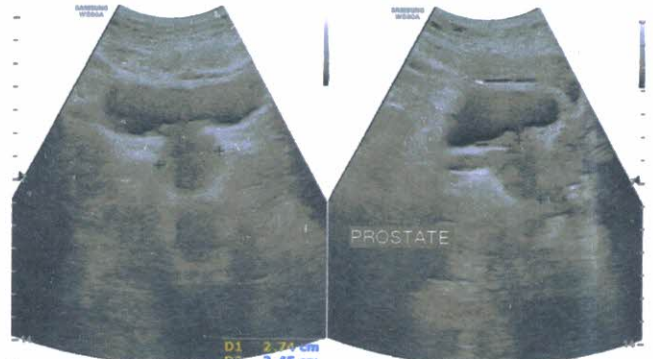W590A 01-11-2021-0002 MR GAURAV 32/M OnePlus Ultrasound Lab MI 1.5 01-11-2021 CA1-7A / Abdomen / FR 25Hz Tib0.1 11:24:08 AM

20 G58-DR130-FA11-P100-Frq Pen.:15.0cm



W590A 01-11-2021-0002 MR GAURAV 32/M OnePlus Ultrasound Lab MI 1.5 01-11-2021 CA1-7A / Abdomen / FR 25Hz Tib0.1 11:24:29 AM

20 G58-DR130-FA11-P100-Frq Pen.:15.0cm

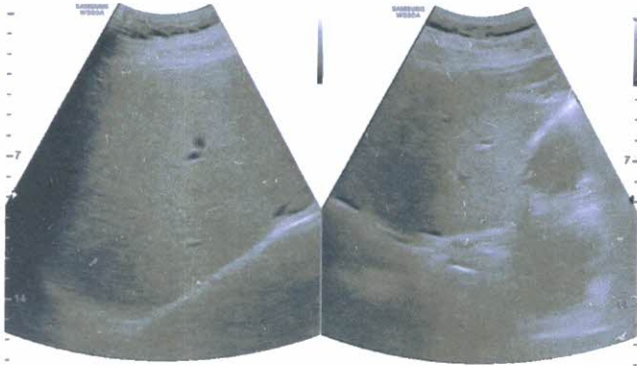


D1 2.74 cm
D2 2.45 cm
D3 2.68 cm
Vol. 9.42 ml

D1 2.74 cm
D2 2.45 cm

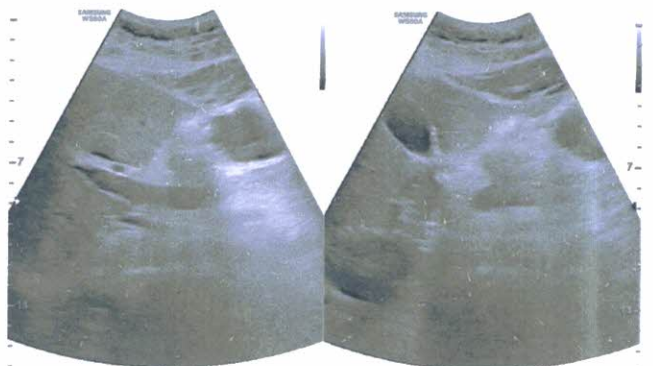
W590A 01-11-2021-0002 MR GAURAV 32/M OnePlus Ultrasound Lab MI 1.5 01-11-2021 CA1-7A / Abdomen / FR 23Hz Tib0.2 11:24:46 AM

20 G61-DR130-FA11-P100-Frq Pen.:17.0cm



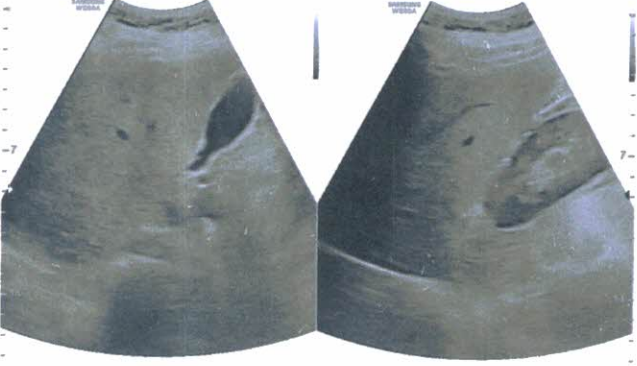
W590A 01-11-2021-0002 MR GAURAV 32/M OnePlus Ultrasound Lab MI 1.5 01-11-2021 CA1-7A / Abdomen / FR 23Hz Tib0.2 11:24:52 AM

20 G61-DR130-FA11-P100-Frq Pen.:17.0cm



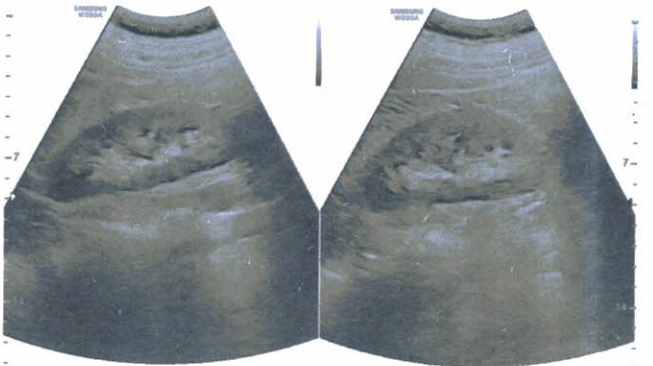W590A 01-11-2021-0002 MR GAURAV 32/M OnePlus Ultrasound Lab MI 1.5 01-11-2021 CA1-7A / Abdomen / FR 23Hz Tib0.2 11:25:05 AM

20 G55-DR130-FA11-P100-Frq Pen.:17.0cm



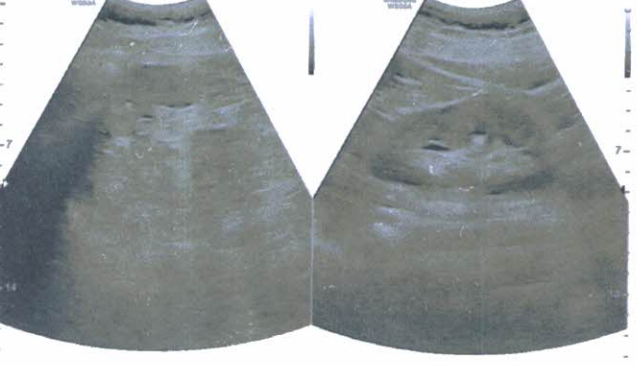
W590A 01-11-2021-0002 MR GAURAV 32/M OnePlus Ultrasound Lab MI 1.5 01-11-2021 CA1-7A / Abdomen / FR 23Hz Tib0.2 11:25:17 AM

20 G55-DR130-FA11-P100-Frq Pen.:17.0cm



W590A 01-11-2021-0002 MR GAURAV 32/M OnePlus Ultrasound Lab MI 1.5 01-11-2021 CA1-7A / Abdomen / FR 23Hz Tib0.2 11:25:31 AM

20 G55-DR130-FA11-P100-Frq Pen.:17.0cm



W590A 01-11-2021-0002 MR GAURAV 32/M OnePlus Ultrasound Lab MI 1.5 01-11-2021 CA1-7A / Abdomen / FR 23Hz Tib0.2 11:25:40 AM

20 G52-DR130-FA11-P100-Frq Pen.:17.0cm





OnePLUS
Ultrasound Lab
— QUALITY FIRST... ALWAYS! —

Dr. Nitin Agarwal

Pathologist & Director
Ex. Sr. Res. MAMC
& Lok Nayak Hospital
Ex. Chief of Lab Dr. Lal Path Labs.

Dr. Pooja (Garg) Agarwal

Radiologist & Director
MAMC & Lok Nayak Hospital

Name	: Mr. GAURAV MITTAL	Age/Sex	: 32 YRS/Male
Ref. By	: Dr. MEDIWHEEL	Lab No	: 012111010005
Date	: 01-Nov-2021	Patient ID	: LSHHI86547

X-ray-Chest PA view

Bony cage and soft tissues are normal.

Cardiothoracic ratio is normal.

Mediastinum is normal.

Both hila are normal.

Both costophrenic angles are clear.

Both domes of diaphragm are normal.

Lung fields are clear. No parenchymal lesion seen.

IMPRESSION: Normal Study.

DR. POOJA GARG
RADIOLOGIST

REG NO-DMC/R/03398

Dr. POOJA GARG
M.B.B.S., D.M.R.D
Reg No DMC/R/03398

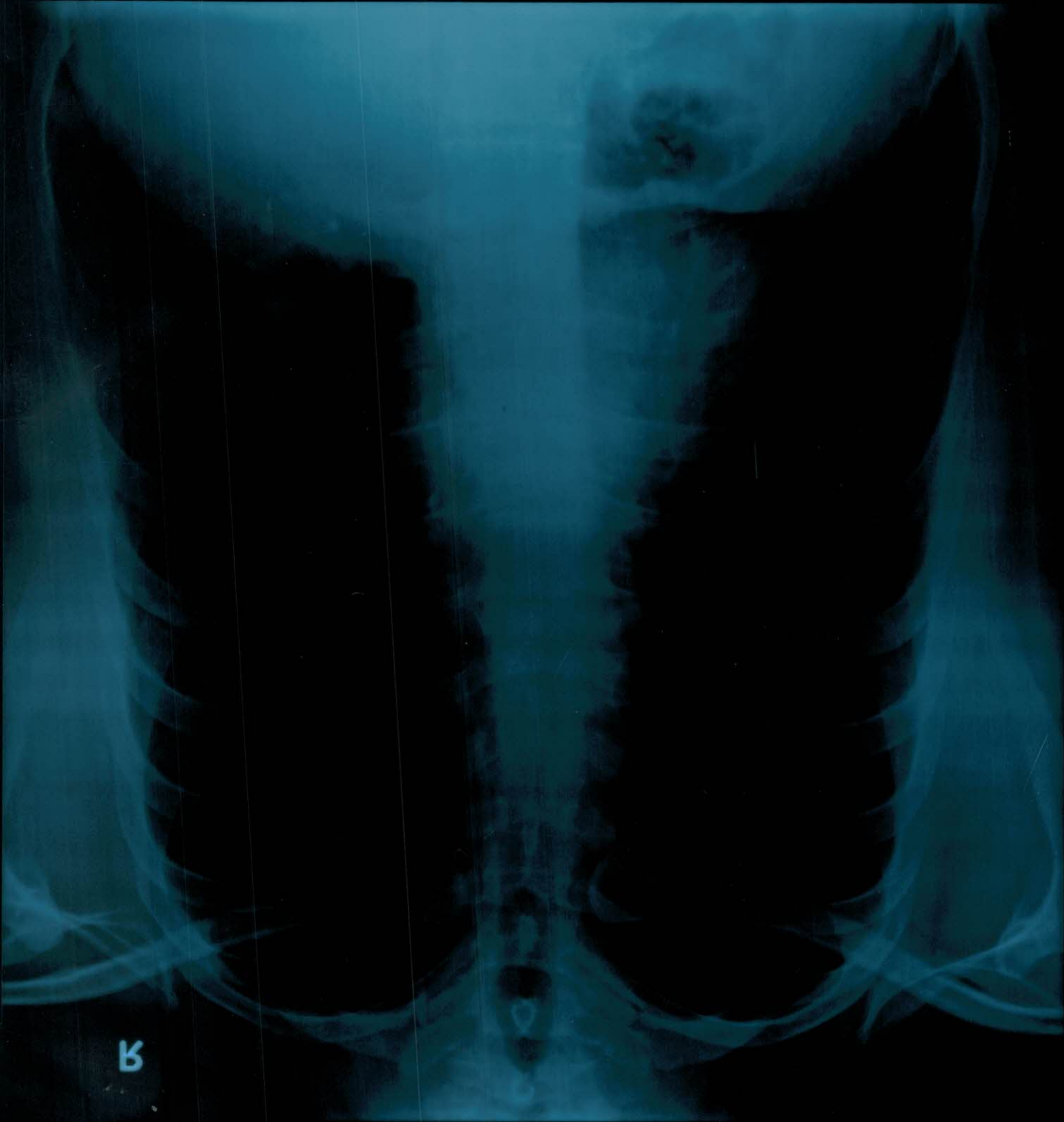
Type By : pooja

47, Harsh Vihar, Pitampura, New Delhi-110034 | Ph.: 011-42480101, 9599913051

E-mail: oneplusul@gmail.com | Web.: www.oneplusul.in

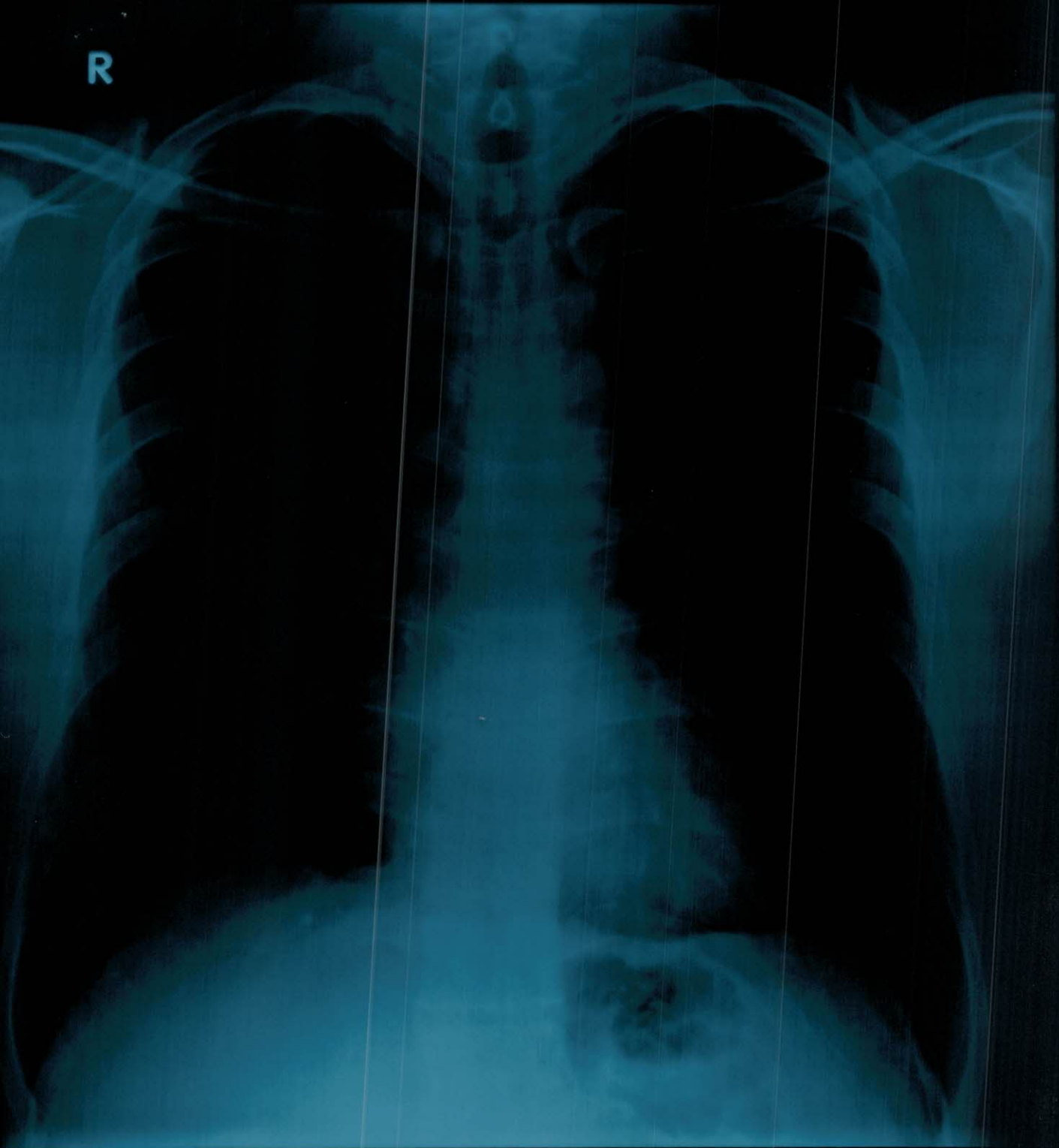Clinical correlation is essential for final diagnosis. • If test results are unsatisfactory please contact personally or on phone. • This report is for perusal of doctors only.
• All disputes Subject to Delhi Jurisdiction only. • Not for medicolegal purposes. • All congenital anomalies in a foetus may not be diagnosed in routine obstetric ultrasound.

АПТЭЖА М СХЕСТА М 1202-11-1 ЗЯС 32 АСЕ МТТАГ АСАВА МР
АПТЭЖА М СХЕСТА М 1202-11-1 ЗЯС 32 АСЕ МТТАГ АСАВА МР



Б

R



MR GAURAV MITTAL AGE 32 YRS 1-11-2021 M CHEST PA
ONEPLUS ULTRASOUND LAB,47-HARSH VIHAR,PITAMPURA



OnePLUS
Ultrasound Lab
— QUALITY FIRST... ALWAYS! —

Dr. Nitin Agarwal
Pathologist & Director
Ex. Sr. Res. MAMC
& Lok Nayak Hospital
Ex. Chief of Lab Dr. Lal Path Labs.

Dr. Pooja (Garg) Agarwal
Radiologist & Director
MAMC & Lok Nayak Hospital



NAME	:Mr. GAURAV MITTAL	Barcode No	:10107395
AGE/GENDER	:32 YRS/Male	SPECIMEN DATE	:01/Nov/2021 09:31AM
PATIENT ID	:86547	SPECIMEN RECEIVED	:01/Nov/2021 09:36AM
REFERRED BY	:Dr. MEDIWHEEL	REPORT DATE	:01/Nov/2021 04:41PM
CENTRE NAME	:ONEPLUS ULTRASOUND LAB	LAB NO.	:012111010005

Test Name	Result	Unit	Ref. Range
-----------	--------	------	------------

HAEMATOLOGY

Health checkup 2 Male

Glycosylated Hemoglobin (HbA1c)	5.2	%	<6.0%
Estimated average blood glucose (eag)	103		

Reference range (mg/dl):

90 - 120:Excellent control, 121 - 150:Good Control, 151 - 180:Average Control, 181 - 210:Action Suggested

>211:Panic value

REMARKS:-

In vitro quantitative determination of **HbA1C** in whole blood is utilized in long term monitoring of glycemia. The **HbA1C** level correlates with the mean glucose concentration prevailing in the course of the patient's recent history (approx - 6-8 weeks) and therefore provides much more reliable information for glycemia monitoring than do determinations of blood glucose or urinary glucose. It is recommended that the determination of **HbA1C** be performed at intervals of 4-6 weeks during Diabetes Mellitus therapy. On testing of HbA1C by HPLC method the result shows high variant window (93.8%) & no value of HbA1C. Therefore for accurate assay of glycaemic Control Fructosamine assay & for variant analysis Hb electrophoresis should be done.

Assay done by : Bio-Rad : D-10 (HPLC)

Checked By.

DR. NITIN AGARWAL
(MBBS, MD(PATHOLOGIST))

Dr. NITIN AGARWAL
M.B.B.S., MD (Path)

47, Harsh Vihar, Pitampura, New Delhi-110034 | Ph.: 011-42480101, 9599913051
E-mail: oneplusul@gmail.com | Web.: www.oneplusul.in

Page 1 of 6



OnePLUS Ultrasound Lab

— QUALITY FIRST... ALWAYS! —

Dr. Nitin Agarwal
Pathologist & Director
Ex. Sr. Res. MAMC
& Lok Nayak Hospital
Ex. Chief of Lab Dr. Lal Path Labs.

Dr. Pooja (Garg) Agarwal
Radiologist & Director
MAMC & Lok Nayak Hospital



NAME	:Mr. GAURAV MITTAL	Barcode No	:10107395
AGE/GENDER	:32 YRS/Male	SPECIMEN DATE	:01/Nov/2021 09:31AM
PATIENT ID	:86547	SPECIMEN RECEIVED	:01/Nov/2021 09:36AM
REFERRED BY	:Dr. MEDIWHEEL	REPORT DATE	:01/Nov/2021 11:09AM
CENTRE NAME	:ONEPLUS ULTRASOUND LAB	LAB NO.	:012111010005

Test Name	Result	Unit	Ref. Range
-----------	--------	------	------------

HAEMATOLOGY

BLOOD GROUP (ABO)

O

Rh typing

POSITIVE

NOTE :

- * Apart from major A,B,H antigens which are used for ABO grouping and Rh typing, many minor blood group antigens exist. Agglutination may also vary according to titre of antigen and antibody.
- * So before transfusion, reconfirmation of blood group as well as cross-matching is needed.
- * Presence of maternal antibodies in newborns, may interfere with blood grouping.
- * Auto agglutination (due to cold antibody, falciparum malaria, sepsis, internal malignancy etc.) may also cause erroneous result.

CBC

Haemoglobin	14.6	g/dl	13.0-17.0
Total Leucocyte Count	6100	/cumm	4000-10000
<u>Differential leucocyte count</u>			
Neutrophils	55	%	40-80
Lymphocyte	36.00	%	20-40
Monocytes	6.20	%	2-10
Eosinophils	2.5	%	1-6
Basophils	0.3	%	0-2
RBC Count	5.00	million/cumm	4.5 - 5.5
PCV(Hematocrit)	46.2	%	40-50
MCV	92.4	fL	83-101
MCH	29.3	Pg	27-32
MCHC	31.7	G/dL	32-35
Platelet count	251000	/cumm	150000-450000
RDW-CV	12.3	%	11.4-14.0
ESR(WESTEGRENs METHOD)	12	mm in 1st hr	0-20

Checked By.

DR. NITIN AGARWAL
MBBS, MD (PATHOLOGIST)

Dr NITIN AGARWAL
M B B S , MD (Path)
DMC/R/01436

47, Harsh Vihar, Pitampura, New Delhi-110034 | Ph.: 011-42480101, 9599913051

E-mail: oneplusul@gmail.com | Web.: www.oneplusul.in

Page 2 of 6



OnePLUS

Ultrasound Lab

— QUALITY FIRST... ALWAYS! —

Dr. Nitin Agarwal
Pathologist & Director
Ex. Sr. Res. MAMC
& Lok Nayak Hospital
Ex. Chief of Lab Dr. Lal Path Labs.

Dr. Pooja (Garg) Agarwal
Radiologist & Director
MAMC & Lok Nayak Hospital



NAME	:Mr. GAURAV MITTAL	Barcode No	:10107395
AGE/GENDER	:32 YRS/Male	SPECIMEN DATE	:01/Nov/2021 09:31AM
PATIENT ID	:86547	SPECIMEN RECEIVED	:01/Nov/2021 01:26PM
REFERRED BY	:Dr. MEDIWHEEL	REPORT DATE	:01/Nov/2021 04:41PM
CENTRE NAME	:ONEPLUS ULTRASOUND LAB	LAB NO.	:012111010005

Test Name	Result	Unit	Ref. Range
-----------	--------	------	------------

BIOCHEMISTRY

Blood sugar fasting	89	mg/dL	70-110
Blood sugar pp	106	mg/dL	70.0-140.0
Bun (blood urea nitrogen)	13.50	mg/dl	8.9-21.6
Uric acid, serum	4.9	mg/dl	3.4-7.0
Creatinine, serum	0.66	mg/dl	0.60-1.1

LFT(LIVER FUNCTION TEST)

Bilirubin Total	0.35	mg/dl	0.1-1.2
Bilirubin Conjugated	0.12	mg/dl	0-0.4
Bilirubin Unconjugated	0.23	mg/dl	up to 0.7
SGOT (AST)	26	U/L	0-35
SGPT (ALT)	38	U/L	<45.0
Alkaline phosphatase	79	U/L	40-129
Gamma glutamyl transpeptidase	27	U/L	<66
Total Protein	6.8	gm/dl	6.60 - 8.70
Albumin	3.9	g/dL	3.8-5.1
Globulin	2.90	gm/dl	1.8-3.4
Albumin/Globulin Ratio	1.34		1.10 - 2.50

LIPID PROFILE

Cholesterol	161	mg/dl	50-200
Triglycerides	64	mg/dL	25-150
HDL Cholesterol	47	mg/dL	30-70
LDL cholesterol	101	mg/dL	<130
VLDL cholesterol	12.8	mg/dL	5-40
Cholesterol/HDL Ratio	3.4		Low Risk 3.3-4.97 Average Risk 4.4-7.1 Moderate Risk 7.1-11.0 High Risk >11.0

Checked By.

DR. NITIN AGARWAL
MBBS,MD(PATHOLOGIST)

Dr NITIN AGARWAL

M.B.B.S., MD (Path)
DMCR/R/01436

47, Harsh Vihar, Pitampura, New Delhi-110034 | Ph.: 011-42480101, 9599913051

E-mail: oneplusul@gmail.com | Web.: www.oneplusul.in

Page 3 of 6



OnePLUS

Ultrasound Lab

— QUALITY FIRST... ALWAYS! —

Dr. Nitin Agarwal
Pathologist & Director
Ex. Sr. Res. MAMC
& Lok Nayak Hospital
Ex. Chief of Lab Dr. Lal Path Labs.

Dr. Pooja (Garg) Agarwal
Radiologist & Director
MAMC & Lok Nayak Hospital



NAME	:Mr. GAURAV MITTAL	Barcode No	:10107395
AGE/GENDER	:32 YRS/Male	SPECIMEN DATE	:01/Nov/2021 09:31AM
PATIENT ID	:86547	SPECIMEN RECEIVED	:01/Nov/2021 01:26PM
REFERRED BY	:Dr. MEDIWHEEL	REPORT DATE	:01/Nov/2021 04:41PM
CENTRE NAME	:ONEPLUS ULTRASOUND LAB	LAB NO.	:012111010005

Test Name	Result	Unit	Ref. Range
LDL/HDL Ratio	2.2		0 - 3.55
According to ATP III and NCEP guidelines			

Parameter	Normal	Desirable	Borderline	High
Total cholesterol	<200	200-239		240
Triglycerides	<150	150-199	200-499	500
LDL	Optimal <100 Near Optimal 100-129	130-159	160-180	190
HDL	<40 : LOW 60 : HIGH			

ENDOCRINOLOGY

PSA TOTAL

Prostatic specific antigen, Total 0.65 ng/ml <4.0

< 40 years	0.21 to 1.72 ng/ml
40 - 49	0.27 to 2.19 ng/ml
50 - 59	0.27 to 3.42 ng/ml
60 - 69	0.22 to 6.16 ng/ml
> 69	0.21 to 6.77 ng/ml

Notes:

PSA is principally produced by the glandular epithelium of the prostate, and is secreted in the seminal fluid. PSA is also present in urine and blood. PSA acts on seminal fluid to fluidify and increase sperm mobility. PSA levels rise in prostatic pathologies such as benign prostatic hyperplasia (BPH) or prostate cancer.

THYROID PROFILE(T3,T4,TSH)

Triiodothyronine total [t3]	0.88	ng/dl	0.52-1.9
Thyroxine total [t4]	5.60	µg/dl	4.4 - 10.8
TSH (Thyroid Stimulating Hormone)	2.10	µIU/ml	0.25-5.0

Checked By.

DR. NITIN AGARWAL
MBBS,MD(PATHOLOGIST)

Dr NITIN AGARWAL
M B B S, MD (Path)
DMCR/01130

47, Harsh Vihar, Pitampura, New Delhi-110034 | Ph.: 011-42480101, 9599913051
E-mail: oneplusul@gmail.com | Web.: www.oneplusul.in

Page 4 of 6



OnePLUS
Ultrasound Lab
— QUALITY FIRST... ALWAYS! —

Dr. Nitin Agarwal
Pathologist & Director
Ex. Sr. Res. MAMC
& Lok Nayak Hospital
Ex. Chief of Lab Dr. Lal Path Labs.

Dr. Pooja (Garg) Agarwal
Radiologist & Director
MAMC & Lok Nayak Hospital



NAME	:Mr. GAURAV MITTAL	Barcode No	:10107395
AGE/GENDER	:32 YRS/Male	SPECIMEN DATE	:01/Nov/2021 09:31AM
PATIENT ID	:86547	SPECIMEN RECEIVED	:01/Nov/2021 01:26PM
REFERRED BY	:Dr. MEDIWHEEL	REPORT DATE	:01/Nov/2021 04:41PM
CENTRE NAME	:ONEPLUS ULTRASOUND LAB	LAB NO.	:012111010005

Test Name	Result	Unit	Ref. Range
-----------	--------	------	------------

AGE WISE VARIATION IN TSH

AGE	TSH(μIU/ml)	AGE	TSH(μIU/ml)
1-4 weeks	1.00 - 19.0	16-20 yrs	0.25 - 5.0
1-12 mths	1.70 - 9.1	21 - 80 yrs	0.25 - 5.0
1-5 yrs	0.80 - 8.2	I st trimester	0.25 - 5.0
6-10 yrs	0.25 - 5.0	II nd trimester	0.50 - 5.0
11-15 yrs	0.25 - 5.0	III rd trimester	0.4 - 6.0

Reference ranges - Interpretation of Diagnostic tests - (Jacques Wallach)

1. Primary hypothyroidism is accompanied by depressed serum T3 and T4 values and elevated serum TSH level.
2. Primary hyperthyroidism is accompanied by elevated serum T3 and T4 levels along with depressed TSH values.
3. Slightly elevated T3 levels may be found in pregnancy and estrogen therapy, while depressed levels may be encountered in severe illness, renal failure and during therapy with drugs like propranolol and propyl thiouracil.
4. Although elevated TSH levels are nearly always indicative of primary hypothyroidism, and may be seen in secondary thyrotoxicosis

CLINICAL PATHOLOGY

URINE ROUTINE

Physical examination

Quantity	20	ML
Colour	PALE YELLOW	
Transparency	SLIGHTLY TURBID	CLEAR
Sp.gravity	1.015	1.010-1.030
pH	6.00	
Reaction	ACIDIC	ACIDIC

Chemical examination

Urine protein	NIL	NIL
Urine sugar	NIL	NIL
Bilirubin, urine	NEGATIVE	NEGATIVE
Urobilinogen	NORMAL	NORMAL
Ketones	NEGATIVE	NEGATIVE

Checked By.

DR. NITIN AGARWAL
MBBS, MD(PATHOLOGIST)

Dr NITIN AGARWAL
M B B S , MD (Path)

47, Harsh Vihar, Pitampura, New Delhi-110034 | Ph.: 011-42480101, 9599913051

E-mail: oneplusul@gmail.com | Web.: www.oneplusul.in

Page 5 of 6



OnePLUS
Ultrasound Lab
— QUALITY FIRST... ALWAYS! —

Dr. Nitin Agarwal

Pathologist & Director
Ex. Sr. Res. MAMC
& Lok Nayak Hospital
Ex. Chief of Lab Dr. Lal Path Labs.

Dr. Pooja (Garg) Agarwal

Radiologist & Director
MAMC & Lok Nayak Hospital



NAME	:Mr. GAURAV MITTAL	Barcode No	:10107395
AGE/GENDER	:32 YRS/Male	SPECIMEN DATE	:01/Nov/2021 09:31AM
PATIENT ID	:86547	SPECIMEN RECEIVED	:01/Nov/2021 01:26PM
REFERRED BY	:Dr. MEDIWHEEL	REPORT DATE	:01/Nov/2021 04:41PM
CENTRE NAME	:ONEPLUS ULTRASOUND LAB	LAB NO.	:012111010005

Test Name	Result	Unit	Ref. Range
<u>Microscopic examination</u>			
Pus cells.	2-3	/HPF	0-2
Epithelial cells	0-1	/HPF	NIL
R.B.C.	NIL	/HPF	NIL
Casts	NIL	/HPF	NIL
Crystals	NIL	/HPF	NIL
Bacteria	NIL	/HPF	NIL
Others.	NIL	NIL	NIL
STOOL ROUTINE			
<u>Physical examination</u>			
Colour	BROWNISH		
Consistency	SEMI FORMED		Semi Formed
Blood	ABSENT		Absent
Mucus	ABSENT		Absent
<u>Chemical examination, stool</u>			
pH	5.50		
<u>Microscopic examination</u>			
Pus cells	NIL	/HPF	NIL
Red blood cells	NIL	/HPF	NIL
Ova	NIL		NIL
Cysts	NIL		NIL
Bacteria	NIL	/HPF	NIL
Others	NIL		

*** End Of Report ***

Checked By.

DR. NITIN AGARWAL
MBBS,MD(PATHOLOGIST)

Dr NITIN AGARWAL
MBBS, MD (Path)
DMC/R/01436

47, Harsh Vihar, Pitampura, New Delhi-110034 | Ph.: 011-42480101, 9599913051
E-mail: oneplusul@gmail.com | Web.: www.oneplusul.in

Page 6 of 6

Clinical correlation is essential for final diagnosis. • If test results are unsatisfactory please contact personally or on phone. • This report is for perusal of doctors only. • All disputes Subject to Delhi Jurisdiction only. • Not for medicolegal purposes. • All congenital anomalies in a foetus may not be diagnosed in routine obstetric ultrasound.