



भारत सरकार
GOVERNMENT OF INDIA



राणा अनिल
Rana Anil
जन्म तारीख/ DOB: 03/04/1974
पुरुष / MALE



4610 7117 8963

મારો આધાર, મારી ઓળખ



भारतीय विशिष्ट पहचान प्राधिकरण
UNIQUE IDENTIFICATION AUTHORITY OF INDIA

सरनाम :
S/O राम नारायण सिंह, डी-204,
अनंता लाईफस्टाइल, आजवा रोड,
सयाजपुरा नी पास, आजवा
चोकडी पास, वडोदरा, वडोदरा,
गुजरातगुजरात - 390019

Address:
S/O Ram Narayan Singh, D-204,
Ananta Lifestyle, Ajwa Road,
Near Sayajipura, Near Ajwa
Chokadi, Vadodara, Vadodara,
Gujarat - 390019

4610 7117 8963



1947




help@uidai.gov.in



www.uidai.gov.in



बैंक ऑफ बड़ोदा
Bank of Baroda



नाम राणा अनिल
Name RANA ANIL
ए.सी. नंबर 114768
E.C. No. 114768

D-K

जारीकर्ता प्राधिकारी
Issuing Authority

Anil

धारक के हस्ताक्षर
Signature of Holder

LETTER OF APPROVAL / RECOMMENDATION

To,

The Coordinator,
Mediwheel (Arcofemi Healthcare Limited)
Helpline number: 011- 41195959

Dear Sir / Madam,

Sub: Annual Health Checkup for the employees of Bank of Baroda

This is to inform you that the following employee wishes to avail the facility of Cashless Annual Health Checkup provided by you in terms of our agreement.

PARTICULARS	EMPLOYEE DETAILS
NAME	MR. ANIL RANA
EC NO.	114768
DESIGNATION	SINGLE WINDOW OPERATOR A
PLACE OF WORK	VADODARA,HO, ALKAPURI
BIRTHDATE	03-04-1974
PROPOSED DATE OF HEALTH CHECKUP	11-02-2023
BOOKING REFERENCE NO.	22M114768100039824E

This letter of approval / recommendation is valid if submitted along with copy of the Bank of Baroda employee id card. This approval is valid from **02-02-2023** till **31-03-2023** The list of medical tests to be conducted is provided in the annexure to this letter. Please note that the said health checkup is a **cashless facility** as per our tie up arrangement. We request you to attend to the health checkup requirement of our employee and accord your top priority and best resources in this regard. The EC Number and the booking reference number as given in the above table shall be mentioned in the invoice, invariably.

We solicit your co-operation in this regard.

Yours faithfully,

Sd/-

Chief General Manager
HRM Department
Bank of Baroda

(Note: This is a computer generated letter. No Signature required. For any clarification, please contact Mediwheel (Arcofemi Healthcare Limited))



Bill of Supply (Interim Bill)



Patient ID : 20230208257

Age / Sex : 49y / M

Patient Name : ANIL . RANA

Dr. Name : DR SAURABH JAIN

Referred By : self

City/Village : Vadodara

Class : Contract

PAN Card : AAQCS5566G

Visit No. : OPD20230224626(OPD)

Bill No. : OPD20230224626

Bill Date : N/A

Speciality : Internal Medicine

Company Name : Mediwheel Health Check Up

GSTIN : 24AAQCS5566G2ZW

Mobile No. : 8780441052

Expense Details	Qty	Rate	Gross Amount	Waive	Net Amount
Visit Charge					
11/02/2023 Physician First Consultation OPD	1.0	0.0	0.00	0.0	0.00
Ophthalmologist First Consultation OPD	1.0	0.0	0.00	0.0	0.00
Dentist First Consultation OPD	1.0	0.0	0.00	0.0	0.00
Visit Charge (Subtotal)			0.0	0.0	0.00
PATHOLOGY					
11/02/2023 CBC, ESR	1.0			0.0	
Urine R/M	1.0			0.0	
STOOL EXAMINATION	1.0			0.0	
Blood Group	1.0			0.0	
FBS & PPBS	1.0			0.0	
TFT (Thyroid Function Test)	1.0			0.0	
Lipid Profile	1.0			0.0	
RENAL FUNCTION TEST	1.0			0.0	
LFT (Liver Function Test)	1.0			0.0	
PSA (Prostate Specific Antigen) Male	1.0			0.0	
HBA1C	1.0			0.0	
MediWheel Full Body Health Check-Up(Male Above 40)	1.0	2500.0	2500.00	0.0	2500.00
PATHOLOGY (Subtotal)			2500.0	0.0	2500.00
Radiology					
11/02/2023 X-RAY CHEST PA	1.0			0.0	
USG WHOLE ABDOMEN SCREENING	1.0			0.0	
X-RAY CHEST PA	1.0	0.0	0.00	0.0	0.00
USG WHOLE ABDOMEN SCREENING	1.0	0.0	0.00	0.0	0.00
Radiology (Subtotal)			0.0	0.0	0.00
Non Invasive Cardiology					
11/02/2023 ECG Charge(OPD Base)	1.0	0.0	0.00	0.0	0.00
ECHO COLOUR DOPPLER SCREENING	1.0	0.0	0.00	0.0	0.00
Non Invasive Cardiology (Subtotal)			0.0	0.0	0.00
Total Bill Amount					2500.00
Net payable amount					2500.00
Bill Outstanding					2500.00

Received With Thanks From ANIL . RANA of Rs 0.0 /-
(Rs Zero Only)

Printed By : (GAYATRI)
For, Savita Hospital-Live





PHYSICIAN EXAMINATION

Name :	ANIL RANA	Age :	49/MALE
Reg.No :	20230208257	DOE :	11/02/2023

Physical Examination:

Height:	170 CM	Weight:	74 KG	PULSE:	85	Temperature:	NORMAL
---------	-----------	---------	----------	--------	----	--------------	--------

BMI :	25.60	BP :	120/82	SPO2	97%
-------	-------	------	--------	------	-----

Chief Complaint :	NAD
Past History :	NAD
General Examination :	NAD
Systemic Examination :	NAD
INVESTIGATION :	NAD
ADVICE :	ADD/FFD

DR. SAURABH JAIN





Examination By Ophthalmologist

Name :	<u>ANIL RANA</u>	Age :	49/MALE
Reg.No :	20230208257	DOE :	11/02/2023

Present Complaints :	NIL
Medical History :	NIL
Examination Of Eye :	NIL

External Examination :	NAD	NAD
Schiotz Tonometry IOP :	NAD	NAD
Fundus :	NILL	

Without Glass	Distant Vision : 6/6	6/6
	Near Vision :	
With Glass	Distant Vision : N6WITH+1.25DSPH	N6WITH+1.50DSPH
	Near Vision :	
Colour Vision (With Ishihara Chart) :	WNL	
Advice :	NIL	

DR CHETAN CHAUHAN





EXAMINATION BY DENTAL

Name :	ANIL RANA	Age/Sex:	49/MALE
Reg No :	20230208257	DOE:	11/02/2023

Presenting Complaint :	NO CHIEF COMPLAINT
-------------------------------	---------------------------

Medical History :	NAD
--------------------------	------------

Examination :	CALCULUS++
----------------------	-------------------


Impression :	NAD
---------------------	------------

Advice :	SCALING
-----------------	----------------

DR RESDA MALEK





Patient Name : Anil . Rana	Sample No. : 20230214578 
Patient ID : 20230208257	Visit No. : OPD20230224626
Age / Sex : 49y/Male	Coll. Date : 11/02/2023 08:38
Consultant : DR SAURABH JAIN	S. Coll. Date : 11/02/2023 10:08
Ward : -	Report Date : 11/02/2023 13:16

CBC, ESR

Investigation	Result	Normal Value
Hemoglobin :	14.4 gm/dl	13.5 to 18.0 gm/dl
P.C.V. :	44.4 %	42.0 to 52.0 %
M.C.V. :	77.1 fL [L]	78 to 100 fL
M.C.H. :	25 pg [L]	27 to 31 pg
M.C.H.C. :	32.4 g/dl	32 to 36 g/dl
RDW :	11.4 %	11.5 to 14.0 %
RBC Count :	5.76 X 10 ⁶ / cumm	4.7 to 6.0 X 10 ⁶ / cumm
Polymorphs :	72 % [H]	38 to 70 %
Lymphocytes :	25 %	15 to 48 %
Eosinophils :	1 %	0 to 6 %
Monocytes :	2 % [L]	3 to 11 %
Basophils :	0 %	0.0 to 1.0 %
Total :	100	< 100 > 100
WBC Count :	6200 /cmm	4000 to 10000 /cmm
Platelets Count :	191000 /cmm	1,50,000 to 4,50,000 /cmm
ESR - After One Hour :	7 mm/hr	1 to 13 mm/hr



Dr. Mehul Desai
M.B.D.C.P
Reg.No.G-9521



Patient Name : Anil . Rana	Sample No. : 20230214578 
Patient ID : 20230208257	Visit No. : OPD20230224626
Age / Sex : 49y/Male	Coll. Date : 11/02/2023 08:38
Consultant : DR SAURABH JAIN	S. Coll. Date : 11/02/2023 10:08
Ward : -	Report Date : 11/02/2023 13:16

Blood Group

Investigation	Result	Normal Value
BLOOD GROUP :		
ABO	O	
Rh	Positive	

FBS & PPBS

Investigation	Result	Normal Value
Blood Sugar (FBS) :	<u>109</u> mg/dl [H]	74 - 100 mg/dl
Urine Sugar (FUS) :	Nil	
Blood Sugar (PP2BS) :	95 mg/dl	70 to 120 mg/dl
Urine Sugar (PP2US) :	Nil	


HBA1C

Investigation	Result	Normal Value
Glycosylated Hb :	<u>6.1</u> % [H]	Near Normal Glycemia : 6 to 7 Excellent Control : 7 to 8 Good Control : 8 to 9 Fair Control : 9 to 10 Poor Control : > 10
Average Plasma Glucose of Last 3 Months :	128.37	



Dr.Mehul Desai
M.B.D.C.P
Reg.No.G-9521



Patient Name :	Anil . Rana	Sample No. :	20230214578 
Patient ID :	20230208257	Visit No. :	OPD20230224626
Age / Sex :	49y/Male	Coll. Date :	11/02/2023 08:38
Consultant :	DR SAURABH JAIN	S. Coll. Date :	11/02/2023 10:08
Ward :	-	Report Date :	11/02/2023 13:16


LFT (Liver Function Test)

Investigation	Result	Normal Value
Total Bilirubin :	0.7 mg/dl	0.2 to 1.0 mg/dl
Direct Bilirubin :	0.3 mg/dl	0.0 to 0.2 mg/dl
Indirect Bilirubin :	0.4 mg/dl	0.0 to 0.8 mg/dl
AST (SGOT) :	23 U/L	5 to 34 U/L
ALT (SGPT) :	10 U/L	0 to 55 U/L
Total Protein (TP) :	7.4 g/dl	6.4 to 8.3, g/dl
Albumin (ALB) :	4.1 g/dl	3.5 to 5.2 g/dl
Globulin :	3.3 g/dl	2.3 to 3.5 g/dl
A/G Ratio :	1.24	
Alkaline Phosphatase (ALP) :	108 U/L	40 to 150 U/L
GAMMA GT. :	11 U/L	7 to 35 U/L



Dr. Mehul Desai
M.B.D.C.P
Reg.No.G-9521



Patient Name :	Anil . Rana	Sample No. :	20230214578 
Patient ID :	20230208257	Visit No. :	OPD20230224626
Age / Sex :	49y/Male	Coll. Date :	11/02/2023 08:38
Consultant :	DR SAURABH JAIN	S. Coll. Date :	11/02/2023 10:08
Ward :	-	Report Date :	11/02/2023 13:16

Lipid Profile


Investigation	Result	Normal Value
Sample :	Fasting	
Sample Type :	Normal	
Cholesterol (Chol) :	129 mg/dl	Low risk : < 200 Moderate risk : 200 - 239 High risk : > or = 240
Triglyceride :	70 mg/dl	Normal : < 200.0 High : 200 - 499 Very High : > or = 500
HDL Cholesterol :	40 mg/dl	Low risk: >or = 60 mg/dL High risk : Up to 35 mg/dL
LDL :	75 mg/dl [L]	131.0 to 159.0(N) < 130.0(L) > 159.0(H)
VLDL :	14 mg/dl	Up to 0 to 34 mg/dl
LDL/HDL Ratio :	1.88	Low risk : 0.5 to 3.0 Moderate risk : 3.0 to 6.0 Elevted level high > 6.0
Total Chol / HDL Ratio :	3.23	Low Risk : 3.3 to 4.4 Average Risk : 4.4 to 7.1 Moderate Risk : 7.1 to 11.0 High Risk : > 11.0
Total Lipids :	539 mg/dl	400 to 700 mg/dl

Note :- Lipemic samples give high triglyceride value and falsely low LDL value.



Dr. Mehul Desai
M.B.D.C.P
Reg.No.G-9521



Patient Name :	Anil . Rana	Sample No. :	20230214578 
Patient ID :	20230208257	Visit No. :	OPD20230224626
Age / Sex :	49y/Male	Coll. Date :	11/02/2023 08:38
Consultant :	DR SAURABH JAIN	S. Coll. Date :	11/02/2023 10:08
Ward :	-	Report Date :	11/02/2023 15:14

RENAL FUNCTION TEST

Investigation	Result	Normal Value
Creatinine :	0.8 mg/dl	0.6 - 1.4 mg/dl
Urea :	16 mg/ dl	13 - 45 mg/dl
Uric Acid :	6.7 mg/dl	3.5 - 7.2 mg/dl
Calcium :	7.8 mg/dl	8.5 - 10.5
Phosphorus :	4.4 mg/dl	1.5 - 6.8



Dr.Mehul Desai
M.B.D.C.P
Reg.No.G-9521



TEST REPORT

Name	: ANIL RANA	Acc. ID	: 231002207
Age/Sex	: 49 Years / Male	Birthdate	: Regd. Dt : 11-Feb-2023 01:06 PM
Refd. By	: SAVITA SUPERSPECIALITY HOSPITAL	Status	: Final
Sample	: Serum (Blood in Plain)	PassportNo:	: Coll Dt. TM. : 11-Feb-2023 12:00 PM
Client Details	: SAVITA SUPERSPECIALITY HOSPITAL	Mobile	: Recd. Dt. Tm. : 11-Feb-2023 01:06 PM
			: Report Dt. Tm. : 11-Feb-2023 02:11 PM

IMMUNOLOGY


Test Name	Result	Unit	Biological Ref. Interval
-----------	--------	------	--------------------------

THYROID FUNCTION TEST

T3 (Triiodothyronine) <small>CHEMILUMINESCENT MICROPARTICLE IMMUNOASSAY</small>	1.64	ng/mL	0.97 - 1.69
T4 (Thyroxine) <small>CHEMILUMINESCENT MICROPARTICLE IMMUNOASSAY</small>	11.90	µg/dL	5.5 - 11.0
TSH <small>CHEMILUMINESCENT MICROPARTICLE IMMUNOASSAY</small>	2.588	µIU/ml	0.4001 - 4.049

----- End Of Report -----

This is an Electronically Authenticated Report.


Dr. Kinjal Patel
M. D. PATHOLOGY
GMC No. G-33123

Verified By
Auto

Dr. VIRAL A. PATEL
M. D. PATHOLOGY
GMC No. G-22658



Unipath Specialty Laboratory (Baroda) LLP- Platinum Complex, Opp. HDFC Bank, Nr. Radha Krishna char rasta, Akota, Vadodara - 390020
 Mobile: 7228800500 / 8155028222 | Email: info.baroda@unipathllp.in



TEST REPORT

Reg. No. : 30201005525	Reg. Date : 11-Feb-2023 12:01	Collected On : 11-Feb-2023 12:01
Name : Mr. ANIL RANA		Approved On : 11-Feb-2023 13:14
Age : 49 Years	Gender : Male	Ref. No. :
Ref. By :		Dispatch At :
Location : SAVITA SUPERSPECIALTY HOSPITAL @ WAGHODIYA ROAD		Tele No. :

Test Name	Results	Units	Bio. Ref. Interval
-----------	---------	-------	--------------------

PROSTATE SPECIFIC ANTIGEN

PSA	0.480	ng/mL	0 - 4
-----	-------	-------	-------

Method:CLIA

Sample Type:Serum

Note:

PSA is a glycoprotein that is produced by the prostate gland, the lining of the urethra, and the bulbourethral gland. Normally, very little PSA is secreted in the blood. Increases in glandular size and tissue damage caused by benign prostatic hypertrophy, prostatitis, or prostate cancer may increase circulating PSA levels.

Digital rectal examination generally does not increase normal prostate-specific antigen (PSA) values. However, cystoscopy, urethral instrumentation, and prostate biopsy may increase PSA levels.

Useful For

1. Evaluating patients with documented prostate problems in whom multiple prostate-specific antigen tests may be necessary per year
2. Monitoring patients with a history of prostate cancer as an early indicator of recurrence and response to treatment.
3. Prostate cancer screening.

----- End Of Report -----

This is an electronically authenticated report.

Test done from collected sample.

Printed On: 11-Feb-2023 13:16

Dr. Ankit Jhaveri
 MD Pathology
 Reg. G-15471

Page 1 of 1



Patient Name :	Anil . Rana	Sample No. :	20230214578 
Patient ID :	20230208257	Visit No. :	OPD20230224626
Age / Sex :	49y/Male	Coll. Date :	11/02/2023 08:38
Consultant :	DR SAURABH JAIN	S. Coll. Date :	11/02/2023 10:08
Ward :	-	Report Date :	11/02/2023 13:16

Urine R/M

Investigation	Result	Normal Value
Quantity - :	20 ml	
Colour - :	Pale Yellow	
Reaction (pH) :	5.0	4.6-8.0
Turbidity :	Clear	
Deposit :	Absent	Absent
Sp.Gravity :	1.030	1.005-1.010
Protein :	Absent	Absent
Glucose :	Absent	Absent
Bile Salts :	Absent	Absent
Bile pigments :	Absent	Absent
Ketones :	Absent	Absent
Urobilinogen :	Absent	
Blood :	Trace	Absent
Pus Cells :	1-2 /hpf	0-5/hpf
Red Blood Cells :	1-3 /hpf	Absent
Epithelial Cells :	1-2 /hpf	



Dr.Mehul Desai
M.B.D.C.P
Reg.No.G-9521

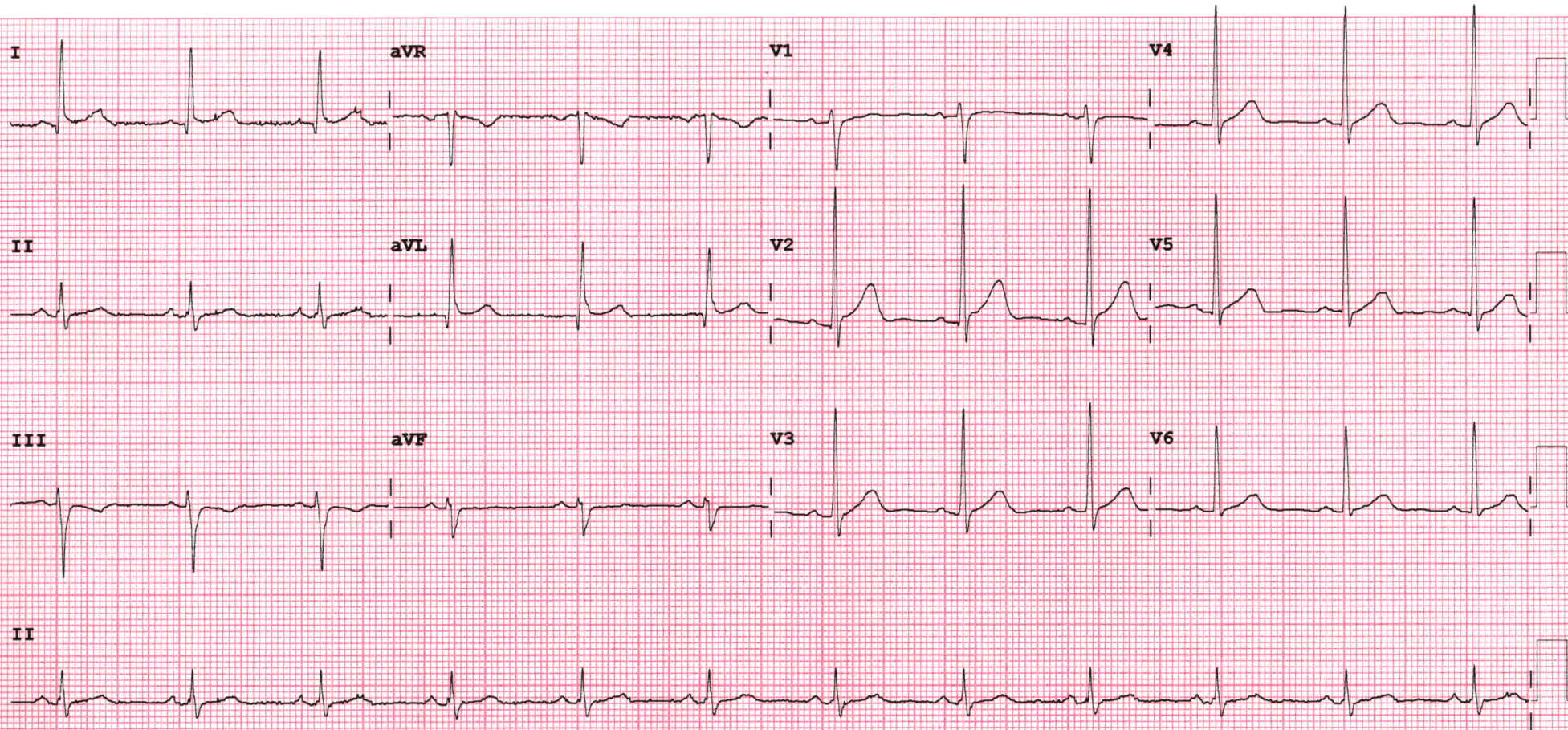
Rate 71

PR 152
QRSD 92
QT 376
QTc 409

--AXIS--

P 61
QRS -19
T 8

12 Lead; Standard Placement



Device:

Speed: 25 mm/sec

Limb: 10 mm/mV

Chest: 10.0 mm/mV

F 50~ 0.50-150 Hz W

PH09

P?



2D-ECHOCARDIOGRAPHY AND COLOR DOPPLER REPORT

NAME: ANIL RANA

AGE/SEX: 49 YRS/ MALE

DATE: 11/02/2023

REF BY: HCP

- NORMAL LV SIZE WITH NORMAL LV SYSTOLIC FUNCTION. LVEF = 60%.
- NO RWMA PRESENT AT REST.
- NO LV DIASTOLIC DYSFUNCTION.
- NORMAL MITRAL VALVE, TRIVIAL MR. NO MS.
- NORMAL TRICUSPID AORTIC VALVE, NO AR. NO AS.
- TRIVIAL TR . NO PAH.
- NORMAL LA,RA, RV SIZE WITH NORMAL RV SYSTOLIC FUNCTION
- NORMAL MPA, RPA & LPA.
- INTACT IAS & IVS.
- NO E/O INTRACARDIAC CLOT/VEGETATION/PE.
- NORMAL SIZE OF IVC. NORMAL PERICARDIUM.

DIMENTIONS: LA:35mm, AO: 25mm, LV: IVS/PW – 10/10 mm, LV chamber S/D- 46/34mm

CONCLUSION:

- NORMAL LV/RV SIZE AND SYSTOLIC FUNCTION (LVEF = 60%)
- NO LV DIASTOLIC DYSFUNCTION
- TRIVIAL TR, NO PULMONARY HYPERTENSION

DR.NIRAV BHALANI
[CARDIOLOGIST]

DR.ARVIND SHARMA
[CARDIOLOGIST]

DR KASHYAP PATEL
[CARDIOLOGIST]

DR PRUTHVIRAJ PUWAR
[CARDIOLOGIST]





Saturday, February 11, 2023

ANIL RANA

49 YEARS/MALE

ULTRASONOGRAPHY OF ABDOMEN AND PELVIS

Liver shows normal size and shows raised echotexture suggest p/o fatty liver.

PV, CBD and intrahepatic biliary radicals shows no dilatation.

The gall bladder is distended and show normal gall bladder. There is no evidence of gallstones.

Spleen appears normal in size and echotexture. No evidence of focal lesion.

Pancreas appears normal in size and echotexture. No focal lesion.

A simple cortical cyst of size 22 x 22 mm is noted at upper pole of right kidney.

Both kidneys show normal size, position and cortical echogenicity.

Right kidney measures 9.9 cm and Left kidney measures 10.4 cm.

Corticomedullary differentiation is preserved bilaterally.

No calculus or hydronephrosis on either side.

The urinary bladder is distended and appears normal.

Prostate appears normal. (17 cc) No focal lesion.

No evidence of Lymphadenopathy or ascites seen.

No e/o dilated bowel loops seen.

CONCLUSION:

- **FATTY LIVER**
- **RIGHT RENAL SIMPLE CORTICAL CYST**



DR. CHETNA DUHAN, M.D

CONSULTANT RADIOLOGIST



11/02/2023
ANIL RANA
49 YEARS/MALE

CHEST X RAY PA VIEW

Rotation++

Unfolding of arch of aorta is noted.

Both the lung fields appear normal.

Both costophrenic angles appear clear.

Cardiac silhouette appear normal.

Both hila appears normal.

Mediastinum and aorta appear normal.

No evidence of free gas seen under dome of diaphragm.



DR. CHETNA DUHAN, M.D
CONSULTANT RADIOLOGIST