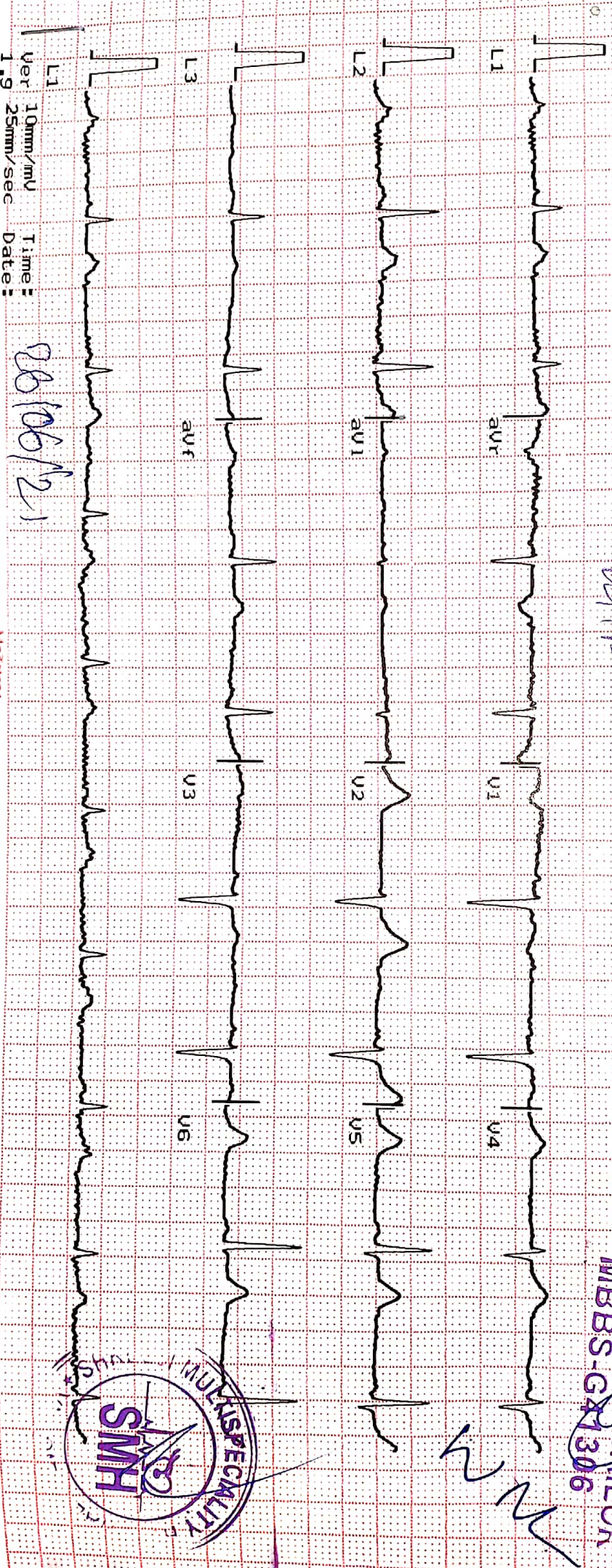



Name : _____
yrs _____ cm _____ Kg _____ BP _____

Venkataraman Suman
2412

DR. VIKAS TALLON
MBBS-GA1306



Maestro5





SHREEJI Multispeciality Hospital

Inspiring better health...

SHREEJI OCCUPATIONAL CENTRE SHREEJI PATHOLOGY LABORATORY

108, Tower-B, Senate Square, Opp. Gangotri Apartment, Vuda Char rasta, Gotri, Vadodara-390021.
M. : 9157022510, Email : shreejihospital19@yahoo.com, smh31082015@gmail.com

NAME Van Katarajram Gurus	DATE 26/06/2021
	SR. NO. 15 SEX. Female AGE 24 HEIGHT - 156 CM. WEIGHT - 61.48

HISTORY

Present History : **NO**
 Past Illness History : **Diabetes/Hypertension/Tuberculosis/Asthma/Epilepsy NO**
 Past Occupational History :
 Family History : **NO**
 Personal History :
 Addiction : **Tobacco/Gutkha/Smoking/Alcohol NO**

GENERAL EXAMINATION

T.P.R. : **77/8/20** B.P. : **118/80** mm Hg :
 Pallor/Icterus/Cyanosis/Varicosity/Lymph Nodes/Thyroid/Oedema/NVE/Other : **NO**

SYSTEMIC EXAMINATION

R.S. :
 C.V.S. :
 C.N.S. : **NO**
 A.S. :
 Musculo-skelet System :

E.N.T. Ex. Dental Ex. Skin Ex. NO Psychic Ex.	ACUITY OF VISION			
	Without Glass	DISTANT	RT EYE 6/6	LTE EYE 6/6
		Near	6/6	6/6
	With Glass	DISTANT	6/—	6/—
Near		6/—	6/—	
COLOUR BLINDNESS NO				

REMARK **Nil**

ADVICE

The Worker is **FIT/UNFIT** for the assigned job.



DR. VIMAL TAILOR
MBBS G41306

DR. VIMAL TAILOR
Occupational Physician
(M.B.B.S, CIH)

REG NO.: G-41306

તમારો આધાર નંબર / Your Aadhaar No. :

5239 2831 0412

VID : 9179 8165 5398 7116

મારો આધાર, મારી ઓળખ



ભારત સરકાર

Government of India



ગુન્ના વેંકટારત્નમ

Gunna Venkataratnam

જન્મ તારીખ/DOB: 27/08/1997

સ્ત્રી/ FEMALE

5239 2831 0412

VID : 9179 8165 5398 7116

મારો આધાર, મારી ઓળખ

G. Venkataratnam



Scanned with CamScanner

Scanned with CamScanner

SHREEJI MULTISPECIALITY HOSPITAL

112/F TOWER A, SENATE SQUARE, VUDA CHOKDI, GOTRI

NAME: VENKATARATNAM GUNNA
AGE/GENDER: 24 yrs/FEMALE

ID: 19
HEIGHT: 156 cm.

PROTOCOL: Bruce
WEIGHT: 61 Kg.

Summary report

DATE/TIME: 26-06-2021 09:29
REF. BY: SMOKER: Non Smoker

Test Results

Protocol : Bruce
Target HR : 196(167)bpm
Maximum HR : 156(80 %) bpm
Max Work load 8.41
Exer. Time : 7:54min
Recov. Time : 1:30min
BMI : 25
Max RPP(1000) : 24.96
Max BP : 160/110 mmHg

(1) Reason for termination :
Fatigue

(2) Functional Capacity :
Normal

(3) HR Response to Exercise :
Appropriate

(4) BP Response to Exercise :
Normal resting BP - Appropriate response

(5) Overall Impression :
Normal stress test

(6) Comment :
Normal ECG

(1) Restring ECG :
Normal

(2) Chest Pain :
None

(3) ST Changes :

(4) Arrhythmias :
None

(5) History :
None

(6) Medication :
None



DR. VIMAL TAILOR
MBBS/G41306

DR VIMAL TAILOR (G41306)

SHREEJI MULTISPECIALITY HOSPITAL

112/F TOWER A, SENATE SQUARE, VUDA CHOKDI, GOTRI

NAME: VENKATARATNAM GUNNA ID: 19 PHOTOCOL: Bruce REF. BY: Summary report
 AGE/GENDER: 24 yrs/FEMALE HEIGHT: 156 cm. WEIGHT: 61 Kg. DATE/TIME: 26-06-2021 09:29 SMOKER: Non Smoker

Stage	Time Min:Sec	HR bpm	BP mmHg	Speed(mph)/Gr ade (°)	Load METS	RPP	II	V2	V5
Supine	00:12	79	126/84	0.0/0.0	1.0	9.954	-0.1/0.4	0.8/0.5	-0.2/0.1
Standing	00:12	84	126/84	0.0/0.0	1.0	10.584	-0.1/0.5	0.8/0.4	-0.3/0.1
HyperV	00:18	77	126/84	0.0/0.0	1.0	9.702	-0.1/0.5	1.0/0.5	-0.2/0.1
Exer : 1/7	03:00	113	140/90	1.7/10.0	4.8	15.82	-0.1/0.8	1.1/0.7	-0.2/0.5
Exer : 2/7	03:00	129	150/100	2.5/12.0	6.8	19.35	-0.1/2.3	1.6/1.5	-0.1/1.3
Exer : 3/7	01:54	159	160/110	3.4/14.0	8.4	25.44	0.5/3.3	2.5/2.7	0.7/2.9
Peak	07:54	156	160/110	3.4/14.0	8.4	24.96	0.7/3.2	1.9/2.3	0.6/1.7
Recovery	01:00	114	140/90	0.0/0.0	1.0	15.96	0.6/2.7	1.6/1.3	0.4/1.5
Recovery	01:30	97	128/84	0.0/0.0	1.0	12.416	1.8/2.9	1.1/0.8	-1.4/0.1

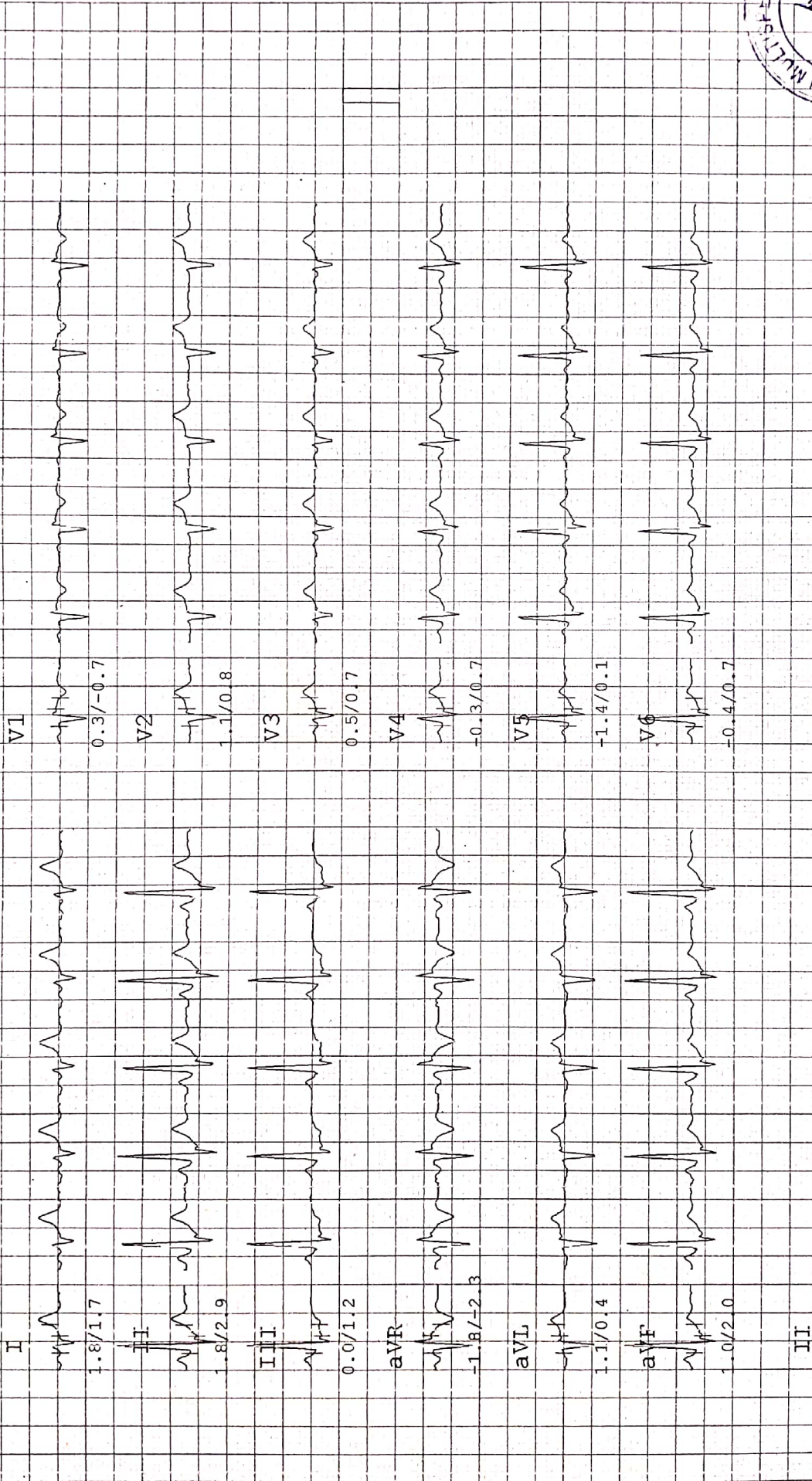


SHREEJI MULTISPECIALITY HOSPITAL

NAME : VENKATARATNAM GUNNI ID: 19
 112/F-TOWER-A, SENATE SQUARE, VUDA CHOKKIL, GOTRI
 AGE/GENDER: 24/FEMALE BP: 128/84 mmHg
 DATE/TIME: 26/Jun/2021(09:29) HR: 97 bpm

ST @ 10 mm/mV
 STL in mm
 STS in mm/sec

PROTOCOL : Bruce
 Linked Median Report:
 STAGE NAME: Recovery
 STAGE TIME: 01:30 PostJ 80

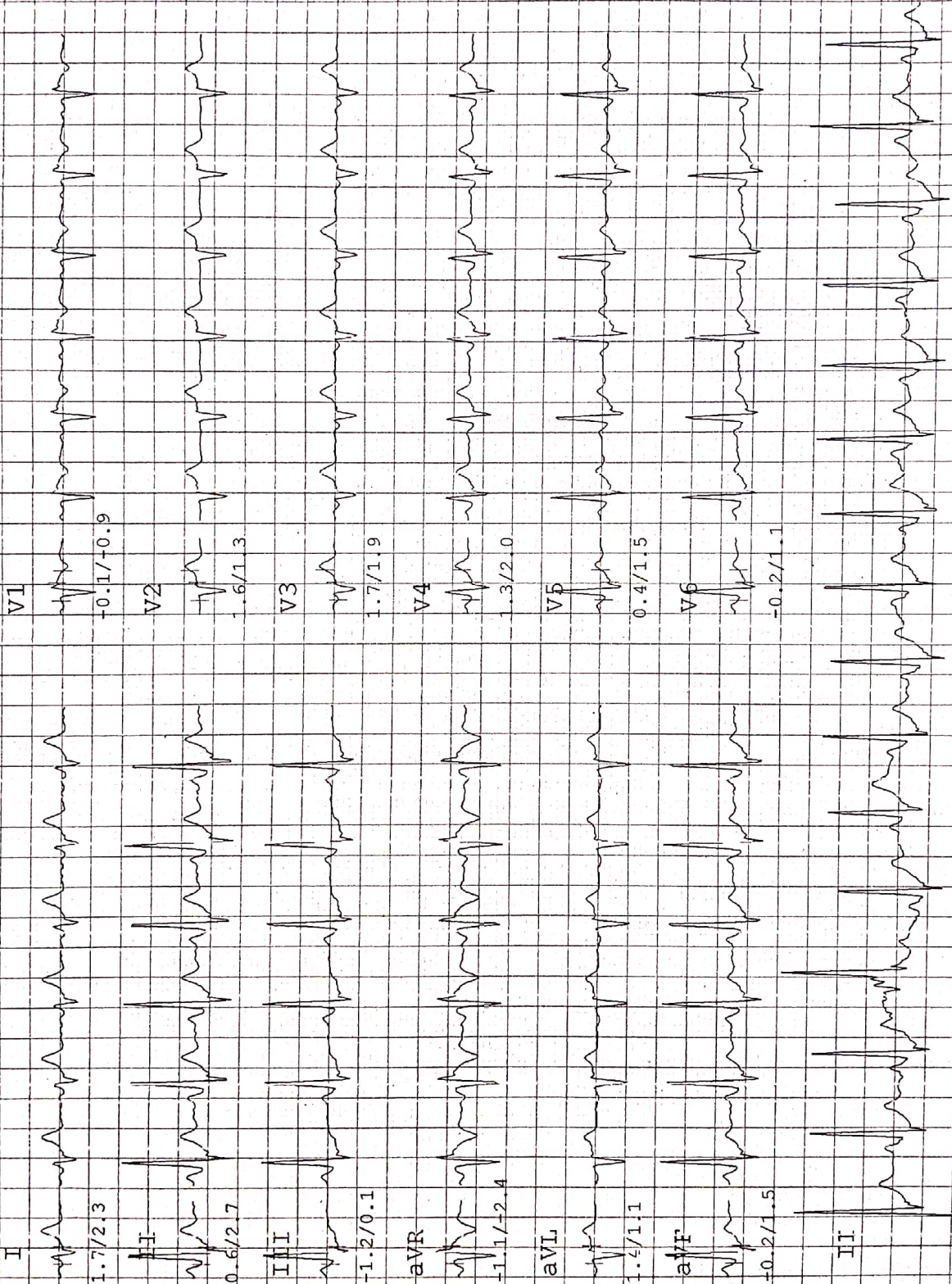


SHREEJI MULTISPECIALITY HOSPITAL

112/F TOWER A, SENATE SQUARE, VUDA CHOKDI, GOTRI

NAME : VENKATARATNAM GUNNA ID: 19 AGE/GENDER: 24/FEMALE BP: 140/ 90 mmHg DATE/TIME : 26/Jun/2021(09:29) HR: 114 bpm	PROTOCOL : Bruce STAGE NAME: Recovery STAGE TIME: 01:00 PostJ 80 Linked Median Report:
---	---

ST @ 10 mm/m7
STL in mm
STS in mm/sec




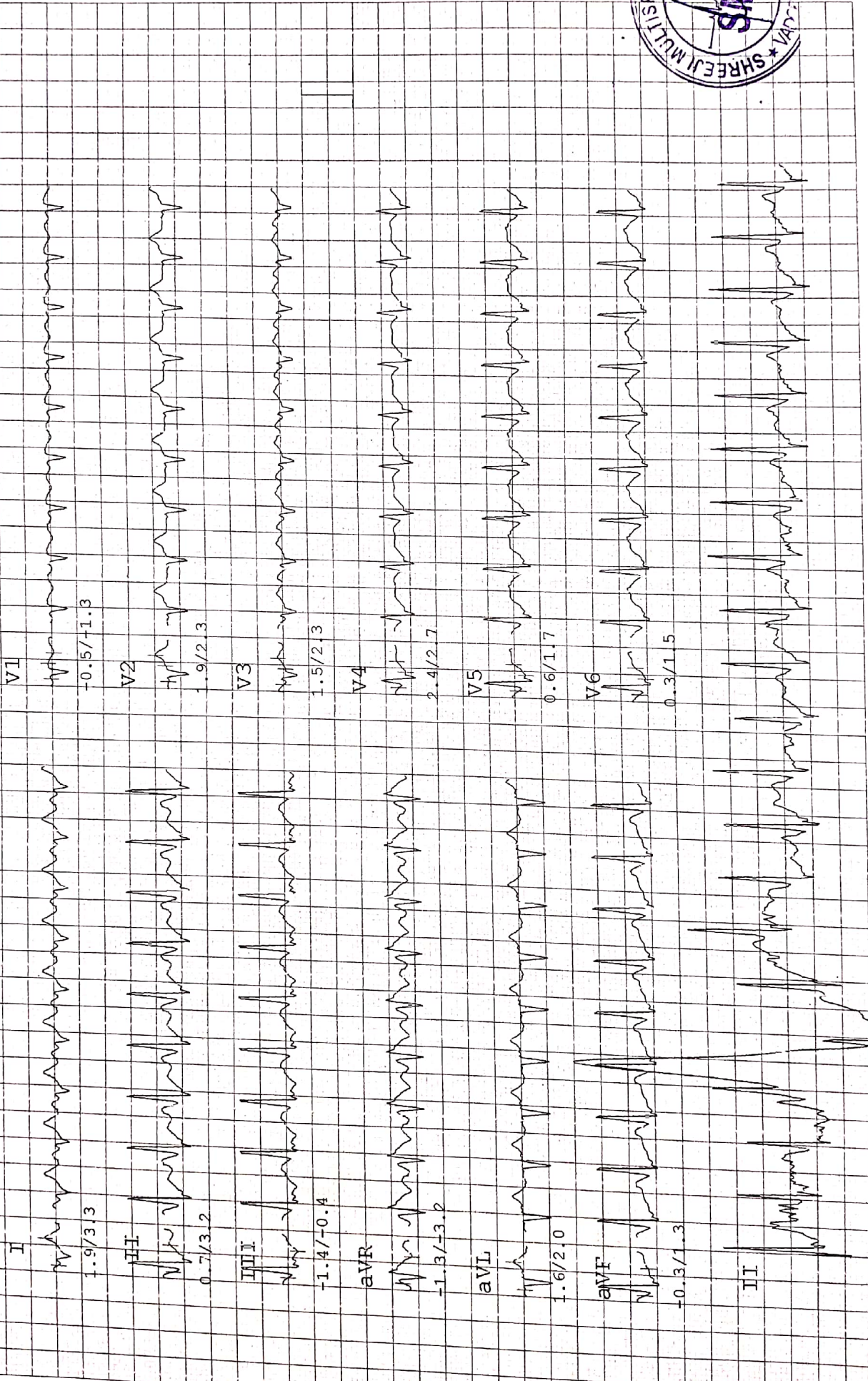
SHREEJI MULTISPECIALITY HOSPITAL

112/F TOWER A, SENATE SQUARE, VUDA CHOKDI, GOPRI

ST @ 10 mm/mV
STL in mm
STS in mm/set

PROTOCOL : Bruce
STAGE NAME: Peak
STAGE TIME: 00:06
PostJ 80

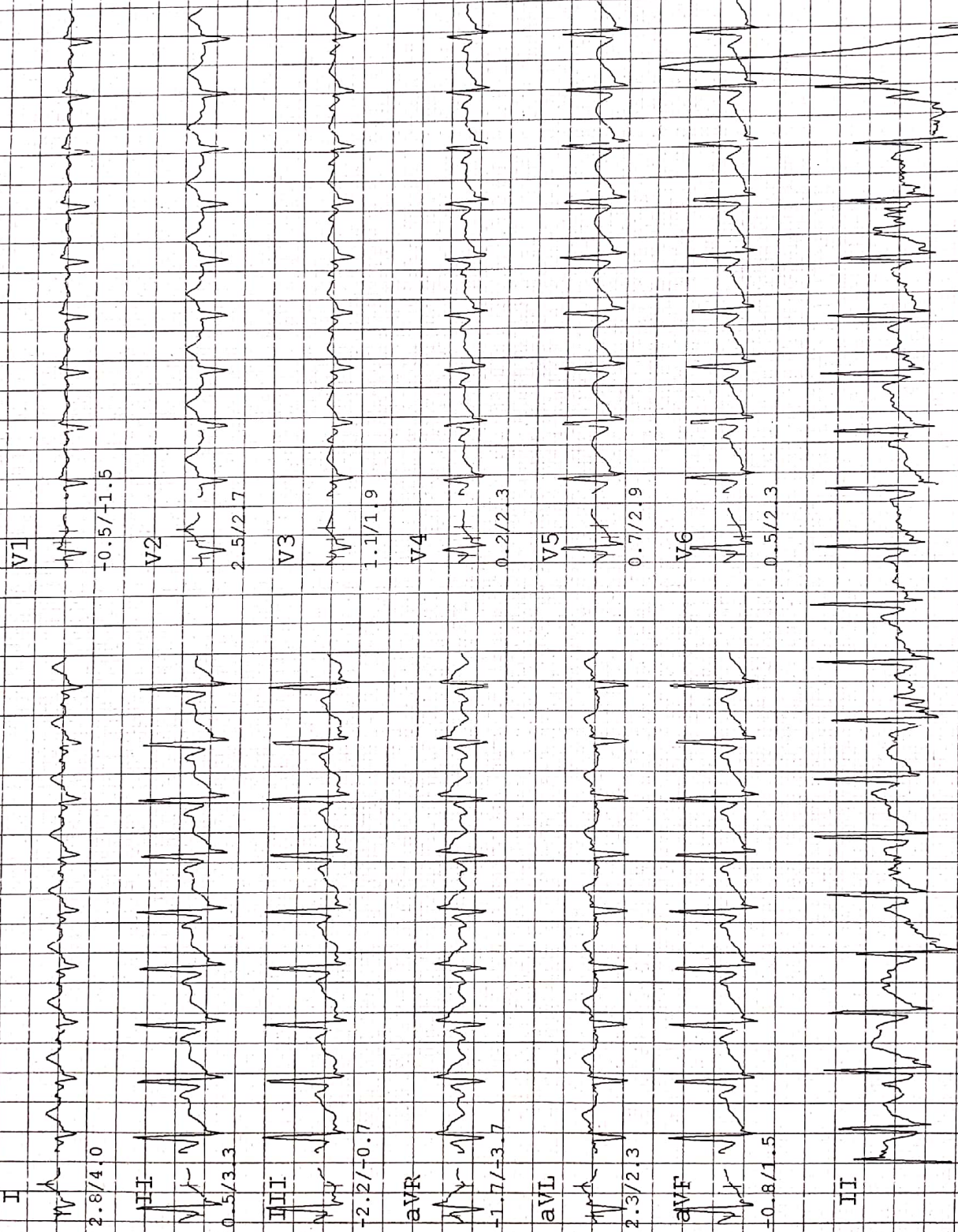NAME : VENKATARAMUNNA ID: 19
AGE/GENDER: 24/FEMALE BP: 160/110 mmHg
DATE/TIME: 26/Jun/2021(09:29) HR: 156 bpm



SHREEJI MULTISPECIALITY HOSPITAL

1-12/F TOWER A, SENATE SQUARE, WUDA CHOKDI, GOTRI

NAME : VENKATARATNAM GUNNA	ID: 19
AGE/GENDER: 24/FEMALE	BP: 160/110 mmHg
DATE/TIME: 26/Jun/2021(09:29)	HR: 159 bpm
PROTOCOL : Bruce STAGE NAME: Exer : 3/7 STAGE TIME: 01:54 PostJ 80	
ST @ 10 mm/mV STL in mm STS in mm/sec	

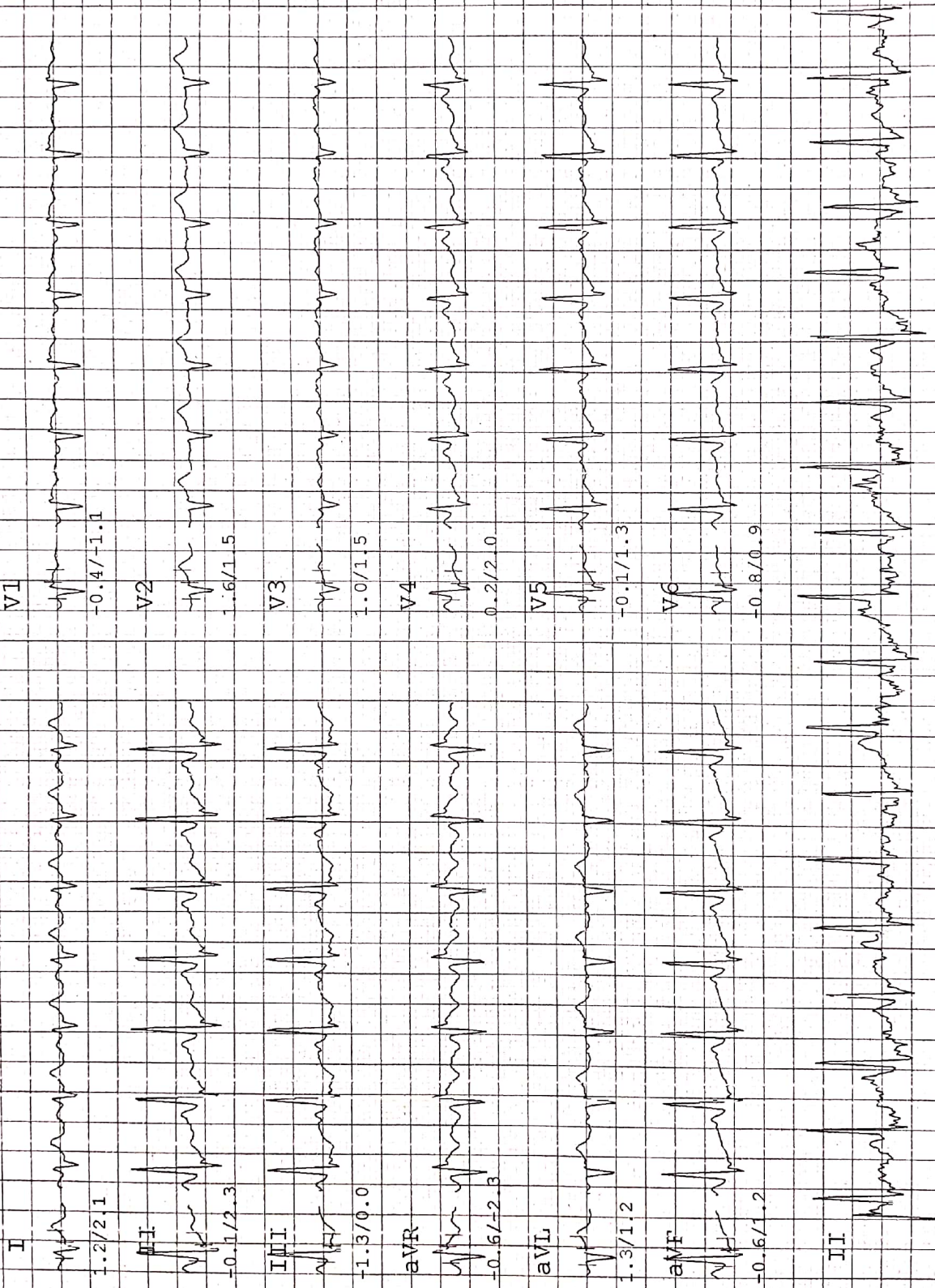


SHREEJI MULTISPECIALITY HOSPITAL

112/F TOWER A, SENATE SQUARE, VUDA CHOKDI, GOTRI

NAME : VENKATARATNAM GUNNA	ID: 19
AGE/SENDER: 24/FEMALE	BP: 150/100 mmHg
DATE/TIME : 26/Jun/2021(09:29)	HR: 129 bpm
PROTOCOL : Bruce	Linked Median Report:
STAGE NAME: Exer : 2/7	
STAGE TIME: 03:00	PostJ 80

ST @ 10 mm/mV
STL in mm
STS in mm/sec



SHREEJI MULTISPECIALITY HOSPITAL

112/F TOWER A, SENATE SQUARE, WUDA CHOKDI, GOTRI

ST @ 10 mm/mV
STL in mm
STS in mm/sec

PROTOCOL : Bruce Linked Median Report:

STAGE NAME: Exer : 1/7

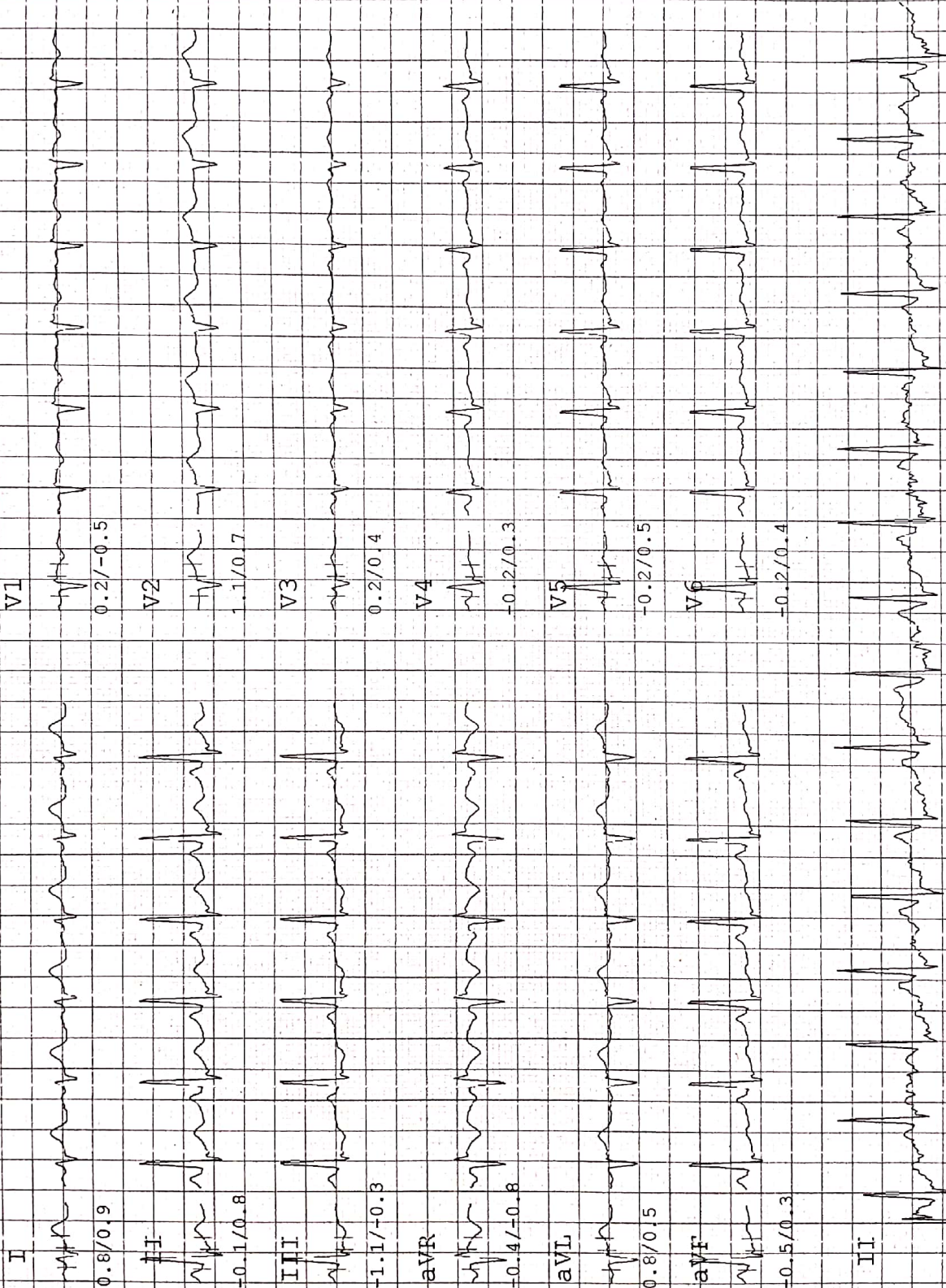
NAME : VENKATARATNAM GUNNA ID: 19

AGE/GENDER: 24/FEMALE BP: 140/ 90 mmHg

DATE/TIME : 26/Jun/2021(09:29) HR: 113 bpm

STAGE TIME: 03:00

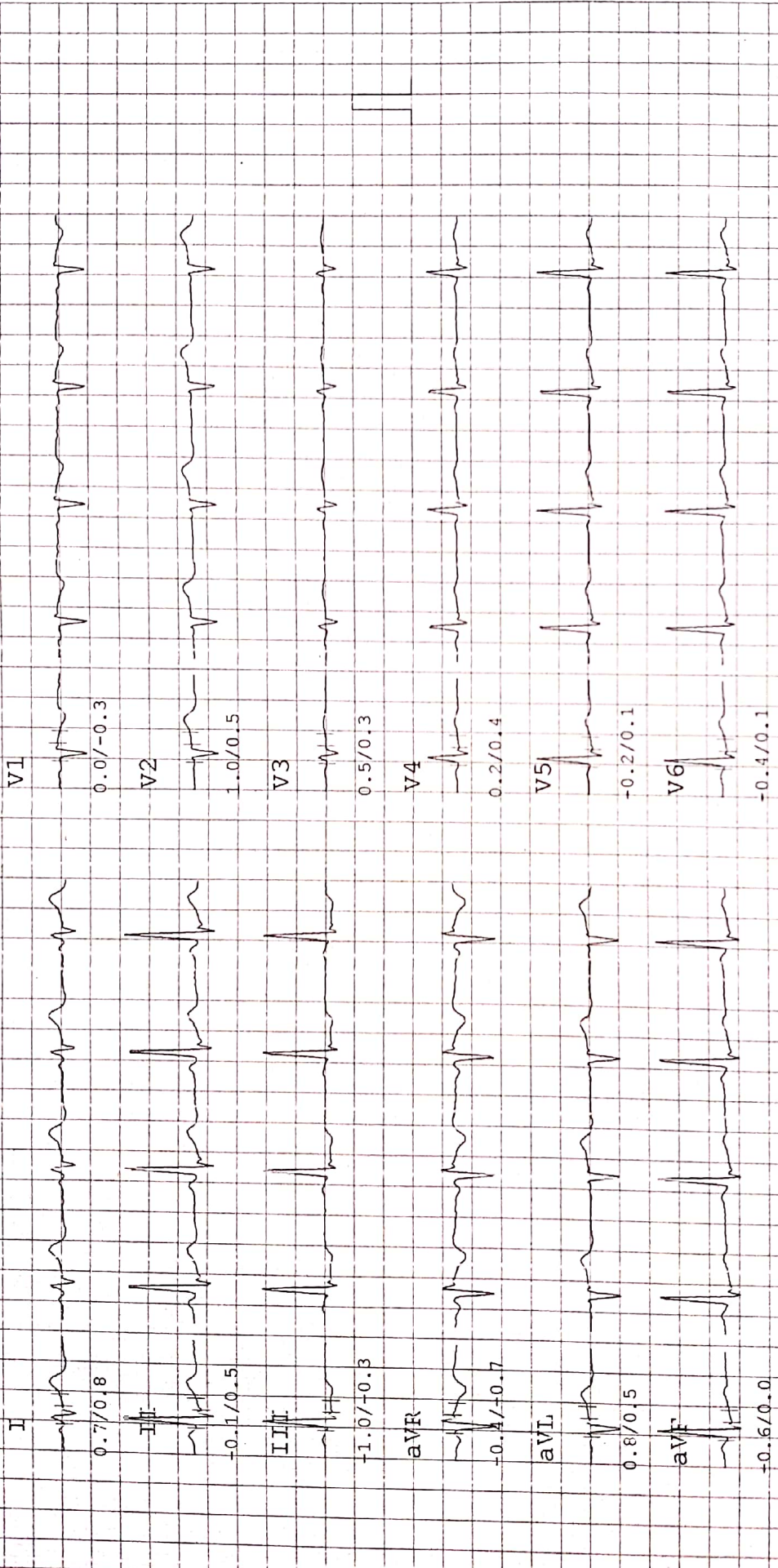
PostJ 80



SHREEJI MULTISPECIALTY HOSPITAL

112/F TOWER 'A', SENATE SQUARE, VUDA CHOKDI, GOTRI

NAME : VENKATARATNAM GUNNA ID: 19	ST @ 1.0 mm/mV
AGE/GENDER: 24/FEMALE	STL in mm
DATE/TIME : 26/Jun/2021(09:29)	STS in mm/set
BP: 126/ 84 mmHg	
HR: 77 bpm	
PROTOCOL : Bruce	Linked Median Report:
STAGE NAME: HyperV	
STAGE TIME: 00:18	
PostJ 80	

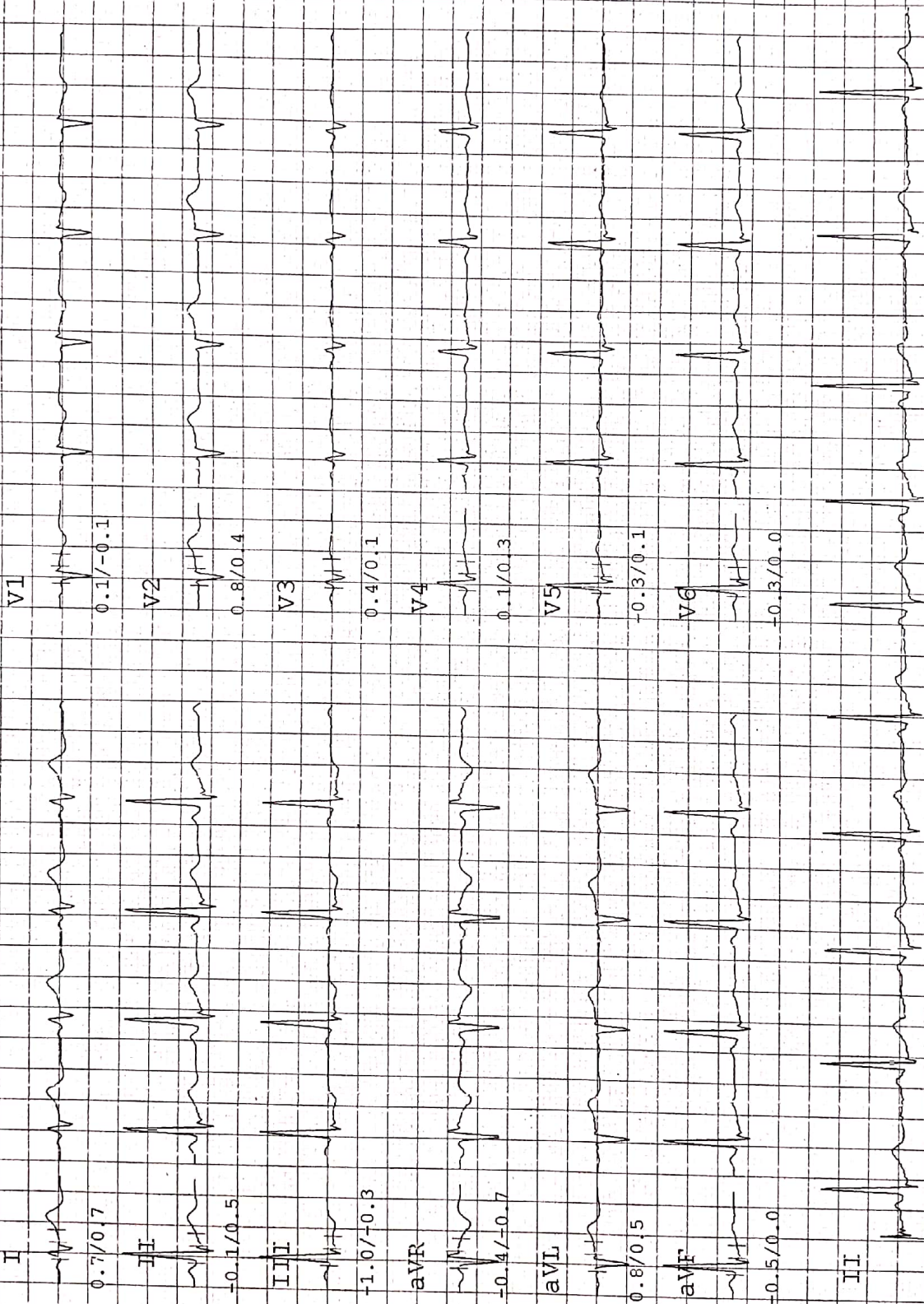


Dr. [Signature]
 Cardiologist
 Shreeji Multispecialty Hospital
 Vadodra

SHREEJI MULTISPECIALITY HOSPITAL

112/F TOWER A, SENATE SQUARE, VUDA CHOKDI, GOFRI

NAME : VENKATARATNAM GUNNI ID: 19	PROTOCOL : Bruce	ST @ 10 mm/mV
AGE/GENDER: 24/FEMALE	STAGE NAME: Standing	STL in mm
DATE/TIME : 26/Jun/2021(09:29)	STAGE TIME: 00:12	STS in mm/sec
	PostJ 80	



SHREEJI MULTISPECIALITY HOSPITAL


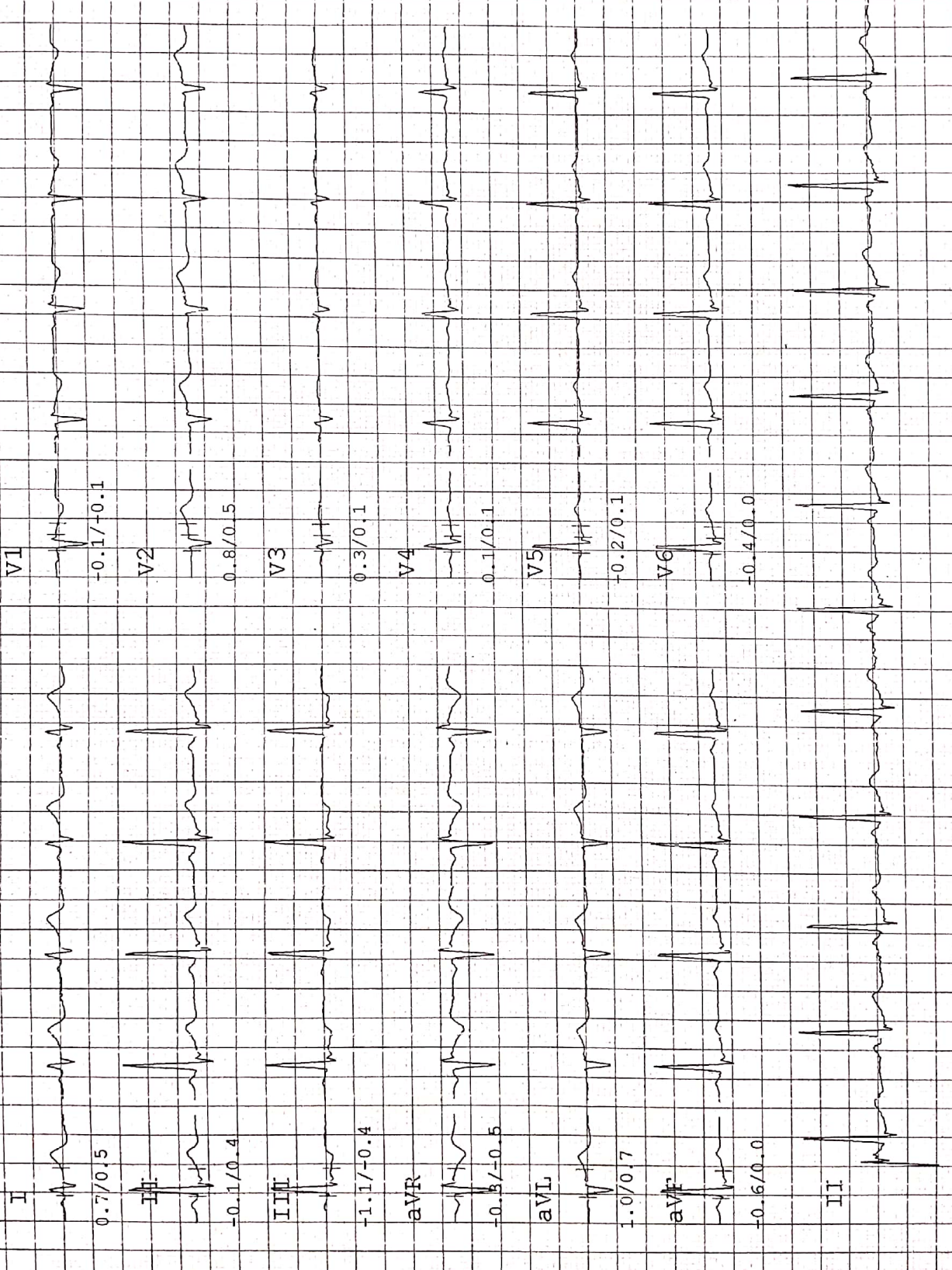
1-12/F TOWER A, SENATE SQUARE, VUDA CHOKDI, GOTRI

ST @ 10 mm/mV
STL in mm
STS in mm/sec

PROTOCOL : Bruce
STAGE NAME: Supine
STAGE TIME: 00:12
PostJ 80

NAME : YENKATPATNAM GUNNA ID: 19
AGE/GENDER: 24/FEMALE
DATE/TIME : 26/Jun/2021(09:29)
BP: 126/ 84 mmHg
HR: 79 bpm

Linked Median Report:





Shreeji Multispeciality Hospital

Inspiring better health...

SHREEJI OCCUPATIONAL CENTRE SHREEJI PATHOLOGY LABORATORY

112F, Tower-A, Senate Square, Opp. Gangotri Apartment, Vuda Char Rasta, Gotri, Vadodara-390021.
M. : 9157022510, Email : shreejihospital19@yahoo.com, smh31082015@gmail.com

Name : VENKATARATNAM GUNNA
Ref By : DR. SMH

Age/Sex : 24 Yrs./F
Date : 26/06/2021
Report ID. : 9

HAEMOGRAM PROFILE

TEST	RESULT	UNIT	METHOD	REFERENCE INTERVAL
<u>BLOOD COUNTS & INDICES</u>				
Haemoglobin	: 12.10	gm%		12.0 - 16.0 gm%
Total RBC	: 4.80	mill/cmm		4.2 - 5.4 mill/cmm
PCV	: 41.00	%		37 - 47 %
MCV	: 85.42	fL		80 - 96 fL
MCH	: 25.21	pg		27 - 31 pg
MCHC	: 29.51	%		32 - 36 %
Total WBC	: 6,200	/cmm		4,000 - 11,000/cmm
Platelet Count	: 2,42,000	/cmm		1.5 - 4.0 Lac/cmm.
<u>DIFFERENTIAL LEUCOCYTES COUNT</u>				
Band Cells	: 00	%		00 - 06 %
Neutrophils	: 58	%		55 - 70 %
Lymphocytes	: 30	%		20 - 40 %
Eosinophils	: 06	%		01 - 06 %
Monocytes	: 06	%		02 - 08 %
Basophils	: 00	%		00 - 01 %
Platelet In Smear	: ADEQUATE			
<u>ERYTHROCYTES SEDIMENTATION RATE</u>				
ESR After 1st Hour	: 3	mm	Westergren	03 - 12 mm
Blood Group	: "AB"			
Rh Factor (Anti D.)	: "POSITIVE"			

(By Fully Automated Cell Counter Sysmex KX-21, Japan)

END OF REPORT




DR VIMAL TAILOR (G41306)
DR YOGESH (G9892)
DR SHIVANI (MICROBIOLOGIST)



Shreeji Multispeciality Hospital

Inspiring better health...

Shreeji Occupational Centre Shreeji Pathology Laboratory

112F, Tower-A, Senate Square, Opp. Gangotri Apartment, Vuda Char rasta, Gotri, Vadodara-390021.

M. : 9157022510, Email : shreejihospital19@yahoo.com, smh31082015@gmail.com

Name : VENKATARATNAM GUNNA

Ref By : DR. SMH

Age/Sex : 24 Yrs./F

Date : 26/06/2021

Report ID. : 9

BIOCHEMISTRY

TEST	RESULT	UNIT	REFERENCE INTERVAL
Blood Urea Nitrogen - BUN	: 8.00	mg/dL	4.5 - 19.0 mg/dL
Serum Creatinine	: 0.90	mg/dL	0.6 - 1.4 mg/dL
Serum Uric Acid	: 4.20	mg/dL	2.4 - 5.7 mg/dL
SERUM PROTEIN			
Serum Protein Total	: 7.30	g/dL	6.6 - 8.3 g/dL
Albumin	: 5.00	g/dL	3.50 - 5.00 g/dL
Globulin	: 2.30	g/dL	2.3 - 3.5 g/dL
A/G Ratio	: 2.2	: 1	1.5 - 2.5 : 1
Billirubin - Total	: 0.3	mg/dL	0.00 - 1.00 mg/dL
Billirubin - Direct	: 0.1	mg/dL	Upto 0.30 mg/dL
Billirubin - Indirect	: 0.2	mg/dL	0.1 - 1.0 mg/dL
SGPT	: 23.0	IU/L	10 - 40 IU/L
SGOT	: 30.0	IU/L	Upto 40 IU/L
Serum Alkaline Phosphatase	: 100.0	U/L	37 - 147 U/L
FASTING (FBS)			
Blood Glucose	: 93.0	mg/dL	70.00 - 110.00 mg/dL
Urine Glucose	: NIL		
POST-PRANDIAL			
Blood Glucose	: 127.0	mg/dL	80 - 140 mg/dL
Urine Glucose	: NIL		
SPECIAL TESTS			
GGTP	: 21	U/L	05 - 85 U/L
Gamma Glutamyltransferase			

Done By Fully Auto Analyzer MIURA, A-1004

END OF REPORT




DR VIMAL TAILOR (G41306)
DR YOGESH (G9892)
DR SHIVANI (MICROBIOLOGIST)



SHREEJI Multispeciality Hospital

Inspiring better health...

SHREEJI OCCUPATIONAL CENTRE SHREEJI PATHOLOGY LABORATORY

112F, Tower-A, Senate Square, Opp. Gangotri Apartment, Vuda Char rasta, Gotri, Vadodara-390021.
M. : 9157022510, Email : shreejihospital19@yahoo.com, smh31082015@gmail.com

Name : VENKATARATNAM GUNNA
Ref By : DR. SMH

Age/Sex : 24 Yrs./F
Date : 26/06/2021
Report ID. : 9

EXAMINATION OF URINE

Sample : RANDOM

PHYSICAL EXAMINATION

Colour	: PALE YELLOW	Quantity	: 10	ml
Specific Gravit	: 1.030	Transparency	: CLEAR	
Deposits	: ABSENT	Reaction	: ACIDIC	

CHEMICAL EXAMINATION

Sugar	: NIL	Albumin	: NIL
Bile Salts	: ABSENT	Acetone	: ABSENT
Urobilinogen	: NORMAL : ~ < 1.0 mg/dL	Bile Pigments	: ABSENT
Nitrate	: ABSENT	Occult Blood	: ABSENT

MICROSCOPIC EXAMINATION

RBC	: NIL	Pus Cells	: 0-1 / hpf
Crystals	: NIL	Epithelial Cell	: NIL
		Amorphous Phosp	: NIL

THYROID FUNCTIONS

<u>TEST</u>	<u>RESULT</u>	<u>UNIT</u>	<u>REFERENCE INTERVAL</u>
Total Triiodothyronine - T3	: 1.00	ng/mL	0.58 - 1.59 ng/mL
Total Thyroxine - T4	: 9.50	ng/mL	4.87 - 11.72 microgram%
Thyroid Sti. Hormone -TSH	: 3.60	ng/mL	0.49 to 4.67 IU/mL

END OF REPORT



DR VIMAL TAILOR (G41306)
DR YOGESH (G9892)
DR SHIVANI (MICROBIOLOGIST)



Shreeji Multispeciality Hospital

Inspiring better health...

SHREEJI OCCUPATIONAL CENTRE SHREEJI PATHOLOGY LABORATORY

112F, Tower-A, Senate Square, Opp. Gangotri Apartment, Vuda Char Rasta, Gotri, Vadodara-390021.
M. : 9157022510, Email : shreejihospital19@yahoo.com, smh31082015@gmail.com

Name : VENKATARATNAM GUNNA
Ref By : DR. SMH

Age/Sex : 24 Yrs./F
Date : 26/06/2021
Report ID. : 9

LIPID PROFILE

TEST	RESULT	UNIT	REFERENCE INTERVAL
Total Lipid (Calculated)	: 486	mg/dL	350 - 750 mg/dL
Serum Cholesterol	: 161.0	mg/dL	130 - 200 mg/dL
Serum Triglyceride	: 95.0	mg/dL	60 - 165 mg/dL
HDL Cholesterol	: 48.0	mg/dL	30 - 70 mg/dL
LDL Cholesterol	: 94.0	mg/dL	Upto 150 mg/dL
CHOL./HDL Chol. Ratio	: 3.35	: 1	Less than 5
LDL Chol/HDL Chol Ratio	: 1.95	: 1	Less than 3.5
VLDL (Calculated)	: 19.00	mg/dL	Upto 30 mg/dL

Hb A1C REPORT

Hb A1C - Glycated Hb Glycated Haemoglobin	: 5.0	%	Non Diabetic : 4.3 - 6.3 % Good Control : 6.4 - 7.5 % Moderate Control : 7.5 - 9.0 % Poor Control : 9.0 % & Above
Avg. Blood Glucose Level	: 101	mg/dL	
Estimated Average Glucose eAG	: 97	mg%	

END OF REPORT



DR VIMAL TAILOR (G41306)
DR YOGESH (G9892)
DR SHIVANI (MICROBIOLOGIST)



SHREEJI Multispeciality Hospital

Inspiring better health...

SHREEJI OCCUPATIONAL CENTRE SHREEJI PATHOLOGY LABORATORY

112F, Tower-A, Senate Square, Opp. Gangotri Apartment, Vuda Char rasta, Gotri, Vadodara-390021.
M. : 9157022510, Email : shreejihospital19@yahoo.com, smh31082015@gmail.com

NAME : VENKATARATNAM GUNNA	AGE : 24 Y/F	DATE : 26/06/2021
----------------------------	--------------	-------------------

X RAY CHEST (PA)

OBSERVATIONS:

Both the lung fields and apices appear clear.

Both the hilar shadow appears normal.

Cardiac silhouette appears normal.

Both the costophrenic sinuses are clear.

Mediastinal and tracheal shadows are normal.

Both the domes of diaphragm are normal.

Visualized rib cage and clavicle are normal.

COMMENTS:

- No significant abnormality is seen.

Mehul Prajapati

DR. MEHUL PRAJAPATI
CONSULTANT RADIOLOGIST





SHREEJI Multispeciality Hospital

Inspiring better health...

SHREEJI OCCUPATIONAL CENTRE SHREEJI PATHOLOGY LABORATORY

112F, Tower-A, Senate Square, Opp. Gangotri Apartment, Vuda Char rasta, Gotri, Vadodara-390021.
M. : 9157022510, Email : shreejihospital19@yahoo.com, smh31082015@gmail.com

NAME : VENKATARATNAM GUNNA

AGE : 24 Y/F

DATE : 26/06/2021

ULTRASONOGRAPHY OF WHOLE ABDOMEN

(Screening Only)

Liver is normal in size and echotexture and shows normal parenchymal reflectivity. No focal lesion is seen. Hepatic veins appear normal. There is no evidence of any dilated intra hepatic biliary radicals.

Portal Vein appears normal in diameter.

Common Bile Duct is of normal diameter.

Gallbladder is physiologically distended with normal wall thickness. There is no evidence of gallstones. No evidence of peri-cholecystic fluid or probe tenderness.

Pancreas is normal in size and shows homogenous reflectivity. There is no evidence of any calcification or ductal dilatation.

Spleen is normal size and shows a homogenous echotexture. There is no evidence of any focal lesion.

Both Kidneys are normal in position and size. They show normal cortical reflectivity and cortico-medullary distinction. Right kidney measures 105x39mm. Left kidney measures 99x49mm. There is no evidence of renal calculi, hydronephrosis or mass seen.

Bladder is well distended and shows normal wall thickness. No evidence of intra-luminal mass or calculi.

Uterus appears normal in size- retroverted. Uterine myometrial echotexture is homogeneous. No focal lesion is seen. CT : 6 mm

Both Ovaries appears normal in size & reflectivity. No evidence of any adnexal mass.

There is no evidence of ascites.

No evidence of any gross bowel mass seen.

No evidence of any aorto-caval or mesenteric root lymphadenopathy.

No mass or collection in right iliac fossa.

CONCLUSION: No sonographic abnormality is seen.

Mehul Prajapati
DR. MEHUL PRAJAPATI
CONSULTANT RADIOLOGIST

