

**Health Check up Booking Confirmed Request(bobE27399),Package Code-
PKG10000249, Beneficiary Code-80033**

Mediwheel <wellness@mediwheel.in>

Wed 2/8/2023 6:02 AM

To: Info Sarjapur <info.sarjapur@narayanahealth.org>

Cc: mediwheelwellness@gmail.com <mediwheelwellness@gmail.com>

Attention: This email originated outside of Narayana Health domain. Links and attachments cannot be verified as authentic. Do not share personal/organisational data including passwords or act based on the content of the email, unless you have verified the authenticity of the sender and email address thoroughly.

011-41195959

Email:wellness@mediwheel.in

Hi **Narayana Multispeciality Clinic,**

Diagnostic/Hospital Location :**83/3 Doddakanneli,Sarjapur,Main Road , Near Wipro Gate-
560035, City:Bangalore**

We have received the confirmation for the following booking .

Beneficiary Name : PKG10000249

Beneficiary Name : Swapna Nair

Member Age : 36

Member Gender : Female

Member Relation : Employee

Package Name : Mediwheel Metro Full Body Health Checkup Female Below 40

Location : BANGALORE,Karnataka-NULL

Contact Details : 9482525823

Booking Date : 30-01-2023

Appointment Date : 11-02-2023

Instructions to undergo Health Check:

1. Please ensure you are on complete fasting for 10-To-12-Hours prior to check.
2. During fasting time do not take any kind of medication, alcohol, cigarettes, tobacco or any other liquids (except Water) in the morning.
3. Bring urine sample in a container if possible (containers are available at the Health Check centre).
4. Please bring all your medical prescriptions and previous health medical records with you.
5. Kindly inform the health check reception in case if you have a history of diabetes and cardiac problems.

For Women:

1. Pregnant Women or those suspecting are advised not to undergo any X-Ray test.
2. It is advisable not to undergo any Health Check during menstrual cycle.

We request you to facilitate the employee on priority.

Employee Name	Mu Swapna Nair
---------------	----------------

Employee ID	bob8E27399, 8r033
-------------	-------------------

Age	38 ym
-----	-------

Gender	female
--------	--------

Date	11/02/2023
------	------------

Name of center	NH SAKAPU
----------------	-----------

City	Bangalore
------	-----------

BASIC PARAMTERS:

Height (in mts)	160 CM
Weight (in Kgs)	71.3 kg
BMI	


Waist circumference (in cms)	83 CM
Hip circumference (in cms)	96 CM
Waist-to-hip ratio	

Systolic BP	100/
Diastolic BP	70

A.B.K



Package Details



Name : Ms Swapna Nair, 2010000023774, female, 38y
 Package Name : EHP Mediwheel Full Body Health checkup Below 40 Female
 Start Date : 11/02/2023 08:41 End Date : 12/02/2023 08:41
 Generated By: Bhuvaneshwari B C
 Generated On : 11-02-2023 08:41

Service Name	Ordered Date	Service Center	Consultant	Qty	Explicit
PAP SMEAR	11/02/2023 08:41 AM	CYTOLOGY	Dr. Sharma Vasant Kumar	1	No
CONSULTATION - FIRST VISIT	11/02/2023 08:41 AM	OPD-2F	Dr. Sharma Vasant Kumar	1	No
CONSULTATION - FIRST VISIT	11/02/2023 08:41 AM	OPD-2F	Dr. Dhivya Chandrasekar	1	No
USG ABDOMEN	11/02/2023 08:41 AM	ULTRA SOUND-2F	Dr. Sharma Vasant Kumar	1	No
ECHO COLOR DOPPLER	11/02/2023 08:41 AM	OPD-2F	Dr. Sharma Vasant Kumar	1	No
XRAY CHEST PA	11/02/2023 08:41 AM	X-RAY	Dr. Sharma Vasant Kumar	1	No
TREADMILL TEST	11/02/2023 08:41 AM	OPD-2F	Dr. Sharma Vasant Kumar	1	No
ECG	11/02/2023 08:41 AM	OPD-2F	Dr. Sharma Vasant Kumar	1	No
BLOOD UREA NITROGEN (BUN)	11/02/2023 08:41 AM	BIOCHEMISTRY	Dr. Sharma Vasant Kumar	1	No
URIC ACID	11/02/2023 08:41 AM	BIOCHEMISTRY	Dr. Sharma Vasant Kumar	1	No
LIVER FUNCTION TEST (LFT)	11/02/2023 08:41 AM	BIOCHEMISTRY	Dr. Sharma Vasant Kumar	1	No
SERUM CREATININE	11/02/2023 08:41 AM	BIOCHEMISTRY	Dr. Sharma Vasant Kumar	1	No
THYROID PROFILE (T3, T4, TSH)	11/02/2023 08:41 AM	BIOCHEMISTRY	Dr. Sharma Vasant Kumar	1	No
LIPID PROFILE (CHOL, TRIG, HDL, LDL, VLDL)	11/02/2023 08:41 AM	BIOCHEMISTRY	Dr. Sharma Vasant Kumar	1	No
HBA1C	11/02/2023 08:41 AM	BIOCHEMISTRY	Dr. Sharma Vasant Kumar	1	No
URINE FOR SUGAR (FASTING)	11/02/2023 08:41 AM	CLINICAL PATHOLOGY	Dr. Sharma Vasant Kumar	1	No
URINE FOR SUGAR (POST PRANDIAL)	11/02/2023 08:41 AM	CLINICAL PATHOLOGY	Dr. Sharma Vasant Kumar	1	No
FASTING BLOOD SUGAR (FBS)	11/02/2023 08:41 AM	BIOCHEMISTRY	Dr. Sharma Vasant Kumar	1	No
POST PRANDIAL BLOOD SUGAR (PPBS)	11/02/2023 08:41 AM	BIOCHEMISTRY	Dr. Sharma Vasant Kumar	1	No
BLOOD GROUP & RH TYPING	11/02/2023 08:41 AM	NARAYANA HRUDAYALAYA BLOOD CENTRE	Dr. Sharma Vasant Kumar	1	No
STOOL ROUTINE EXAMINATION	11/02/2023 08:41 AM	CLINICAL PATHOLOGY	Dr. Sharma Vasant Kumar	1	No
URINE ROUTINE & MICROSCOPY	11/02/2023 08:41 AM	CLINICAL PATHOLOGY	Dr. Sharma Vasant Kumar	1	No

Wt - 71.3 kg
 HT - 160 cm
 waist - 83 cm
 Hsp - 96 cm
 11/02/23



Handwritten signature: S.B.K



Service Name	Ordered Date	Service Center	Consultant	Qty	Explicit
COMPLETE BLOOD COUNT (CBC)	11/02/2023 08:41 AM	HEMATOLOGY	Dr. Sharma Vasant Kumar	1	No
ERYTHROCYTE SEDIMENTATION RATE (ESR)	11/02/2023 08:41 AM	HEMATOLOGY	Dr. Sharma Vasant Kumar	1	No



Handwritten signature: S. B. K.

11-02-2023 08:41

TRANS-THORACIC ECHO REPORT

Patient MRN : 20100000023774 Date : 11.02.2023
 Patient Name : Ms.SWAPNA NAIR Age/Gender : 38 yrs/Female

M-MODE / 2D MEASUREMENTS

LVEF (>55)% : 60%	LVID(d) (40-56)mm : 41mm	LVID (s) mm : 27mm
TAPSE (>16) mm : 20mm	IVS (d) (6-10)mm : 10mm	LV-EDV ml : --
LA (<39) mm : 26mm	PWD (d) (6-10)mm : 9mm	LV-ESV ml : --
RA (<44)mm : 29mm	RV (<35) mm : 25mm	BSA m ² :-

DOPPLER MEASUREMENTS

MITRAL VALVE : E/A - 0.6/0.5 M/S, NORMAL LV DIASTOLIC FUNCTION, MR-TRIVIAL
 AORTIC VALVE : PG -5 MMHG/AR-TRIVIAL
 TRICUSPID VALVE : TR -TRIVIAL
 PULMONARY VALVE : PG -2 MMHG
 PA PRESSURE : PASP-18 MMHG/ NORMAL PA PRESSURE.

FINDINGS

SITUS SOLITUS, LEVOCARDIA, AV AND VA CONCORDANT, NORMAL GREAT ARTERY RELATIONSHIP

VALVES

MITRAL : NORMAL
 AORTIC : NORMAL
 TRICUSPID : NORMAL
 PULMONARY : NORMAL

CHAMBERS

LV : NORMAL SIZED, NORMAL LV SYSTOLIC FUNCTION.
 RV : NORMAL SIZED, NORMAL RV FUNCTION.
 RWMA : NO RWMA
 LVOT : NORMAL
 LEFT ATRIUM : NORMAL SIZED
 RIGHT ATRIUM : NORMAL SIZED

SEPTAE

IVS : INTACT

IAS : INTACT

ARTERIES & VEINS

AORTA : AORTIC ANNULUS- 17 MM, ASCENDING AORTA- 26 MM,
NORMAL ARCH NORMAL SIZED.

PULMONARY ARTERY : NORMAL

IVC, SVC & CS : IVC – 12 MM, NORMAL SIZED, COLLAPSING, NORMAL RA PRESSURE.

PULMONARY VEINS : NORMAL

PERICARDIUM : NORMAL

VEGETATION / THROMBUS / TUMOR: NIL

OTHER FINDINGS:

SINUS RHYTHM-85 BPM
NO PREVIOUS ECHO REPORT

CONCLUSION

NORMAL CHAMBER DIMENSIONS
NORMAL PA PRESSURE
NO RWMA
NORMAL LV SYSTOLIC FUNCTION
LVEF:- 60%


CHANDANA V
CARDIAC SONOGRAPHER



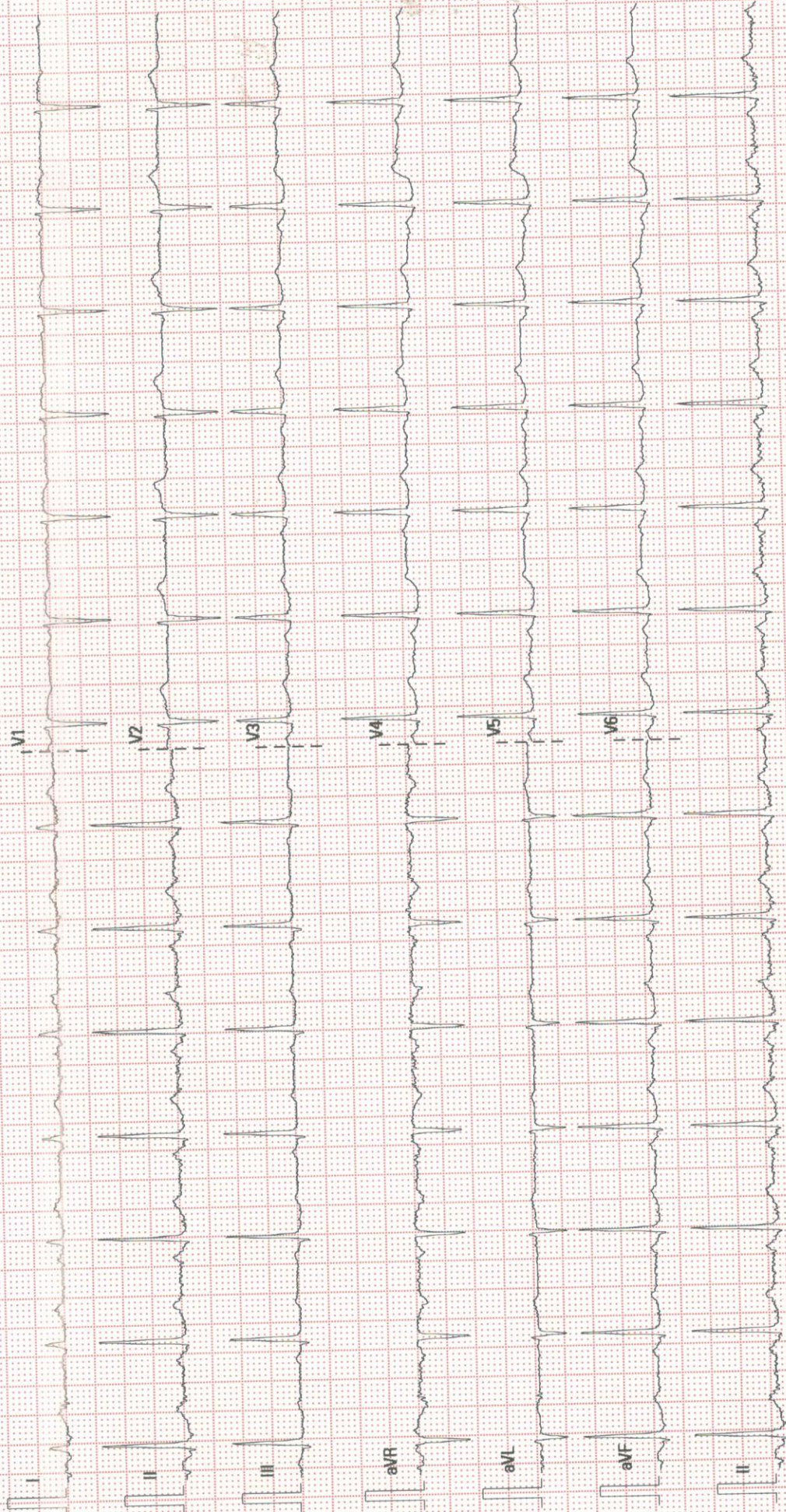
ID: 201-23774
Name: MRS. SWAPNA NAIR
Age: 38 Years
Gender: Female

11-02-2023 11:48:57

Vent. Rate 85 bpm
PR Interval 140 ms
QRS Duration 84 ms
QT/QTc Interval 356/400 ms
P/QRS/T Axis 60/77/52 deg
RV5/SV1 1.401/1.149 mV
RV5+SV1 2.550 mV
0Tc:Hodges

Sinus rhythm
Normal ECG

Unconfirmed Diagnosis



25 mm/s

10 mm/mV

50 Hz

BDR 35 Hz

NARAYANA MSC - SARJAPUR

02.04.00/V28.4.1

SN-FIN-58 003398

Patient Name : Mr. SWAPNA NAIR
Age : 38 Years
Referring Doctor : PKG

Patient ID : 201-23774
Sex : female
Date : 11.02.2023

ULTRASOUND ABDOMEN AND PELVIS

FINDINGS:

Liver is normal in size (14.3cm), and echopattern. No intra or extra hepatic biliary duct dilatation. No focal lesions.

Portal vein is normal in size, course and caliber. CBD is not dilated.

Gall bladder is normal without evidence of calculi, wall thickening or pericholecystic fluid.

Pancreas to the extent visualized, appears normal in size, contour and echogenicity.

Spleen is normal in size (7.4cm), shape, contour and echopattern. No evidence of mass or focal lesions.

Right Kidney is normal in size (measures 10.4 cm in length & 1.3 cm in parenchymal thickness), position, shape and echopattern. Corticomedullary differentiation is maintained. No evidence of calculi or hydronephrosis.

Left Kidney is normal in size (measures 10.4 cm in length & 1.4 cm in parenchymal thickness), position, shape and echopattern. Corticomedullary differentiation is maintained. No evidence of calculi or hydronephrosis.

Retroperitoneum – Obscured by bowel gas

Urinary Bladder is well distended. Wall thickness is normal. No evidence of calculi, mass or mural lesion.

Uterus is anteverted and normal in size, measures 7.8 X 4 X 6.2 cm. **diffusely altered Myometrium echo texture.** Endometrium measures –13.2 mm. Endometrial cavity is empty.

Both ovaries are normal in size and echopattern.

Right ovary: measures 2 X 1.3 cm. Left ovary: measures 2.8 X 2.1 cm.

Both adnexa: Normal. No mass is seen.

Fluid - There is no ascites or pleural effusion.

IMPRESSION:

- UNREMARKABLE STUDY OF ABDOMEN AND PELVIS.



Dr. Ananthalakshmi.S



Narayana Hrudayalaya Limited

Above HDFC Bank, 83/3, Doddakannelli, Sarjapura Main Road,
Varthur Hobli, Bangalore - 560035

Tel: + 91 88844 31319, Email: info.sarjapura@narayanahealth.org

Industrial Area, Ankal Taluk, Bangalore 560099

