

MEDICAL SUMMARY

NAME:	MR. MOHIT GUPTA	UHID:	22203
AGE:	36 yrs	Date of Health Check:	07/4/23
GENDER:	MALE	Date of Post Consultation:	
Height:	169 cm	Marital status:	Married
Weight:	76 kg	No. of Children:	

C/O: - Frequent bowel movements K/C/O: DM Type II

P/M/H: - Visual disturbance

Present Medication: - Tab. Metformin 0.3
- Tab. Zoster 20
- Tab. Glycomet XR 500


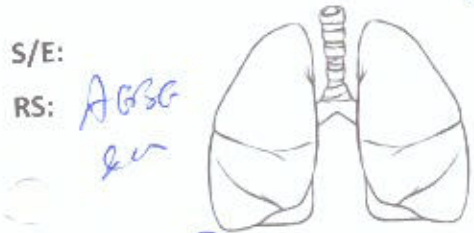
P/S/H: - nil

...A: Smoking - No
Alcohol - Yes
Tobacco/Pan - No

Family History: Father - Normal
Mother - HbC Ca.

O/E:
BP: 110/70 mmHg Pulse: 74/min
Temperature: Normal Scars: No
SpO2 - 98%

Lymphadenopathy:
Pallor/Icterus/Cynosis/Clubbing: Nil
Oedema:



CVS: S5S0
CNS: -

Extremities & Spine: -
ENT: -
Skin: -

Vision :

	Without Glass		With Glass	
	Right Eye	Left Eye	Right Eye	Left Eye
Far				
Near				
Colour Vision				
Advise				

Name	: Mr. Mohit Gupta	Gender	: Male	Age	: 36 Years
UHID	: AM10.221208	Bill No	: ACR128811	Lab No:	A-746-12
Ref. by	: SELF	Sample Col.Dt	: 07/04/2023 09:40		
Barcode No	: 1731	Reported On	: 07/04/2023 14:27		

TEST	RESULTS	BIOLOGICAL REFERENCE INTERVAL
------	---------	-------------------------------

HAEMOGRAM(CBC,ESR,P/S)-WB (EDTA)

Haemoglobin(Colorimetric method)	12.1	g/dl	13 - 18
RBC Count (Impedance)	6.29	Millions/cumm.	4 - 6.2
PCV/Haematocrit(Calculated)	39.6	%	35 - 55
MCV:(Calculated)	63	fl	78 - 98
MCH:(Calculated)	19.3	pg	26 - 34
MCHC:(Calculated)	30.6	gm/dl	30 - 36
RDW-CV:	18.1	%	11.5 - 16.5
Total Leucocyte count(Impedance)	7040	/cumm.	4000 - 10500
Neutrophils:	51	%	40 - 75
Lymphocytes:	39	%	20 - 40
Eosinophils:	05	%	0 - 6
Monocytes:	05	%	2 - 10
Basophils:	00	%	0 - 2
Platelets Count(Impedance method)	2.34	Lakhs/c.mm	1.5 - 4.5
MPV	10.1	fl	6.0 - 11.0
ESR(Westergren Method)	05	mm/1st hr	0 - 20
Peripheral Smear (Microscopic examination)			
RBCs:	Hypochromasia(++),Microcytosis(++),Anisocytosis(+)		
WBCs:	Normal		
Platelets	Adequate		
Note:	Test Run on 5 part cell counter. Manual diff performed.		

Sushant Gaikwad
 Entered By

Ms Kaveri Gaonkar
 Verified By



Dr. Milind Patwardhan
 M.D(Path)
 Chief Pathologist

End of Report
 Results are to be correlated clinically



Indira Health And Lifestyle Private Limited.

NABL Accredited Laboratory

"Xtrium", Ground Floor, Next to Holy Family Church,
Andheri - Kurla Road, Chakala, Andheri (East), Mumbai - 400 093.

Tel.: +91 22 46105555, Mob.: 98200 87235

E: andherieast@apolloclinic.com

Apollo Clinic
Expertise. Closer to you.
Andheri

Name	: Mr. Mohit Gupta	Gender	: Male	Age	: 36 Years
UHID	: AM10.221208	Bill No	: ACR128811	Lab No:	A-746-12
Ref. by	: SELF	Sample Col.Dt	: 07/04/2023 09:40		
Barcode No	: 1731	Reported On	: 07/04/2023 16:02		

TEST

RESULTS

Blood Grouping (ABO & Rh)-WB(EDTA) Serum

ABO Group:

:B:

Rh Type:

Positive

Method :

Tube Agglutination (forward and reverse)

Alsaba Shaikh
Entered By

Ms Kaveri Gaonkar
Verified By

Dr. Milind Patwardhan
M.D(Path)
Chief Pathologist

End of Report
Results are to be correlated clinically

Card Name: Matrix octoplus Complete Grouping Card

Test Name: Complete Grouping (A-B-D+A1-B-O)

Card Barcode: 2828623012312000445

Card Lot No: 01

Date: 07/04/2023

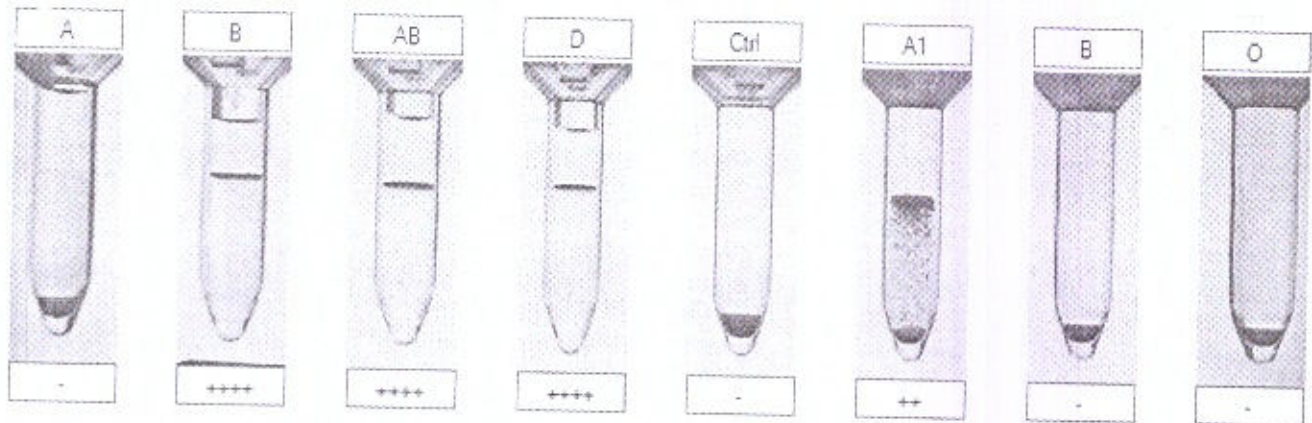
Time: 12:49 PM

Card Expiry: 12/2023

Patient's ID: 1731

Donors Unit No:

Patient's Name: MOHIT GUPTA



Result Interpretation: Group: B, Rh: Positive

Remarks:

User ID: USER

Authorized By:

Date: 07/04/2023



Indira Health And Lifestyle Private Limited.
NABL Accredited Laboratory
"Xtrium", Ground Floor, Next to Holy Family Church,
Andheri - Kurla Road, Chakala, Andheri (East), Mumbai - 400 093.
Tel.: +91 22 46105555, Mob.: 98200 87235
E: andherieast@apolloclinic.com

Apollo Clinic
Expertise. Closer to you.
Andheri

Name : Mr. Mohit Gupta Gender : Male Age : 36 Years
UHID : AM10.221208 Bill No : ACR128811 Lab No: A-746-12
Ref. by : SELF Sample Col.Dt : 07/04/2023 09:40
Barcode No : 1731 Reported On : 07/04/2023 16:01

TEST	RESULTS	UNITS	BIOLOGICAL REFERENCE INTERVAL
PLASMA GLUCOSE			
Fasting Plasma Glucose :	168	mg/dL	Normal < 100 mg/dL Impaired Fasting glucose : 101 to 125 mg/dL Diabetes Mellitus : \geq 126 mg/dL (on more than one occasion) (American diabetes association guidelines 2016)
Post Prandial Plasma Glucose :	260	mg/dL	Normal < 140 mg/dL Impaired Post Prandial glucose : 140 to 199 mg/dL Diabetes Mellitus : \geq 200 mg/dL (on more than one occasion) (American diabetes association guidelines 2016)

Method : Hexokinase

Vasanti Gondal
Entered By

Ms Kaveri Gaonkar
Verified By


Dr. Milind Patwardhan
M.D(Path)
Chief Pathologist

End of Report
Results are to be correlated clinically



Indira Health And Lifestyle Private Limited.
NABL Accredited Laboratory
"Xtrium", Ground Floor, Next to Holy Family Church,
Andheri - Kurla Road, Chakala, Andheri (East), Mumbai - 400 093.
Tel.: +91 22 46105555, Mob.: 98200 87235
E: andherieast@apolloclinic.com

Apollo Clinic
Expertise. Closer to you.
Andheri

Name : Mr. Mohit Gupta Gender : Male Age : 36 Years
UHID : AM10.221208 Bill No : ACR128811 Lab No: A-746-12
Ref. by : SELF Sample Col.Dt : 07/04/2023 09:40
Barcode No : 1731 Reported On : 07/04/2023 13:15

TEST RESULTS UNITS BIOLOGICAL REFERENCE INTERVAL

Lipid Profile- Serum

S. Cholesterol(Oxidase)	154	mg/dL	Desirable < 200 Borderline:>200-<240 Undesirable:>240
S. Triglyceride(GPO-POD)	161	mg/dL	Desirable < 150 Borderline:>150-<499 Undesirable:>500
S. VLDL:(Calculated)	32.2	mg/dL	Desirable <30
S. HDL-Cholesterol(Direct)	32.0	mg/dL	Desirable > 60 Borderline:>40-<59 Undesirable:<40
S. LDL:(calculated)	89.8	mg/dL	Desirable < 130 Borderline:>130-<159 Undesirable:>160
Ratio Cholesterol/HDL	4.8		3.5 - 5
Ratio of LDL/HDL	2.8		2.5 - 3.5

Vasanti Gondal
Entered By

Ms Kaveri Gaonkar
Verified By

Dr. Milind Patwardhan
M.D(Path)
Chief Pathologist

End of Report
Results are to be correlated clinically

Name : Mr. Mohit Gupta Gender : Male Age : 36 Years
UHID : AM10.221208 Bill No : ACR128811 Lab No: A-746-12
Ref. by : SELF Sample Col.Dt : 07/04/2023 09:40
Barcode No : 1731 Reported On : 07/04/2023 13:15

TEST RESULTS UNITS BIOLOGICAL REFERENCE INTERVAL

LFT(Liver Function Tests)-Serum

S.Total Protein (Biuret method)	7.42	g/dL	6.6 - 8.7
S.Albumin (BCG method)	4.77	g/dL	3.5 - 5.2
S.Globulin (Calculated)	2.65	g/dL	2 - 3.5
S.A/G Ratio:(Calculated)	1.8		0.9 - 2
S.Total Bilirubin (DPD):	1.17	mg/dL	0.1 - 1.2
S.Direct Bilirubin (DPD):	0.39	mg/dL	0.1 - 0.3
S.Indirect Bilirubin (Calculated)	0.78	mg/dL	0.1 - 1.0
S.AST (SGOT)(IFCC Kinetic with P5P):	22	U/L	5 - 40
S.ALT (SGPT) (IFCC Kinetic with P5P):	28	U/L	5 - 41
S.Alk Phosphatase(pNPP-AMP Kinetic):	73	U/L	40 - 129
S.GGT(IFCC Kinetic):	35	U/L	11 - 50

Vasanti Gondal
Entered By

Ms Kaveri Gaonkar
Verified By



Dr. Milind Patwardhan
M.D(Path)
Chief Pathologist

End of Report
Results are to be correlated clinically

Name : Mr. Mohit Gupta Gender : Male Age : 36 Years
 UHID : AM10.221208 Bill No : ACR128811 Lab No: A-746-12
 Ref. by : SELF Sample Col.Dt : 07/04/2023 09:40
 Barcode No : 1731 Reported On : 07/04/2023 13:15

TEST	RESULTS	UNITS	BIOLOGICAL REFERENCE INTERVAL
RFT - Renal Profile-serum			
S.Urea(Urease-GLDH)	17.6	mg/dL	10.0 - 45.0
S. Urea Nitrogen(Calculated)	8.21	mg/dL	5 - 20
S.Creatinine(Jaffe's Kinetic)	0.90	mg/dL	0.50 - 1.3
S.Uric Acid(Uricase-POD)	6.9	mg/dL	3.4 - 7.0
S.Total Protein(Biuret)	7.42	g/dL	6.6 - 8.7
S.Albumin(BCG)	4.77	g/dL	3.5 - 5.2
S.Globulin(Calculated)	2.65	g/dL	2 - 3.5
A/G Ratio(Calculated)	1.8		0.9 - 2
S.Sodium(Na) (ISE-Direct)	139	mmol/L	135 - 145
S.Potassium(K) (ISE-Direct)	5.1	mmol/L	3.5 - 5.3
S.Chloride(Cl) (ISE-Direct)	103	mmol/L	95 - 106
S.Calcium(NM-BAPTA)	9.28	mg/dL	8.6 - 10.0
S.Phosphorus(UV Phosphomolybdate)	2.96	mg/dL	2.5 - 4.5

Vasanti Gondal
Entered By

Ms Kaveri Gaonkar
Verified By



Dr. Milind Patwardhan
M.D(Path)
Chief Pathologist

End of Report
Results are to be correlated clinically

Name : Mr. Mohit Gupta Gender : Male Age : 36 Years
UHID : AM10.221208 Bill No : ACR128811 Lab No: A-746-12
Ref. by : SELF Sample Col.Dt : 07/04/2023 09:40
Barcode No : 1731 Reported On : 07/04/2023 13:15

TEST	RESULTS	UNITS	BIOLOGICAL REFERENCE INTERVAL
Thyroid (T3,T4,TSH)- Serum			
Total T3 (Tri-iodo Thyronine) (ECLIA)	1.97	nmol/L	1.3 - 3.1 nmol/L
Total T4 (Thyroxine) (ECLIA)	98.11	nmol/L	66 - 181 nmol/L
TSH-Ultrasensitive (Thyroid-stimulating hormone) Method : ECLIA	4.82	μIU/ml	Euthyroid : 0.35 - 5.50 μIU/ml Hyperthyroid : < 0.35 μIU/ml Hypothyroid : > 5.50 μIU/ml

Grey zone values observed in physiological/therapeutic effect.

Note:

T3 :

1. Decreased values of T3 (T4 and TSH normal) have minimal Clinical significance and not recommended for diagnosis of hypothyroidism.
2. Total T3 and T4 values may also be altered in other conditions due to changes in serum proteins or binding sites ,Pregnancy, Drugs (Androgens,Estrogens,O C pills, Phenytoin) etc. In such cases Free T3 and free T4 give corrected Values.
3. Total T3 may decrease by < 25 percent in healthy older individuals

T4 :

1. Total T3 and T4 Values may also be altered in other condition due to changes in serum proteins or binding sites, Pregnancy Drugs (Androgens,Estrogens,O C pills, Phenytoin), Nerphrosis etc. In such cases Free T3 and Free T4 give Corrected values.

TSH :

1. TSH Values may be transiently altered because of non thyroidal illness like severe infections,liver disease, renal and heart failure. Severe burns, trauma and surgery etc.
2. Drugs that decrease TSH values e,g L dopa, Glucocorticoids.
3. Drugs that increase TSH values e.g. Iodine,Lithium, Amiodarone

Vasanti Gondal
Entered By

Ms Kaveri Gaonkar
Verified By



Dr. Milind Patwardhan
M.D(Path)
Chief Pathologist

End of Report
Results are to be correlated clinically

Name	: Mr. Mohit Gupta	Gender	: Male	Age	: 36 Years
UHID	: AM10.221208	Bill No	: ACR128811	Lab No:	A-746-12
Ref. by	: SELF	Sample Col.Dt	: 07/04/2023 09:40		
Barcode No	: 1731	Reported On	: 07/04/2023 16:02		

TEST	RESULTS	BIOLOGICAL REFERENCE INTERVAL
------	---------	-------------------------------

URINE REPORT

PHYSICAL EXAMINATION

QUANTITY	20	mL	
COLOUR	Pale Yellow		
APPEARANCE	Clear		Clear
SEDIMENT	Absent		Absent

CHEMICAL EXAMINATION(Strip Method)

REACTION(PH)	5.0		4.6 - 8.0
SPECIFIC GRAVITY	1.020		1.005 - 1.030
URINE ALBUMIN	Absent		Absent
URINE SUGAR(Qualitative)	Trace		Absent
KETONES	Absent		Absent
BILE SALTS	Absent		Absent
BILE PIGMENTS	Absent		Absent
UROBILINOGEN	Normal(<1 mg/dl)		Normal
OCCULT BLOOD	Absent		Absent
Nitrites	Absent		Absent

MICROSCOPIC EXAMINATION

PUS CELLS	1 - 2/hpf		0 - 3/hpf
RED BLOOD CELLS	Nil /HPF		Absent
EPITHELIAL CELLS	2 - 3 /hpf		3 - 4/hpf
CASTS	Absent		Absent
CRYSTALS	Absent		Absent
BACTERIA	Absent		Absent

Anushka Chavan
 Entered By

Ms Kaveri Gaonkar
 Verified By



Dr. Milind Patwardhan
 M.D(Path)
 Chief Pathologist

End of Report
 Results are to be correlated clinically

36 Year

Male

Location:
Room:
Order Number:
Indication:
Medication 1:
Medication 2:
Medication 3:

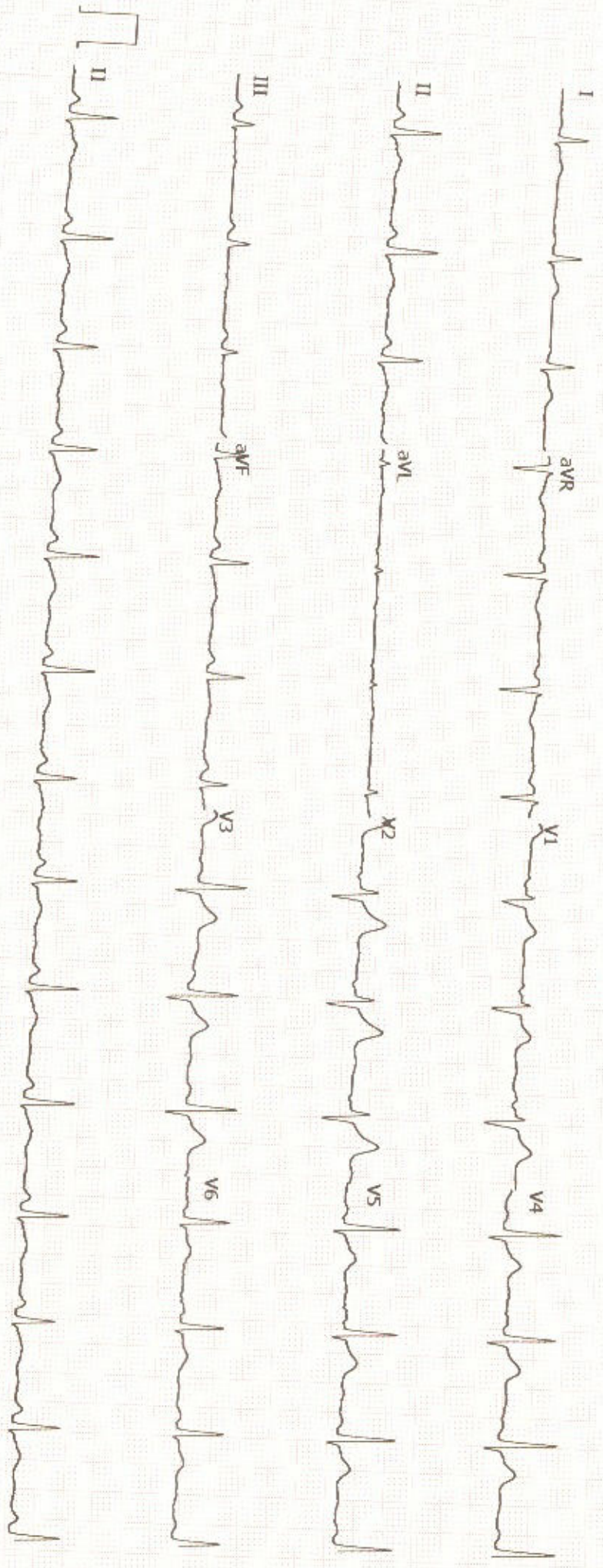
81 bpm
--/-- mmHg

QRS : 78 ms
QT / QTcBaz : 338 / 392 ms
PR : 142 ms
P : 106 ms
RR / PP : 740 / 740 ms
P / QRS / T : 75 / 56 / 54 degrees

Normal sinus rhythm
Normal ECG

Technician:
Ordering Ph:
Referring Ph:
Attending Ph:

Dr DINESH ROHIRA
Echo cardiologist
DNB (Internal Medicine)
Reg No. 2009604/0837



GE MAC2000 1.1 12SL™ V241

25 mm/s 10 mm/mV

ADS 0.56-20 Hz 50 Hz 4x2.5x3 25 R1

Unconfirmed

Name : Mr Mohit Gupta

Gender : Male

Age : 36 Years

UHID : AM10.0000221208

Bill No : ACR128811 Lab No :

Ref. by : Self

Date : 07-Apr-2023 Time : 02:04 PM

Echo (Color Doppler)

DIMENSIONS	VALUES (RANGE)	DIMENSIONS	VALUES (RANGE)
AO (ed)	26mm	IVS (ed)	9mm
LA (es)	32mm	LVPW (ed)	9mm
RVID (ed)	21mm	EF	60%
LVID (ed)	45mm	EPSS	4mm
LVID (es)	26mm		

MORPHOLOGICAL DATA

Mitral Valve

AML Normal

PML Normal

Aortic Valve Normal

Tricuspid Valve Normal

Pulmonary Valve Normal

Right Ventricle Normal

Left ventricle Normal

Interatrial Septum Intact

Interventricular Septum Intact

Pulmonary Artery Normal

Aorta Normal

Name : Mr Mohit Gupta

Gender : Male Age : 36

UHID : AM10.0000221208

Bill No : ACR128811 Lab No :

Ref. by : Self

Date : 07-Apr-2023 Time : 02:04 PM

Right Atrium Normal

Left Atrium Normal


LV - RWMA Normal

LV - FUNCTION Normal

Pericardium Normal

Doppler Studies Normal

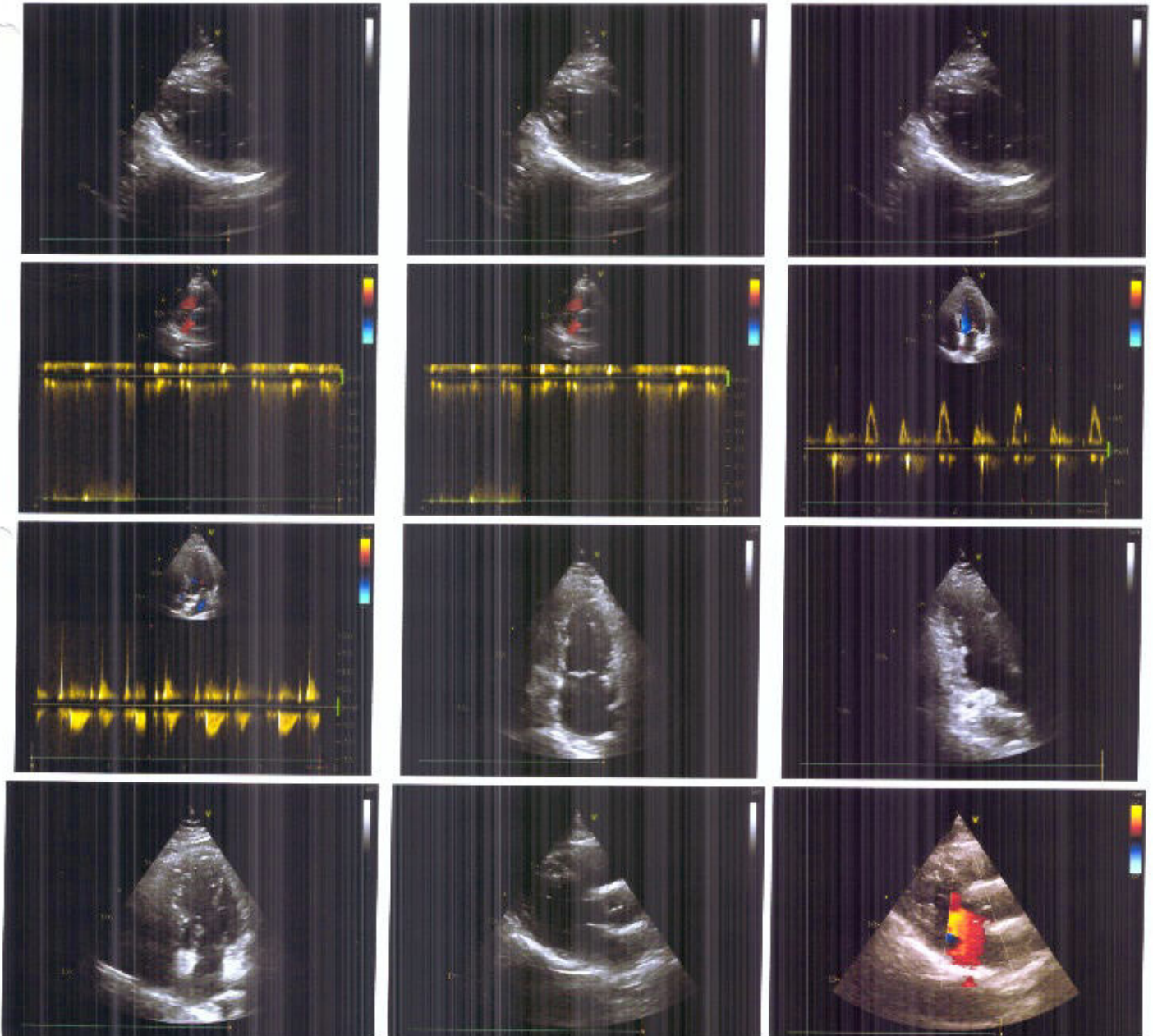
IMPRESSION : Normal LV and RV Systolic Function LVEF=60%


Dr. Ameya Tirodkar
DNB-Medicine

Apollo Clinic
Xtrim Ground Floor, Next to Holy Family Church,
Andheri (E).

Patient ID: 2023Ap0031
Name: MOHIT GUPTA
Sex: M

Date: 07-Apr-2023



Ultrasound

Name : Mr Mohit Gupta Gender : Male Age : 36 Years
UHID : AM10.0000221208 Bill No : ACR128811 Lab No :
Ref. by : Self Date : 07-Apr-2023 Time : 12:55 PM

Ultrasound Whole Abdomen (Male)

LIVER : Liver is normal in size and **shows fatty infiltration** . No focal intra-hepatic lesion detected. Intra-hepatic biliary radicals are not dilated. Portal vein and CBD appear normal in calibre.

GALL BLADDER : Physiologically well distended Gall bladder is seen with normal wall thickness. No evidence of any calculus or abnormal mass lesion seen.

PANCREAS : Pancreas is normal in size and echotexture.

SPLEEN : Spleen is normal in size & echotexture.

Aorta and IVC appear normal in course and calibre.

KIDNEYS : Both Kidneys are normal in size, position, have smooth outlines and show a uniform parenchymal echogenicity. The cortico-medullary ratio is well maintained. There is no evidence of any Pelvi-calyceal dilatation seen on either side. No abnormal focal mass lesions seen.

A non obstructing calculus measuring 3 mm is noted in the mid pole calyx of the left kidney.
RK -10.8 x 4.8 cms Lk - 10.7 x 5.6 cms

The Urinary Bladder is well distended. Its walls show a smooth outline . There is no evidence of any intraluminal or perivesical abnormality.

PROSTATE : Prostate is normal in size and echo-texture. . No focal lesion seen.

No free fluid or lymphadenopathy seen.

IMPRESSION :
Grade II fatty liver.
Left renal calculus.

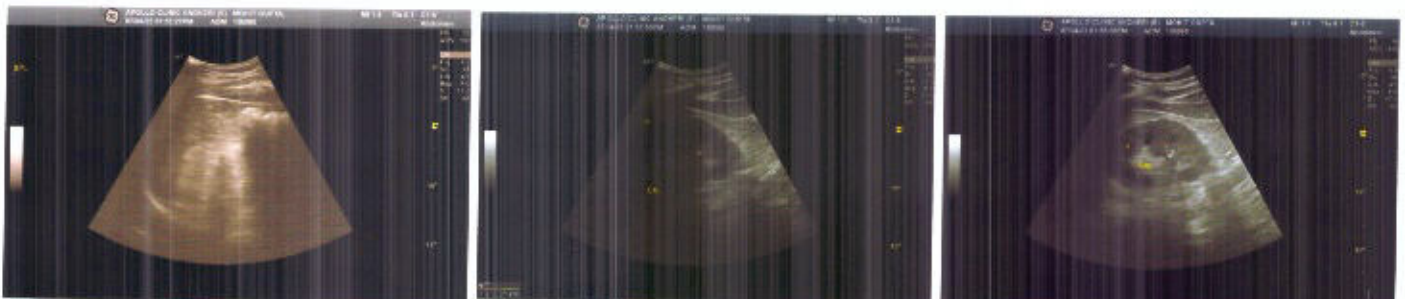
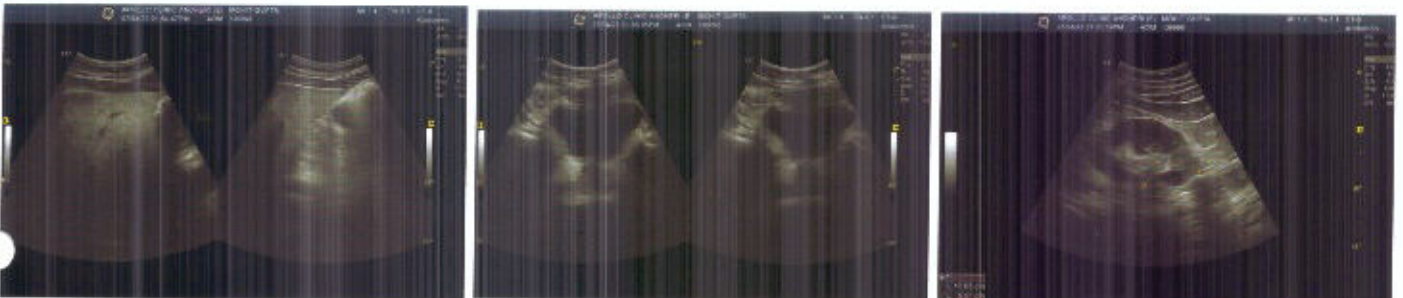
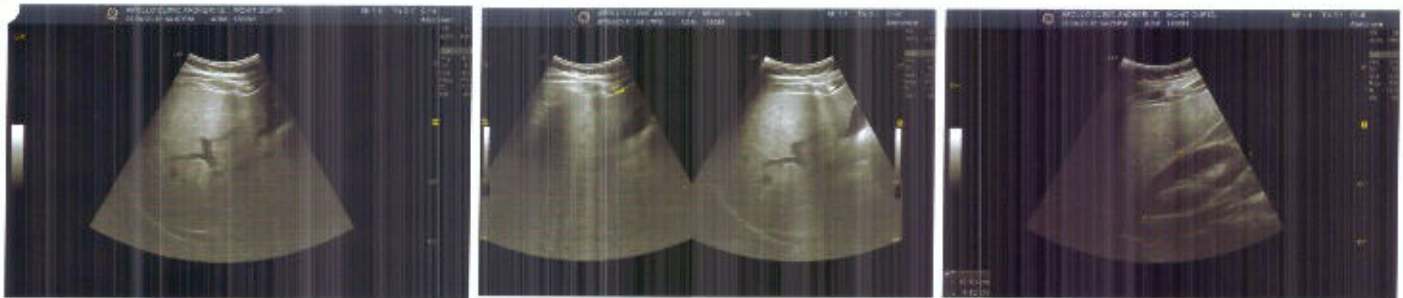Dr. Anagha Shetty
Consultant Radiologist

Apollo Clinic
Xtrim Ground Floor, Next to Holy Family Church,
Andheri (E).

Patient ID: 136098
Name: MOHIT GUPTA
Sex: M

Date: 07-Apr-2023



Name : Mr Mohit Gupta

Gender : Male Age : 36 Years

UHID : AM10.0000221208

Bill No : ACR128811 Lab No :

Ref. by : Self

Date : 07-Apr-2023 Time : 01:29 PM

Xray Chest PA

Both lung fields do not reveal any significant pulmonary parenchymal lesion.

Both costophrenic and cardiophrenic angles are clear.

Both hila appear normal.

Cardiac size is within normal limits.

Both the domes of diaphragm appear normal in contour and position.

Visualised bony thorax and dorsal spine appear normal.

IMPRESSION : Normal x-ray chest.

Note: Findings in Chest Xray are affected by many factors. Any findings on Chest Xray need to be confirmed by Chest CT.



Dr. Anagha Shetty
Consultant Radiologist

APOLLO CLINIC

Andheri - East

Date 7/4/2023

Patient Name Mohit Gupta

Age 36 Sex M

For ENT Check - Up

RIGHT

LEFT

Ears -

Tympanic Membrane -



Ⓢ

Ⓢ

Tuning Fork Test -

Rinnes -

+

+

Weber -

→

Nose -

DNs N

Throat -

Ⓢ - 130

Remarks -

WNL


Dr. Anita Babiwale
ENT) D.O.
Consultant ENT Surgeon
Reg. No. 2009/10/3551

NABL Accredited : The highest Quality Certification for Medical Laboratories in our country
Consultation • Diagnostics • Health Check-Ups • Dentistry • Skin Clinic • Weight Loss Clinic

APOLLO CLINIC

Andheri - East

Date 06/04/23.

Patient Name

Mohit Gyale

Age

36

Sex

M

UHID :

	Right Eye			Left Eye				
	Sphere	Cylinder	Axis	Vision	Sphere	Cylinder	Axis	Vision
Distance	-	T.00	30	6/6	-	0.25	140	6/6
Near	—————			N6	—————			N6
Glasses: Distance/Near/Bifocals								

test

20090101111

NABL Accredited : The highest Quality Certification for Medical Laboratories in our country
Consultation • Diagnostics • Health Check-Ups • Dentistry • Skin Clinic • Weight Loss Clinic

APOLLO CLINIC

Andheri - East

Date 7/4/23

Patient Name MR. MOHIT GUPTA

Age 36yrs Sex M.

Complaints : H/o glasses for dist @
Aching (R > L)
Redness occ. Dom @ - 24x onn-
fbs - 120.

Visual Acuity :

Distant - Unaided

With Glasses

Near Vision

RE

LE

6/6 (bin)
(-1.00 x 30) 6/6

6/6
(-0.25 x 140)

NG

NG

Slit Lamp Examination (BE) AS - WDR

Application Tonometry :

Applanation :

Colour Vision : (BE) Normal

Fundus Examination through undilated pupil :

Media -

Cup / Disc Ratio -

Shape -

Colour -

Margins -

Macula -

Vessels -

Periphery -

(BE) OD - 4

Mac - appear @

Impression :

(BE) Ref error =

Rx (BE) locally

①. Olopat eyedrop

②. Refresh tear eyedrop

2 times/day + 3week.

x 3week

NABL Accredited : The highest Quality Certification for Medical Laboratories in our country
Consultation • Diagnostics • Health Check-Ups • Dentistry • Skin Clinic

Name: MR. MOHIT GUPTA

Age: 36 YRS

Date of Health Check: 07/09/23

DENTAL EXAMINATION

Scaling & Polishing : _____

Fillings : _____

Root Canal : _____

Extraction : _____

Replacement of Missing Teeth : _____

Any other Remarks : _____

Doctor's Sign & Stamp :

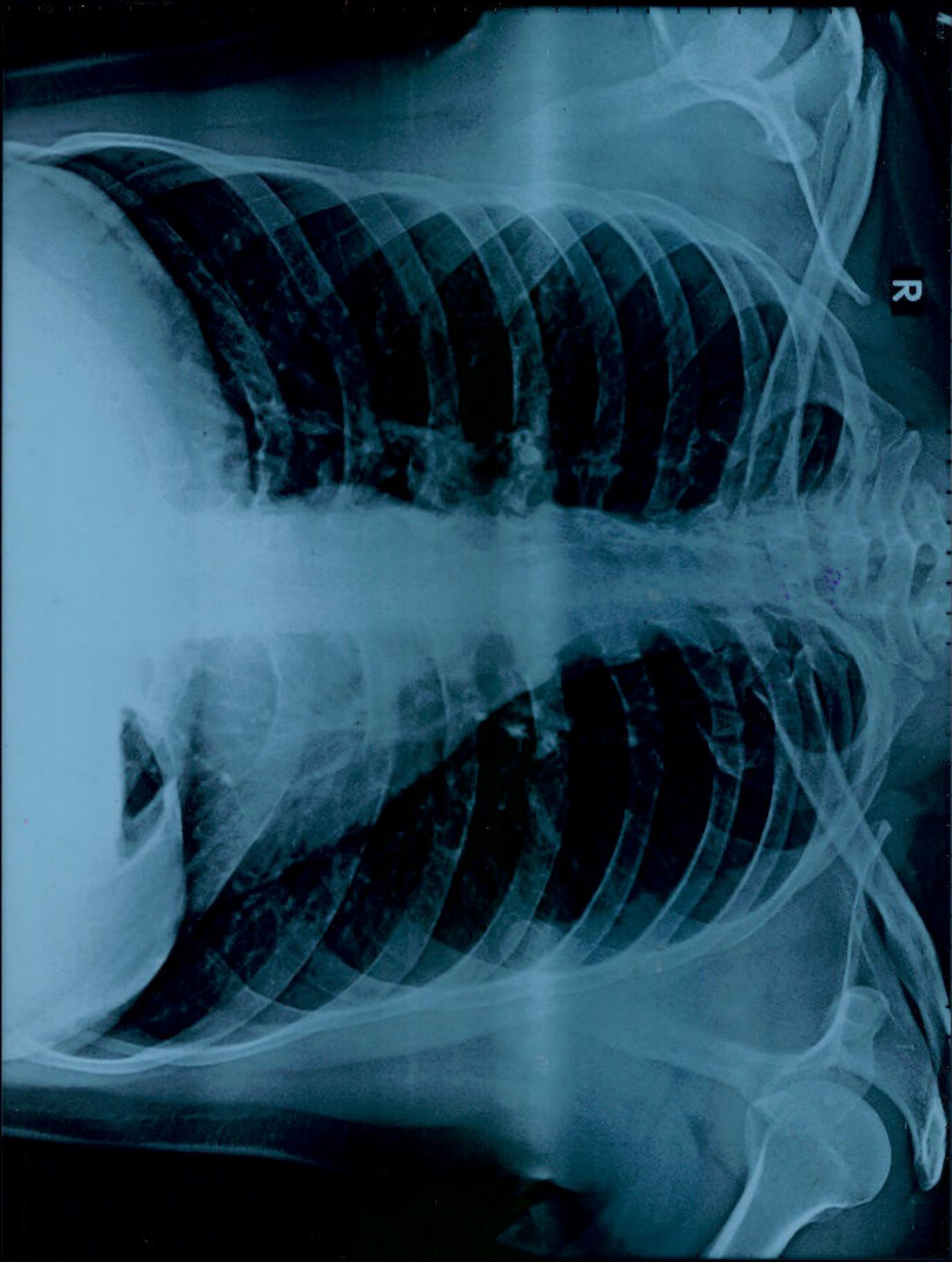
Recommend

Findings and Recommendation :

- 1) Follow iron rich, low fat, high fibre - diabetic diet
- 2) Exercise regularly, reduce weight
- 3) Take plenty of oral fluids.
- 4) Consult physician's reports.

Signature:
Consultant - Internal Medicine

R



221208 MR. MOHIT GUPTA 36Y-M CHEST PA 07-Apr-23

APOLLO CLINIC