



बैंक ऑफ बड़ोदा
Bank of Baroda

नाम: **NISHA MEENA**
Name: **NISHA MEENA**

कर्मचारी कूट क्र.
E. C. No. **107492**



आरीकर्ता प्राधिकारी, मु. प्र. (सु.) अ.का. न.दि.
Issuing Authority CM (S), ZO, ND.


धारक के हस्ताक्षर
Signature of Holder





DR. NITIN AGARWAL
MBBS, MR
Reg. No. DMC-R-122

ONEPLUS ULTRASOUND LAB
47, Hansi Vihar, Phase - II, Pura
Delhi-110034
Ph 011-42485101, 42485102
E-mail onepus@oneplusultrasound.com

12

12

12

ONEPLUS ULTRASOUND LAB

47, HARSH VIHAR, PITAMPURA, DELHI- 110034

Ms. NISHA GUPTA

Age : 31/F

Ref. by : MEDIWHEEL

Indication1 :

Indication2 :

Indication3 :

COMMENTS : Normal ECG.

ID : 1646

HMMF : 163/56

Recorded : 22-6-2021 10:12

Medication1 :

Medication2 :

Medication3 :

BPM : 86
 BP : 124/78
 P Axis : 86 deg
 QRS Axis : 86 deg
 T Axis : 63 deg

P duration : 86 msec
 PR duration : 130 msec
 QRS duration : 96 msec
 QT Interval : 306 msec
 QTc Interval : 351 msec

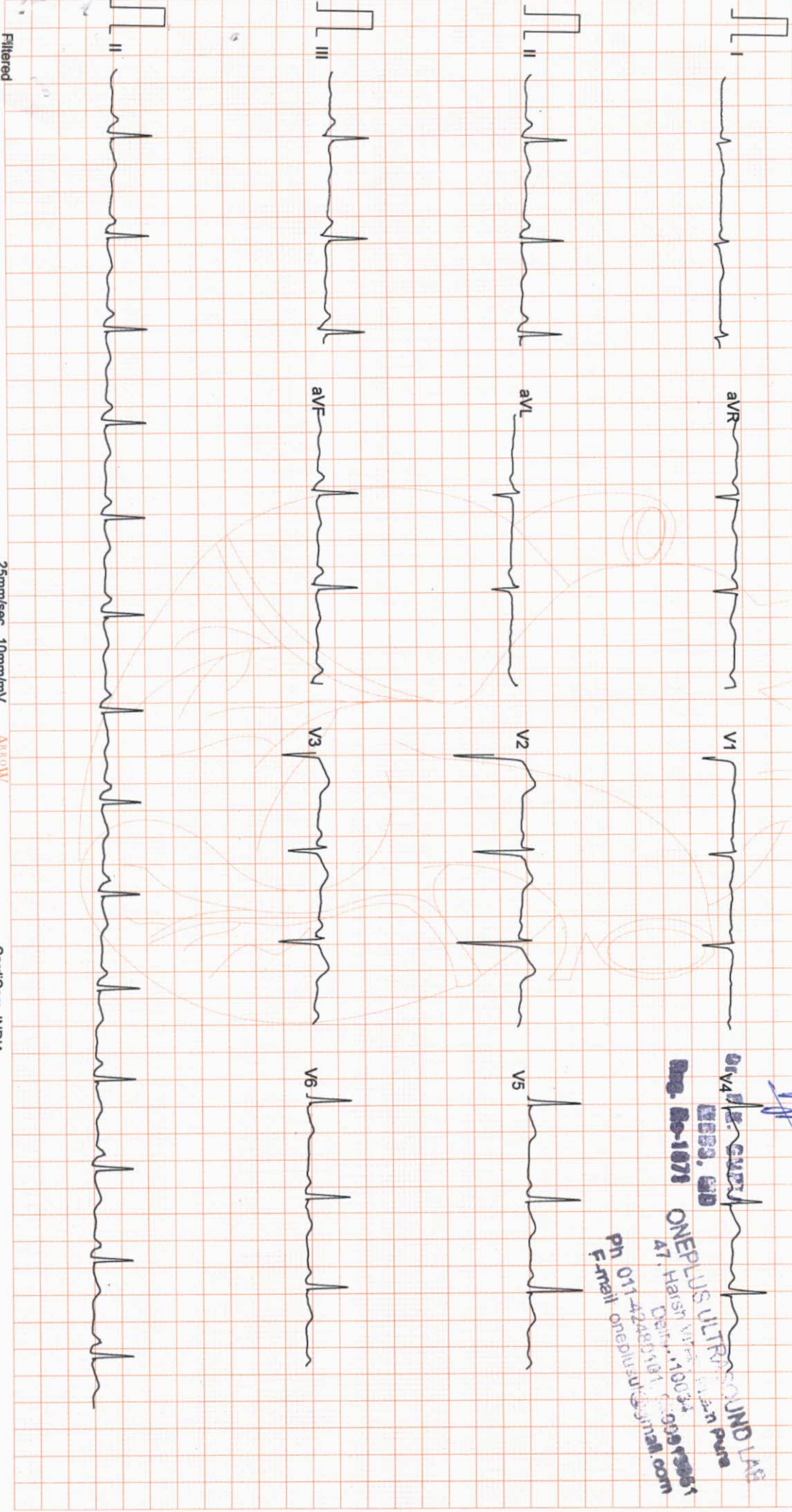
Raw E.C.G. (Seq)

AKS

Unconfirmed Report Reviewed By:
 Cardiologist

SK

Dr. Nisha Gupta
 MBBS, MD
 Reg. No-1071 ONEPLUS ULTRASOUND LAB
 47, Harsh Vihar, Pitampura
 Delhi-110034
 Ph: 011-42480341
 Email: onepplus@gmail.com



Filtered

25mm/sec 10mm/mV

ARROW

CardiCom, INDIA



[Handwritten signature]

DR. NITIN AGARWAL
M.B.B.S., M.R.
Reg. No. DMC-R-145

ONEE - Dr. UTRASH KUND
47, Jyoti Vihar, Pitam Pura
Ph: 011-26489441, 989993861
F-mail: onee@onee@gmail.com

ONEPLUS ULTRASOUND LAB

47, HARSH VIHAR PITAMPURA DELHI 110034

Ms. NISHA GUPTA

Age : 31/F

Ref. by : MEDIWHEEL

Indication1 :

Indication2 :

Indication3 :

ID : 999

HWWT : 163/56

Recorded : 22-6-2021 10:15

TREADMILL TEST SUMMARY REPORT

Protocol: BRUCE

History:

Medication1 :

Medication2 :

Medication3 :

PHASE	PHASE TIME	STAGE TIME	SPEED (Km./Hr.)	GRADE (%)	H.R. (BPM)	B.P. (mmHg)	RPP X100	II	ST LEVEL (mm) V2	V5	METS
SUPINE											
STANDING											
STAGE 1	2:59	2:59	2.70	10.00	89	124/78	110	0.8	1.9	0.8	
STAGE 2	5:59	2:59	4.00	12.00	108	138/84	149	0.4	1.8	0.7	4.80
STAGE 3	8:59	2:59	5.40	14.00	122	150/88	183	0.0	1.6	0.7	7.10
STAGE 4	9:59	0:59	6.70	16.00	151	162/92	244	0.0	1.9	0.5	10.00
PEAK EXER	10:02	1:02			163	176/94	286	0.1	2.0	0.2	11.32
RECOVERY	2:59	2:59	0.00	0.00	94	126/80	118	0.2	1.8	0.1	11.39

RESULTS

Exercise Duration

Max Heart Rate

Max Blood Pressure

Max Work Load

Reason of Termination

IMPRESSIONS

10:02 Minutes

163 bpm - 86 % of target heart rate - 189 bpm

176/94 mmHg

11.39 METS

Heights for stable walk

Cardiologist

Dr. P.S. GUPTA

MBBS, CCG

Reg. No-1079

ONEPLUS ULTRASOUND LAB
47, Harsh Vihar
Delhi-110034
Ph: 011-42430354
E-mail: oneplusul@gmail.com

Ph: 011-42430354
E-mail: oneplusul@gmail.com

ONEPLUS ULTRASOUND LAB

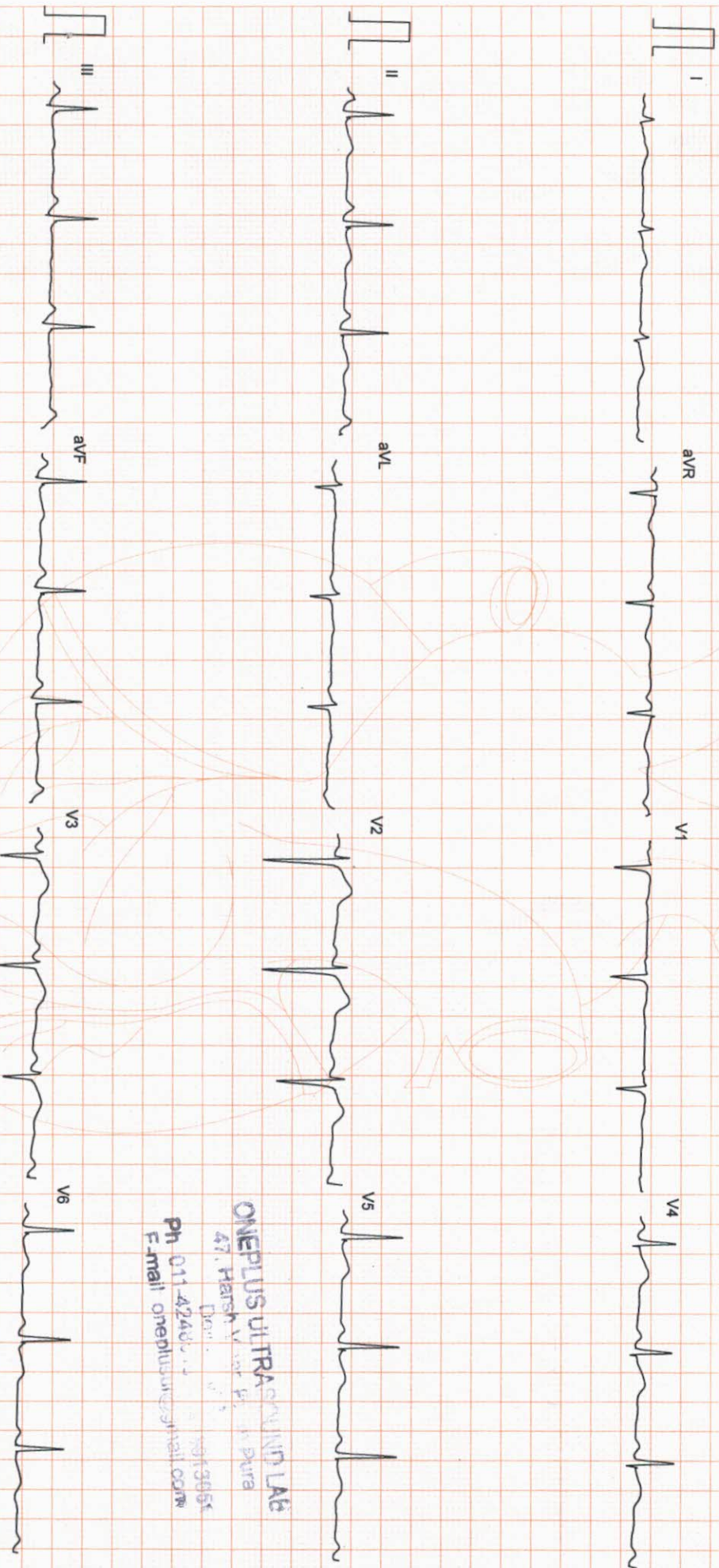
SUPINE
PRETEST

ST @ 10mm/mV
80ms PostJ

Ms. NISHA GUPTA
I.D. : 999
AGE/SEX : 31/F
RECORDED : 22-6-2021 10:15

RATE : 89 BPM
B.P. : 124/78 mmHg

RAW E.C.G.



ONEPLUS ULTRASOUND LAB
47, Hansa Vihar, Sector 14, Gurgaon
Ph: 011-42461111, 9613665x
E-mail: onepplus@gmail.com

ONEPLUS ULTRASOUND LAB

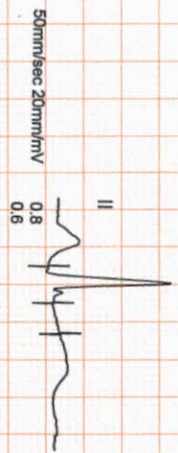
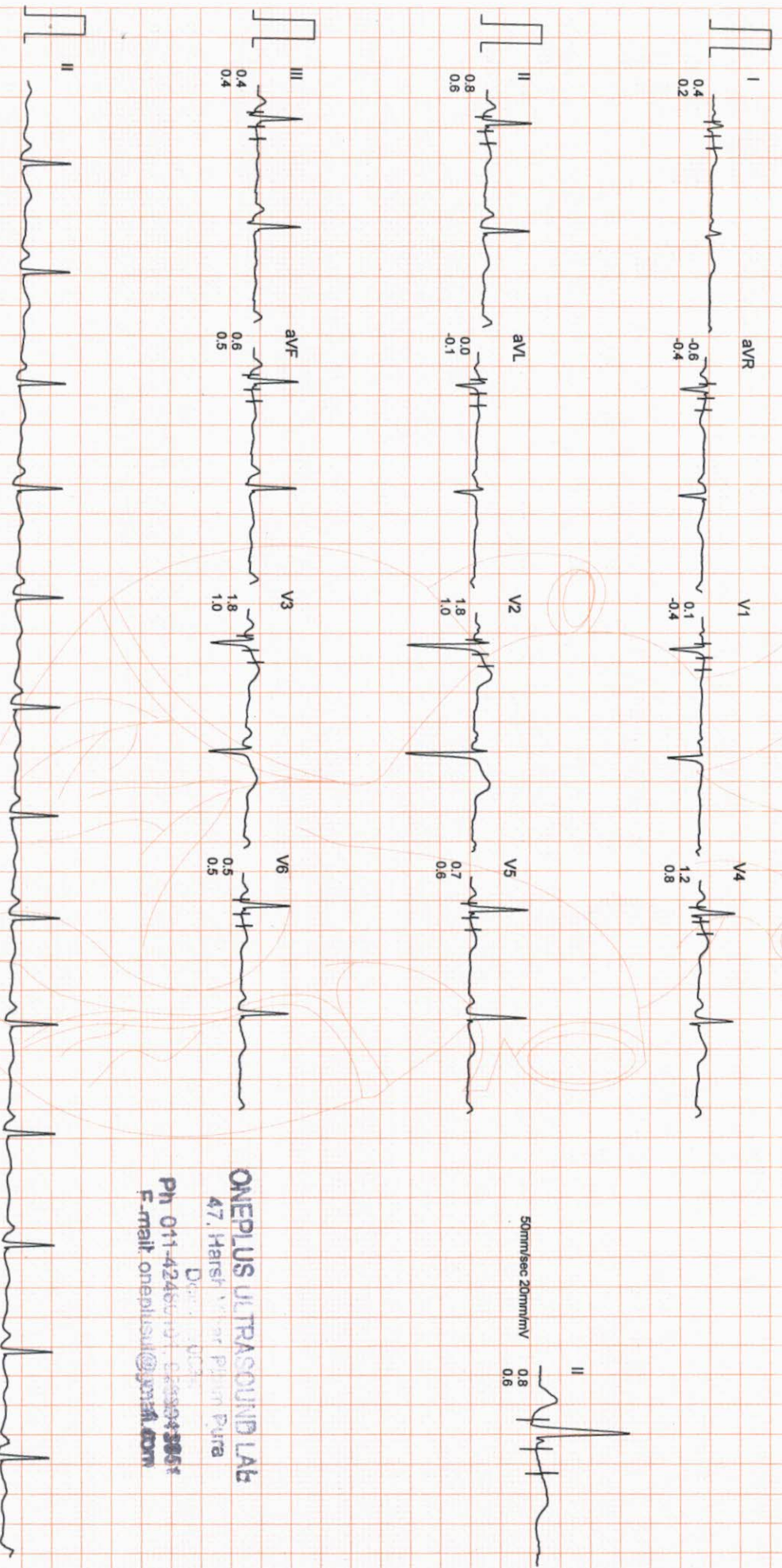
STANDING
PRETEST

ST @ 10mm/mV
80ms PostJ

Ms. NISHA GUPTA
I.D. : 999
AGE/SEX : 31/F
RECORDED : 22-6-2021 10:15

RATE : 83 BPM
B.P. : 124/78 mmHg

LINKED MEDIAN



ONEPLUS ULTRASOUND LAB
47, Hansi, Sector Piplim Pura
Durgam Chokki
PH 011-42460191, 0226993861
E-mail: oneplusul@jmiil.com

Filtered Computer Corrected Baseline

25mm/sec 10mm/mV

ARROW

CardiCom, INDIA Ph. no. 724 2222

ONEPLUS ULTRASOUND LAB

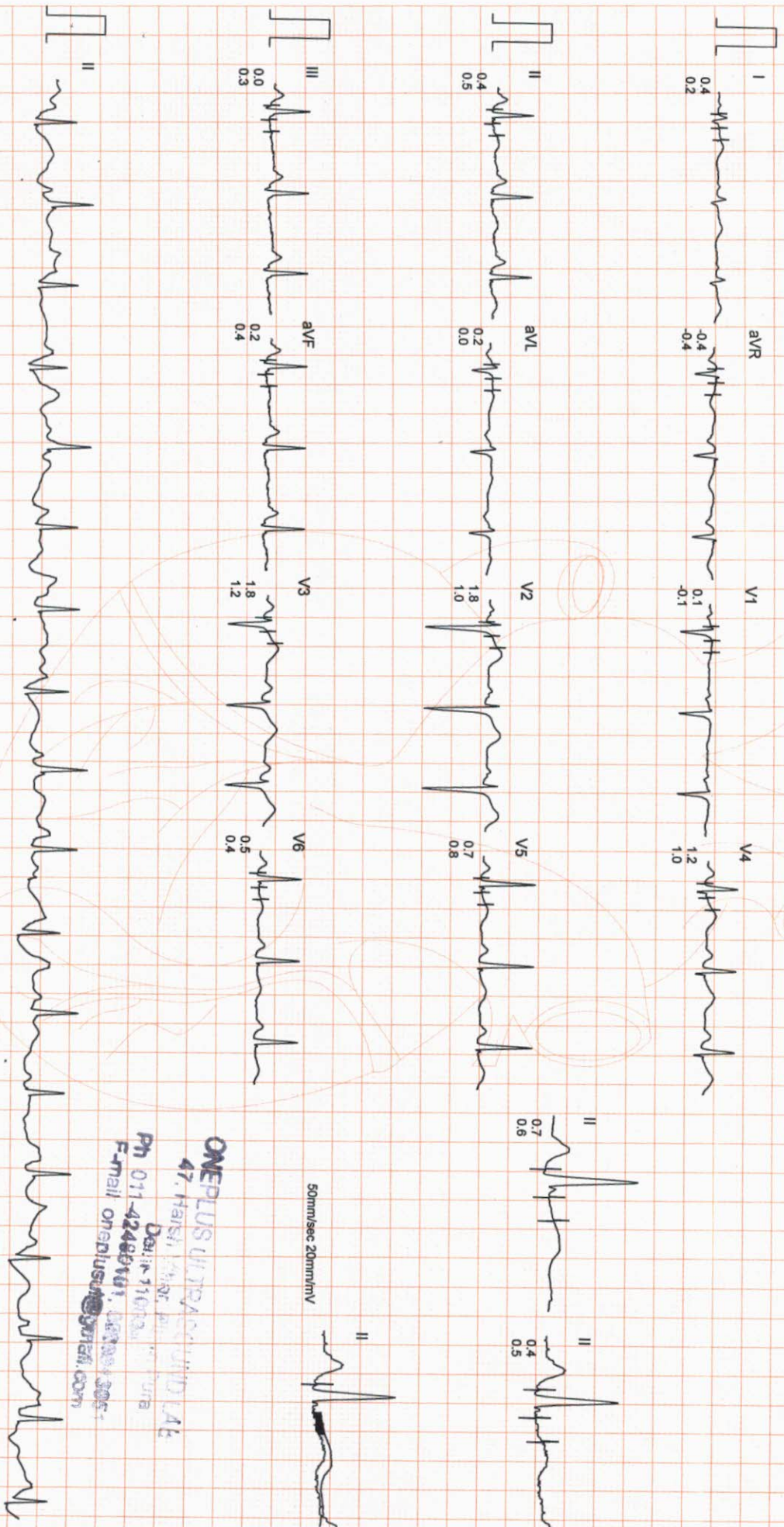
Ms. NISHA GUPTA
 I.D. : 999
 AGE/SEX : 31/F
 RECORDED : 22-6-2021 10:15

RATE : 108 BPM
 B.P. : 138/84 mmHg

BRUCE
 EXERCISE 1
 PHASE TIME : 2:59
 STAGE TIME : 2:59

ST @ 10mm/mv
 80ms PostJ
 SPEED : 2.7 Km./Hr.
 GRADE : 10.0 %

LINKED MEDIAN



Filtered Computer Corrected Baseline 25mm/sec 10mm/mv

ONEPLUS ULTRASOUND LAB
 47, Hansi, Near J.P. Narayan
 Delhi - 110028
 Ph 011-42489101, 42489102
 Email onepplus@oneplus.com

Cardicom, INDIA Ph.:091-731-2620740, Telefax:091-731-2431214

ONEPLUS ULTRASOUND LAB

Ms. NISHA GUPTA

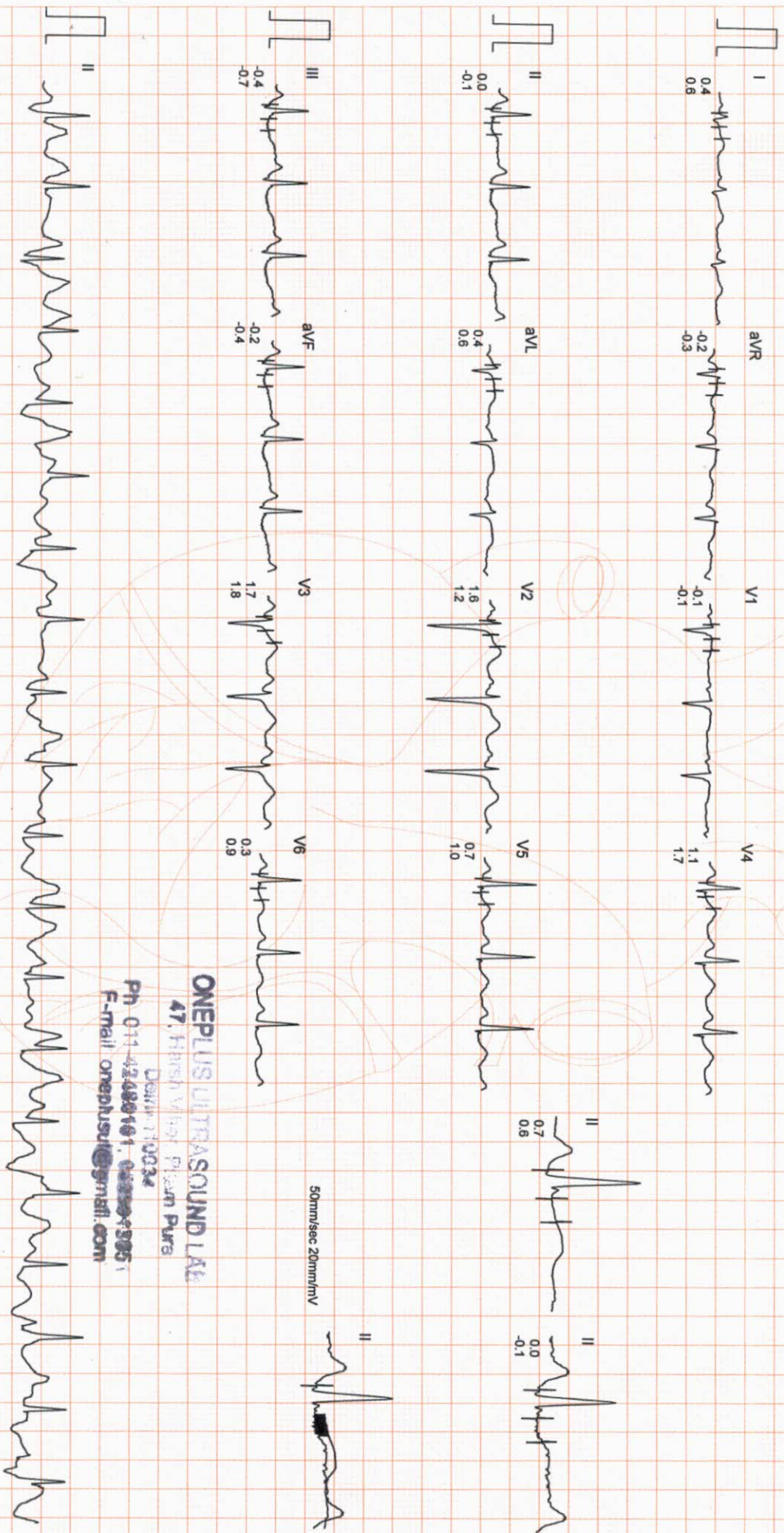
I.D. : 999
AGE/SEX : 31/F
RECORDED : 22-6-2021 10:15

RATE : 122 BPM
B.P. : 150/88 mmHg

BRUCE
EXERCISE 2
PHASE TIME : 5:59
STAGE TIME : 2:59

ST @ 10mm/mV
80ms PostJ
SPEED : 4.0 Km./Hr.
GRADE : 12.0 %

LINKED MEDIAN



ONEPLUS ULTRASOUND LAB
47, Hrishyagar, Piplun Pura
Durgam 50034
Ph: 011-42489191, 0226-93951
E-Mail: oneplusul@gmail.com

ONEPLUS ULTRASOUND LAB

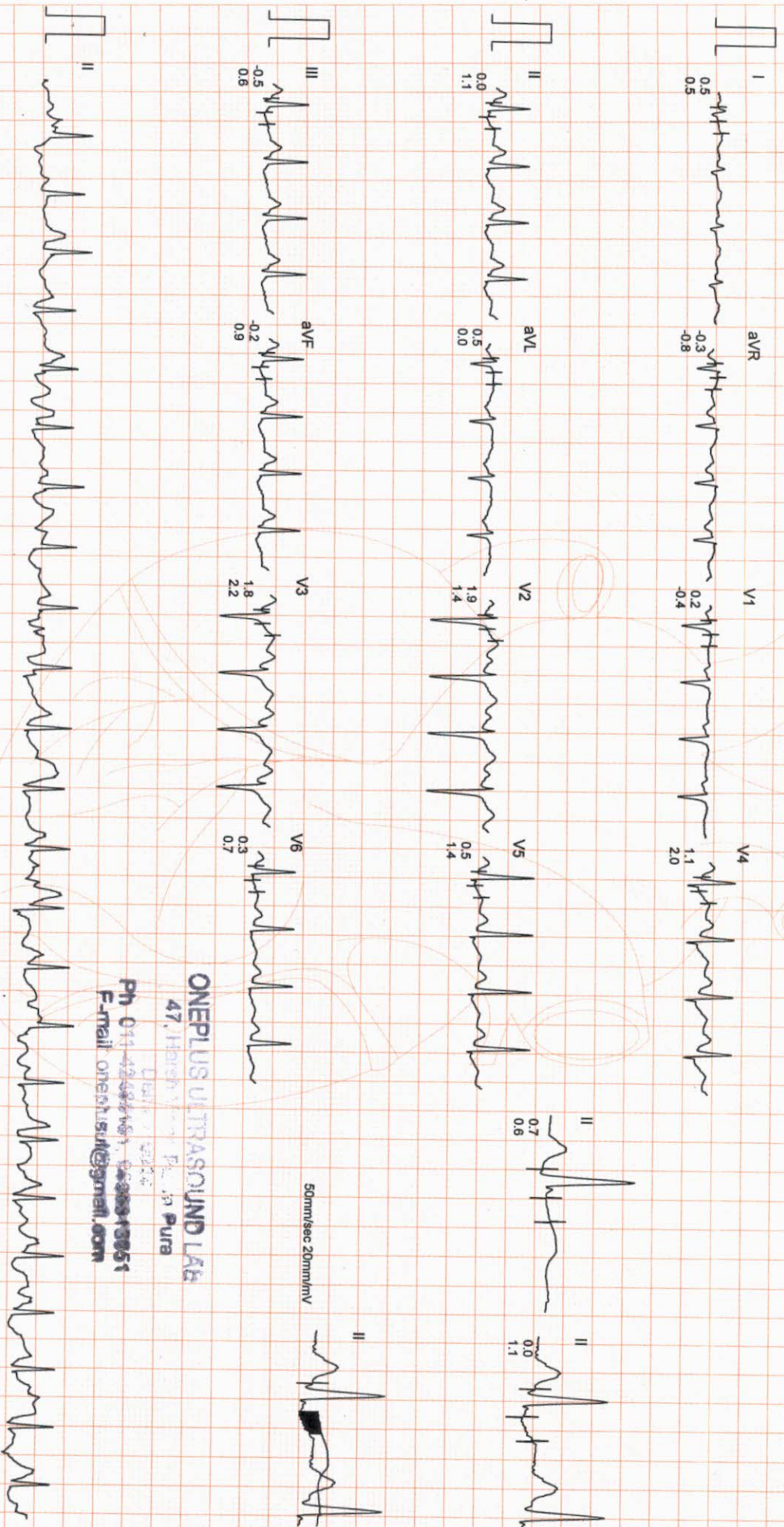
Ms. NISHA GUPTA
 I.D. : 999
 AGE/SEX : 31/F
 RECORDED : 22-6-2021 10:15

RATE : 151 BPM
 B.P. : 162/92 mmHg

BRUCE
 EXERCISE 3
 PHASE TIME : 8:59
 STAGE TIME : 2:59

ST @ 10mm/mV
 80ms PostJ
 SPEED : 5.4 Km./HR.
 GRADE : 14.0 %

LINKED MEDIAN



Filtered Computer Corrected Baseline

25mm/sec 10mm/mV

ARROW

CardiCom, INDIA Ph. 091-731-2620740 TeleFax:091-731-2432114

ONEPLUS ULTRASOUND LAB
 47, Harsh Vihar, Pura
 Lucknow, U.P.
 Ph 011-44884467, 99913051
 E-mail oneml@oneplusultrasound.com

50mm/sec 20mm/mV

Ms. NISHA GUPTA

I.D. : 999

AGE/SEX : 31/F

RECORDED : 22-6-2021 10:15

ONEPLUS ULTRASOUND LAB

BRUCE

EXERCISE 4

PHASE TIME : 9:44

STAGE TIME : 0:44

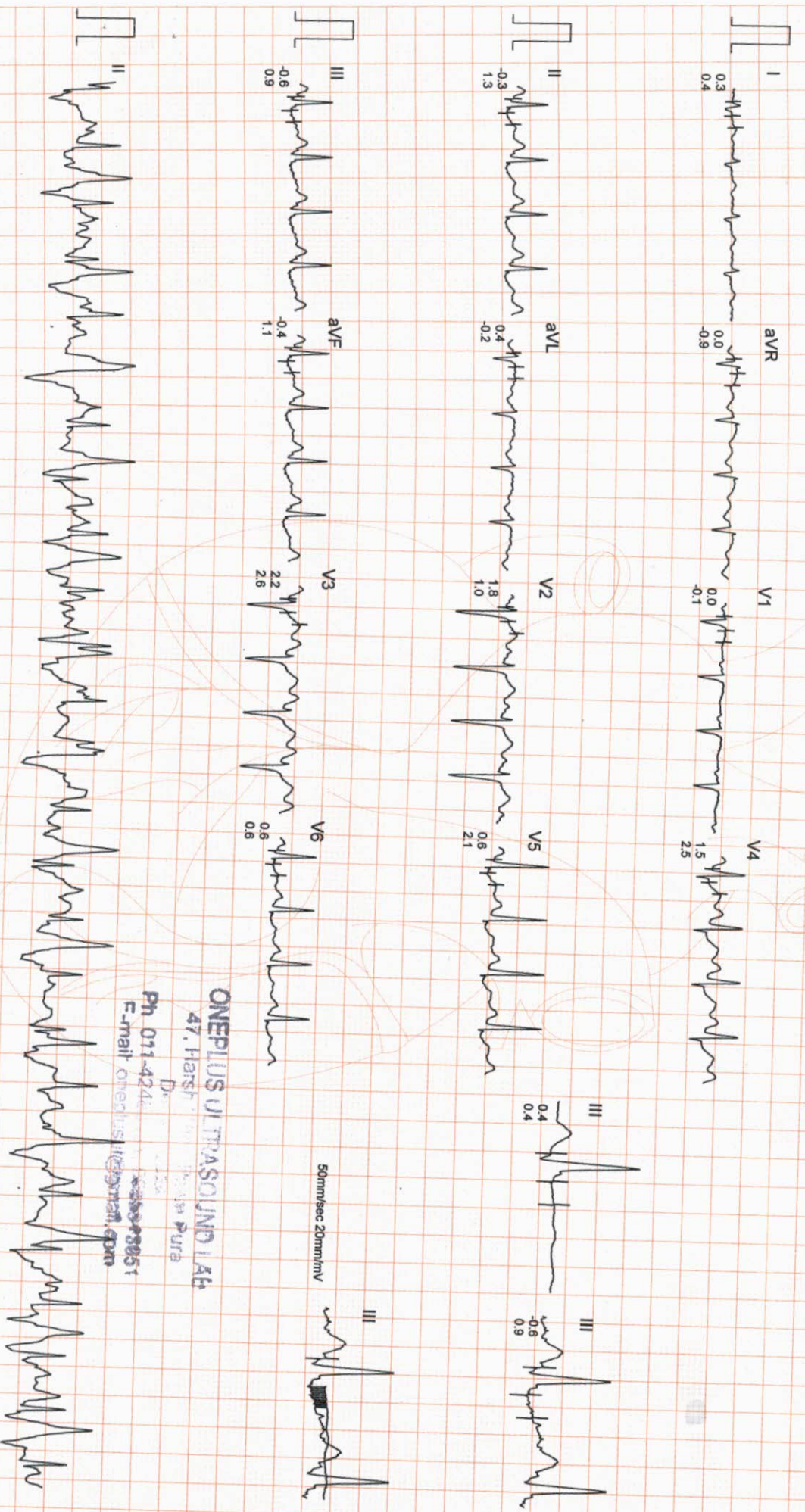
ST @ 10mm/mv

80ms PostJ

SPEED : 6.7 Km./HR.

GRADE : 16.0 %

LINKED MEDIAN



Filtered

Computer Corrected Baseline

25mm/sec 10mm/mV

ARRG

CardiCom, INDIA Ph. : 091-731-2620720 T-1-1-1

ONEPLUS ULTRASOUND LAB
47, Hansi Road, Sector 14, Gurgaon, Haryana

Dr. Nisha Gupta

Ph. 011-4224

E-mail: onepplus@rediffmail.com

011-2620720

ONEPLUS ULTRASOUND LAB

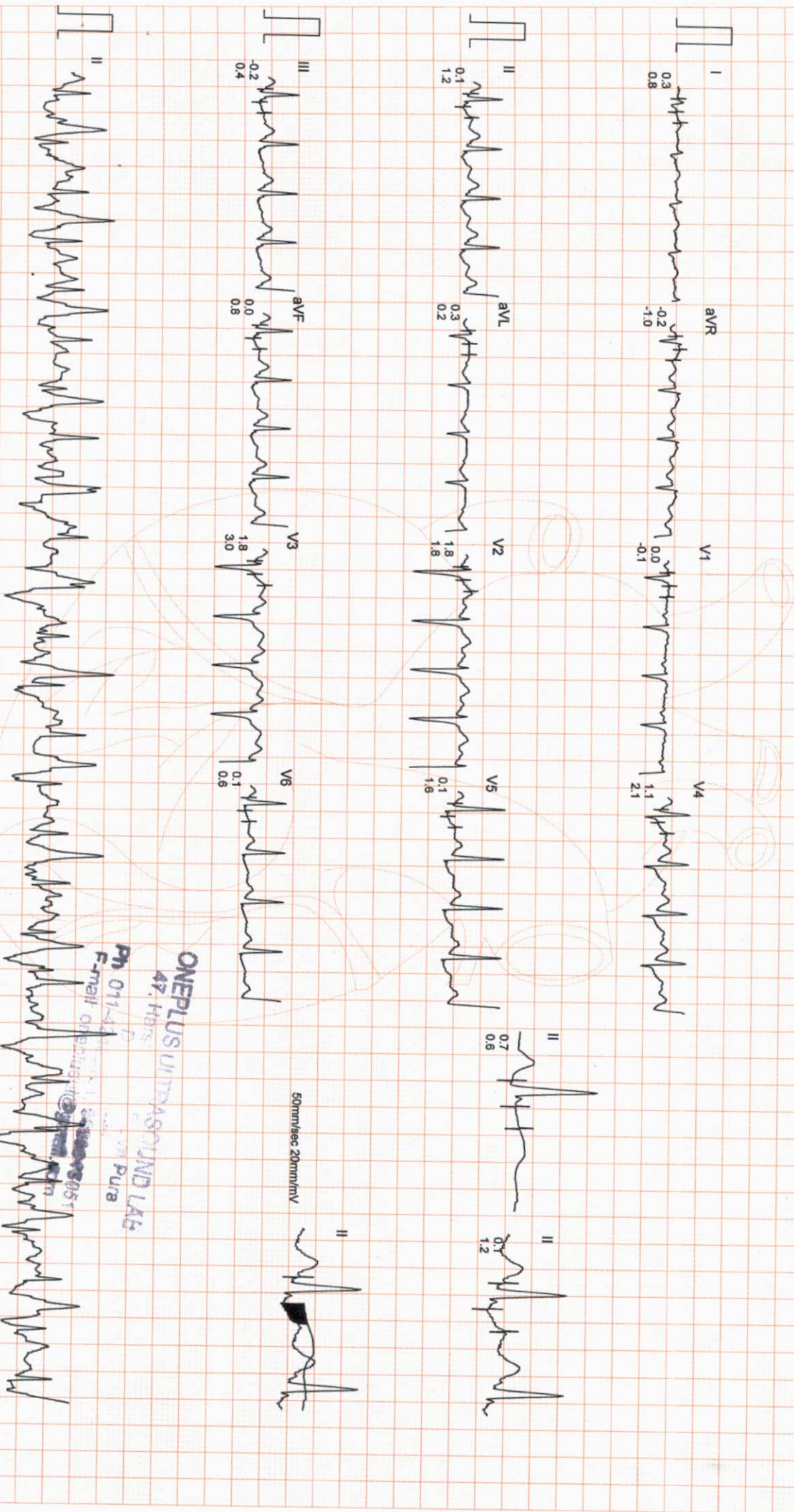
Ms. NISHA GUPTA
I.D. : 999
AGE/SEX : 31/F
RECORDED : 22-6-2021 10:15

RATE : 163 BPM
B.P. : 176/94 mmHg

BRUCE
PEAK EXER
PHASE TIME : 10:02
STAGE TIME : 1:02

ST @ 10mm/mV
80ms PostJ
SPEED : 6.7 Km./Hr.
GRADE : 16.0 %

LINKED MEDIAN



Filtered Computer Corrected Baseline 25mm/sec 10mm/mV

ONEPLUS ULTRASOUND LAB
47, Hhrs
Ph. 011-41111111
Email: oneplus@oneplus.com

ONEPLUS ULTRASOUND LAB

Ms. NISHA GUPTA

I.D. : 999

AGE/SEX : 31/F

RECORDED : 22-6-2021 10:15

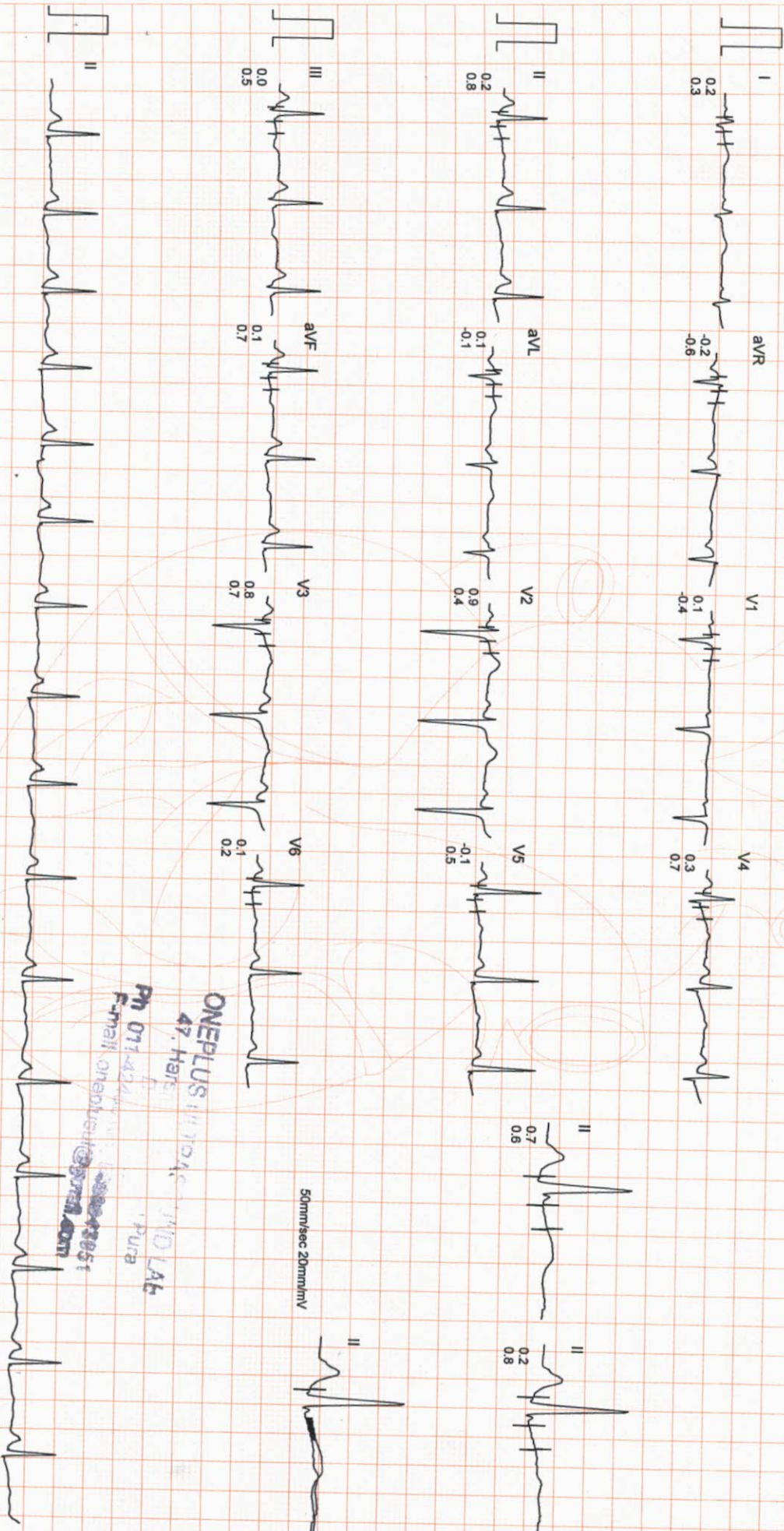
RATE : 94 BPM

B.P. : 126/80 mmHg

BRUCE
RECOVERY
PHASE TIME : 2:59

ST @ 10mm/mV
80ms PostJ
SPEED : 0.0 Km./hr.
GRADE : 0.0%

LINKED MEDIAN



ONEPLUS
47, Har...

M 071-422...
E-mail: onepplus@oneplus.com

071051

50mm/sec 20mm/mV

Filtered

Computer Corrected Baseline

25mm/sec 10mm/mV

ARROW

Cardio-Cath Lab



ONEPLUS ULTRASOUND LAB
 47 Heer
 Ph 011-42450101
 F-mail: oneplusultrasoundlab@gmail.com











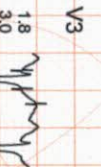

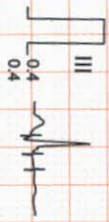







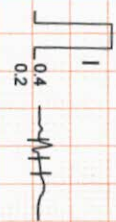
ONEPLUS ULTRASOUND LAB

STANDING
 0.0Kmph
 0.0%
 83 bpm
 B.P. 124/78
 80ms PostJ


PEAK EXERCISE
 10:02
 1:02
 6.7Kmph
 16.0%
 163 bpm
 B.P. 176/94
 80ms PostJ

STANDING
 0.0Kmph
 0.0%
 83 bpm
 B.P. 124/78
 80ms PostJ

PEAK EXERCISE
 10:02
 1:02
 6.7Kmph
 16.0%
 163 bpm
 B.P. 176/94
 80ms PostJ



ONEPLUS ULTRASOUND LAB
 47, Harsa, ...
 PNo. 011-42400001, 3051
 Email: onepus@oneplus.com





OnePLUS
Ultrasound Lab

QUALITY FIRST... ALWAYS!

Dr. Nitin Agarwal
Pathologist & Director
Ex. Sr. Res. MAMC
& Lok Nayak Hospital
Ex. Chief of Lab Dr. Lal Path Labs.

Dr. Pooja (Garg) Agarwal
Radiologist & Director
MAMC & Lok Nayak Hospital

Name	: Mrs. NISHA GUPTA	Age/Sex	: 31 YRS/Female
Ref. By	: Dr. MEDIWHEEL	Lab No	: 012106220005
Date	: 22-Jun-2021	Patient ID	: LSHHI80366

ULTRASOUND EXAMINATION----WHOLE ABDOMEN

Liver is normal in size (12.5 cm) and outline with normal echopattern. Intrahepatic biliary radicles are not dilated. No abscess or mass lesion seen. Hepatic veins, portal vein, IVC and aorta are normal. CBD is normal in caliber.

Gall bladder is well distended with anechoic lumen. Wall thickness is normal.

Both kidneys are normal in size, shape, position, outline and echopattern. Corticomedullary differentiation is maintained. No pelvicalyceal dilation or mass lesion is seen.

Spleen is normal in size and echotexture. No mass lesion seen.

Pancreas is normal in size, outline and echotexture.

Urinary bladder is normal in shape and position. No evidence of intravesical stone or mass seen.

Uterus. is normal in size (measures 7.9 x 4.3 cm), shape, position and echopattern. No mass seen

Uterine cavity contains **IUCD insitu**. Endometrial thickness is 9.4mm.

Both ovaries appear normal in size, shape and echopattern. No tubo-ovarian mass seen.

No abnormal bowel wall thickening seen in right iliac fossa.
No free fluid seen anywhere in abdomen.

IMPRESSION:

- Normal study.

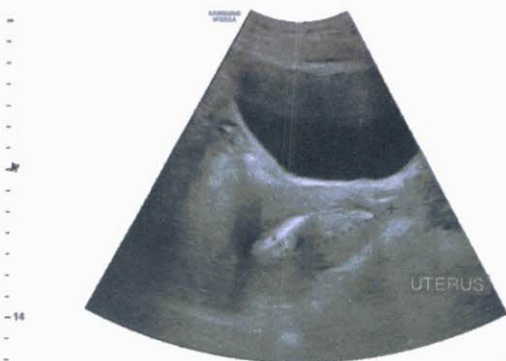DR. POOJA GARG
RADIOLOGIST
REG NO- DMC/R/03398

Type By : pooja

47, Harsh Vihar, Pitampura, New Delhi-110034 | Ph.: 011-42480101, 9599913051
E-mail: oneplusul@gmail.com | Web.: www.oneplusul.in

W880A MRS NISHA 37/F OnePlus Ultrasound Lab MI 1.5 22-06-2021
CA1-7A / Abdomen / FR 24Hz Tib0.1 10:19:28 AM

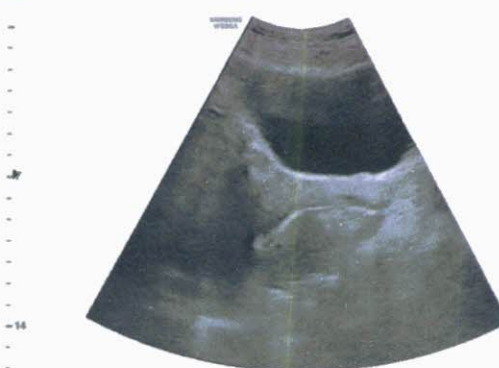20 G51 DR130 FA11 P100 Frq Pen. 18.0cm



D1 7.86 cm
D2 4.26 cm

W880A MRS NISHA 37/F OnePlus Ultrasound Lab MI 1.5 22-06-2021
CA1-7A / Abdomen / FR 24Hz Tib0.1 10:19:37 AM

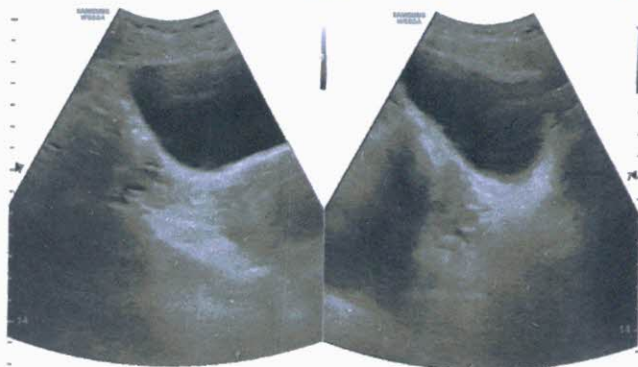
20 G51 DR130 FA11 P100 Frq Pen. 18.0cm



W880A MRS NISHA 37/F OnePlus Ultrasound Lab MI 1.5 22-06-2021
CA1-7A / Abdomen / FR 24Hz Tib0.1 10:20:02 AM

20 G51 DR130 FA11 P100 Frq Pen. 18.0cm

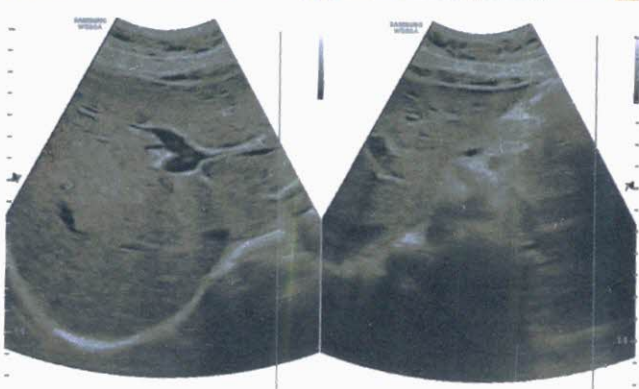
20 G51 DR130 FA11 P100 Frq Pen. 18.0cm



W880A MRS NISHA 37/F OnePlus Ultrasound Lab MI 1.5 22-06-2021
CA1-7A / Abdomen / FR 24Hz Tib0.1 10:20:20 AM

20 G53 DR130 FA11 P100 Frq Pen. 18.0cm

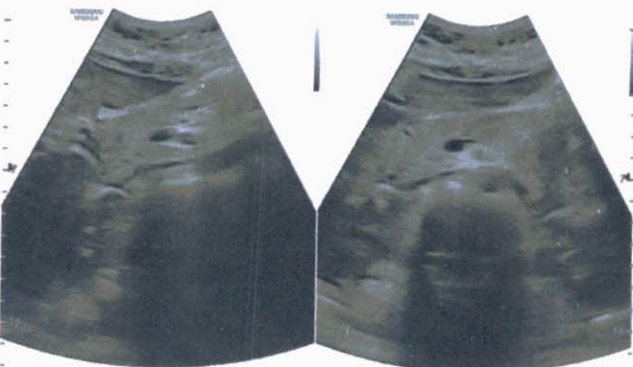20 G53 DR130 FA11 P100 Frq Pen. 18.0cm



W880A MRS NISHA 37/F OnePlus Ultrasound Lab MI 1.5 22-06-2021
CA1-7A / Abdomen / FR 24Hz Tib0.1 10:20:24 AM

20 G53 DR130 FA11 P100 Frq Pen. 18.0cm

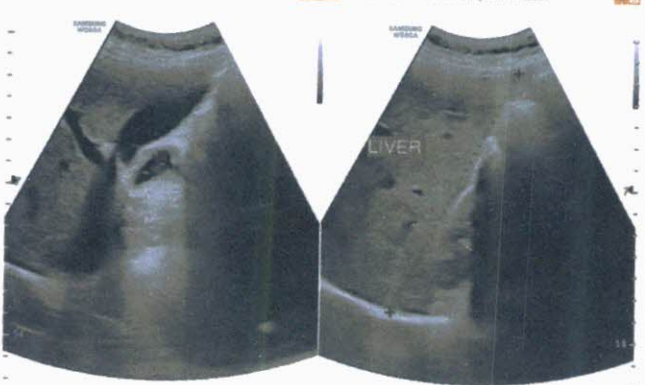20 G53 DR130 FA11 P100 Frq Pen. 18.0cm



W880A MRS NISHA 37/F OnePlus Ultrasound Lab MI 1.5 22-06-2021
CA1-7A / Abdomen / FR 24Hz Tib0.1 10:20:49 AM

20 G53 DR130 FA11 P100 Frq Pen. 18.0cm

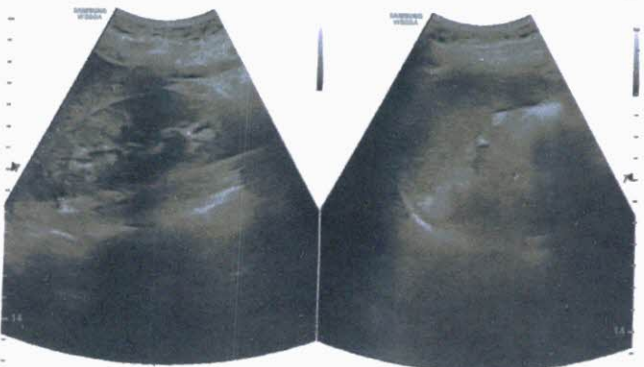20 G53 DR130 FA11 P100 Frq Pen. 18.0cm



W880A MRS NISHA 37/F OnePlus Ultrasound Lab MI 1.5 22-06-2021
CA1-7A / Abdomen / FR 24Hz Tib0.1 10:21:22 AM

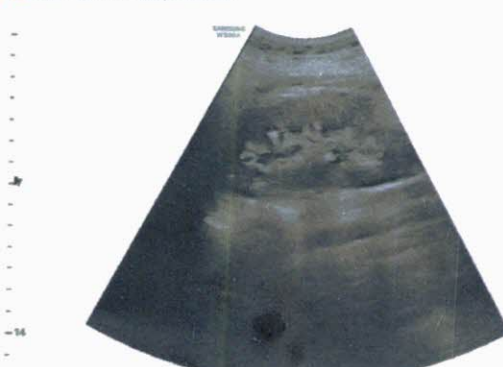20 G53 DR130 FA11 P100 Frq Pen. 18.0cm

20 G53 DR130 FA11 P100 Frq Pen. 18.0cm



W880A MRS NISHA 37/F OnePlus Ultrasound Lab MI 1.5 22-06-2021
CA1-7A / Abdomen / FR 24Hz Tib0.1 10:21:28 AM

20 G56 DR130 FA11 P100 Frq Pen. 18.0cm





OnePLUS
Ultrasound Lab

— QUALITY FIRST... ALWAYS! —

Dr. Nitin Agarwal
Pathologist & Director
Ex. Sr. Res. MAMC
& Lok Nayak Hospital
Ex. Chief of Lab Dr. Lal Path Labs.

Dr. Pooja (Garg) Agarwal
Radiologist & Director
MAMC & Lok Nayak Hospital

Name	: Mrs. NISHA GUPTA	Age/Sex	: 31 YRS/Female
Ref. By	: Dr. MEDIWHEEL	Lab No	: 012106220005
Date	: 22-Jun-2021	Patient ID	: LSHHI80366

X-ray-Chest PA view

Bony cage and soft tissues are normal.

Cardiothoracic ratio is normal.

Mediastinum is normal.


Both hila are normal.

Both costophrenic angles are clear.

Both domes of diaphragm are normal.

Lung fields are clear. No parenchymal lesion seen.

IMPRESSION: Normal Study.


DR. POOJA GARG
RADIOLOGIST
REG NO- DMC/R/03398

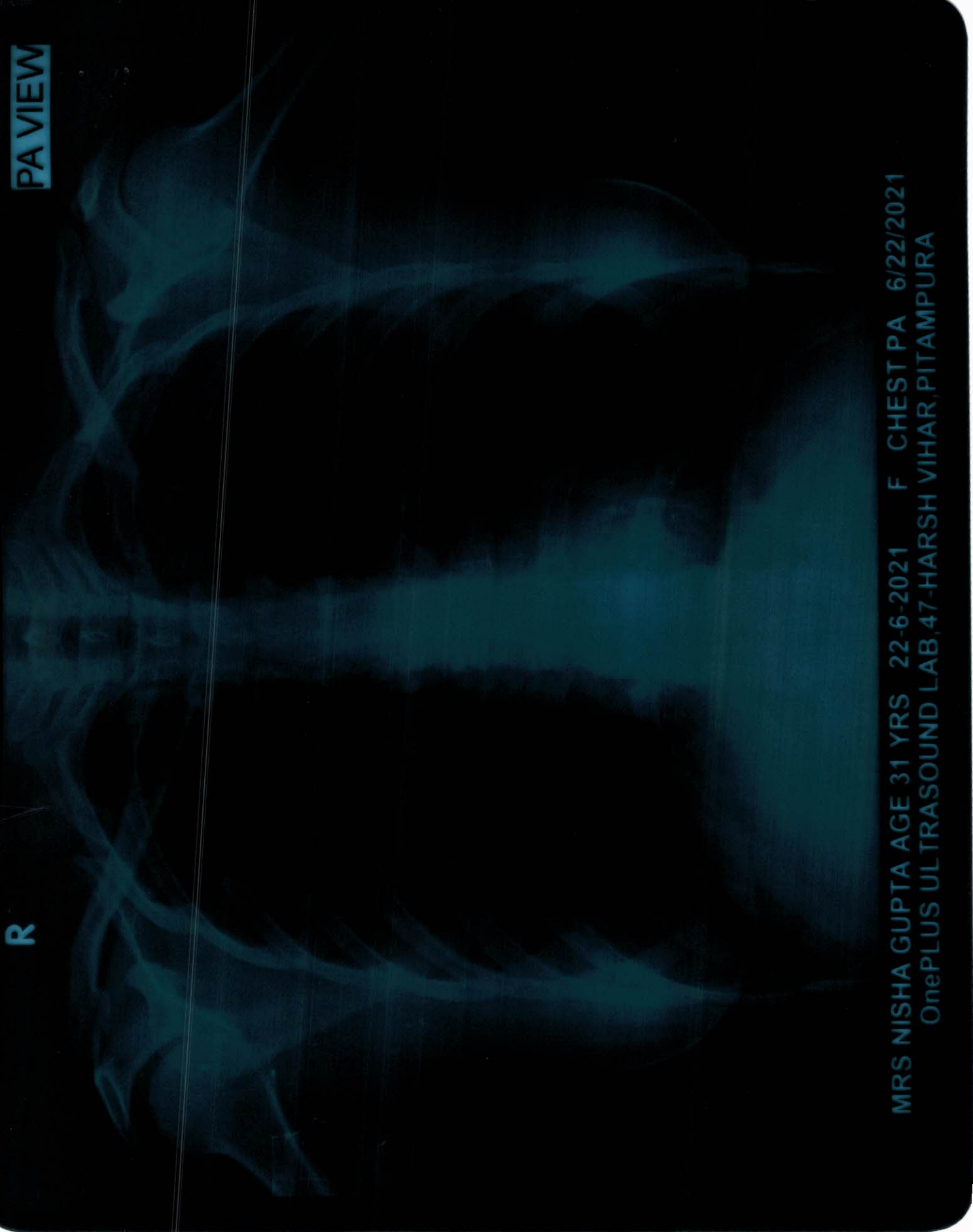
Type By : pooja

47, Harsh Vihar, Pitampura, New Delhi-110034 | Ph.: 011-42480101, 9599913051
E-mail: oneplusul@gmail.com | Web.: www.oneplusul.in

Clinical correlation is essential for final diagnosis. • If test results are unsatisfactory please contact personally or on phone. • This report is for perusal of doctors only.
• All disputes Subject to Delhi Jurisdiction only. • Not for medicolegal purposes. • All congenital anomalies in a foetus may not be diagnosed in routine obstetric ultrasound.

R

PA VIEW



MRS NISHA GUPTA AGE 31 YRS 22-6-2021 F CHEST PA 6/22/2021
OnePLUS ULTRASOUND LAB, 47-HARSH VIHAR, PITAMPURA

OnePLUS ULTRASOUND LAB 4A HARSH NIVAR, PITALAMPURA
MRS NISHA GUPTA AGE 31 YRS SS-E-5051 F CHEST PA 015515051

R

PA VIEW



NAME	:Mrs. NISHA GUPTA	Barcode No	:10099077
AGE/GENDER	:31 YRS/Female	SPECIMEN DATE	:22/Jun/2021 09:04AM
PATIENT ID	:80366	SPECIMEN RECEIVED	:22/Jun/2021 09:12AM
REFERRED BY	:Dr. MEDIWHEEL	REPORT DATE	:22/Jun/2021 01:11PM
CENTRE NAME	:ONEPLUS ULTRASOUND LAB	LAB NO.	:012106220005

Test Name	Result	Unit	Ref. Range
-----------	--------	------	------------

HAEMATOLOGY

Health checkup 2 Female

Glycosylated Hemoglobin (HbA1c)	5.2	%	Non Diabetic adults <5.7 Prediabetic (at risk) 5.7-6.4 Diabetes >6.4
--	-----	---	--

Estimated average blood glucose (eag) 103

Reference range (mg/dl):

90 - 120:Excellent control, 121 - 150:Good Control, 151 - 180:Average Control, 181 - 210:Action Suggested

>211:Panic value

REMARKS:-

In vitro quantitative determination of **HbA1C** in whole blood is utilized in long term monitoring of glycemia. The **HbA1C** level correlates with the mean glucose concentration prevailing in the course of the patient's recent history (approx - 6-8 weeks) and therefore provides much more reliable information for glycemia monitoring than do determinations of blood glucose or urinary glucose. It is recommended that the determination of **HbA1C** be performed at intervals of 4-6 weeks during Diabetes Mellitus therapy. On testing of HbA1C by HPLC method the result shows high variant window (93.8%) & no value of HbA1C. Therefore for accurate assay of glycaemic Control Fructosamine assay & for variant analysis Hb electrophoresis should be done.

Assay done by : Bio-Rad : D-10 (HPLC)

BLOOD GROUP (ABO)	B
Rh typing	POSITIVE

NOTE :

- * Apart from major A,B,H antigens which are used for ABO grouping and Rh typing, many minor blood group antigens exist. Agglutination may also vary according to titre of antigen and antibody.
- * So before transfusion, reconfirmation of blood group as well as cross-matching is needed.
- * Presence of maternal antibodies in newborns, may interfere with blood grouping.
- * Auto agglutination (due to cold antibody, falciparum malaria, sepsis, internal malignancy etc.) may also cause erroneous result.

CBC

Haemoglobin	11.6	g/dl	11.5-15.0
-------------	------	------	-----------

Checked By.

DR. NITIN AGARWAL
MBBS, MD (PATHOLOGIST)
RAC/10/10/10
DR. NITIN AGARWAL
MBBS, MD (PATHOLOGIST)



NAME	:Mrs. NISHA GUPTA	Barcode No	:10099077
AGE/GENDER	:31 YRS/Female	SPECIMEN DATE	:22/Jun/2021 09:04AM
PATIENT ID	:80366	SPECIMEN RECEIVED	:22/Jun/2021 09:12AM
REFERRED BY	:Dr. MEDIWHEEL	REPORT DATE	:22/Jun/2021 01:11PM
CENTRE NAME	:ONEPLUS ULTRASOUND LAB	LAB NO.	:012106220005

Test Name	Result	Unit	Ref. Range
Total Leucocyte Count	6510	/cumm	4000-10000
<u>Differential leucocyte count</u>			
Neutrophils	55.3	%	40-80
Lymphocyte	32.50	%	20-40
Monocytes	7.30	%	2-10
Eosinophils	4.7	%	1-6
Basophils	0.2	%	0-2
RBC Count	4.54	million/cumm	3.8-4.8
PCV(Hematocrit)	38	%	36-46
MCV	83.7	fL	83-101
MCH	25.5	Pg	27-32
MCHC	30.5	G/dL	32-35
Platelet count	264000	/cumm	150000-450000
RDW-CV	15.2	%	11.4-14.0
ESR(WESTEGRENs METHOD)	15	mm/1hr	<20


BIOCHEMISTRY

<u>Blood sugar fasting</u>	93	mg/dL	70-110
<u>Bun (blood urea nitrogen)</u>	12.60	mg/dl	7-18.7
<u>Uric acid, serum</u>	4.6	mg/dl	2.4-5.7
<u>Creatinine, serum</u>	0.83	mg/dl	0.60-1.1

LFT(LIVER FUNCTION TEST)

Bilirubin Total	0.65	mg/dl	0.1-1.2
Bilirubin Conjugated	0.34	mg/dl	0-0.4
Bilirubin Unconjugated	0.31	mg/dl	up to 0.7
SGOT (AST)	23	U/L	0-31
SGPT (ALT)	28	U/L	<34
Alkaline phosphatase	108	U/L	64-306
Gamma glutamyl transpeptidase	27	U/L	9-39

Checked By.


DR. NITIN AGARWAL
MBBS,MD(PATHOLOGIST)

47, Harsh Vihar, Pitampura, Delhi-34 ☎ 011-4248 0101, 9599913051

✉ Email: oneplusul@gmail.com 🌐 www.oneplusul.in

Page 2 of 6



NAME	:Mrs. NISHA GUPTA	Barcode No	:10099077
AGE/GENDER	:31 YRS/Female	SPECIMEN DATE	:22/Jun/2021 09:04AM
PATIENT ID	:80366	SPECIMEN RECEIVED	:22/Jun/2021 09:12AM
REFERRED BY	:Dr. MEDIWHEEL	REPORT DATE	:22/Jun/2021 01:11PM
CENTRE NAME	:ONEPLUS ULTRASOUND LAB	LAB NO.	:012106220005

Test Name	Result	Unit	Ref. Range
Total Protein	6.7	gm/dl	6.40 - 8.20
Albumin	3.9	g/dL	3.5-5.5
Globulin	2.80	gm/dl	1.8-3.4
Albumin/Globulin Ratio	1.39		1.10 - 2.50

LIPID PROFILE

Cholesterol	203	mg/dl	50-240
Triglycerides	73	mg/dL	25-150
HDL Cholesterol	45	mg/dL	30 - 70
LDL cholesterol	143	mg/dL	< 130
VLDL cholesterol	14.6	mg/dL	5-40
Cholesterol/HDL Ratio	4.5		Low Risk 3.3-4.97 Average Risk 4.4-7.1 Moderate Risk 7.1-11.0 High Risk >11.0
LDL/HDL Ratio	3.2		0 - 3.55

According to ATP III and NCEP guidelines

Parameter	Normal	Desirable	Borderline	High
Total cholesterol	<200	200-239		240
Triglycerides	<150	150-199	200-499	500
LDL	Optimal <100 Near Optimal 100-129	130-159	160-180	190
HDL	<40 : LOW 60 : HIGH			

ENDOCRINOLOGY

THYROID PROFILE(T3,T4,TSH)

Triiodothyronine total [t3]	0.86	ng/dl	0.52-1.9
Thyroxine total [t4]	7.90	µg/dl	4.8-11.6
TSH (Thyroid Stimulating Hormone)	6.60	µIU/ml	0.25-5.0

Checked By.

DR. NITIN AGARWAL
M.B.B.S., MD
DMCR
DR. NITIN AGARWAL
MBBS,MD(PATHOLOGIST)



NAME	:Mrs. NISHA GUPTA	Barcode No	:10099077
AGE/GENDER	:31 YRS/Female	SPECIMEN DATE	:22/Jun/2021 09:04AM
PATIENT ID	:80366	SPECIMEN RECEIVED	:22/Jun/2021 09:12AM
REFERRED BY	:Dr. MEDIWHEEL	REPORT DATE	:22/Jun/2021 01:11PM
CENTRE NAME	:ONEPLUS ULTRASOUND LAB	LAB NO.	:012106220005

Test Name	Result	Unit	Ref. Range
-----------	--------	------	------------

AGE WISE VARIATION IN TSH

AGE	TSH(μIU/ml)	AGE	TSH(μIU/ml)
1-4 weeks	1.00 - 19.0	16-20 yrs	0.25 - 5.0
1-12 mths	1.70 - 9.1	21 - 80 yrs	0.25 - 5.0
1-5 yrs	0.80 - 8.2	I st trimester	0.25 - 5.0
6-10 yrs	0.25 - 5.0	II nd trimester	0.50 - 5.0
11-15 yrs	0.25 - 5.0	II rd trimester	0.4 - 6.0

Reference ranges - Interpretation of Diagnostic tests - (Jacques Wallach)

1. Primary hypothyroidism is accompanied by depressed serum T3 and T4 values and elevated serum TSH level.
2. Primary hyperthyroidism is accompanied by elevated serum T3 and T4 levels along with depressed TSH values.
3. Slightly elevated T3 levels may be found in pregnancy and estrogen therapy, while depressed levels may be encountered in severe illness, renal failure and during therapy with drugs like propranolol and propyl thiouracil.
4. Although elevated TSH levels are nearly always indicative of primary hypothyroidism, and may be seen in secondary thyrotoxicosis

CLINICAL PATHOLOGY

URINE ROUTINE


Physical examination

Quantity	20	ML
Colour	PALE YELLOW	
Transparency	SLIGHTLY TURBID	CLEAR
Sp.gravity	1.015	1.010-1.030
pH	6.00	
Reaction	ACIDIC	ACIDIC

Chemical examination

Urine protein	NIL	NIL
Urine sugar	NIL	NIL
Bilirubin, urine	NEGATIVE	NEGATIVE
Urobilinogen	NORMAL	NORMAL
Ketones	NEGATIVE	NEGATIVE

Checked By.


DR. NITIN AGARWAL
M.B.B.S., MD MBBS,MD(PATHOLOGIST)
DMC/R/01436

47, Harsh Vihar, Pitampura, Delhi-34 ☎ 011-4248 0101, 9599913051

✉ Email: oneplusul@gmail.com 🌐 www.oneplusul.in

Page 4 of 6



NAME	:Mrs. NISHA GUPTA	Barcode No	:10099077
AGE/GENDER	:31 YRS/Female	SPECIMEN DATE	:22/Jun/2021 09:04AM
PATIENT ID	:80366	SPECIMEN RECEIVED	:22/Jun/2021 09:12AM
REFERRED BY	:Dr. MEDIWHEEL	REPORT DATE	:22/Jun/2021 01:11PM
CENTRE NAME	:ONEPLUS ULTRASOUND LAB	LAB NO.	:012106220005

Test Name	Result	Unit	Ref. Range
Microscopic examination			
Pus cells.	2-3	/HPF	1-2
Epithelial cells	8-10	/HPF	0-5
R.B.C.	NIL	/HPF	NIL
Casts	NIL	/HPF	NIL
Crystals	NIL	/HPF	NIL
Bacteria	NIL	/HPF	NIL
Others.	NIL		NIL

Checked By.

DR. NITIN AGARWAL
MBBS, MD (Path)
MNC/19143

DR. NITIN AGARWAL
MBBS, MD (PATHOLOGIST)

47, Harsh Vihar, Pitampura, Delhi-34 ☎ 011-4248 0101, 9599913051

✉ Email: oneplusul@gmail.com 🌐 www.oneplusul.in

Page 5 of 6

* Clinical correlation is essential for final diagnosis. * If test results are unsatisfactory please contact personally or on phone.
* This report is for perusal of doctors only. * All disputes are subject to Delhi jurisdiction only. * Not for medico legal case.
* All congenital anomalies in a foetus may not be diagnosed in routine obstetric ultrasound.



Dr. Nitin Agarwal
Pathologist & Director
Ex. Sr. Res. MAMC
& Lok Nayak Hospital
Ex. Chief of Lab Dr. Lal Path labs.

Dr. Pooja (Garg) Agarwal
Radiologist & Director
(MAMC & Lok Nayak Hospital)



NAME	:Mrs. NISHA GUPTA	Barcode No	:10099077
AGE/GENDER	:31 YRS/Female	SPECIMEN DATE	:22/Jun/2021 09:04AM
PATIENT ID	:80366	SPECIMEN RECEIVED	:22/Jun/2021 09:12AM
REFERRED BY	:Dr. MEDIWHEEL	REPORT DATE	:22/Jun/2021 01:15PM
CENTRE NAME	:ONEPLUS ULTRASOUND LAB	LAB NO.	:012106220005

CYTOLOGY

PAP SMEAR

STATEMENT OF ADEQUACY : Satisfactory for evaluation.

GENERAL CATEGORISATION : Benign cellular changes due to inflammation.

DESCRIPTIVE DIAGNOSIS

1. Superficial squamous cells with intermediate and occasional metaplastic squamous cells.
2. Moderate to dense polymorphonuclear leucocytes.
3. No epithelial cell abnormality.

COMMENTS :

NEGATIVE FOR INTRAEPITHELIAL LESION/MALIGNANCY.

P/48/21

*** End Of Report ***

Checked By.

DR. NITIN AGARWAL
MBBS, MD (Path)
22/06/21
DR. NITIN AGARWAL
MBBS, MD (PATHOLOGIST)

47, Harsh Vihar, Pitampura, Delhi-34 ☎ 011-4248 0101, 9599913051

✉ Email: oneplusul@gmail.com 🌐 www.oneplusul.in

Page 6 of 6

• Clinical correlation is essential for final diagnosis. • If test results are unsatisfactory please contact personally or on phone.
• This report is for perusal of doctors only. • All disputes are subject to Delhi jurisdiction only. • Not for medico legal case.
• All congenital anomalies in a foetus may not be diagnosed in routine obstetric ultrasound.