

Mr. Anubrat Sharma

Age - 35/M



wt - 80kg,

HT - 164

BMI - 29.8

Veg. egg vegetarian

58.96 kg IBW.

1800 kcal

7:30 → water - 2 glasses

8 AM - tea + Biscuits (2)

9 AM - upma / daliya / oats / Sattu / sprouts / egg white (2)

milk / butter milk / coconut water

11 AM - fruits (100gm)

11 AM -

1-3 PM -

roti - (3) + dal + green leafy veg + salad (200gm)
curd.

6 PM - flax seed, dry fruits, butter milk, coconut water

7-10 PM - glass 3 AM/07

10:30 PM - milk

Dr. Swathi
25/03/23

TO BOOK AN APPOINTMENT

0731 4870 738

FOR SAMPLE COLLECTION

9893 110 657

Licenses: Gurjar Hospital & Endoscopy Centre Pvt. Ltd.

1, Scheme No. 44-B, Siddarth Nagar, BhanwarKuan Square,

A. B. Road, Indore (M.P.) 452 001

E-mail : ab.road@apolloclinic.com Visit us at : www.apolloclinic.com

Consultations | Diagnostics | Health Checks | CT Scan | Sonography | Foetal Sonography | Health@Home | Diabetes Care | Dentistry | Minor Procedures | Physiotherapy | Pharmacy

25/03/23

Mr. Anubrat Sharma

Age - 35/m.



Dislodgement of crown

Root
re-restoration

Dental check done

A handwritten signature in black ink, appearing to be 'J' followed by a flourish.

Licensee: Gurjar Hospital & Endoscopy Centre Pvt. Ltd.

1, Scheme No. 44-B, Siddarth Nagar, BhanwarKuan Square,

A. B. Road, Indore (M.P.) 452 001

E-mail : ab.road@apolloclinic.com Visit us at : www.apolloclinic.com

TO BOOK AN APPOINTMENT

0731 4870 738

FOR SAMPLE COLLECTION

9893 110 657

Patient Name:	MR.ANUBHAT SHARMA	MR NO:	FABR.0000003103
VISIT NO. :	FABROPV0000003560	Age / Gender :	35Y / M
Conducted by :	DR PARAG CHANDAK.	Conducting Date :	25/03/2023

ECG REPORT

- The rhythm is sinus, Normal
- Heart Rate is 65 beats per minute.
- Normal P -47, R-267, T-71axis.
- Normal PRI -140 ms, QRS-86ms, QT -414ms, QTC- 430 uration
- No Pathological Q wave or ST-T changes seen.
- No evidence of chamber hypertrophy or enlargement seen.

IMPRESSION . NORMAL STUDY

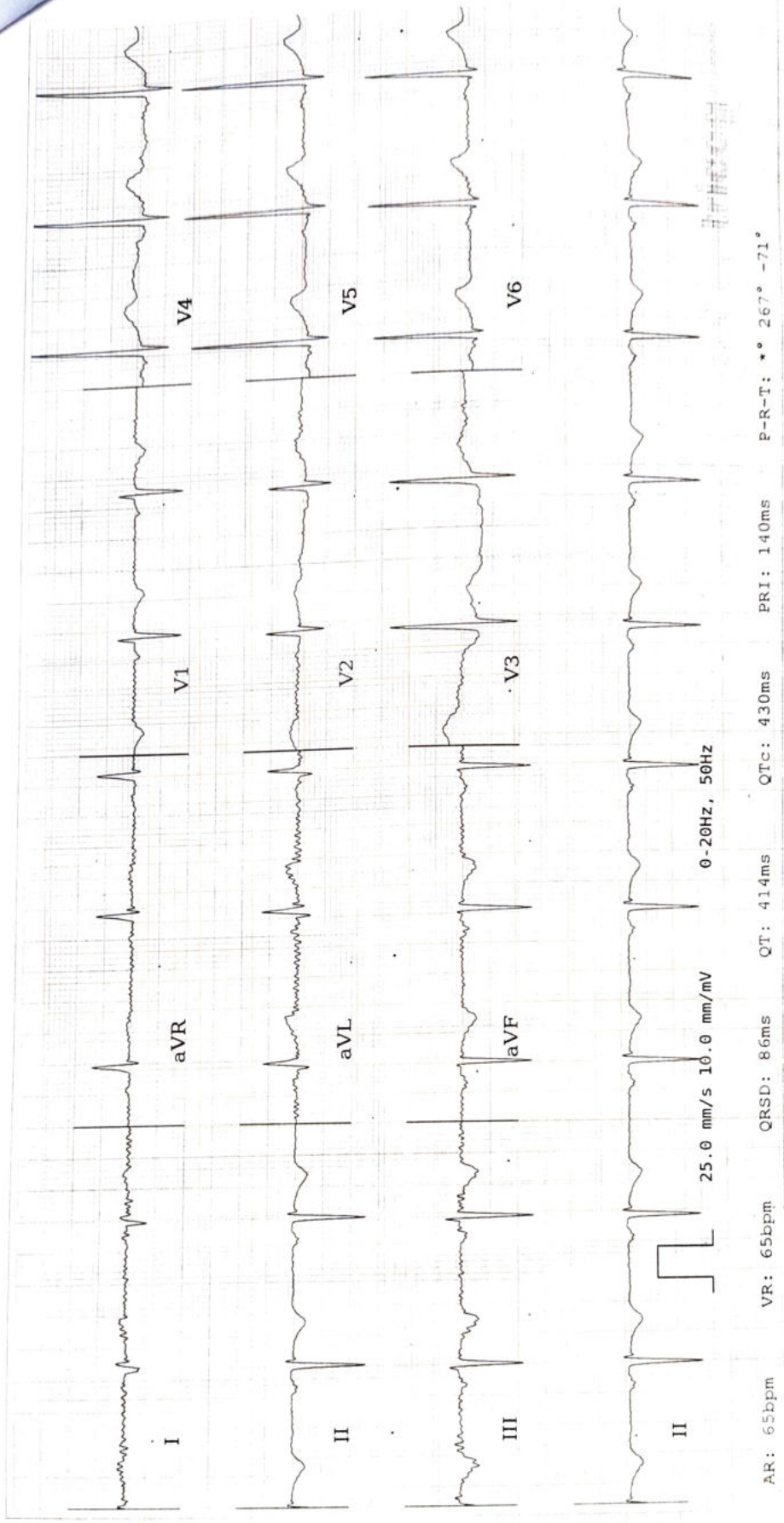


DR. PARAG CHANDAK



Age / Gender: 35/Male
Patient ID: 0000003103

Date and Time: 25th Mar 23 1:04 PM



ECG Within Normal Limits: Limb Lead Reversal Suspected, Sinus Rhythm. Please correlate clinically.

Disclaimer: Analysis in this report is based on ECG alone and should only be used as an adjunct to clinical history, symptoms and results of other invasive and non-invasive tests and must be interpreted by a qualified physician.

Patient's Name	MR ANUBRAT SHARMA				
Age / Sex	35 Yrs. /M	MOB NO	8770795849	Report Date:	25.03.2023
Ref. By	SELF			MR NO	FABR.0000003103

ECHOCARDIOGRAPHY

Study done in various view shows normal size left atrium. Pulmonary veins join LA.

Inter arterial septum is intact. Right atrium is normal size.

Tricuspid valves is structurally & functionally normal. Right ventricle is placed anteriorly & is normal. MPA is normal. Pulmonary valve cups are normal.

Mitral valve cups are normal in thickness & excursion.

M.V. orifices area during diastolic is normal. MV closure is complete.

Aortic valve is normal with normal opening.

LV wall thickness is normal. Segment LV contractility is fair thus over LVEF 65 %.

Pericardium is normal.

No visible vegetation/clots/intracardiac mass.

IMPRESSION:- 1. Normal LV function.

2. No RWMA LVEF 65 %

3. Normal Cardiac Valves.

4. Normal size cardiac chambers.

5. No LVDD.

DR VATSAL KAYAL

(DM CARDIOLOGY)

Licensee: Gurjar Hospital & Endoscopy Centre Pvt. Ltd.

1, Scheme No. 44-B, Siddarth Nagar, BhanwarKuan Square,
A. B. Road, Indore (M.P.) 452 001

E-mail : ab.road@apolloclinic.com, Visit us at : www.apolloclinic.com

TO BOOK AN APPOINTMENT

 0731 4870 738

FOR SAMPLE COLLECTION

 9893 110 657

	Observed values	Normal values
MITRAL VALVE ANTERIOR LEAFLET		
Structure	Normal	
Excursion		80-150
E.F. Slope		
E.P.S.S.		2-7
B.Bump		
Posterior Leaflet		
Structure	Normal	
Excursion	Normal.	
TRICUSPID VALVE		
	Normal	
PULMONARY VALVE		
	Normal	
AORTIC VALVE		
Structure	Normal	
Cusp Opening		
Closure line	Central	
DIMENSION		
LVID Diastole	46.0 mm	37-56 mm (FLAT) 35-57 mm (LEFT LAT.)
LVID SYSTOLE	29.0 mm	24-42 mm
RVID		7-23 mm (FLAT) 9-26 mm (LEFT LAT.)
IVS Thickness	9.0 mm	6-11
LVPW	9.0 mm	6-11 mm
LA	31.0 mm	19-40 mm
AO	26.0 mm	20-37 mm

LV function

LVEF 65 %

DOPPLER STUDY

	Peak Velocity (m/sec)	Peak PG (mm/Hg)	Regulation
MV	Normal	Normal	Trivial
AV	Normal	Normal	Absent
PV	Normal	Normal	Absent
TV	Normal	Normal	Trivial


CERTIFICATE OF MEDICAL FITNESS

This is to certify that I have conducted the clinical examination

of Anubrat Sharma on 25/3/22

After reviewing the medical history and on clinical examination it has been found that he/she is

	Tick
<ul style="list-style-type: none"> • Medically Fit 	✓
<ul style="list-style-type: none"> • Fit with restrictions/recommendations <p>Though following restrictions have been revealed, in my opinion, these are not impediments to the job.</p> <p>1.....</p> <p>2.....</p> <p>3.....</p> <p>However, the employee should follow the advice/medication that has been communicated to him/her.</p> <p>Review after _____</p>	
<ul style="list-style-type: none"> • Currently Unfit. Review after _____ recommended 	
<ul style="list-style-type: none"> • Unfit 	

Dr. 
Medical Officer
The Apollo Clinic,
DR. PARAG CHANDAK
MBBS, MD (MEDICINE)
Reg. No. 18725

This certificate is not meant for medico-legal purposes

Patient Name : Mr. ANUBRAT SHARMA
UHID/MR No. : FABR.0000003103
Visit Date : 25-03-2023 11:22
Sample Collected on : 25-03-2023 13:17
Ref Doctor : SELF
Package Name : ARCOFEMI - MEDIWHEEL - FULL BODY ANNUAL PLUS
 MALE - 2D ECHO - PAN INDIA - FY2324
Emp/Auth/TPA ID : MR.VISHAL GUPTA
Sponsor Name : ARCOFEMI HEALTHCARE LIMITED


DEPARTMENT OF LABORATORY MEDICINE

TEST NAME	RESULT	BIOLOGICAL REFERENCE INTERVALS	UNITS
GLUCOSE - (POST PRANDIAL) GLUCOSE POST PRANDIAL, Method: GOD-PAP	122.3	Normal: <140	mg/dl

End of the report

Results are to be correlated clinically

Lab Technician / Technologist
GHI0039


 DR. S.K SHARMA (V)
 MBBS MD
 MD PATHOLOGY

Mr. Anubrat Sharma
Age - 35/M



wt - 80kg,
HT - 164
BMI - 29.8
veg - eggitarian
58.96kg IBW.
1800 kcal

- 7:30 → water - 2 glasses
- 8 AM - tea + Biscuits (2)
- 9 AM - upma/dalia / oats / Sattu / sprouts / egg white (2)
milk / butter / milk / coconut water
- 10-11 AM - fruits (100gm)
- 11 AM - roti - (3) + dal + green leafy veg + Salsal (200gm)
Aard.
- 1-3 PM -
- 5-6 PM - for Seed, dry fruits, butter milk, Coconut water
- 7-10 PM - गणेश जी मंत्राय
- 10:30 PM - milk

Dr. Swathi
25/03/23

Licensee: Gurjar Hospital & Endoscopy Centre Pvt. Ltd.
1, Scheme No. 44-B, Siddarth Nagar, BhanwarKuan Square,
A. B. Road, Indore (M.P.) 452 001
E-mail : ab.road@apolloclinic.com Visit us at : www.apolloclinic.com


TO BOOK AN APPOINTMENT
0731 4870 738
FOR SAMPLE COLLECTION
9893 110 657

946 Anubrat Sharma



C/S by Dr A. VERMA
(MS ENT)
9575630420

No ENT complaints


 Nose - (E) DNS is spec.
 Ears - B/L TTA intact.
 B/L loss of COL.
 (L) TTA retracted

Rx - Mispay Fluticome Cx
 1 puff BS BY
 nose
 - T. Lecope AD HIS

DR. ANJANEYA VERMA
MS ENT
Reg. No. MP-9152

Patient's Name	MR ANUBRAT SHARMA				
Age / Sex	35 Yrs. / M	Mob.No.	8770795849	Report Date:	25.03.2023
Ref. By	SELF			MR. NO.	FABR.0000003103

SONOGRAPHY WHOLE ABDOMEN

Liver is borderline enlarged in size (16.2 cm in midclavicular span) with moderate generalized increase in parenchymal echogenicity s/o grade II fatty infiltration. Portal vein is normal in caliber with normal hepatopetal flow. Intra hepatic biliary radicles and CBD are undilated. No focal lesion is seen.

Gall bladder is thin walled, physiologically distended, nonlithiasic. Contents are anechoic.

Pancreas is normal in size and echotexture .Pancreatic duct is undilated.

Spleen is normal in size (7.8 cms) and shows normal echogenicity.

Both kidneys are normal in size, shape and position. Renal contours are smooth, parenchymal echogenicity is normal. Both renal pelvi-calyceal systems and both ureters are undilated. Corticomedullary differentiation is maintained.

Right kidney - 10.6 X 4.0 cms.

Left kidney -9.8 x 4.4 cms.


No ascitis.

Urinary bladder has thin and smooth walls, Contents are anechoic.

Post void residual urine is insignificant,approx 10 cc.

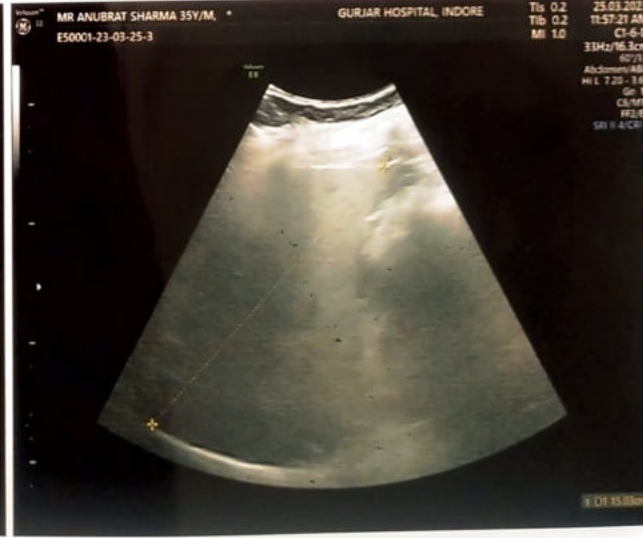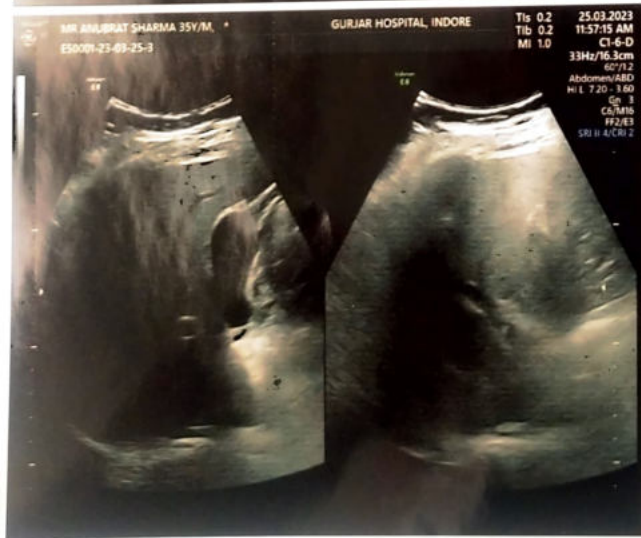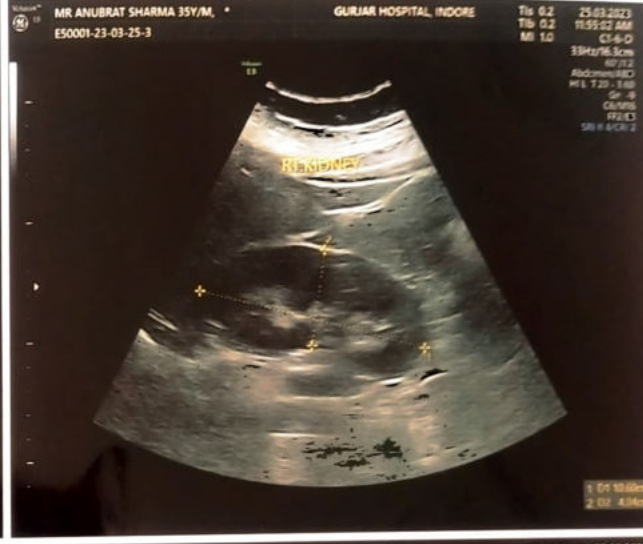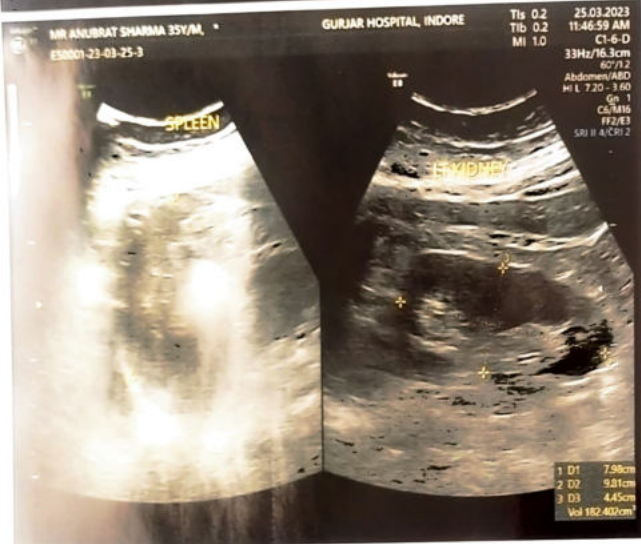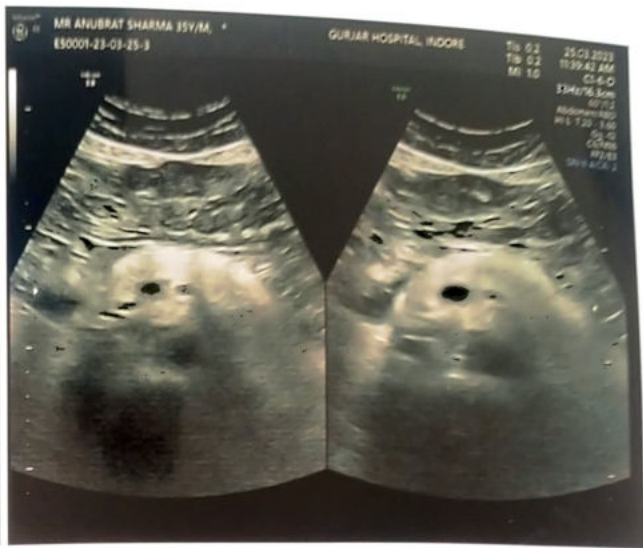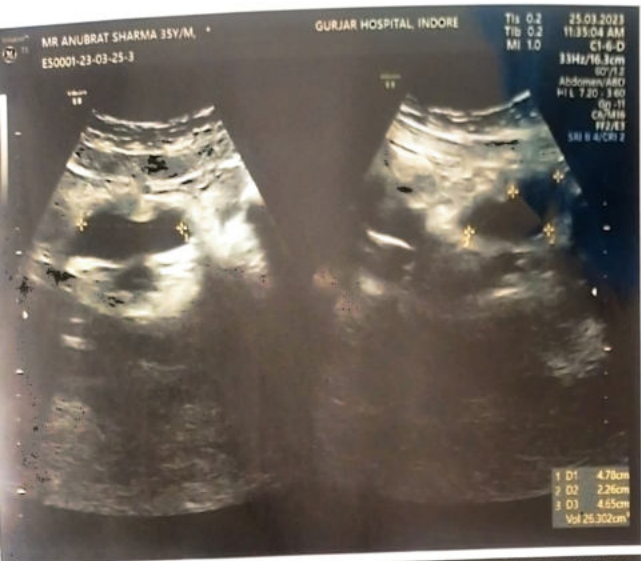
Prostate is mildly enlarged in size, with smooth outlines and shows homogenous echotexture . It measured 2.6 x 3.2 x 3.0 cms (Weight approx 13 grms) .

IMPRESSION : Borderline hepatomegaly with grade II fatty infiltration.

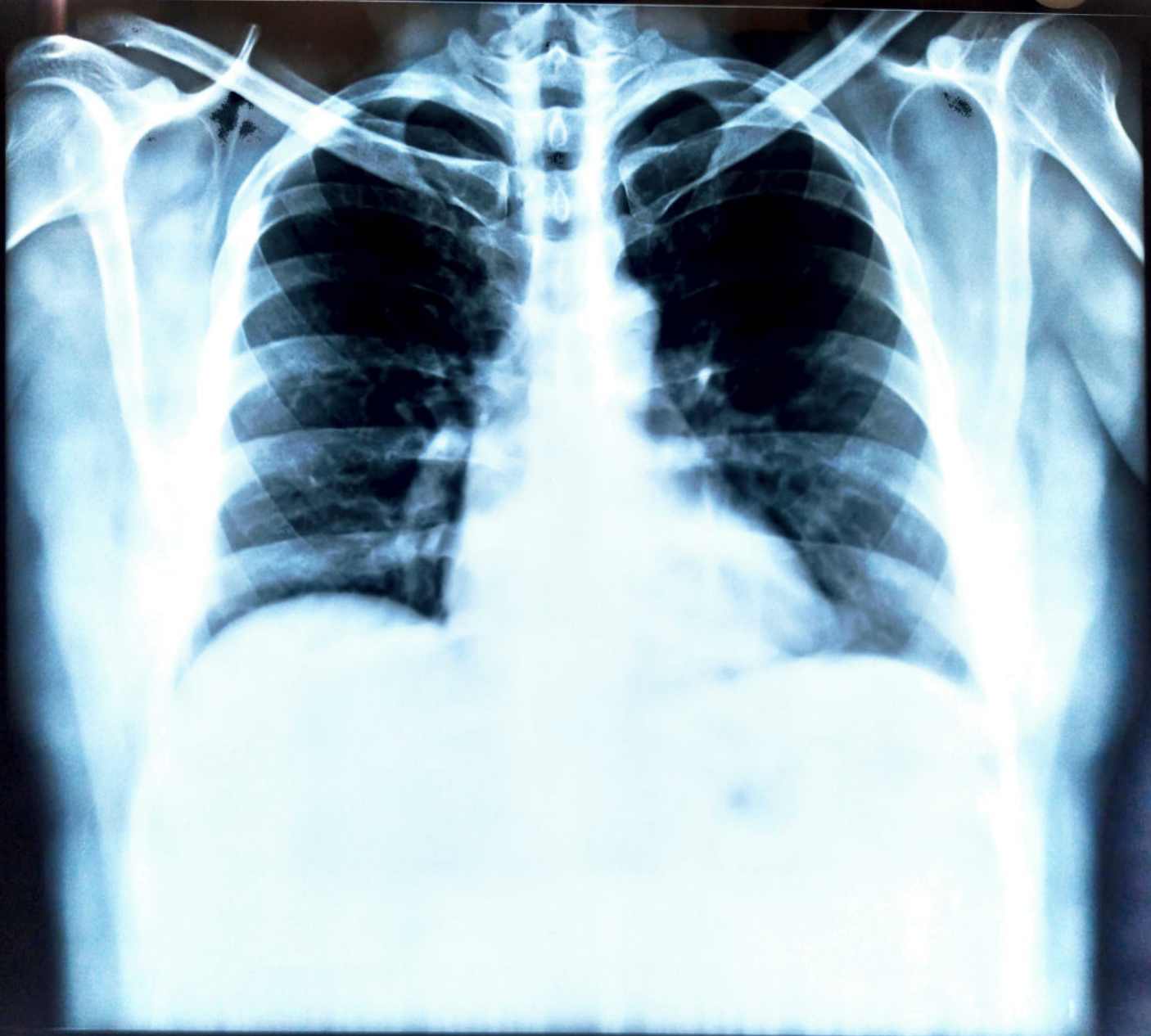
DR. NEETU BALWANI
M.B.B.S. D.N.B.
REG.NO. -9035

APOLLO CLINIC, INDORE

MR ANUBRAT SHARMA 35Y/M



R



Mr. Anubrat Sharma 36Yrs 25032303 M CHEST PA 25-Mar-23 10:43 AM
APOLLO CLINIC, INDORE [M.P.]

Name	Mr. Anubrat Sharma 36Yrs				
Age/Sex	36Y/M	Patient ID	25032303	Referred By	DR.P.CHANDAK
Study Date	2023-03-25 10:43	Report Date	2023-03-25 10:54		

X - RAY CHEST PA VIEW

FINDINGS :-

Mildly bilateral prominent hila with prominent bronchovascular markings in bilateral lung fields .

Rest of lung fields are normal

Trachea is in midline.

Cardiac silhouette maintained.

Both CP angles are clear.

IMPRESSION :-

Mildly bilateral prominent hila with prominent bronchovascular markings in bilateral lung fields .

For clinical correlation.



DR. Avinash Rathod
Consultant Radiologist
MBBS,DMRD
Reg No. 201105/1616