



K. Sauthi
Age - 28 Y / F

Date : 24/9/22

Dr. P. Lalitha

Dr. K. Harish

Dr. K. HARISH KATRAGADDA
MBBS, MD,

FCI, DNB, FRCR

Consultant Physician, Radiologist
SENTINI HOSPITALS PRIVATE LTD.,
54-15-5, B & C, Near Vinayaka Theatre
Ring Road, VIJAYAWADA-520 008

Bp = 110/70

- patient come for M.H.C

- No running nose for

7-10 days

sw
by / MAB

(Adm)

10 days x ① T. morbit - fx

0-0-1

Adm



Department Of Laboratory

Date :

Name : Mrs. KURRA SRUTHI	Age /Sex : 28 Y(s)/Female
Bill Date : 24-Sep-2022 09:37 AM	UMR No. : UMR2213291
Rept. Dt : 24-Sep-2022 11:40 AM	Bill No. : BIL22019748
Ref By : Dr.GENERAL HEALTH CHECK UP	Result No : 0 / RES22021044

<u>Parameter</u>	<u>Result</u>	<u>Normal Values</u>
LFT(LIVER FUNCTION TEST)		
Total Bilirubin	: 0.7 mg/dl	0.1 - 1.2 mg/dl
Direct Bilirubin	: 0.2 mg/dl	0.0 - 0.3 mg/dl
Indirect Bilirubin	: 0.5 mg/dl	
SGOT	: 24 IU/L	5 - 55 IU/L
SGPT	: 31 IU/L	5 - 55 IU/L
Alkaline Phosphatase	: 124 IU/L	Adult : 35 - 125 IU/L Children : 125 - 330 IU/L
Total Protein	: 6.4 gm/dl	6.0 - 8.3 gm/dl
Albumin	: 3.4 gm/dl	3.2 - 5.0 gm/dl
Globulin	: 3.0 gm/dl	2.5 - 3.0 gm/dl
A / G RATIO	: * 1.1	1.51 - 1.81
CBC (COMPLETE BLOOD COUNT)		
HAEMOGLOBIN	: 14.8 g/dl	11.5 - 16.0 g/dl
Total WBC Count	: 8,300 cells/cumm	4000 - 11000 cells/cumm
DC COUNT		
Neutrophils	: 70 %	50 - 70 %
Lymphocytes	: 25 %	15 - 40 %
Eosinophils	: 03 %	0 - 7 %
Monocytes	: 02 %	0 - 4 %
Basophils	: 00 %	0 - 1 %
RBC COUNT	: 4.9 millions/cumm	4.5 - 6.5 millions/cumm
PLATELET COUNT	: 2.24 lakhscells/cumm	1.5 - 4.0 lakhscells/cumm

*** End Of Report ***

Lab Tech.

Bio-Chemist

Lab In-Charge

Incharge Pathologist

Correlate Clinically, We use only sterilised disposable syringes & needles.

Discrepancies due to technical or typing errors should be reported within 3 days for correction.

This report is to help you for better management of patient and not valid for medicolegal purpose.



Department Of Laboratory

Date :

Name : Mrs. KURRA SRUTHI	Age /Sex : 28 Y(s)/Female
Bill Date : 24-Sep-2022 09:37 AM	UMR No. : UMR2213291
Rept. Dt : 24-Sep-2022 11:40 AM	Bill No. : BIL22019748
Ref By : Dr.GENERAL HEALTH CHECK UP	Result No : 0 / RES22021044

Parameter	Result	Normal Values
Fasting Blood Sugar	: 90 mg/dl	70 - 110 mg/dl
RFT (RENAL FUNCTION TEST)		
BLOOD UREA	: 18 mg/dl	13 - 45 mg/dl
Serum Creatinine	: 0.9 mg/dl	0.7 - 1.4 mg/dl
LIPID PROFILE		
Fasting Blood Sugar	: 90 mg/dl	70 - 110 mg/dl
Total Cholesterol	: 182 mg/dl	150 - 240 mg/dl
Triglycerides	: 103 mg/dl	50 - 200 mg/dl
HDL Cholesterol	: 39 mg/dl	
LDL Cholesterol	: 123 mg/dl	80 - 160 mg/dl
VLDL	: 20 mg/dl	10 - 50 mg/dl
Cholesterol / HDL ratio	: 4.6	< 6
LDL / HDL	: 3.1	< 4
URINE ROUTINE EXAMINATION		
Sugar	: Nil	
Albumin	: Nil	
Microscopic Examination		
Pus cells	: 1-2 /HPF	
Epithelial cells	: 1-2 /HPF	
RBC	: Nil /HPF	
Blood Grouping & Rh Typing	: "O" POSITIVE	

*** End Of Report ***


Lab Tech.


Bio-Chemist

Lab In-Charge

Incharge Pathologist

ID: 23

Name: [redacted]
Age: [redacted]

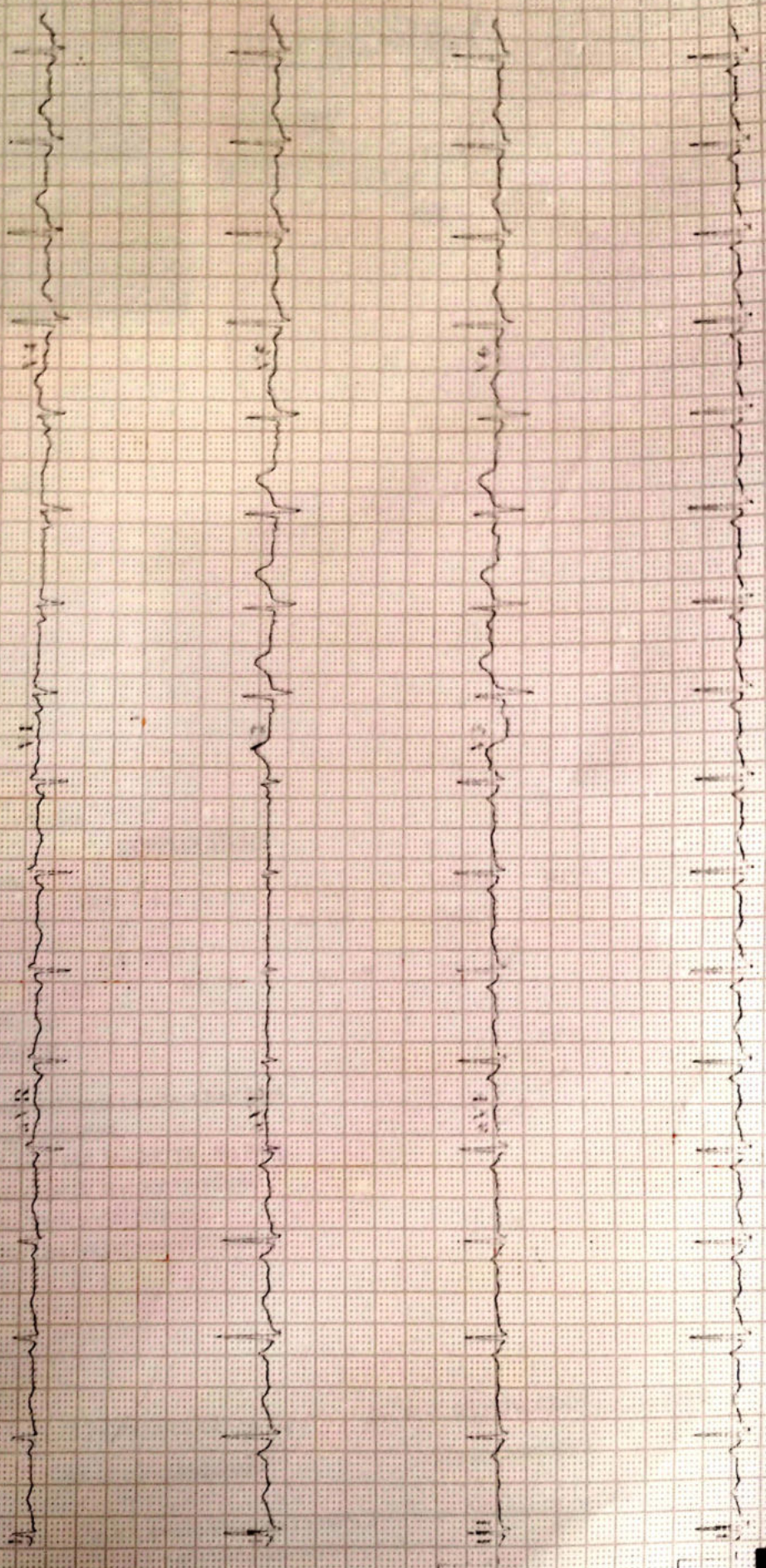
Years: [redacted] Gender: Male

Diagnosis Information:
800: Sinus Rhythm
Normal ECG

mps. K. Sauthi
age 28y1f

HR	:	99	B
p Dur	:	101	ms
pR int	:	126	ms
QRS Dur	:	84	ms
QT/QTc int	:	334/430	ms
P-QRS/T axis	:	69/65/51	°
RV5/SV1 amp	:	0.977/0.402	mV
RV5+SV1 amp	:	1.379	mV
RV6/SV2 amp	:	0.245/0.272	mV

Report Confirmed by:





Sentini Hospitals (P) Limited
Cardiology Department

ECHOCARDIOGRAM REPORT

Name : MRS K.SRUTHI

UMR/OP/IP No : 2213291

Age : 28 Years

Sex : F

Date : 24/09/2022

Echo No : 408

Technician: Srinivas/Chetansai

MITRAL VALVE : Normal
AORTIC VALVE : Normal
TRICUSPID VALVE : Normal
PULMONARY VALVE : Normal
AORTA : 27 mm
LEFT ATRIUM : 34 mm
LEFT VENTRICLE : Normal
RWMA : No LV RWMA
IVS : 10 mm LV IDd : 37 mm
PW : 10 mm LVIDs : 24 mm
LV EF : 64 %
RIGHT ATRIUM : Normal
RIGHT VENTRICLE : Normal
PULMONARY ARTERY : Normal
PULMONARY VEINS : Normal
IAS : Intact
IVS : Intact
PERICARDIUM : Normal
PERICARDIAL EFFUSION : No Effusion

DOPPLER STUDY

MITRAL FLOW : E>A
TRICUSPID FLOW : TRJV- m/s TR Gr: mmHg RVSP: mmHg
AORTIC JET VELOCITY : 1.2 m/s AV Gr: mmHg
PULMONARY JET VELOCITY : 0.8 m/s
COLOUR DOPPLER : 1+ MR No TR No AR No PR
IVC : Normal
SVC : Normal
OTHERS :

CONCLUSION : Normal Sized Cardiac Chambers,
No LV RWMA,
Trivial MR, No AR, TR, No PAH,
Normal LV Systolic Function,
No Pericardial Effusion,
No Clot/Vegetation/Masses.

Dr. MADHURI MD.DM

Dr. A.RAVI KUMAR MD.DM

Dr. P.V. SIVA PRASAD MD. DM. FESC

CONSULTANT CARDIOLOGIST

CONSULTANT CARDIOLOGIST

CHIEF CARDIOLOGIST

Sentini Hospital, Do. No: 54-15-5, B & C, Beside Vinayaka Theatre, Ring Road, Vijayawada-520008
Phone No: 0866-6465111 Email: info@sentinihospitals.com



Department Of Laboratory Date :

Name : Mrs. KURRA SRUTHI	Age /Sex : 28 Y(s)/Female
Bill Date : 24-Sep-2022 09:37 AM	UMR No. : UMR2213291
Rept. Dt : 24-Sep-2022 12:56 PM	Bill No. : BIL22019748
Ref By : Dr.GENERAL HEALTH CHECK UP	Result No : 0 / RES22021072

<u>Parameter</u>	<u>Result</u>	<u>Normal Values</u>
HB A1C	: 5.0 %	Non Diabetic : < 6.0 % Good Control : 6.0 - 7.5 % Fair control : 7.5 - 8.5 % Poor Control : > 8.5 %
Post Prandial Blood Sugar	: 116 mg/dl	80 - 199 mg/dl
TFT (THYROID FUNCTION TEST)		
T3 (TRI IODO THYRONINE)	: 113 ng/dl	80 - 200 ng/dl
T4 (THYROXINE)	: 8.9 ug/dl	5.1 - 14.1 ug/dl
TSH (THYROID STIMULATING HORMONE)	: * 5.84 mIU/l	0.3 - 4.2 mIU/l

*** End Of Report ***


Lab Tech.

Correlate Clinically

Bio-Chemist

Lab In-Charge

Incharge Pathologist

We use only sterilised disposable syringes & needles.

This report is to help you for better management of patient and not valid for medicolegal purpose.

Discrepancies due to technical or typing errors should be reported within 3 days for correction.



K. SRUTHI

Date: 24/09/2022

UMR: 2213291

Age/Sex: 28Y/F

Ref :GENERAL

REAL TIME ULTRASONOGRAPHY OF THE ABDOMEN

LIVER: Normal in size, shape and outline. Parenchymal texture Normal. No focal cystic or solid mass lesion. No intrahepatic biliary dilatation. Intrahepatic portion of IVC is normal.
Portal vein is normal. Porta hepatis is normal.

G. B: Normal.

C.B.D: Not dilated.

PANCREAS: Parenchymal texture normal. No ductal dilatation. No calculi.

SPLEEN: Normal in size & echotexture.

AORTA: Normal.

KIDNEYS: **Right kidney** measures 9.0 x 4.2cm .
Normal in size, shape and outline. Parenchymal texture normal.
Corticomedullary differentiation is well made out and is normal.
No evidence of calculi/ Hydronephrosis.

Left kidney measures 9.4 x 4.5cm
Normal in size, shape and outline. Parenchymal texture normal.
Corticomedullary differentiation is well made out and is normal.
No evidence of calculi / Hydronephrosis.

U.B: Normal.

UTERUS : Normal

OVARIES : Normal

* No evidence of free fluid / lymphadenopathy.

IMPRESSION:

- **NORMAL STUDY.**

- For clinical correlation & follow up.

Dr. PIJAYA RAM MD RD.,
[Consultant Radiologist]