



Patho Treat

DIAGNOSTIC CENTRE & POLYCLINIC

TEST REPORT

Regd. Off : 75, Dum Dum Road, Kolkata - 700 074

Phone No.: (033) 2560 3641 / 3642, (033) 6526 0026, (Infront of Motijheel College of Commerce)

Associate Code : D1

Received On : 26/07/2021

Patient's Name : MR AVIJIT AICH

Reported On : 27/07/2021

ID Number : 10140/G-936

Age/Sex : 31Y/MALE

Referred By : SELF

Sample Source :

ClinicPro/debjan

Page 1 of 1

ULTRASONOGRAPHY OF WHOLE ABDOMEN

LIVER

It is normal(13.3 cm) in size. **Parenchymal echotexture is raised** No focal parenchymal lesion is seen. Intrahepatic biliary radicles not dilated.

PORTA

PV : Normal in diameter with echofree lumen. PV measures 0.9 cm.

CD : Normal in caliber. No calculus is seen upto tracable part. CD measures 0.3 cm.

GALL BLADDER

Gall bladder is normally distended with normal wall thickness. No intraluminal calculus is noted.

PANCREAS

Normal in size, shape & outline. **parenchymal echotexture is raised.** No focal S.O.L. or calcification noted. Main pancreatic duct – not dilated.

SPLEEN

Spleen is normal in size (10.7 cm). Parenchymal echotexture is normal. Splenic vein at its hilum is not dilated.

KIDNEY

Both kidneys are normal in size , shape and outline. Cortical echogenicity appears normal on both sides. Central echocomplexes are normal. Corticomedullary differentiation is maintained. No evidence of stone, hydronephrosis or any mass lesion seen on either side.

DR. S. PAL
M.B.B.S.(KOL),
APUSC-CBET(WBUHS)
CONSULTANT SONOLOGIST

DR. V. J. VIMAL
MD,DMRD
CONSULTANT RADIOLOGIST

Checked by.....

Regd. Off : 75, Dum Dum Road, Kolkata - 700 074

Phone No.: (033) 2560 3641 / 3642, (033) 6526 0026, (Infront of Motijheel College of Commerce)

URETERS

Not visualized hence not dilated.

URINARY BLADDER

Urinary bladder is well distended and normal in wall thickness. No intraluminal pathology or intramural mass lesion seen.

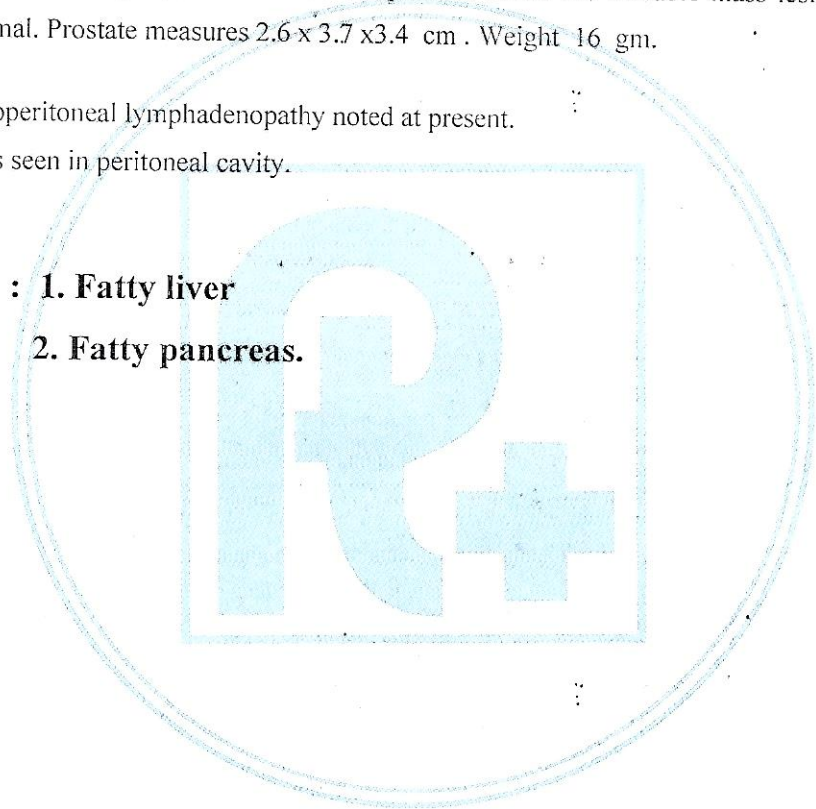
PROSTATE

Prostate is normal in size, shape and echotexture. Capsule is intact. No sizeable mass lesion is seen. Both seminal vesicles appear normal. Prostate measures 2.6 x 3.7 x 3.4 cm. Weight 16 gm.

No appreciable retroperitoneal lymphadenopathy noted at present.

No detectable ascites seen in peritoneal cavity.

IMPRESSION : 1. Fatty liver
2. Fatty pancreas.



DR. S. PAL
M.B.B.S.(KOL),
APUSC-CBET(WBUHS)
CONSULTANT SONOLOGIST

DR. V. J. VIMAL
MD,DMRD
CONSULTANT RADIOLOGIST

Checked by.....