

Medisheel.

आयकर विभाग
INCOME TAX DEPARTMENT



भारत सरकार
GOVT. OF INDIA


TABASSUM SHAKEEL AHMED SHAIKH

GULAMNABI CHAND KARDEKAR

07/03/1973

Permanent Account Number

HHBPS0877J



23122016

Tabassum
Signature

Tabassum

491F

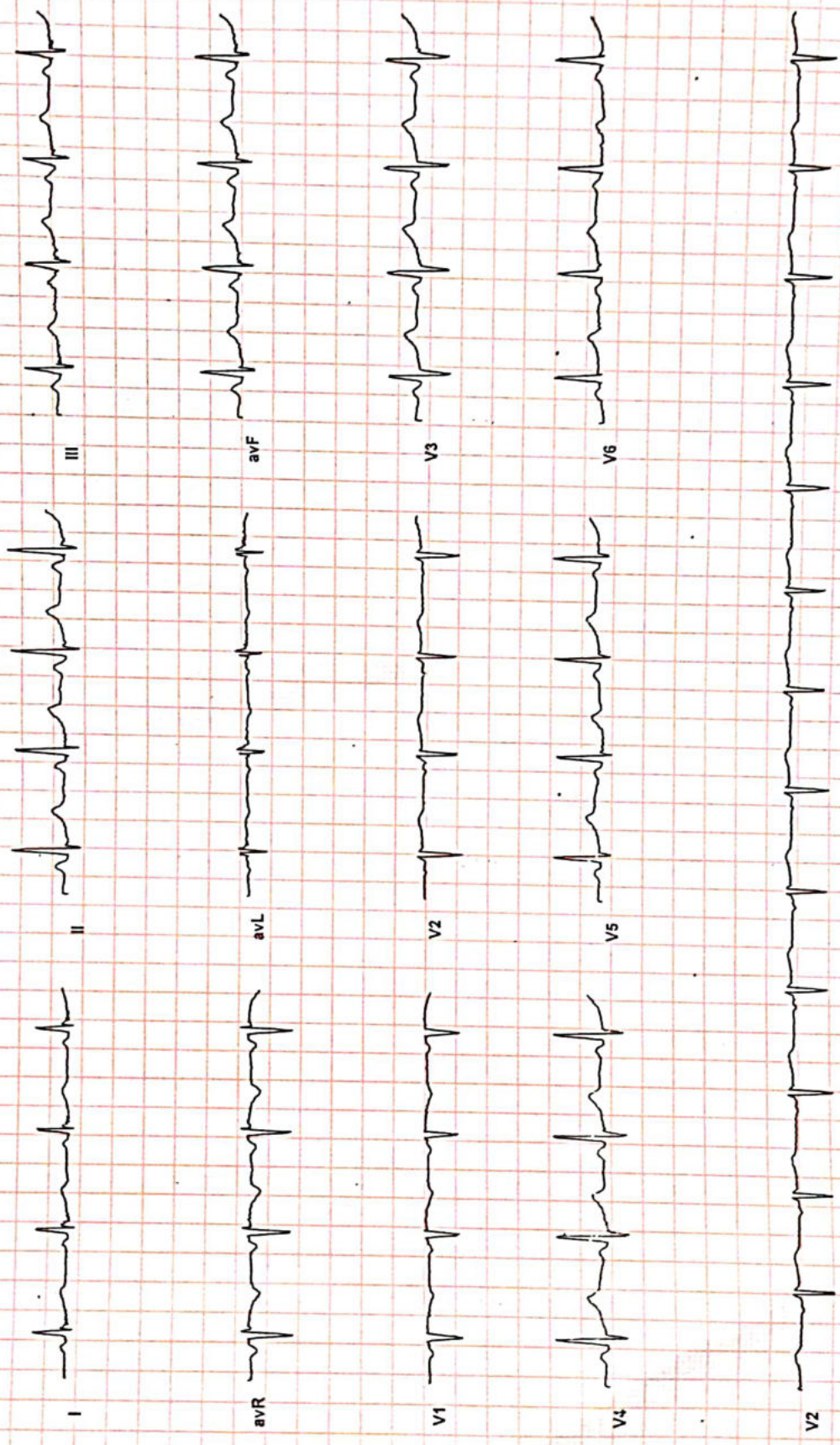
DR. HARICHHABLANI
M.D. (P) (PSP MEDICINE) POSTGRADUATE
FELLOW INTENSIVE CARE
MMC REG. NO. - 91702

'DR. PLUS HEALTHCARE CENTRE'
'KATHANI HEIGHTS', B-WING,
42, MUMBAI CENTRAL (EAST)

1
2
3
4
5
6
7
8
9
10
11
12
13
14
15
16
17
18
19
20
21
22
23
24
25
26
27
28
29
30
31
32
33
34
35
36
37
38
39
40
41
42
43
44
45
46
47
48
49
50
51
52
53
54
55
56
57
58
59
60

ECG

DR PLUS HEALTHCARE CENTRE- MUMBAI CENTRAL
2192 / TABASSUM SHAIKH / 49 Yrs / F
Heart Rate : 81 bpm / Tested On : 24-Sep-22 10:24:44 / HF 0.05 Hz - LF 100 Hz / Notch 50 Hz / Sn 1.00 Cm/mV / Sw 25 mm/s
/ Refd By.: DR.HARI CHHABLANI



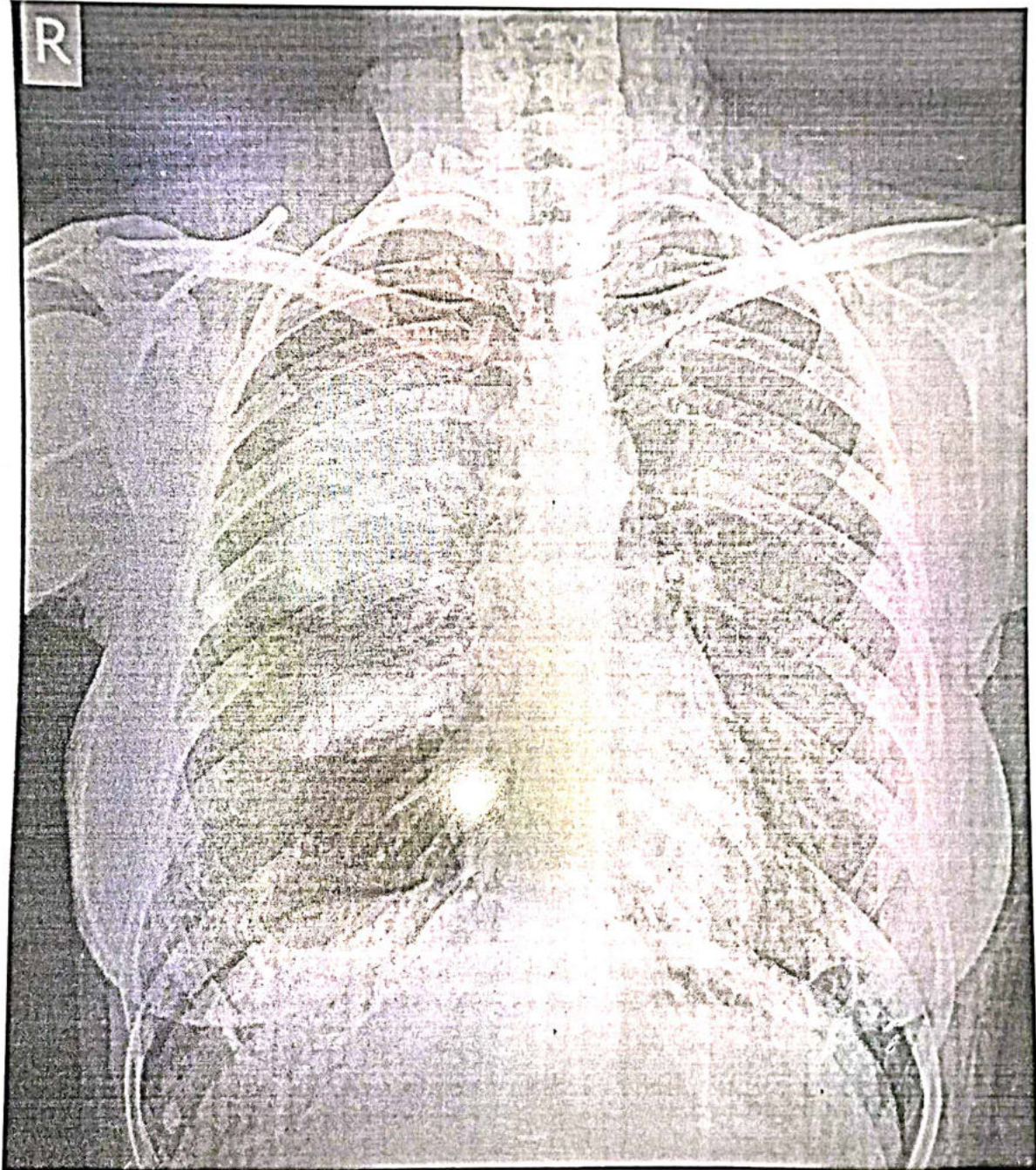
DR. PURVI CHHABLANI
Reported By: DR. PURVI CHHABLANI
Consultant Physician And Intensiv
Reg. No 7780F

WNL

TABASSUM SHAIKH.

49/F

24/09/22





Dr-Plus Healthcare Centre

NATHANI HEIGHTS, B-Wing, Shop No. 42, Ground Floor, Opp. Mumbai Central Station (East), Mumbai - 400 008.

Patient's Name : SHAIKH TABASSUM

Report Date : 24/09/2022

Referred By : SELF

Age : 49 Years

Sex : FEMALE

X- RAY CHEST

BOTH THE LUNG FIELED ARE CLEAR.

THE HILAR SHADOWS APPEAR NORMAL.

THE COSTO-PHRENIC ANGELS ARE CLEAR.

THE CARDIAC SHADOWS APPEAR NORMAL.

THE TRACHEAL IS CENTRAL IN POSITION.

THE BONY CAGE APPEARS NORMAL.

IMPRESSION : THE ABOVE EXAMINATION IS WITHIN NORMAL LIMITS.


DR. A. J. MAZUMDAR

MD. DMRE, MDRD

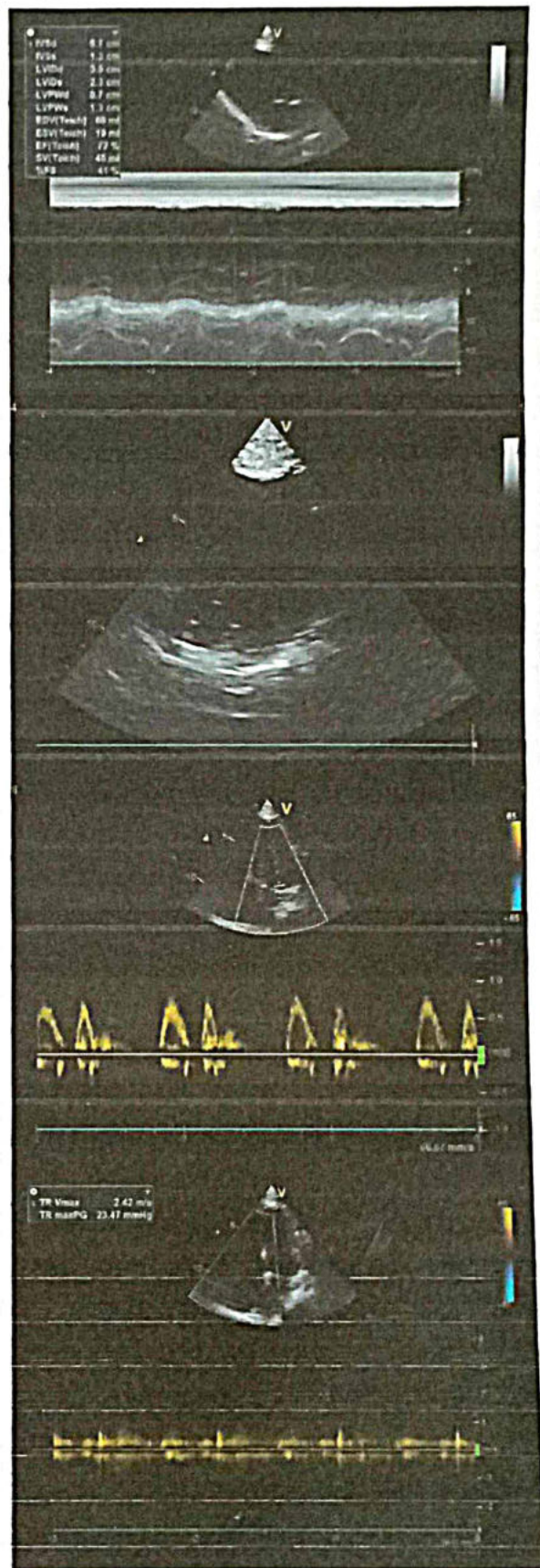
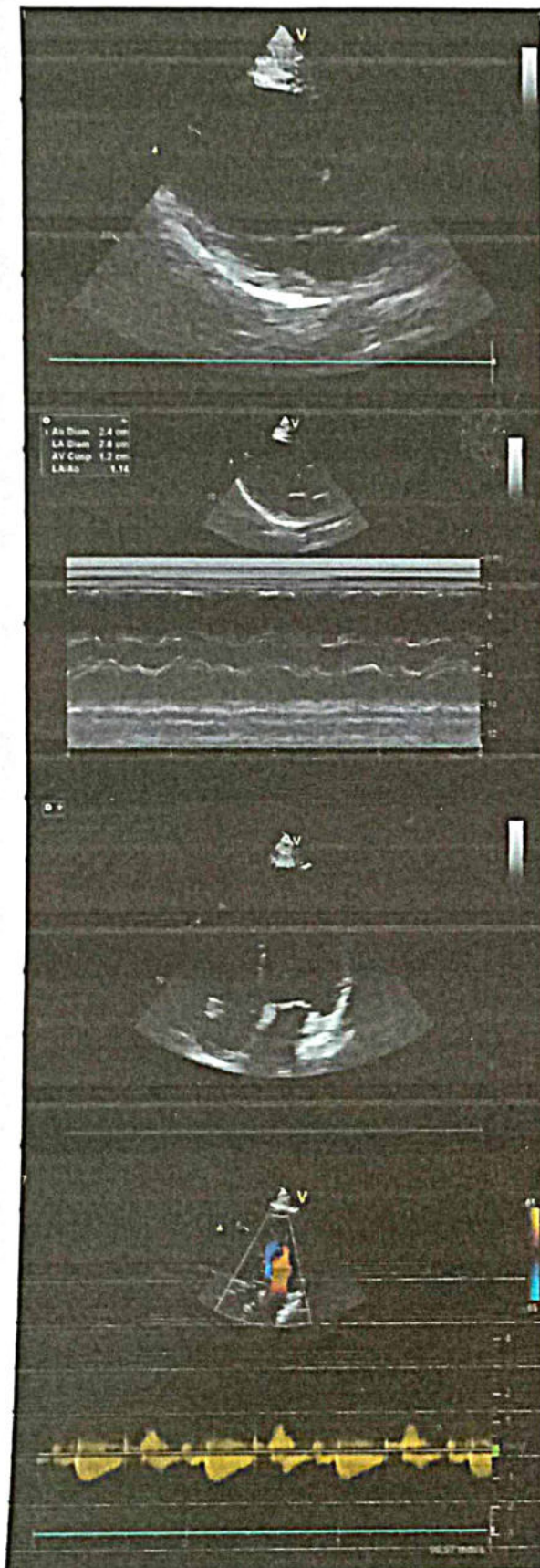
DR. PLUS HEALTHCARE CENTRE
NATHANI HEIGHTS, B-WING,
42, MUMBAI CENTRAL (EAST)

Name **TABASSUM SHAIKH**

Sex **Female**

Age **49**

Date **24/09/2022**





NAME : TABASSUM SHAIKH

49/F

DATE:24/09/2022

REF BY : SELF

2D-ECHO. AND COLOR DOPPLER REPORT

- NORMAL CARDIAC VALVES WITH TRIVIAL TR.
- NORMAL CARDIAC CHAMBERS
- NO E/O REGIONAL WALL MOTION ABNORMALITY. WITH NORMAL LVEF OF 60 %.
- NO E/O PULMONARY HYPERTENSION .PASP 30 mmHg by TR jet.
- NO E/O LEFT VENTRICULAR HYPERTROPHY.
- NO E/O DIASTOLIC DYSFUNCTION.
- NO E/O PERICARDIAL EFFUSION.
- NO E/O INTRACARDIAC CLOT OR VEGETATION
- INTACT IAS / IVS

- **CONVENTIONL DOPPLER :**

E TO A RATIO IS MORE THAN ONE IN LV INFLOW.

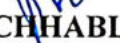
THERE IS NO GRADIENT ACROSS AV, LVOT OR RVOT

PASP FROM TR JET IS 30 mm OF Hg.

- **COLOUR DOPPLER:**

TRIVIAL TR

EF Slope	117	85-120 mm/sec		
Opening Amplitude	23			
Posterior leaflet				
E.P.S.S	02	mm		
Mitral valve prolapse				
Vegetations				
TRICUSPID VALVE	OBSERVED	NORMAL VALUES		
PULMONARY VALVE	OBSERVED	NORMAL VALUES		
EF Slope				
'A' Wave				
Midsystolic notch				
Flutter				
Other Findings				
AORTIC VALVE	OBSERVE	NORMAL VALUES		
Cuspal opening	12	mm		
Closure line	Central			
Eccentricity index	1			
Other Findings				
DIMENSIONS	OBSERVED	NORMAL VALUES		
1. Lvd (Diastolic)	39	26-52		
2. Lvd (Systolic)	28	24-42mm		
3. RVD (Diastolic)	17	7-23mm		
4. IVST (Diastolic)	07	6-11mm		
5. IVST (Systolic)	13			
6. LVPWT (Diastolic)	07	6-11mm		
7. LVPWT (Systolic)	13			
8. Aortic root	24	22-37mm		
9. left Atrium	28	19-40mm		
	STRUCTURE	REGURG GRADING	VELOCITY m/sec	STENOSIS GRADIENT mm/Hg
			Max mean	Peak mean
MITRAL VALVE	NORMAL	0/3	/	/
TRICUSPID VALVE	NORMAL	TRIVIAL	/	/
PULMONARY VALVE	NORMAL	0/4	/	/
AORTIC VALVE	NORMAL	0/4	/	/


DR.P.H.CHHABLANI
 M.B.B.S, DNB.(MEDICINE)
 CONSULTANT PHYSICIAN AND CARDIOLOGIST.

DR. PURVI CHHABLANI

M.B.S. DNB. Medicine
 Consultant Physician And Intensive.

Reg No 77696



Dr-Plus Healthcare Centre

NATHANI HEIGHTS, B-Wing, Shop No. 42, Ground Floor, Opp. Mumbai Central Station (East), Mumbai - 400 008.

Full Name

TABASSUM SHAIKH

49/F

24/09/2022

Life to be assured:

	Type of Test	Actual Reading	Normal Range
1	Fasting Blood Sugar	126.5	70-100 mg%
2	PPBS	145.6	110 TO 140 mg%
3	Total Cholesterol	231.1	120-200 mg%
4	VERY LOW DENSITY LEVEL(VLDL)	30.6	10-30 mg/dl
5	High Density Lipid (HDL)	41.9	40-60 mg%
6	Low Density Lipid (LDL)	158.6	Upto 150
7	S. Triglycerides	154.6	50-150 mg%
8	CHOL/HDL	5.5	Upto 5
9	HDL/LDL	0.2	
10	S. Creatinine	0.8	0.5-1.2 mg%
11	Blood Urea Nitrogen (BUN)	13.6	7-21 mg%
12	BUN/CREAT RATIO	17	
13	S. Proteins	6.8	6.0-7.9 mg%
14	(a) Albumin	3.8	3.5-5.5 mg%
15	(b) Globulin	3.0	2.0-3.5 mg%
16	A/G RATIO	1.2	
17	S. Bilirubin	0.9	0.3-1.3mg%
18	(a) Direct	0.6	0.0-0.8 mg%
19	(b) Indirect	0.3	0.0-0.5 mg%
20	SGOT (AST)	23.5	05-34 IU
21	SGPT (ALT)	28.4	05-40 IU
22	GGTP (GGT)	35.1	05-50 IU
23	SGOT/SGPT	0.8	
24	HBA1C	6.8	UPTO 6.5
25	S. Alkaline Phosphatase	98.9	30-115 IU
26	T3	128.9	80-180ng/dl
27	T4	6.6	4.6-12 ug/dl
28	TSH	2.8	0.4-4.0 mIU/L
29	SERUM URIC ACID	5.5	2.5-7.2mg/dl
30	URINE SUGAR PP	ABSENT	
31	URINE SUGAR FASTING	ABSENT	
32	BLOOD GROUP	"A POSITIVE "	

DR. PRAKASH PATKAR
M.D., M.B. (Pathology)



Dr-Plus Healthcare Centre

NATHANI HEIGHTS, B-Wing, Shop No. 42, Ground Floor, Opp. Mumbai Central Station (East), Mumbai - 400 008.

Full Name of life to be assured:

TABASSUM SHAIKII 49/F

24/09/2022

HAEMOGRAM

		Normal Range			
1.	Red Blood Cell Count	3.8	[M : 4.5 - 5.6 / F : 3.5 - 5.5/cu.mm]		
2.	Hb%	11.2	[M: 14-18 / F : 11-16%]		
3.	Hematocrit	32.2	[M : 40-53 / F : 30-47 %]		
4.	Indices:				
(a)	MCV(Mean Corpuscular Volume)	80.7	[79-101 cu.mi.]		
(b)	MCH(Mean Corpuscular Hb)	28.3	[27-32 pg]		
(c)	MCHC(Mean Corpuscular Hb Concentration)	32.6	[32-38%]		
5.	Morphology				
	Macrocytes :	--	Microcytes: --	Hypochromia:	--
	Piokilocytosis:	--	Anisocytosis: --		
6.	Target cells:	--			
	Spherocytes:	--	Elliptocytes: --		
7.	TOTALW.B.C.Count	6,000	{4000-11000/cu.mm}		
Differential Count0					
a)	Neutrophils :	59	[45 -70%]	c)	Eosinophils: 05 [01 - 06%]
b)	Lymphocytes :	31	[20 - 45%]	d)	Monocytes: 05 [00 - 08%]
e)	Basophils :	00	[00 - 01%]		
8.	Platelets :2.59	1.5-4.5 Lacks/cu.mm			
9.	Erythrocyte Sedimentation Rate: 14	20 mm at end of 1 hour			Method : Westergrens

ROUTINE URINE EXAMINATION (RUA)

1. Physical Examination

(i)	Colour:	PALE YELLOW	(ii)	Sediment:	CLEAR
(iii)	Transparency:	ABSENT	(iv)	Reaction:	ACIDIC
(v)	Specific gravity	1.005			

2. Chemical Examination:

(i)	Protein :	ABSENT	(ii)	Sugar:	ABSENT
(iii)	Bile salt:	ABSENT	(iv)	Bile pigment:	ABSENT

3. Microscopic Examination:

(i)	Red Blood Cells:	ABSENT	(ii)	Epithelial Cells:	ABSENT
(iii)	Crystals:	ABSENT	(iv)	Pus Cells:	02 TO 03/HPF
(v)	Casts:	ABSENT	(vi)	Deposits:	ABSENT
(vii)	Bacteria's :	ABSENT			

DR. AKESH PATKAR
M.D., D.M.B. (Pathology)
Reg. No. 2013/05/1660



ATTACHED TO : Wockhardt Hospital • Saifee Hospital • Apollo Spectra Hospital

NATHANI HEIGHTS, B-Wing, Shop No. 42, Ground Floor, Opp. Mumbai Central Station (East),
Mumbai - 400 008. • Cell : 98206 46163 • E : drharichhablani@gmail.com

PHYSICIAN REPORT

DATE : 24/09/2022

NAME : TABASSUM SHAIKH 49/F

PRESENTING COMPLAINS : K/C/O DM- SINCE 10 YEARS .

K/C/O HTN -SINCE 10 YEARS .

K/C/O HYPERLIPIDEMIA SINCE 10 YEARS.

PAST HISTORY :NIL

FAMILY HISTORY: NOT SIGNIFICANT.

TREATMENT : TRIGLYNASE ,SGLT-2, TELMIKIND, ROSEDAY.

HABITS: NIL

HT.- 150 CM. WT.- 58 Kg. BMI.-25.7

P: 80/MIN ., REGULAR BP: 118/76

EYE EXAMINATION : NEAR VISION -B/E- N6 , DISTANT VISION -B/E -6/6 COLOR VISION : NORMAL

RS: CLEAR

CVS: S1,S2 REGULAR

PA: SOFT

CNS: CLINICALLY NAD

ENT EXAMINATION : WNL


LABS: ATTACHED

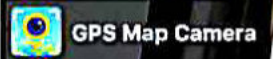
2-D- ECHO : ATTACHED

ECG: ATTACHED

X-RAY : ATTACHED

IMPRESSION : : FIT ON CLINICAL MEDICAL EXAMINATION .


DR. HARI CHHABLANI
M.B.B.S.F.C.C.P.(RESP MEDICINE) PGCHHM, PGDMLS
FELLOW INTENSIVE CARE
MMC REG. NO. - 01702



Mumbai, Maharashtra, India

Shop No 65, Nathani Heights, Marzban Parsi Colony, Dalal Estate, Mumbai Central, Mumbai, Maharashtra 400008, India

Lat 18.968778°

Long 72.819975°

24/09/22 09:12 AM GMT +05:30

