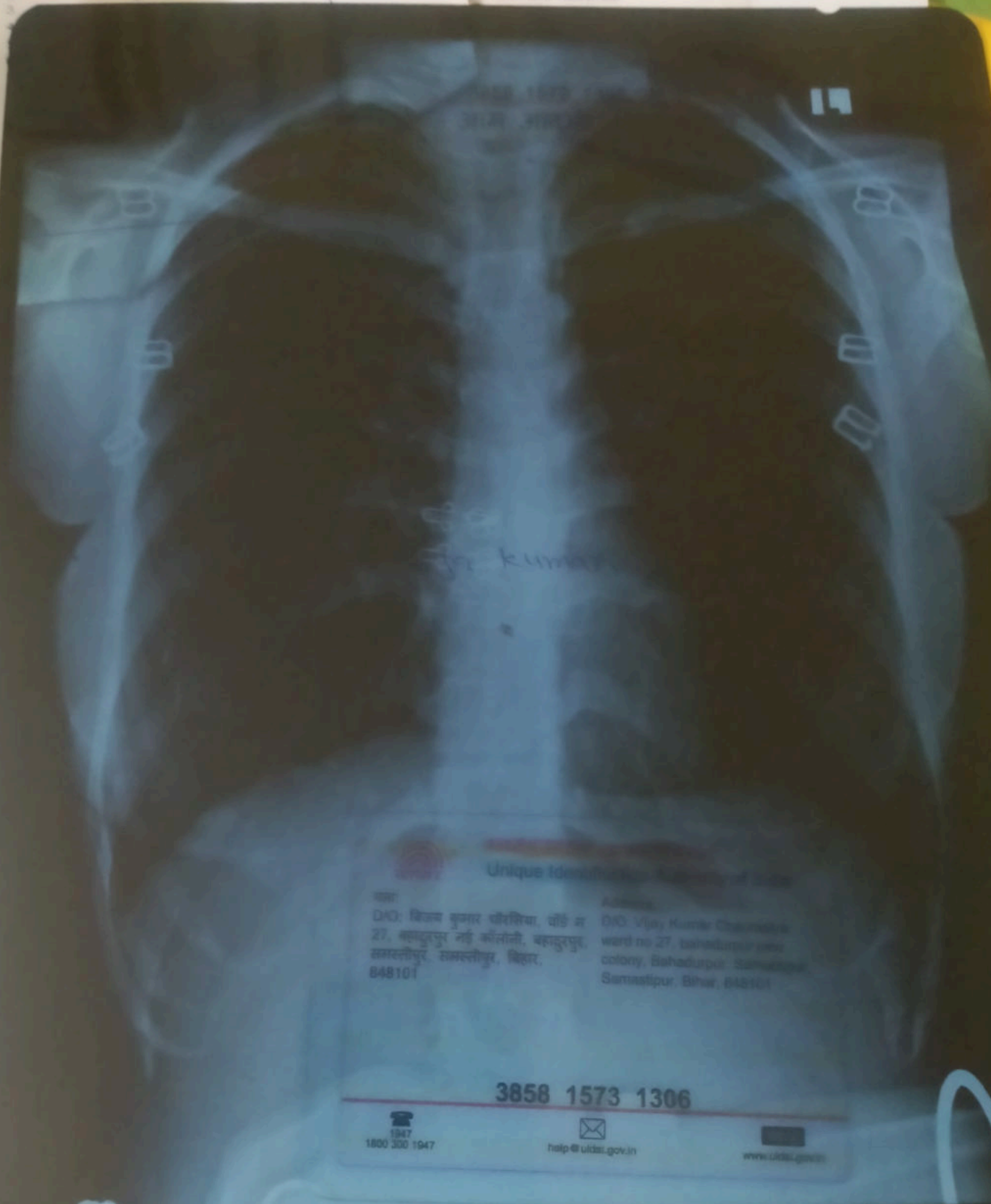


Mod No. 1
Region to be Scanned

Government of India
Ministry of Health & Family Welfare
New Delhi - 110002



Unique Identification - Ministry of India
Name: Dr. विजय कुमार चौधरी, पीठ नं. 27, बहादुरपुर नई कोलोनी, बहादुरपुर, समस्तीपुर, समस्तीपुर, बिहार, 848101
Address: Dr. Vijay Kumar Choudhary, ward no 27, Bahadurpur new colony, Bahadurpur, Samastipur, Samastipur, Bihar, 848101

3858 1573 1306

1947
1800 300 1947

help@uidai.gov.in

www.uidai.gov.in

POOJA KUMARI AGE 25 YEARS 2132 BY DR. MEDIWHEEL CHEST.FRN P->A 9/24/2022

A.L.C. Advance Imaging Diagnostics Centre PATNA - 20

Dr. P. K. Tiwari
MD, M.Sc (Radio Imaging)
Ph.D (Ab Nuclear Medicine)
Consultant Imagingologist & Sonologist

MD (Pat)
Consultant Pathologist

Consultant Neuropathologist

INCIDENT SHOULD BE REPORTED BACK IMMEDIATELY/यहाँ जन्म से पहले भ्रुण का लिंग जांच

भारत सरकार
Government of India

पूजा कुमारी
Pooja Kumari
जन्म तिथि / DOB: 02/01/1998
महिला / Female



3858 1573 1306

आधार - आम आदमी का अधिकार

Pooja kumar;

भारतीय विशिष्ट पहचान प्राधिकरण
Unique Identification Authority of India

आधार

पता:	Address:
D/O: बिजय कुमार चौरसिया, वॉर्ड न 27, बहादुरपुर नई कॉलोनी, बहादुरपुर, समस्तीपुर, समस्तीपुर, बिहार, 848101	D/O: Vijay Kumar Chaurasiya, ward no 27, bahadurpur new colony, Bahadurpur, Samastipur, Samastipur, Bihar, 848101

3858 1573 1306


MEDIWHEEL

FOR MALE	FOR FEMALE
CBC	CBC
ESR	ESR
Blood group & RH Factor	Blood Group & RH Factor
Blood and Urine Sugar Fasting	Blood and Urine Sugar Fasting
Blood and Urine Sugar PP	Blood and Urine Sugar PP
Stool Routine	Stool Routine
Lipid Profile	Lipid Profile
Total Cholesterol	Total Cholesterol
HDL	HDL
LDL	LDL
VLDL	VLDL
Triglycerides	Triglycerides
HDL/ LDL ratio	HDL/ LDL ratio
Liver Profile	Liver Profile
AST	AST
ALT	ALT
GGT	GGT
Bilirubin (total, direct, indirect)	Bilirubin (total, direct, indirect)
ALP	ALP
Proteins (T, Albumin, Globulin)	Proteins (T, Albumin, Globulin)
Kidney Profile	Kidney Profile
Serum creatinine	Serum creatinine
Blood Urea Nitrogen	Blood Urea Nitrogen
Uric Acid	Uric Acid
HBA1C	HBA1C
Routine urine analysis	Routine urine analysis
USG Whole Abdomen	USG Whole Abdomen
General Tests	General Tests
X Ray Chest	X Ray Chest
ECG	ECG
2D/3D ECHO / TMT	2D/3D ECHO / TMT
Stress Test	Thyroid Profile (T3, T4, TSH)
PSA Male	Mammography (as per Age criteria – to be specified) and Pap Smear
Thyroid Profile (T3, T4, TSH)	Dental Check-up consultation
Dental Check-up consultation	Physician Consultation
Physician Consultation	Eye Check-up consultation
Eye Check-up consultation	Skin/ENT consultation
Skin/ENT consultation	Gynaec Consultation
TOTAL Rs - 2000	

From ALC ADVANCE IMAGING DIAGNOSTICS

Authorized Signatory

Somytiwaj





Pt. Name :- POOJA KUMARI
Ref. By :- DR . MEDIWEEL

Date:- 15-Oct-22
Age / Sex - Yrs. F.

REAL TIME U.S.G. OF WHOLE ABDOMEN
Thanks for your kind referral

(Report.)

- LIVER :- Measures 13.20 cm. Normal in shape, size and echo texture. I.H.B.R. are not dilated. Hepatic veins are normal. No SOL seen.
- G.BL. :- Lumen is echo free. Wall thickness appears normal.
- C.B.D. :- Measures 3.3 mm in diameter with echo free lumen. No calculi or mass seen.
- P.V. :- Measures 7.2 mm in diameter. Appears normal. No thrombus seen.
- PANCREAS :- Normal in shape, size and echo texture. No calcification mass seen.
- SPLEEN :- Measures 7.30cm. Normal in shape, size and echo texture. No SOL seen.
- KIDNEY :- Both kidney shows normal shape, size & echotexture. C.M.D.intact. P.C.S.is not dilated. No calculi, cyst or hydronephrosis seen on either side.
Right Kidney :- Measures 9.80 X 3.3 cm.
Left Kidney :- Measures 9.60 X 3.4 cm.
- URETER :- Not dilated. No apparent calculi seen.
- U.BLADDER:- Shows normal in outline with echo free lumen. No calculi or mass seen.
Pre void - 210 ml. Post void - is in significant
- UTERUS :- Is normal in size, shape & position measuring 8.60 X 5.60 cm. Endometrial And Myometeriam appears normal in limits No focal mass lesion seen
- ADNEXA :- Both ovary appears normal in size and shape.
Rt Ovary Measures - 2.10 cm Lt Ovary Measures 2.30 cm
- P.O.D :- No collection seen in P.O.D
- R.I.F. :- Son graphically no appendicular mass or collection seen.
- OTHERS :- No Ascites . no Lymph Adenopathy. No pleural effusion seen on either side .



IMPRESSION

➤ **Son graphically normal scan no detectable lesion seen**

Handwritten signature and date: 15/10/22

Consultant Radiologist

- K. Tiwari**
(Radio Imaging)
Nuclear Medicine)
Imagionologist & Sonologist
- Dr. S. Kumar**
MD (Pat)
Consultant Pathologist
- Dr. Abhishek Kumar**
MBBS, MD
Consultant Neuropatho Physiologist
- Dr. Kumari Suman**
MBBS, DGO, MD
Consultant (TVS & HSG Specialist)
- Dr. A. K. Singh**
MBBS, PGDMCH
Consultant Radiologist & Sonologist



ALC Advance Imaging Dignostics
 (A Unit of Subham Imaging P.K. Arogyam Health & Wellness Center)
 E-95, P.C. Colony, Near Sai Netralaya Transformer, Kankarbagh, Patna - 20
 www.pkarogyamhealthcheckup.com

PATIENT ID: 2132

ID 2132 CASE 1 POOJA KUMARI
 AGE 25 Y 0M 0D FEMALE
 Cms 48K0

15/10/2022 12 31 18
 ALC ADVANCE IMAGING DIAGNOSTICS
 E95 PC COLONY KANKARBAGH PATNA

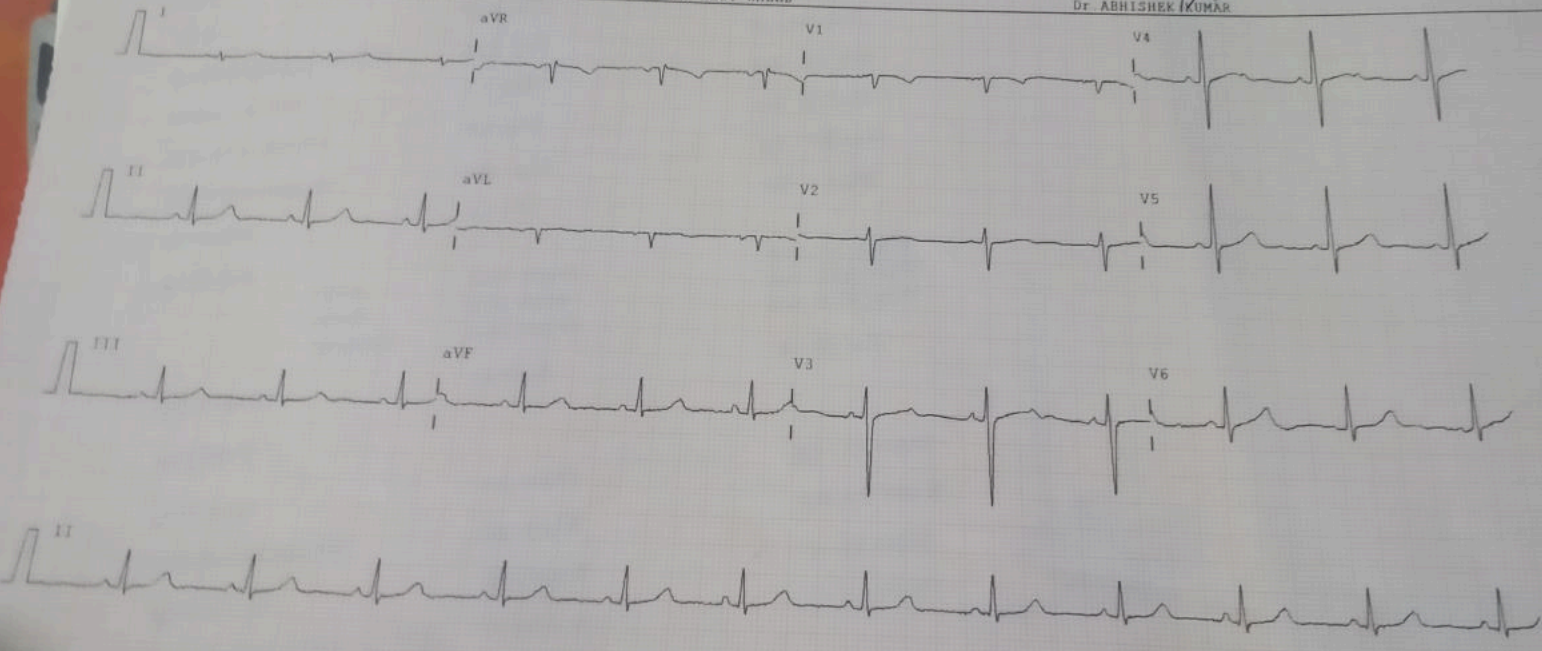
RATE 72 bpm SINUS RHYTHM
 R-R 826 ms
 P-R 116 ms
 QRS 78 ms
 QT 402 ms
 QTc 423 ms
 P-AXIS 78°
 QRS 85°
 T 68°

NORMAL ECG

12 SL. REPORT FORMAT 3a4*1L SQ

REF DR MEDI WHEEL

Dr. ABHISHEK KUMAR



25mm/sec 10mm mV Notch ON BLC ON 0.05-35Hz

ALLEGERS PISCES 1012(VER --- 1 8)

CLINICALLY CORRELATE THE FINDINGS.

Dr. P. K. Tiwari
 MD, M.Sc (Radio Imaging)
 M.D (Ab Nuclear Medicine)
 Consultant Radiodiagnosis & Sonologist

Dr. S. ...
 MD (Path)
 Consultant Pathologist

MBBS, ...
 Consultant Neurophysiologist

PRINTING MISTAKE SHOULD BE REPORTED BACK IMMEDIATELY/ यहाँ जन्म से पहले भ्रूण का लिंग जानें

SUNDAY

EMERGENCY REPORTING FACILITY AVAILABLE



A.L.C. Advance Imaging Diagnostics

(A Unit of Subham Imaging P.K. Arogyam Health & Wellness Center)

E-95, P.C. Colony, Near Sai Netryalaya Transformer, Kankarbagh, Patna - 20
www.pkarogayamhealthcheckup.com

Phone: 9855124124, 9855124125

OPINION MUST BE CORRELATES WITH CLINICALLY & OTHER INVESTIGATION FOR FINAL DIAGNOSIS. NOT FOR MEDICO LEGAL PURPOSE

PATIENT NAME : Mrs. POOJA KUMARI

PATIENT ID: 2132

COL DATE : 16/10/2022 REPORTING DATE: 16/10/2022 AGE SEX:- 25 YRS/F

REF.BY : DR./ MEDIWHEEL.

TEST NAME	RESULT	Unit	REF.RANGE
-----------	--------	------	-----------

LFT:-

SGPT	16.6 IU/L		5 - 48 IU/L
SGOT	15.0 IU/L		5 - 40 IU/L
ALKALINE PHOSPHATASE	74.4 IU/L		25 - 147 IU/L
TOTAL PROTIN	7.1 g/dl		6.0 - 8.7 g/dl
SERUM ALBUMIN	4.3 g/dl		3.5 - 5.4 g/dl
SERIUM GLUBLINE	2.8 g/dl		2.3 - 3.6 g/dl
AG RATIO	1.5 : 1		1.0 - 2.3 g/dl
BILIRUBIN			
TOTAL	0.65 mg/dl		0.1 - 1.1 mg/dl
IRECT	0.21 mg/dl		0.0 - 0.32 mg/dl
INDIRECT	0.46 mg/dl		0.0 - 0.78 mg/dl
GGTP (GGT)	14.9 iu/L		8 - 38 iu/L

KFT/RFT

URIC ACID	4.4 mg/dl		3.2 - 7.0 mg/dl
SERUM CREATNINE	0.8 mg/dl		0.6 - 1.5 mg/dl
BLOOD URIA	29.4 mg/dl		5 - 45 mg/dl
BLOOD URIA NITROZEN(BUN).	13.7 mg/dl		5 - 23 mg/dl

16/10/22
Consultant Radiologist

Dr. P. K. Tiwari

MD (Radio Imaging)
Nuclear Medicine)

Imagionologist & Sonologist

Dr. S. Kumar

MD (Pat)
Consultant Pathologist

Dr. Abhishek Kumar

MBBS, MD
Consultant Neuropatho Physiologist

Dr. Kumari Suman

MBBS, DGO, MD
Consultant (TVS & HSG Specialist)

Dr. A. K. Singh

MBBS, PGDMCH
Consultant Radiologist

REPORTING MISTAKE SHOULD BE REPORTED BACK IMMEDIATELY/ यहाँ जन्म से पहले भ्रुण का लिंग जाँच नहीं

A.L.C. Advance Imaging Dignostics

(A Unit of Subham Imaging P.K. Arogyam Health & Wellness Center)

F-35, P.C. Colony, Near Sai Netryalaya Transformer, Kankarbagh, Patna - 20
www.paragayamhealthcheckup.com

Patna - 20

RESULTS MUST BE CORRELATES WITH CLINICALLY & OTHER INVESTIGATION FOR FINAL DIAGNOSIS. NOT FOR MEDICO LEGAL PURPOSE

GGTP (GGT)	19.9 iu/L	8-38 iu/L
------------	-----------	-----------



Handwritten signature or initials in blue ink.

PATIENT ID: 2132

PATIENT NAME : Mrs. POOJA KUMARI

COL DATE : 16/10/2022

REPORTING DATE: 16/10/2022 AGE SEX : 25 YRS/F

REF.BY : DR. /MEDIWHEEL.

TEST NAME	RESULT	Unit	REF.RANGE
BLOOD SUGAR (F)	91.0 mg/dl		70 - 110 mg/dl

LIPID PROFILE:-

TOTAL CHOLESTROL	152.2 mg/dl		130 -250 mg/dl
TRIGLYCERIDE	103.0 mg/dl		50 -160 mg/dl
HDL CHOLESTROL	39.0 mg/dl		30 - 60 mg/dl
LDL CHOLESTROL	92.6 mg/dl		80 -130 mg/dl
VLDL CHOLESTROL	20.6 mg/dl		15 - 40 mg/dl
T.CH./HDL RATIO	3.9:1		Upto 5:1
LDL/HDL RATIO	2.3:1		2 - 4:1

Consultant

REF BY:-

Dr. P. K. Tiwari
M.Sc (Radio Imaging)
D (AI) Nuclear Medicine
Consultant Radiologist & Sonologist

Dr. S. Kumar
MD (Pat)
Consultant Pathologist

Dr. Abhishek Kumar
MBBS, MD
Consultant Neuropatho Physiologist

Dr. Kumari Suman
MBBS, DGO, MD
Consultant (TVS & HSG Specialist)

Dr. A.
MBBS, PGD
Consultant

PATIENT'S NAME: DR. S. KUMAR
 CLINICAL: HYPERTENSION, DIABETES MELLITUS, AGE 50, 25 YEARS
 SEX: M

TEST NAME	RESULT	UNIT	REF RANGE
TSH (Thyroid Stimulating Hormone)	1.2	μIU/ml	0.45 - 4.20 μIU/ml
Free T4 (Thyroxine)	1.2	ng/dl	1.10 - 1.40 ng/dl
Free T3 (Triiodothyronine)	1.2	pg/ml	0.27 - 4.20 pg/ml

- 1. TSH (μIU/ml) EUTHYROID STATE
- 2. TSH (μIU/ml) HYPERTHYROIDISM
- 3. TSH (μIU/ml) HYPOTHYROIDISM
- 4. TSH (μIU/ml) SUB-CLINICAL HYPOTHYROIDISM
- 5. TSH (μIU/ml) SUB-CLINICAL HYPERTHYROIDISM
- 6. TSH (μIU/ml) T3 TOXICITY

TSH (μIU/ml) is dependent on T4 level.

Free T4 (ng/dl) is a better MARKER of Thyroid Function.

[Signature]
16/10/20

Consultant Radiologist

Dr. S. Kumar Dr. Abhishek Kumar Dr. Kumanj Suman Dr. A. K. Singh
 Consultant Radiologist Consultant Radiologist Consultant (TUS & PAC Specialist) Consultant Radiologist

RESULTS SHOULD BE REPORTED BACK IMMEDIATELY / यदि जल्द से जल्द हुए का रिजल्ट जीव नहीं हो

PATIENT NAME : Mrs. POOJA KUARI


PATIENT ID: 2132

COL DATE : 16/10/2022 REPORTING DATE: 16/10/2022 AGE SEX : 25 YRS/F

REF BY : DR./ MEDIWHEEL

GLYCOSYLATED HEMOGLOBIN

TEST NAME	RESULT	Unit	REF. RANGE
HbA1c	3.6 %		Below 5.7 % : Normal 5.7 – 6.4 % : Prediabetic > = 6.5 % : Diabetic
AVERAGE PLASMA GLUCOSE	91.0 mg/dl		90 – 120 mg/dl : Good Control 121 – 150 mg/dl : Fair Control 151- 180 mg/dl: Unsatisfactory Control >180 mg/dl : Poor Control


16/10/22

Consultant Radiologist

P. K. Tiwari

M.Sc (Radio Imaging)

MD Nuclear Medicine

Consultant Radiologist & Sonologist

Dr. S. Kumar

MD (Path)
Consultant Pathologist

Dr. Abhishek Kumar

MBBS, MD
Consultant Neuropatho Physiologist

Dr. Kumari Suman

MBBS, DGO, MD
Consultant (TVS & HSG Specialist)

Dr. A. K. Singh

MBBS, PGDMCH
Consultant Radiologist & Sonologist

REPORTING MISTAKE SHOULD BE REPORTED BACK IMMEDIATELY/ यहाँ जन्म से पहले भ्रुण का लिंग जाँच नहीं होता

...ING FACILITY

Advance Imaging Dignostics

(A Unit of Subham Imaging P.K. Arogyam Health & Wellness Center)

F-95, P.C. Colony, Near Sai Netryalaya Transformer, Kankarbagh, Patna - 20

www.pkarogayamhealthcheckup.com

Ph: 985514 8071

RESULT MUST BE CORRELATES WITH CLINICALLY & OTHER INVESTIGATION FOR FINAL DIAGNOSIS. NOT FOR MEDICO LEGAL PURPOSE

PATIENT NAME : Mrs. POOJA KUMARI

PATIENT ID: 2132

COL DATE : 16/10/2022 REPORTING DATE: 16/10/2022 AGE SEX:- 25 YRS/F


REF.BY : DR. / MEDIWHEEL

TEST NAME	RESULT	Unit	REF.RANGE
-----------	--------	------	-----------

BLOOD GROUP	: ' B '		
-------------	---------	--	--

Rh Typing	: POSITIVE		
-----------	------------	--	--

Note: Do always cross – matching before blood transfusion


16/10/22

Consultant Radiologist

Dr. P. K. Tiwari

MD (Radio Imaging)

Consultant Nuclear Medicine

Consultant Radiologist & Sonologist

Dr. S. Kumar

MD (Path)

Consultant Pathologist

Dr. Abhishek Kumar

MBBS, MD

Consultant Neuropatho Physiologist

Dr. Kumari Suman

MBBS, DGO, MD

Consultant (TVS & HSG Specialist)

Dr. A. K. Singh

MBBS, PGDARCH

Consultant Radiologist

REPORTING MISTAKE SHOULD BE REPORTED BACK IMMEDIATELY/ यहाँ जन्म से पहले पुन का सिग जीव नहीं

PATIENT NAME : Mrs. POOJA KUMARI
 COL DATE : 16/10/2022 REPORTING DATE: 16/10/2022 AGE SEX:- 25 YRS/F
 REF. BY : DR./ MEDIWHEEL. PATIENT ID: 2132

TEST NAME	RESULT	Unit	REF.RANGE
ESR	14 mm/hr		<20 mm/hr
CBC			
Total W.B.C. Count	5,400 /cumm		4000-11,000 /cumm
R B C COUNT	4.01 Million/ CUmm		4 - 7 Million/ CUmm
Platelets count	1.56 Lakh/ cumm		1.5-5.0 Lakh/ cumm
Differential Count of W.B.C.			
Neutrophils	60 %		40-70%
Lymphocytes	37 %		25-40%
Eosinophils	02 %		01-05%
Mnonocytes	01 %		00-02%
Basophiles	00 %		00-0%
HAEMOGLOBIN	11.4 gm/dl (78.0 %)		14.6 gm/dl = 100%
PCV	36.0 %		35-47 %
MCV	87.4 fl		76-96 fl
MCH	28.5 pg		29-35 pg
MCHC	33.4 %		30-38 %

[Handwritten Signature]
 16/10/22

Consultant Radiologist

K. Tiwari (Radio Imaging) Nuclear Medicine) **Dr. S. Kumar** (Put) Consultant Pathologist **Dr. Abhishek Kumar** MBBS, MD Consultant Neuropatho Physiologist **Dr. Kumari Suman** MBBS, DGO, MD Consultant (TVS & HSG Specialist) **Dr. A. K. Singh** MBBS, PGDMCH Consultant Radiologist & Sonologist

REPORTING MISTAKE SHOULD BE REPORTED BACK IMMEDIATELY/ यहाँ जन्म से पहले भ्रुण का लिंग जाँच नहीं होता है

PATIENT ID: 2132
 PATIENT NAME: Mrs. POOJA KUMARI
 COL DATE: 16/10/2022 REPORTING DATE: 16/10/2022 AGE SEX: 25 YRS/F
 REF BY: DR. /MEDWHEEL

ROUTINE EXAMINATION OF URINE

PHYSICAL EXAMINATION

Quantity	30 ml	Colour	Straw
Appearance	Clear	Sediment	Nil
Specific gravity	1.010		

CHEMICAL EXAMINATION

Reaction	6.0	Nitrite	Not done
Sugar	Nil	Bile Pigment	Not done
Albumin	Nil	Urobilinogen	Not done
Excess of Phosphate	Nil	Chile	Not done
Bile Salt	Not Done	Acetone	Not done

MICROSCOPIC EXAMINATION

Erythrocytes	Nil	Casts	Nil
Leucocytes	1-6 / HPE	Crystals	Nil
Epith. Cell	A, Few	Others	Nil

(Handwritten signature and date)
 16/10/22

Consultant Radiologist

Tiwari **Dr. S. Kumar** **Dr. Abhishek Kumar** **Dr. Kumari Suman** **Dr. A. K. Singh**
 (also Imaging) MD (Put) MBBS, MD MBBS, DGO, MD MBBS, PGD&MCH
 (Gen Medicine) Consultant Pathologist Consultant Neuropatho Physiologist Consultant (TVS & HSG) Specialist Consultant Radiologist & Sonologist
 Radiologist & Sonologist

NG MISTAKE SHOULD BE REPORTED BACK IMMEDIATELY/ वही जन्म से पहले भ्रम का लिए जीव नहीं होता है ।



ECHOCARDIOGRAPHY & COLOR DOPPLER REPORT

Patient's Name : Mrs. POOJA KUMARI

Age/Sex : 25 Yrs /F

Ref. by : B O B

Date : 23-Oct-22

ECHOCARDIOGRAPHIC WINDOW: Fair

2D & M MODE ECHOCARDIOGRAPHY

Left ventricle

EDD:	52	mm (20 - 28 mm / m ²)	ESD:	33	mm(13 - 21 mm / m ²)
IVS :	10	mm (6 - 11 mm)	PW:	8	mm(6 - 11 mm)
Ejection fraction:	65% (61 ± 8%)		FS:	35	% (34 - 44 %)
IVS:	Intact		LV clot	Absent	

Left atrium/ Aorta 33/30 mm

Right ventricle Normal

Right atrium Normal

Pericardium Normal with no pericardial effusion

2D:

Normal LA/LV Size and normally contracting left ventricle. No RWMA, concentric LVH

Mitral valve

AML/ PML: Normal

Tricuspid valve Normal

Aortic valve Normal

Pulmonary valve Normal

Continuous & Pulse Wave Doppler study

Valve	Velocity (m/sec)			Gradient (mmHg)			Valve area (PHT Method)	Regurg.
	Peak	Mean	EDV	Peak	Mean	EDG		
Mitral	E=1.2 A=0.7			6.0	2.0			Nil
Tricuspid	E=1.5 A=0.2			1.3	0.2			Nil
Aortic	1.3			5.0	2.5			Nil
Pulmonary	6.3			3.5	1.7			Nil

Consultant Radiologist

wari

ingini

adical

gust & Sologor

Dr. S. Kumar

MD (Pat)
Consultant Pathologist

Dr. Abhishek Kumar

MBBS, MD
Consultant Neuropatho Physiologist

Dr. Kumari Suman

MBBS, DGO, MD
Consultant (TVS & HSG Specialist)

Dr. A. K. Singh

MBBS, PGDMCH
Consultant Radiologist & Sonologist

Colour Flow Imaging

No TR, No MR/PR, No AR
No flow shunt

COMMENTS :

- ◆ Normal size all chamber
- ◆ Normal LV filling Pressure
- ◆ No RWMA
- ◆ Normal LV systolic function
- ◆ Grade I LV diastolic dysfunction.
- ◆ Global LVEF = 60%
- ◆ All cardiac valves are normal
- ◆ No PAH, Mild concentric LVH
- ◆ No MS / TS / AS / PS / PR
- ◆ No clot / vegetation / pericardial effusion.

IMPRESSION:

All chambers are normal
No RWMA, No PAH
Grade I LV diastolic dysfunction.
Normal LV systolic function, LVEF – 60%

Please correlate clinically

DR. SANDEEP KUMAR MBBS MD

STB BY:-

Consultant Radiologist

Dr. P. K. Tiwari
M.Sc (Radio Imaging)
(All Nuclear Medicine)
Consultant Radiologist & Sonologist

Dr. S. Kumar
MD (Pat)
Consultant Pathologist

Dr. Abhishek Kumar
MBBS, MD
Consultant Neuropathologist & Physiologist

Dr. Kumari Suman
MBBS, DGO, MD
Consultant (TVS & HSG Specialist)

Dr. A. K. S...
MBBS, PGDMCH
Consultant Radiologist