



सत्यमेव जयते
भारत सरकार



आधार

भारत सरकार
Government of India

भारतीय विशिष्ट पहचान प्राधिकरण
Unique Identification Authority of India


नामांकन क्रम / Enrollment No. : 0013/05010/10202

To
Swati Yadav
स्वाति यादव
C/O: Ravi Raj Yadav,
P29,
Priydarshini Paramount,
Opposite Vrindavan Dhaba, Hoshangabad Road,
VTC: Huzur, PO: University,
Sub District: Huzur, District: Bhopal,
State: Madhya Pradesh, PIN Code: 462026,
Mobile: 7509663670

28821920



KF288219200FI



आपका आधार क्रमांक / Your Aadhaar No. :

3188 9246 6337

मेरा आधार, मेरी पहचान



भारत सरकार
Government of India



आधार

Issue Date: 06/05/2012



स्वाति यादव
Swati Yadav
जन्म तिथि / DOB: 03/03/1983
महिला / Female

3188 9246 6337

मेरा आधार, मेरी पहचान

Scanned with CamScanner

Scanned with CamScanner



द्विवाकर डायग्नोस्टिक सेंटर

E-7/636, पंजाब नेशनल बैंक के पास, मैन रोड, अरेरा कॉलोनी भोपाल (म.प्र.)


फोन: 0755-2465288, 0755-3520545 मो: 9826340190

Pt Name :	Mrs. Swati Yadav
Age :	39/F
Ref.By :	BOB
Lab. No. :	289
Date :	25/06/2022

EXAMINATION OF BLOOD

TEST	RESULT	NORMAL VALUE
Haemoglobin	13.4mgs%	Female 12-16gms%, Male 14-18gms%
Red Cell count	4.6	4.5-5.6 million /cumm
Platelet Count	1.74	1.5-5.6 Lac/cumm
Leucocytes per.cu.mm	5300/cumm	5000-11000/cumm
Neutrophils	49%	50-70%
Lymphocytes	40%	20-40%
Eosinophils	06%	0-7%
Monocytes	05%	2-8%
PCV	43.1	37-47
MCV	92.7	76-96
MCH	28.8	27-32
MCHC	31.0	31-35
ESR	11	Male 0-9, Female 0-20mm/FHR
Blood Group	"A" Positive	By Slide Method
S.Bilirubin(Total)	0.78	0.2-1.0mg/dl
Direct	0.34	0.0-0.25mg/dl
Indirect	0.44	
SGOT	24.1	5-35U/L
SGPT	28.0	8-40U/L
Alk Phosphatase	9.1	3-13 KA units
S. Protein(Total)	6.8	6.0-8.0mg%
Albumin	4.1	3.7-5.3mg%
Globulin	3.1	1.5 to 3.5 mg%
AG Ratio	1.28	1.-2.0
Blood Urea Nitrogen (BUN)	11.6	7-20 mg/dl
S.Creatine	0.88	0.5-1.4mg/dl
Uric Acid	4.9	4.8 to 7.5 mg/dl
Calcium	8.6	8.5-10.5 gm/dl
GGTP	29.6	5-35 UL/dl
Fasting Blood Sugar	79.6	70 to 110mg/dl
Post Prandial Blood Sugar	122.3	Up to 150mg/dl
Total Serum Cholesterol	168.3	100-250 mg%
Serum Triglyceride	131.6	Up to 160 mg%
Serum Cholesterol HDL	42.5	Up to 65 mg%
Serum Cholesterol LDL	99.4	Up to 125 mg%
VLDL	26.3	Up to 30 mg%
TC/HDL Ratio	3.28	Bellow 5
Glycosylated Hemoglobin HBA1c	5.3	Below - 6.0 % -Non Diabetic control 6-7 % -Excellent control Above- 8 % -Poor control

All test have technical limitation. Collaborative clinic pathological interpretation is mandatory. In case of disparity test may be repeated immediately. Typographical mistakes should be get correct instantly. This report is not valid for medico legal purpose



Pathologist
Dr. B. M. Aggarwal
MBBS, DCP
Consultant Pathologist



दिवाकर डायग्नोस्टिक सेंटर

E-7/636, पंजाब नेशनल बैंक के पास, मैन रोड, अरेरा कॉलोनी भोपाल (म.प्र.)

फोन: 0755-2465288, 0755-3520545 मो: 9826340190

Pt Name :	Mrs. Swati Yadav
Age :	39/F
Ref.By :	BOB
Lab. No. :	289
Date :	25/06/2022

URINE ANALYSIS

<u>A. PHYSICALEXAMINATION</u>		<u>C. MICROSCOPIEXAMINATION</u>	
1. Colour	Yellow	Pus Cells	3-4/HPF
2. Appearance	Clear	R.B.C.	Nil
3. Specific Gravity	Q.N.S.	Epithelial Cell	1-2/HPF
<u>B. CHEMICAL EXAMINATION</u>		Cast	Nil
1.Reaction	Acidic	Crystals(Cal.Oxa)	Nil
2.Albumin	Absent	Bacteria	Nil
3.Sugar	Nil	Amorphous	Nil
4.Bile Salts	Absent	T. Vaginitis	Nil

URINE COTININE	Negative	By Card method
----------------	----------	----------------



Dr. B. M. Agarwal
MBBS DCP
Consultant Pathologist

All test have technical limitation. Collaborative clinic pathological interpretation is mandatory. In case of disparity test may be repeated immediately. Typographical mistakes should be get correct instantly. This report is not valid for medico legal purpose



दिवाकर डायग्नोस्टिक सेंटर

E-7/636, पंजाब नेशनल बैंक के पास, मैन रोड, अरेरा कॉलोनी भोपाल (म.प्र.)

फोन: 0755-2465288, 0755-3520545 मो: 9826340190

Pt Name :	Mrs. Swati Yadav
Age :	39/F
Ref.By :	BOB
Lab. No. :	289
Date :	25/06/2022
Skigram	X Ray Chest PA View
Radiologist	Dr. B.M.Agarwal MD (Radiology)

REPORT

Tricia Central

Thoracic cage normal

Both Lungs Field Clear.

Both hilers normal

Cardiac border normal

Both cp angles clear

Both domes and diaphragm normal

IMPRESSION

- NO CARDIO PULMONARY PATHOLOGY
- COORELATE WITH CLINICAL FINDINGS.

Dr. B. M. Agarwal
MD, Radiology
Consultant Radiologist





दिवाकर डायग्नोस्टिक सेंटर

E-7/636, पंजाब नेशनल बैंक के पास, मैन रोड, अरेरा कॉलोनी भोपाल (म.प्र.)

फोन: 0755-2465288, 0755-3520545 मो: 9826340190

Pt Name :	Mrs. Swati Yadav
Age :	39/F
Ref.By :	BOB
Lab. No. :	289
Date :	25/06/2022

EXAMINATION OF BLOOD

Thyroid profile


<u>TEST</u>	<u>RESULT</u>	<u>NORMAL VALUE</u>
T3 - TOTAL	116.8	82-213 ng/dL
T4 - TOTAL	7.26	6.09-12.23 ug/dL
THYROID STIMULATING HARMONE (TSH)	2.88	0.45-4.25 ul/mL

Interpretation:

TSH Levels will be elevated in primary hypothyroidism, TSH levels will be low in Hyperthyroidism there is decreased production of thyroid hormones by the thyroid hence the person may experience symptoms such as weight gain, constipation, cold intolerance and fatigue. Iodine deficiency and Hashimoto thyroiditis is the most common cause of hypothyroidism It makes Thyroid stimulating hormone. If TSH levels are abnormally high it could mean you have an underactive thyroid or hypothyroidism.

Dr. B. M. Agarwal
MBBS, D.P.
Pathologist
Consultant Pathologist

All test have technical limitation. Collaborative clinic pathological interpretation is mandatory. In case of disparity test may be repeated immediately. Typographical mistakes should be get correct instantly. This report is not valid for medico legal purpose

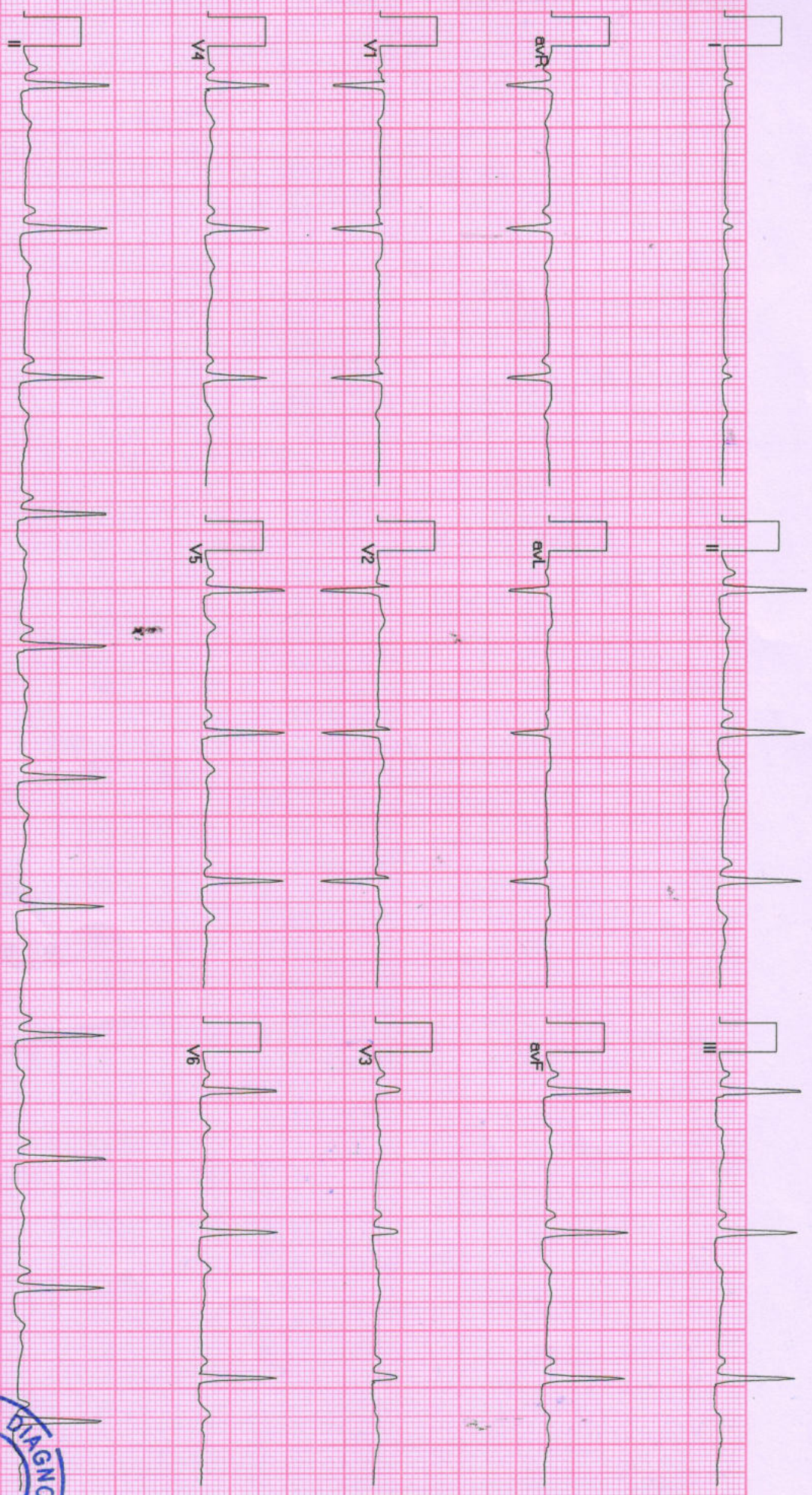


Allengers Global Healthcare Pvt Ltd.
133 / MRS. Swati yadav / 39 Yrs / F / 160Cms. / 54Kgs.
Heart Rate : 64 bpm / Tested On : 25-Jun-22 10:19:36 / HF 0.05 Hz - LF 100 Hz / Notch 50 Hz / Sn 1.00 Cm/mV / Sw 25 mm/s
/ Revid By: MEDIWHEEL

ECG



BPL-DYNATRAC



Allengers ECG (Pisces)(PIS213180317)

Swati Yadav





डॉ. सविता क्लिनिक

34, भूतल, मोहिनी अदिति आर्केड, शाहपुरा मस्जिद के पास
भरत नगर रोड, ई-7/194, अरेरा कॉलोनी, भोपाल - 462038

Mob. : 8989649694, 9516333619

Clinic Registration : CL/5392/Jun/2017

PNDT Registration : MPPCPNDT/BPL/2017/206



Name : Mrs. Swati Yadav Age 39 YRS./F

R/B Health check-up No. 25/6/22 Date 25/6/22

WHOLE ABDOMES ULTRASOUND REPORT

Indication:

Liver appears normal in size and shape with normal outline. Normal/
~~increased~~ perenchymal echogenicity is noted. No E/O focal lesion/ IHBR
dilatation is seen. Hepatic veins and portal veins appear normal.

No E/O subdiaphragmatic Collection.

Gall Bladder is physiologically well distended. No. E/O echogenic foci in GB
lumen. GB wall is normal / ~~thickened~~. No E/O pericholecystic collection.
Common duct reveals normal course and caliber.

Pancreas appear normal in size, shape and echo texture with smooth
contour. No peripancreatic pathology seen. (~~Not seen due to gases~~)

Spleen is normal in size and echo texture.

IVC and aorta appear to be normal.

No evidence of lymphadenopathy is noted.

No evidence of free fluid is noted.

Right Kidney is normal in size, size, shape and position. Corticomedullary
differentiation (CMD) is well maintained. Normal cortical thickness is
noted. No E/O hydronephrosis or calculus is noted.

PTO

Dr. P. Savita, MD
MBBS, MD (O&G) Reg. No. 9971
स्त्री रोग विशेषज्ञ

Dr. Jayant Yadav, MD
MBBS, MD (Radiologist) Reg. No. 4166
रेडियोलॉजिस्ट

Left Kidney is normal in size, shape and position. CMD is well maintained. Normal cortical thickness is noted. No E/O hydronephrosis or calculus is noted.

Urinary Bladder is well distended (physiological). its contents are echo free. No E/O bladder wall thickening is noted. ~~Post-void residue is insignificant.~~

Prostate is normal in size. Shape and echo texture with smooth outline. No E/O focal lesion is noted.

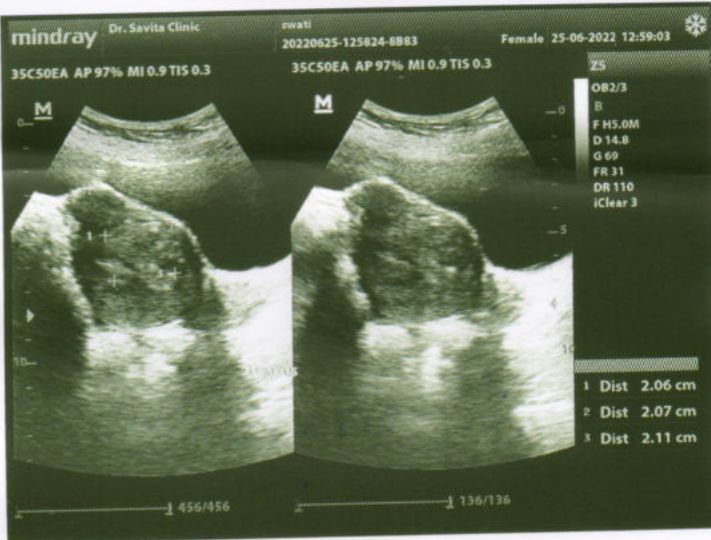
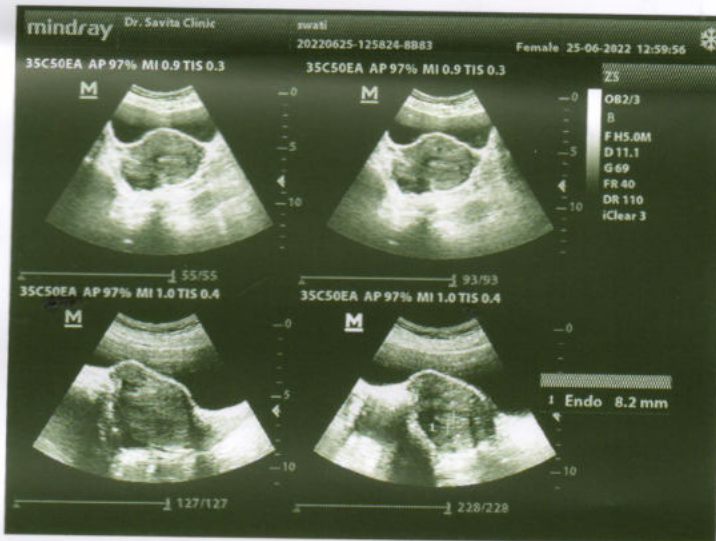
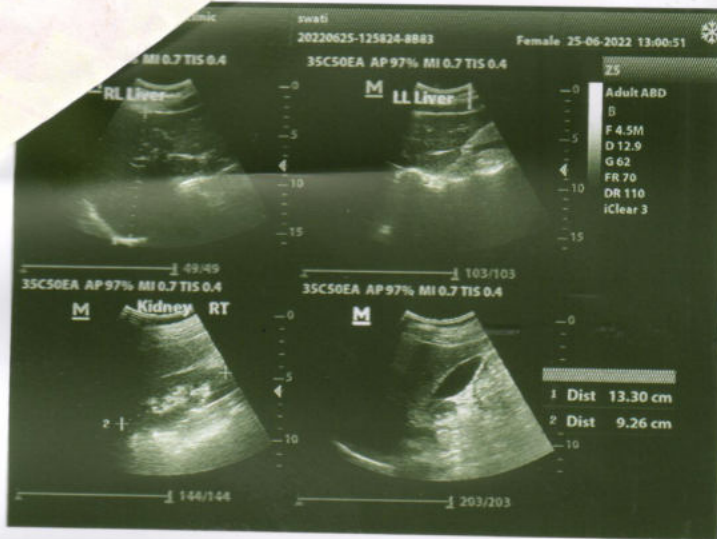
Uterus is ante/~~retro~~ verted and ~~normal~~ in size, ~~shape and echo texture with smooth outline.~~ No E/O focal lesion is noted. Endometrial echo appear normal. Cervical and vaginal shadows appear normal.

bulky & Irregular shape
Multiple seedling Myometrial fibroids seen - 2.06 / 2.07 / 2.11 cm
side.
Right Ovary appears ~~enlarged~~ / Normal in size, shape and echo texture.

Left Ovary appears ~~enlarged~~ / Normal in size, shape and echo texture.

Impression : ~~Normal study.~~ *fibroid uterus.*

Advised clinical Correlation.



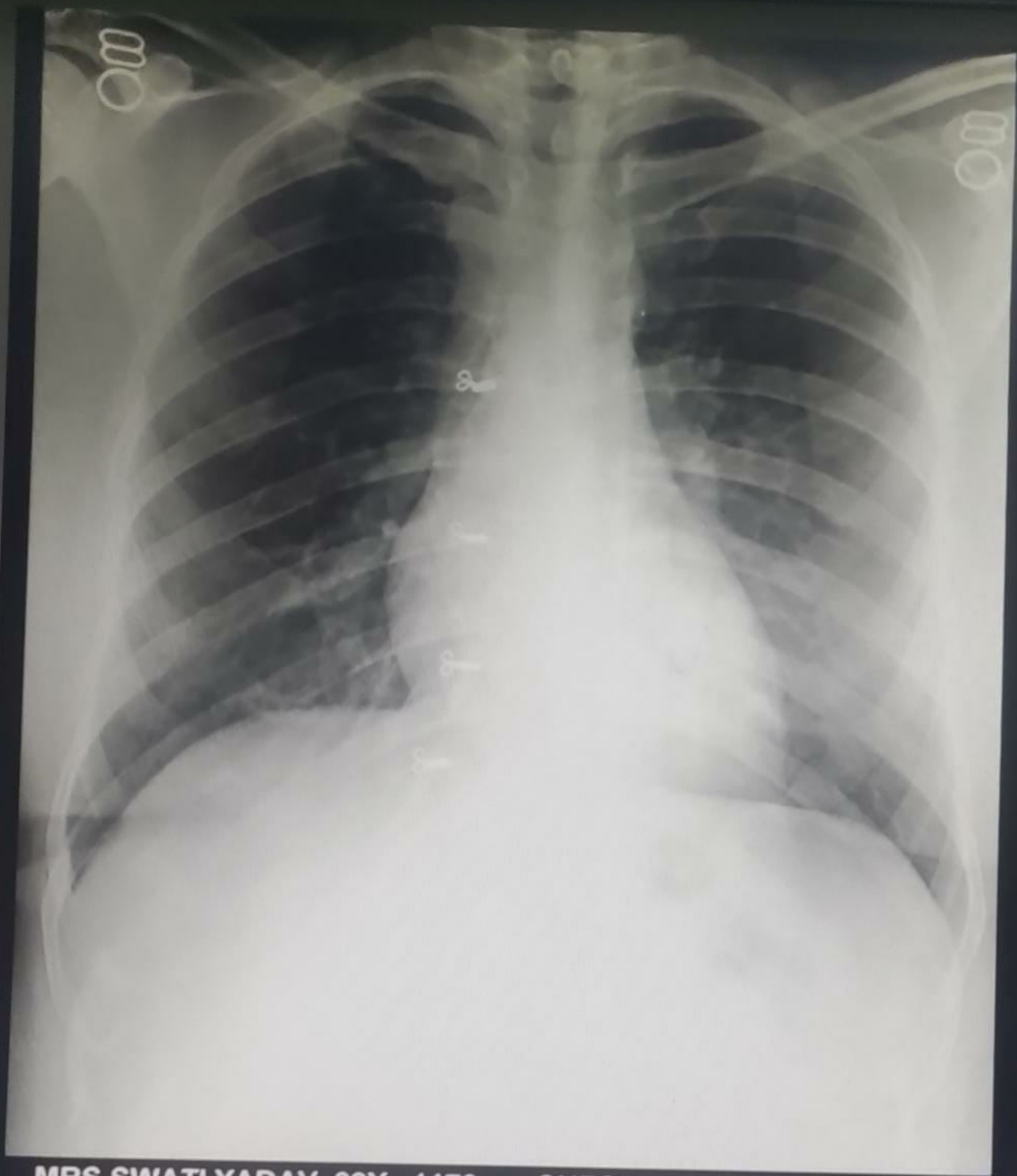


Divakar Diagnostic Centre

एक्स-रे | ई.सी.जी. | एको कार्डियो ग्राफी | सोनोग्राफी



THE BEST OF THE BEST
BEHIND YOUR CITY



**MRS SWATI YADAV 39Y 1173 CHEST,FRN P->A 25-JUN-22
DIWAKAR DIAGNOSTIC CENTRE , ARERA COLONY ,BHOPAL**