

RUO
CHEST PA

AMRUTHA SAI DIAGNOSTIC CENTER
MRS M SWATHI 35Y

02

02-Mar-22

Acq Tm: 05:25 PM

LEFT

3520 X 4280

W: 4001 L: 2281

MRS M SWATHI 36Y 02 CHEST PA 02-Mar-22 05:26 PM C/O MED WHEEL

AMRUTHA SAI DIAGNOSTIC CENTRE, OPP. BALAJI KALYANAMANDAPAM, SRINIVASA NAGAR, ANANTAPUR, 8688984900



AMRUTHA SAI DIAGNOSTIC CENTRE



Cell: 868 898 4900, 9966 77 4621

email: amruthasailab@gmail.com

ISO.9001:2015 Certificate Number: Q91864141412

Patient Name : Mrs M Swathi

Sex : Female Age : 35 Yrs

Id.No : D4/22

Bill Date : 02-03-2022

Report Date : 02-03-2022

Ref. by : Mediwheel BOB

Address : A T P

LAB REPORT

Blood For :-

Parameter	Findings	Reference Range
Complete Haemogram (CBP) :-		
Haemoglobin % (C M G)	: 10.0 gm %	F : 11.0- 16.0 gms %
Total WBC Count	: 5100 ce/cu mm	A : 4000 – 11000 ce/cu mm
Differential WBC Count	: Neutrophils – 47 % Lymphocytes – 47 % Eosinophils – 04 % Monocytes – 02 %	45 – 65 % 25 – 45 % 01 – 06 % 02 – 08 %
E S R (Westergren Method)	: 28 mm/ 1 hr	F : 02 - 20 mm/ 1 hr
RBC Count	: 4.2 mill/cu mm	F : 3.5 – 5.5 mill/cu mm
Platelet Count	: 2.5 Lach/cu mm	1.5 – 4.0 Lach/cu mm
Packed Cell Volume (PCV)	: 36.2 %	F : 36 – 47 %
Mean Corpuscular Volume (MCV)	: 82.7 fl	82 – 92 fl
Mean Corpuscular Haemoglobin (MCH)	: 28.3 pg	27 – 32 pg
Mean Corpuscular Haemoglobin Concentration (MCHC)	: 32.5 %	32 – 36 %

Complete Urine Analysis(C U A) :-

Physical Examination :-

Colour	: Pale Yellow	Transparency	: Clear
Reaction	: Acidic	Sediment	: NIL
Sp.Gravity	: 1.005	pH	: 6.5


Chemical Examination :-

Sugar	: Absent	Proteins	: Traces
Bile Salts	: Absent	Bile Pigments	: Absent
Urobilinogen	: Normal	Ketone Bodies	: Negative
Blood	: Absent		

Microscopic Examination :-

Pus Cells	: 6 - 8 /hpf	E.P.Cells	: 5 - 6 /HPF
RBC's	: Absent	Casts	: Absent
Crystals	: Absent	Deposits	: Absent
Bacteria	: Absent		

@ Suggested clinical Correlation, If there is need, kindly discuss.


S. Vijaya Lakshmi
M.Sc (Biochemistry)

Under AP Govt. Regd. Diagnostic Centre R.No.98/2012-2013

Genuineness is our gene

Scanned with CamScanner



AMRUTHA SAI DIAGNOSTIC CENTRE



Cell: 868 898 4900, 9966 77 4621

email: amruthasailab@gmail.com

ISO.9001:2015 Certificate Number: Q91864141412

Patient Name : Mrs M Swathi

Sex : Female Age : 35 Yrs

Id.No : D4/22

Bill Date : 02-03-2022

Report Date : 02-03-2022

Ref. by : Mediwheel BOB

Address : A T P

LAB REPORT

Blood For :-

Parameter	Findings	Reference Range	
LIPID PROFILE :-			
Cholesterol Total	: 192 mg/dl	150 - 260 mg/dl	
H D L Cholesterol	: 43 mg/dl	M : 35 - 55 mg/dl	
Triglycerides	: 181 mg/dl	36 - 165 mg/dl	
CHOL : HDL Chole	: 5.0 : 1	3.0 - 5.0 : 1	
Fasting Blood Sugar	: 90 mg/dl	65 - 110 mg/dl	
Post Prandial Blood Sugar	: 132 mg/dl	80 - 160 mg/dl	
Renal Function Test (RFT) :-			
Blood Urea	: 31 mg/dl	15 - 45 mg/dl	
Serum Creatinine	: 1.0 mg/dl	0.7 - 1.4 mg/dl	
Serum Uric Acid	: 2.9 mg/dl	3.0 - 5.7 mg/dl	
Serum Calcium	: 8.8 mg/dl	8.7 - 10.4 mg/dl	
LIVER FUNCTION TEST (LFT) :-			
Bilirubin Total	: 0.7 mg/dl	0.1 - 1.0 mg/dl	
Bilirubin Direct	: 0.18 mg/dl	0.0 - 0.25 mg/dl	
Bilirubin Indirect	: 0.5 mg/dl	0.2 - 0.8 mg/dl	
Total Proteins	: 6.5 gm/dl	6.0 - 8.0 gm/dl	
Albumin	: 4.3 gm/dl	3.7 - 5.3 gm/dl	
S G O T (A S T)	: 28 IU/L	Upto - 40 IU/L	
S G P T (A L T)	: 34 IU/L	Upto - 47 IU/L	
Alkaline Phosphatase (ALP)	: 174 IU/L	A : 100 - 290 IU/L	
Gamma Glutamyl Transferase (GGT)	: 22 IU/L	F : Upto - 30 IU/L	
TEST NAME	METHOD	VALUE	UNITS
GLYCOSYLATED HAEMOGLOBIN (Hb A1 c) %	TURBIDOMETRY	5.13	%

Reference Range :-

BELOW 6.0 %	- NORMAL VALUE
6.0 % - 7.0 %	- GOOD CONTROL
7.0 % - 8.0 %	- FAIR CONTROL
8.0 % - 10.0 %	- UNSATISFACTORY CONTROL
ABOVE 10.0 %	- POOR CONTROL

@ Suggested clinical Correlation, If there is need, kindly discuss.

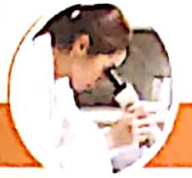S. Vijaya Lakshmi
LAB INCHARGE
S. Vijaya Lakshmi

Under AP Govt. Regd. Diagnostic Centre R.No.98/2012-2013

Genuineness is our gene



AMRUTHA SAI DIAGNOSTIC CENTRE



Cell: 868 898 4900, 9966 77 4621

email: amruthasailab@gmail.com

ISO.9001:2015 Certificate Number: Q91864141412

Patient Name : Mrs M Swathi

Sex : Female Age : 35 Yrs

Id.No : D4/22

Bill Date : 02-03-2022

Report Date : 02-03-2022

Ref. by : Mediwheel BOB

Address : A T P

X-RAY CHEST PA VIEW REPORT

Lung Parenchyma is normal with bronchovascular markings


Both hila are normal.

Cardiac with in normal limits.

Both CP angles and domes are normal.

Soft tissue and bony cage are normal.

IMPRESSION :- NORMAL STUDY.


Dr. K. RADHARANI, MD (S)
Specialist in Ultr Sound
Radio Diagnosis & C.T. Scan
Asst. Chief Surgeon
RADIOLOGIST SIGNATURE
Govt. Medical College &
General Hospital
ANANTAPUR

@ Suggested clinical Correlation, If there is need, kindly discuss.

Note:- Amrutha Sai Diagnostic Centre . (Fully Automated A/C Laboratory)

***** Since - 25 Years *****

Opp. Balaji Kalyana Mantapam, Near RTC Bus Stand, Reliance Mart Road,
Srenivasa Nagar, ANANTHAPURAM. CELL - 86 88 984900.

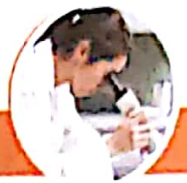Under AP Govt. Regd. Diagnostic Centre R.No.98/2012-2013

Genuineness is our gene

Scanned with CamScanner



AMRUTHA SAI DIAGNOSTIC CENTRE



Cell: 868 898 4900, 9966 77 4621

email: amruthasailab@gmail.com

ISO.9001:2015 Certificate Number: Q91864141412

Name :- Mrs M Swathi

Age/Sex :- 35 y/Female

Date :- 02-03-2022

Ref.by :- Mediwheel (BOBES-8511)

ID.No:- D4/2022

EMPLOYEE MEDICAL CHEK UP FORM

Physical Examination :-

Height :- 162 cms.

Weight :- 56 kgs.

Abdomen (CMS) :- 72 cms

Chest Expir(CMS):- 60

Chest Insp(CMS) : 65

Personal History :-

Smoking :- Yes/No ✓

Alcohol sim :- Yes/No ✓

Diabetes :- Yes/No ✓

Allergy :- Yes/No ✓

Body mass index(BMI) :-

Pulse Rate :- 74 minute. (Regular / Abnormal)

Skin :- Normal Open Lesions :- No

Oral Hygeine : Healthy

BP :- 120/80 mm/hg

Nails :-

Complaints if Any :- since 5 years diagnosis in thyroid [T45, Thyronorm 75 daily once]

Family History :- Nil

Complaints if Any :- Nil

Systemic Examination (Abnormality - if Yes Please Explain) :-

CVS - Yes/ No ✓

CNS - Yes/ No ✓

Gi Tract - Yes/No ✓

Abdomen - Yes/ No ✓

Respiratory Tract - Yes/ No ✓

INVESTIGATIONS : (N= Normal, R= See Report)

Complete Blood Picture With ESR = NORMAL

Complete Urine Examination = NORMAL

FBS, PLBS = NORMAL

Colour Vision = NORMAL

USG = NORMAL

* ECG = NORMAL

* SGPT = NORMAL


* Cholesterol = NORMAL

* Eye Examination = NORMAL

* 2D ECHO = NORMAL

Diagnosis (If Any) :- Nil

RECOMMENDATIONS / IMPRESION :- Nil


Dr. V. Narayanaappa,
PHYSICIAN SIGNATURE
M.B.B.S,FCGP,
PHYSICIAN & SURGEON
Regd.No. 88543
Authorised Doctor,
For State Bank of India

Under AP Govt. Regd. Diagnostic Centre R.No.98/2012-2013

Genuineness is our gene

आयकर विभाग
INCOME TAX DEPARTMENT



भारत सरकार
GOVT OF INDIA

SWATHI MAMILLAPALLI

LAKSHMAIAH MAMILLAPALLI

10/06/1985

Permanent Account Number
ASCPM4265D



19012000

M. Swathi
Signature

यदि कार्ड के खोने / चोरी पर कृपया सूचित करें / लॉटरी
आयकर सेना सेवा इकाई, एन एच सी ब्लॉक
पहली मंजिल, टाईम्स टॉवर, कम्पले मिडल स्ट्राम्पाएड
एच. बी. मार्ग, लोकर पोल, मम्बई - 400 013

If this card is lost / someone's card is found.
Please inform / return to:
Income Tax PAN Services Unit, NSDL,
1st Floor, Trade Tower,
Kamala Mills Compound,
S. B. Marg, Lower Parel, Mumbai - 400 013
Tel: 91 22 406 4630 Fax: 91 22 2492 0664
e-mail: pan@nsdl.co.in

M. Swathi

1st Cross, Sai Nagar,
Near Surya Nagar Bus Stop,
ANANTAPURAMU - 515001.
Contact : +91 79893 30974



VASUNDHARA
DIAGNOSTICS
FETAL MEDICINE CENTRE

Patient Name : Mrs. M.Swathi

Patient Id : 220302-022 Gender/Age : Female / 35 Y

Referred By : Amrutha Sai diagnostic center

Reg Date : 02-03-2022

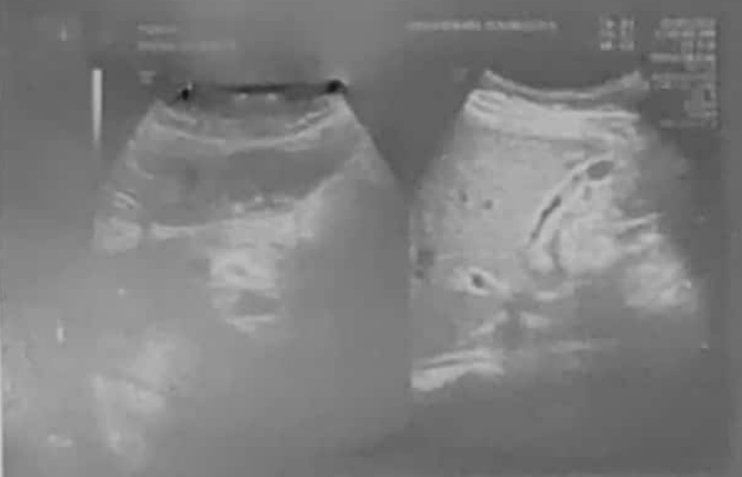ULTRASONOGRAPHY OF WHOLE ABDOMEN

- Liver** : Normal in size(13.3cm) with normal echotexture.
No focal lesions or dilated biliary radicles.
No IHBD / CBD dilatation. Portal vein is normal.
- Gall bladder** : Minimally distended . No calculi .No wall thickening.
- CBD** : Normal in course and calibre .Lumen echo free.
- Portal vein** : Normal in size and course. Lumen echo free .
- Spleen** : Normal in size(8.3cm) with normal echotexture. No focal lesions.
- Pancreas** : Head, body, visualized parts of tail are normal. No focal lesions
or peripancreatic collections are seen.
- Kidneys** : Right kidney: 9.0x4.0 cm, Left kidney: 9.5 x 4.5 cm.
Normal in size, shape and echotexture.Corticomedullary junction is made out.
No calculi or hydronephrosis on both sides.
- Urinary bladder** : Well distended. No calculi are seen.
- Uterus** : Anteverted ,normal in size measuring 6.9x3.5x4.1 cm and normal in echotexture
No focal lesions. Cervix measuring 2 cm.
Endometrial thickness measuring 9.6 mm.
- Ovaries** : Right ovary measuring 2.3x1.8x5.3cm (5.4cc)
Left ovary measuring 2.1x2.4 x3cm (8.6cc)
No focal lesions .No adnexal lesions .
- Others** : No evidence of ascites .Appendix not seen due to bowel gas.
No evidence of lymph node enlargement. **No obvious inflammed bowel seen.**
Defect at umbilicus measuring 1cm with herniation of omentum
- Impression** : **Umbilical hernia (Defect : 1.0cm Content : Omentum)**

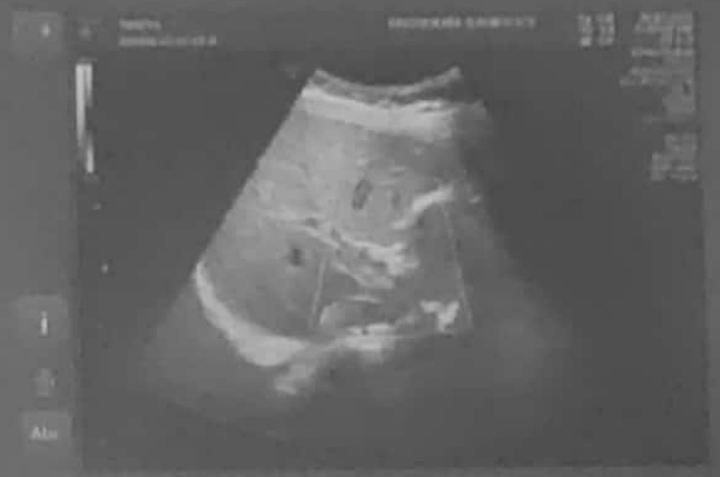For clinical correlation please...

M.Swathi

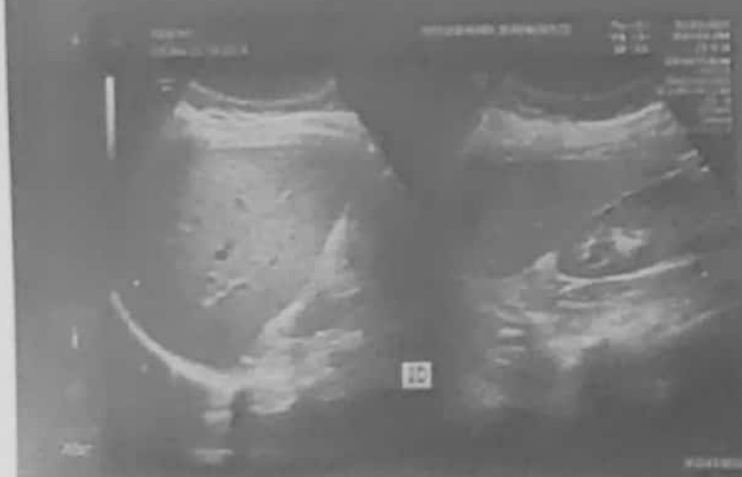Dr.N.Vasundhara
MD Radiology
Consultant in fetal medicine



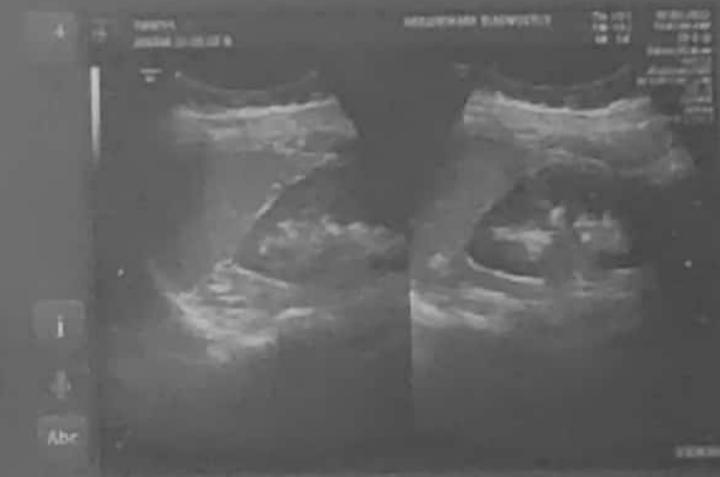2D



CFM



2D



2D

- Select All
- Thumbnail All
- Print
- Full Data
- Zoom
- Freeze
- Focus
- Image
- Help

- ▼
- ▼



MALVINA HOSPITAL & EYE CENTRE



Name of the patient : M. SWATHI

Date: 02-03 -2022


Age/Sex : 35 Y/F

2D ECHO / COLOUR DOPPLER REPORT

Mitral Valve	: NORMAL		
Tricuspid valve	: NORMAL		
Aortic Valve	: NORMAL		
Pulmonary valve	: NORMAL		
IVSD	: 0.97	cm	
LVISDD	: 4.01	cm	EDV: 70 ml
LVPWD	: 0.97	cm	ESV : 25 ml
IVSS	: 1.10	cm	
LVIDS	: 2.56	cm	
LVPWS	: 1.10	cm	
EF	: 66	%	
FS	: 36	%	
LA	: 2.9	cm	
IVs	: INTACT		
IAS	: INTACT		
RA	: NORMAL		
RV	: NORMAL		
Pulm artery	: NORMAL		
AORTA	: 2.4	cm	
Doppler Data	: NO MR/AR/TR		
Mitral Flow	:	E/A = 1.3	
A.F	:	AJV: 110	cm/s
PF	:	PJV: 90	cm/s
TF	:	PAT: 105	ms
Pericardium	: NO PERICARDIAL EFFUSION, NO CLOT.		
Others	:		
Impression	: NORMAL SIZED CARDIAC CHAMBERS, NORMAL VALVES, NO RWMA, NO MR/AR/TR, NO PAH, NO IC SHUNTS, NORMAL LV/RV SYSTOLIC FUNCTION, NO PE, NO CLOT.		

M. Swathi

Dr. J.MILTON ALFRED., Cons. Cardiologist



Recognized by. Dr. Y. S. R. Aarogysri and E. H. S

Phone : 08554 - 226000, Cell : 9441722666




12-2-820, SAI NAGAR, 8th CROSS, ANANTHAPURAMU.



Adult

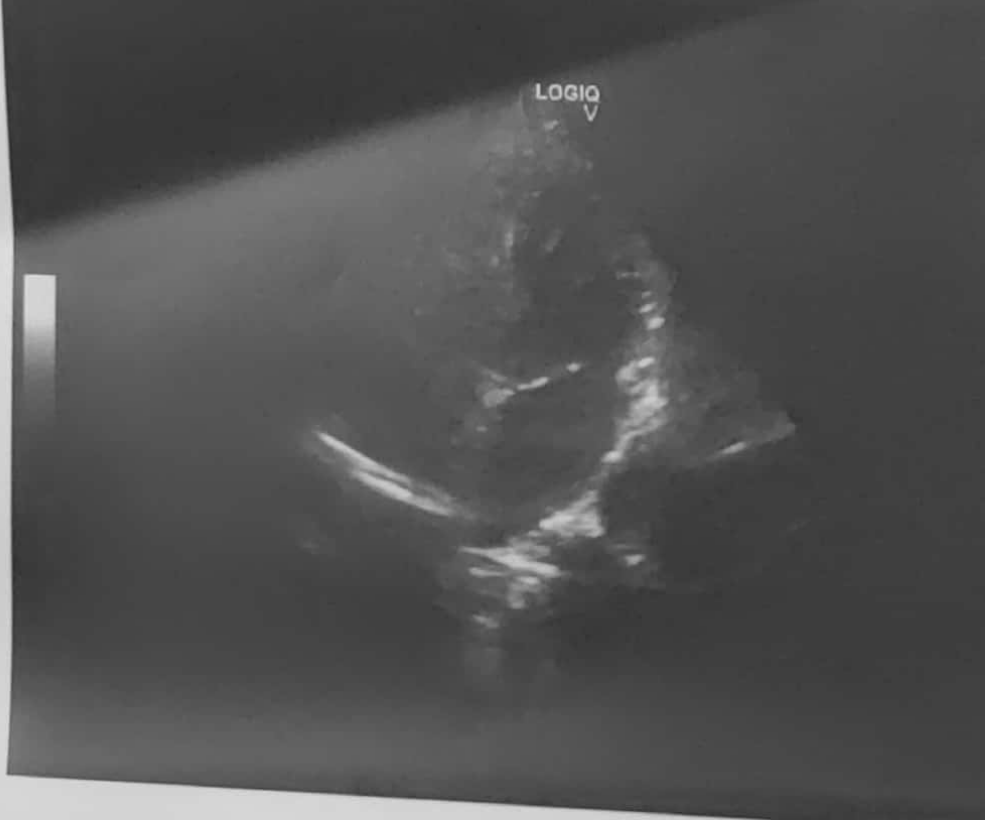
1 IVSd	0.97 cm
2 LVIDd	4.01 cm
EDV(Teich) 70.46 ml	
3 LVPWd	0.97 cm
4 IVSs	1.10 cm
5 LVIDs	2.56 cm
ESV(Teich) 23.60 ml	
EF(Teich) 66.51 %	
%FS 36.26 %	
6 LVPWs	1.10 cm
d	8.07 cm
PEd	0.00 cm



0	FR	38
	AC%	100
5	CHI	
	Frq	3.2
	Gn	52
10	S/A	4/3
	Map	C/D
	D	16.0
15	DR	66



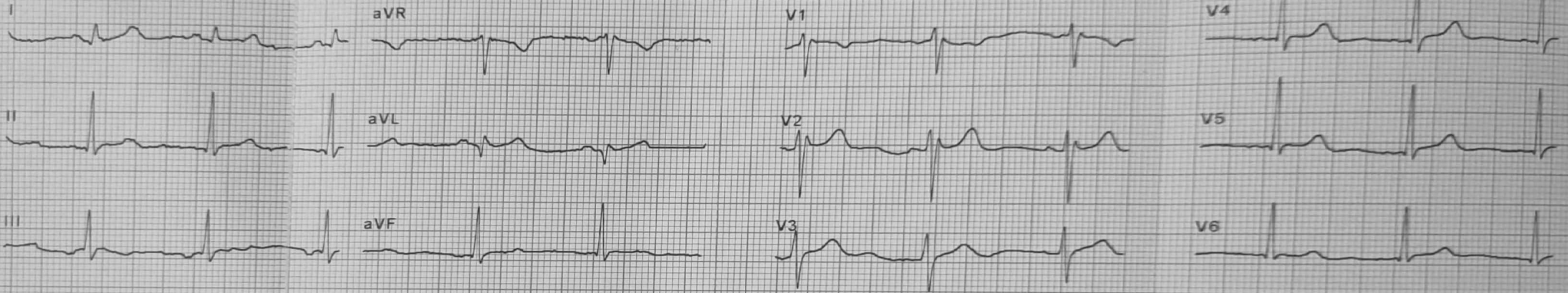
Adult



	FR	68
	AC%	100
0	CHI	
	Frq	3.2
	Gn	47
	S/A	4/3
	Map	H/O
	D	16.0
5	DR	66

HR 74 /bpm

02.03.2022 09:13:29



25 mm/s, 10 mm/mV

LP 25 Hz, AC 50 Hz

Sequential

Poor lead quality

AT-1 G2 (1070 006301), 1.2.1

SCHILLER Part No.2.157044M CE 0123

SCHILLER Part No.2.157044M CE 0123 N.BB

SCHILLER Part No.2.157044M CE 0123

SCHILLER Part No.2.157044M CE 0123 N.BB

02.03.2022 09:13:29

Otherwise normal ECG

Sinus rhythm
Normal electrical axis
Incomplete right bundle branch block
Unconfirmed report

M. Swathi

AT-1 G2 (1070.006301), 1.2.1

Mrs. M Swathi

35g/R

Date: 02/3/2022

Time: 09:15 AM

HR 74/bpm

RR 810 ms
P 82 ms
PR 126 ms
QRS 98 ms
QT 362 ms
QTc 402 ms (Bazett)
Sokolow 2.48 mV
Cornell 0.84 mV
Lewis -0.36 mV
Romhilt 1

P axis 41°
QRS axis 72°
T axis 8°

[Signature]
Dr. V. Narayana

M.B.B.S, FCGP
PHYSICIAN & SURGEON
Regd. No. 38543
Authorised Doctor,
For State Bank of India
ANANTAPUR.

02.03.2022 09:13:29

Name

Patient ID
Date of Birth
Gender
Pacemaker

Height
Weight

BP / mmHg

Medication
Remarks

AT-1 G2 (1070.006301), 1.2.1

