

REVIVAL DIAGNOSTICS



HEALTH CHECK-UP SUMMARY

Name: Niketa Wala

Date: 28/05/2022

Email ID:

Sex: F Age: 33 Years Contact No: 9914716817 Remarks:

Under-weight	<u>—</u>
Normal	<u>✓</u>
Over-weight	<u>—</u>

i> BMI

Height (in Cm): <u>161</u>	Weight (in Kg): <u>57</u>	BMI: <u>22</u>
----------------------------	---------------------------	----------------

ii> Blood Pressure & Pulse

116/74 mmHg
78/min. regular

If high or low, whether the person is on medication: YES / NO

iii> Blood Tests & Lung Function Remarks

RS
CPE
CNS } ⓐ

If abnormal, whether the person is on medication: YES / NO

iv> Eye Test Remarks

Eye Sight: (R+) 6/6 (L+) 6/6
Color Vision: ⓐ

v> Heart Disease

Whether any specific heart ailment detected (ECG findings):
normal

vi> Any other problems needing attention / Overall Assessment:

NO

ⓐ N D Wala

Revival Diagnostic
401, Aqua Corridor,
B/s. Star Bazar, Surat-395009.
Mo. 91062-28601

C.K. Patel
Signature of the Doctor

Dr. Chirag Patel
M.B.B.S. G-49432

Laboratory Test Result are Subject to technical limitation and should be clinically correlate for final diagnosis













Dental Assessment Form

NAME Niketa wala
AGE 33 yrs

DATE 25/05/22
SEX Female

* CHIEF COMPLAINT

- A CLINICAL FEATURES :- 
- 1 CAVIES :- 
- 2 MISSING TOOTH :-
- 3 MALOCCLUSION :-
- 4 FILLING :-  1st lower molar  Lower 1st molar
- B DIAGNOSIS :- 
- C PERSONAL HISTORY :- 
- D PROVISIONAL D/G :- 
- E MEDICAL HISTORY :- 
- F FINAL D/G :- 
- G TREATMENT PLAN :- 

CLINT SIGN

N.D. wala

Revival Diagnostic

401, Aqua Corridor,
B/s. Star Bazar, Surat-395009.

Mo. 97062-28601

DOCTOR SIGN

Laboratory Test Result are Subject to technical limitation and should be clinically correlate for final diagnosis

📍 4th Floor, Aqua Corridor, Hazira Road, Adajan Paal, Surat-395009.

☎ 0261 2747788

✉ revivaldiagnostics.surat@gmail.com

🌐 www.revivaldiagnostics.com

This medical report is not intended for medico-legal purposes.



Name : NIKETA D WALA
Age/Sex : 33 Yrs. Female
UHID : 12253
Ref. By Dr. : MEDI WHEEL
Category : CTR

Date : 28-May-2022 9:52 am
Receipt No : 1512
Lab ID : 13992


Collection Date & Time : 28-May-2022 9:52 am

CBC HAEMOGRAM

PARAMETER	RESULT	UNITS	Biological Reference Range
Hemoglobin	: 12.5	gm/dL	11.5-16.4
RBC Count	: 4.91	m/c.mm.	3.9-5.6
WBC Count	: 9650	c. mm.	4,000 - 10,000
Platelet Count	: 2.85	c. mm.	1.5 Lac - 5.0 Lac
Blood Indices			
Hematocrit (PCV)	: 39.7	%	36-47 %
MCV	: 80.9	fl	75-96
MCH	: 25.5	pg	27-32
MCHC	: 31.5	g/dL	30-36
RDW	: 13.2	%	11- 16
ESR (WINTORBE)	: 06	mm./hr.	0-30 below the age of 50 yrs.
DIFF WBC Count			
Neutrophils	: 62	%	40-75
Lymphocytes	: 33	%	20-50
Eosinophils	: 03	%	1-6
Monocytes	: 02	%	2-10
Basophils	: 00	%	0-5
Band Form	: 00	%	0-5
Smear Study			
Platelets in Smear	: Adequate		
Malarial Parasites	: Malarial Parasites Not Detected		
Blood Group	: "A"		
RH Factor	: Positive		

Lab Technician/Technologist

Revival Diagnostic
401, Aqua Corridor,
B/s. Star Bazar, Surat-395009
Mo. 91062-28604


Dr. Mihir Icecreamwala
M.B.B.S.,M.D. Pathologist

Operator Name: Zarna Gandhi | Subject to technical limitation and should be clinically correlate for final diagnosis | Reporting Print Date & Time: 28-May-2022



Name : NIKETA D WALA
Age/Sex : 33 Yrs. Female
UHID : 12253
Ref. By Dr. : MEDI WHEEL
Category : CTR

Date : 28-May-2022
Receipt No : 1512
Lab ID : 13992


Collection Date & Time : 28-May-2022 9:52 am

REPORT OF SERUM LIPID PROFILE

Test	Result	Biological Reference Range	
Serum Cholesterol (Mehod : CHOD-POD)	153	Normal	: Less than 200 mg / dl
		Borderline	: 200 to 239 mg / dl
		Undesirable	: More than 240 mg / dl
Serum Triglyceride (Mehod : GPO-POD)	143	Normal	: Less than 150 mg / dl
		Borderline High	: 150 to 199 mg / dl
		High	: 200 - 499 mg / dl
		Very High	: More than 500 mg / dl
Serum HDL - Cholesterol (Mehod : PVS-PEGME Precipitation with CHOD-POD)	50	Desirable	: More than 65 mg / dl
		Borderline	: 45 to 65 mg / dl
		Undesirable	: Less than 45 mg / dl
Serum LDL - Cholesterol (Mehod : Calculated)	74.4	Optimal	: Less than 100 mg / dl
		Above Optimal	: 100 - 129 mg / dl
		Borderline High	: 130 to 159 mg / dl
		High	: 160 to 189 mg / dl
		Very High	: More than 190 mg / dl
VLDL (Mehod : Calculated)	28.6	Normal	: 5 to 30 mg / dl
Chol. / HDL - Chol. Ratio	3.1	Low Risk	: Less than 3.1
		Medium Risk	: 3.1 to 5.9
		High Risk	: More than 6
LDL / HDL - Chol. Ratio	1.49	Low Risk	: Less than 3.55
		Medium Risk	: 3.55 - 4
		High Risk	: More than 6

Lab Technician/Technologist

Revival Diagnostic
401, Aqua Corridor,
B/s. Star Bazar, Surat-395009
Mo. 91062-28601


Dr. Mihir Icecreamwala
M.B.B.S..M.D. Pathologist

Operator Name: Zarna Gandhi

Reporting PrintDate & Time: 28-May-2022

Laboratory Test Result are Subject to technical limitation and should be clinically correlate for final diagnosis



Name : NIKETA D WALA
Age/Sex : 33 Yrs. / Female
UHID : 12253
Category : CTR
Ref. By Dr. : MEDI WHEEL

Date : 28-May-2022 9:52 am
Receipt No : 1512
Lab ID : 13992
Collection Date & Time : 28-May-2022 9:52 am

ROUTINE URINE EXAMINATION REPORT

PHYSICAL EXAMINATION :

Quantity : 25 ml
Colour : Pale Yellow
Appearance : Clear
Reaction : Acidic
Specific Gravity : 1.010

CHEMICAL EXAMINATION :

Proteins : Absent
Sugar : Absent
Acetone : Absent
Bile Salts : Absent
Bile Pigments : Absent
Urobilinogen : Normal
O.B.T. : Negative

MICROSCOPIC EXAMINATION :

Pus Cells : 1-2/hpf.
R. B. C. : Absent
Epithelial Cells : 1-2/hpf.
Bacteria : Absent
Casts : Absent
Crystals : Absent
Yeast cell : Absent
Mucus : Absent
Other Findings : NIL

Revival Diagnostic

401, Aqua Corridor,
B/s. Star Bazar, Surat-395009
Mo. 91062-28601

Lab Technician/Technologist


Dr. Mihir Icecreamwala
M.B.B.S.,M.D. Pathologist

Laboratory Test Result are Subject to technical limitation and should be clinically correlate for final diagnosis



Name : NIKETA D WALA

Date : 28-May-2022

Age/Sex : 33 Yrs. Female

Receipt No : 1512

UHID : 12253

Ref. By Dr. : MEDI WHEEL

Lab ID : 13992

Report By Dr. : Dr.

Catagory : CTR

Collection Date & Time : 28-May-2022 9:52 am

REPORT OF GLYCOSYLATED HEMOGLOBIN [HbA1C]

Parameter	Result	Unit	Biological Reference Interval
Hemoglobin A1C(HbA1C)	5.2	%	HbA1C Degree of Glucose Control

< 5.6 % Non Diabetics
5.7 - 6.4 % Prediabetics
> = 6.5 % Diabetics

(REF : Wallace, 11th Edition)

REMARKS:

6 - 7 % Excellent Control
7 - 8 % Good Control
8 -10 % Unsatisfactory Control
> 10 % Poor Control


Method : High performance liquid chromatography (HPLC)

MEAN BLOOD GLUCOSE OVER THE PAST 60 DAYS FROM THE HbA1C RESULT : 000 mg/dl

Remarks : GHb test is useful for the long term control and monitoring of diabetes mellitus since it reflects the integration of blood glucose levels during past 4-8 weeks.

Lab Technician/Technologist

Revival Diagnostic
401, Aqua Corridor,
B/s. Star Bazar, Surat-395009
Mo. 91062-28601


Dr. Mihir Icecreamwala
M.B.B.S..M.D. Pathologist

Operator Name :Zarna Gandhi

Reporting Print Date & Time :28-May-2022

Laboratory Test Result are Subject to technical limitation and should be clinically correlate for final diagnosis

4th Floor, Aqua Corridor, Hazira Road, Adajan Paal, Surat-395009.

0261 2747788

revivaldiagnostics.surat@gmail.com

www.revivaldiagnostics.com

This medical report is not intended for medico-legal purposes.



Name : NIKETA D WALA
Age/Sex : 33 Yrs. Female
UHID : 12253
Ref. By Dr. : MEDI WHEEL
Category : CTR

Date : 28-May-2022 9:52 am
Receipt No : 1512

Lab ID : 13992

Collection Date & Time : 28-May-2022 9:52 am

THYROID TEST


TEST	RESULT	Biological Reference Range
T3	1.01	0.87 - 1.78 ng/ml
T4	6.37	4.60 - 13.5 ug/dl
TSH	1.74	0.50 - 5.50 uIU/ml 5.5 to 15 uIU/ml - Suggested Clinical co-relation Or Repeat test with new sample as physiological factors can give falsely high TSH Above 15uIU/ml Hypothyroid

PREGNANT WOMEN normal ranges for TSH:
1st Trimester :0.0878 - 2.8293 uIU/ml
2nd Trimester :0.1998 - 2.7915 uIU/ml
3rd Trimester :0.307 - 2.9028 uIU/ml
Ref:Tietz Fundamentals of Clinical Chemistry.

Revival Diagnostic

401, Aqua Corridor,
B/s. Star Bazar, Surat-395009
Mo. 91062-28601

Lab Technician/Technologist


Dr. Mihir Icecreamwala
M.B.B.S.,M.D. Pathologist

Operator Name : Zarna Gandhi

Reporting Print Date & Time : 28-May-2022

Laboratory Test Result are Subject to technical limitation and should be clinically correlate for final diagnosis

4th Floor, Aqua Corridor, Hazira Road, Adajan Paal, Surat-395009.

0261 2747788

revivaldiagnostics.surat@gmail.com

www.revivaldiagnostics.com

This medical report is not intended for medico-legal purposes.



NAME: Niketa Wala SEX: F
BIRTHDATE: 28/02/1989 AGE: 33

DEPARTMENT OF OPHTHALMOLOGY

EYE TEST:

1. VISION:

RIGHT EYE - 6/6
LEFT EYE - 6/6

2. COLOR VISION:

RIGHT EYE - (2)
LEFT EYE - (2)

3. FUNDUS:

RIGHT EYE - (2)
LEFT EYE - (2)

REMARKS:

N.D. Wala

Revival Diagnostic
401, Aqua Corridor,
B/s. Star Bazar, Surat-395009.
Mo/ 91062-28601

Ophthalmologist/Optomtrist

Laboratory Test Result are Subject to technical limitation and should be clinically correlate for final diagnosis



2D-ECHOCARDIOGRAPHY & COLOR DOPPLER REPORT

Name:	NIKETA D. WALA	Age/Gender	33Yrs /F
Referred by:	MEDI WHEEL	Date	28/05/2022

VITALS: BP = 116/74mmHg, PULSE =78 bpm, SPO2 =98%

INDICATION: Preventive Health check up

- **CARDIAC CHAMBERS:** Left Ventricle: Normal size, Left Atrium: Normal size.
- No e/o thrombus in LA/LV.
- **Right Atrium:** Normal size. **Right Ventricle:** Normal size,
- **Normal Right Ventricular function.** (TAPSE=20mm)
- **Normal Left Ventricular systolic function. LVEF = 60% ,**
No regional wall abnormality. No thinning / scarring / dyskinesia of LV wall.
- **No Concentric Left Ventricular Hypertrophy.** (IVSd= 11 mm),
- **LV Compliance :**
No Left Ventricular Diastolic Dysfunction [LVDD]. No Doppler e/o raised LVEDP.
- **VALVES:**
- Structurally Normal Mitral valve/ Aortic valve/Tricuspid valve/ Pulmonary valve.
No significant Valvular Stenosis.
- **Doppler findings:** AV max = 1.23 m/s, PV max = 0.9 m/s.
Trivial Pulmonary Regurgitation, Trivial Tricuspid regurgitation.
- **No Pulmonary Arterial Hypertension.** PASP by TRjet vel.method = 23 mmHg.
- **SEPTAE:** IAS / IVS Appear Intact.
- **IVC :** Normal in dimension and shows good inspiratory 12mm collapse.
- **OTHERS:** No e/o Pericardial effusion / vegetation.

IMPRESSION:

**NORMAL LV SYSTOLIC FUNCTION, LVEF= 60 %, NO RWMA,
NO LVH , NO LVDD ,TRIVIAL PR/TR, NO PAH.**

Revival Diagnostic
401, Aqua Corridor,
B/s. Star Bazai, Surat-395009.
Mo. 91062-28601


DR SUSHIL YADAV
CONSULTING & CLINICAL
CARDIOLOGIST

Laboratory Test Result are Subject to technical limitation and should be clinically correlate for final diagnosis

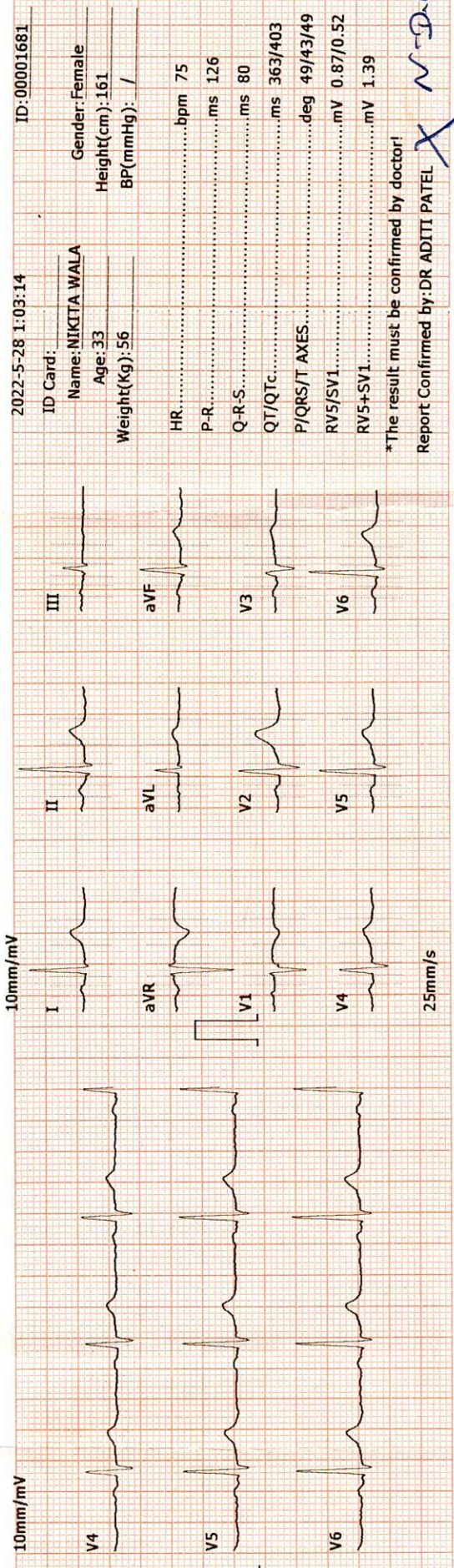
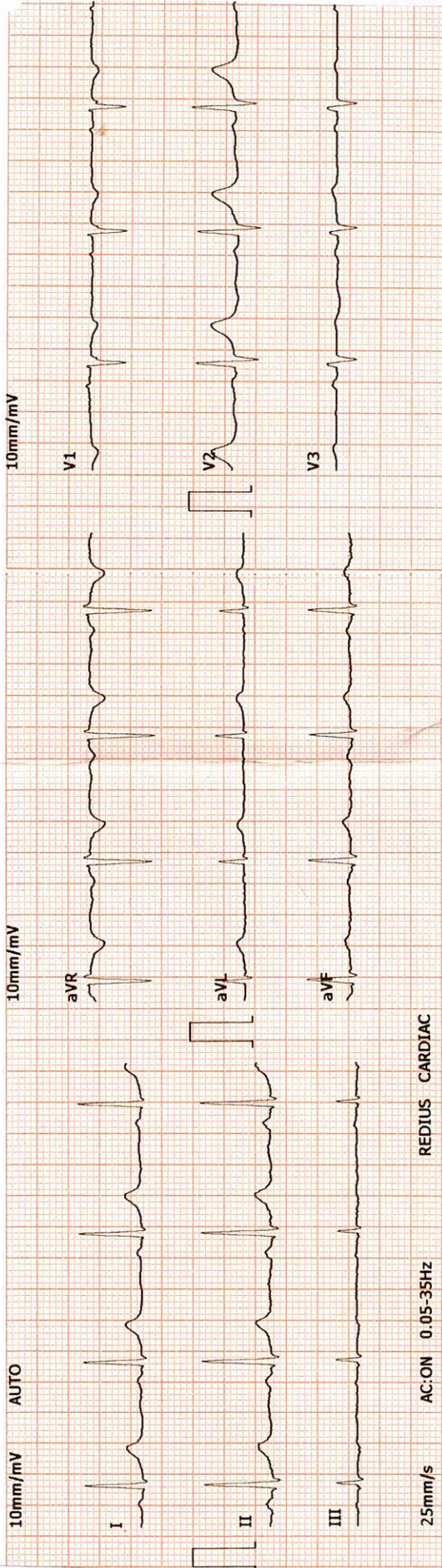
4th Floor, Aqua Corridor, Hazira Road, Adajan Paal, Surat-395009.

☎ 0261 2747788

✉ revivaldiagnostics.surat@gmail.com

🌐 www.revivaldiagnostics.com

This medical report is not intended for medico-legal purposes.



2022-5-28 1:03:14 ID:00001681

ID Card: Name: MIKITA WALA Gender: Female
 Age: 33 Height(cm): 161
 Weight(Kg): 56 BP(mmHg): /

HR:bpm 75
 P-R:ms 126
 Q-R-S:ms 80
 QT/QTc:ms 363/403
 P/QRS/T AXES:deg 49/43/49
 RV5/SV1:mV 0.87/0.52
 RV5+SV1:mV 1.39

*The result must be confirmed by doctor!
 Report Confirmed by: DR ADITI PATEL X *N.D.W.C.*

DR. ADITI PATEL
 M.B.B.S., D. CARD (MUM)
 CLINICAL CARDIOLOGIST
 REG.NO.G-42901

Revival Diagnostics
 401, Aqua Corridor,
 B/s. Star Bazar, Surat-395009.
 No. 91062-28601



Name : NIKETA D WALA

Age/Sex : 33 Yrs. Female

UHID : 12253

Ref. By Dr : MEDI WHEEL

Category : CTR

Date : 28-May-2022

Rec No : 1512

Lab ID : 13992

Collection Date & Time : 28-May-2022 9:52 am

ECG

Test	Observed Value	Biological Reference Interval
------	----------------	-------------------------------

ECG

1. The rhythm is sinus.
2. Heart rate is 75 beats per minute.
3. Normal P, QRS, T wave axis.
4. Normal PR, QRS, Q.T. Duration.
5. No pathological q wave or ST-T changes seen.
6. No evidence of chamber hypertrophy or enlargement seen.

IMPRESSION : ECG WITHIN NORMAL LIMITS

DR. ADITI PATEL
M.B.B.S., (D. CARDIUM)
CLINICAL CARDIOLOGIST
REG.NO.G-42901

Revival Diagnostic
401, Aqua Corridor,
B/s. Star Bazar, Surat-395009.
Mo. 91062-28601

Laboratory Test Result are Subject to technical limitation and should be clinically correlate for final diagnosis

4th Floor, Aqua Corridor, Hazira Road, Adajan Paal, Surat-395009.

☎ 0261 2747788

✉ revivaldiagnostics.surat@gmail.com

🌐 www.revivaldiagnostics.com

This medical report is not intended for medico-legal purposes.



Name : NIKETA D WALA

Age/Sex : 33 Yrs. Female

UHID : 12253

Ref. By Dr : MEDI WHEEL

Catagory : CTR

Date : 28-May-2022

Rec No : 1512

Lab ID : 13992

Collection Date & Time : 28-May-2022 9:52 am

CHEST RADIOGRAPH-PA VIEW

Hilar shadows are within normal limits.

Pulmonary vasculature appears normal.

Cardiac appears normal in size.

Both domeh of the diaphragm are smooth.

Both costophrenic recesses are clear.

Both lung fields appear normal.

Visualized bones and soft tissue shadows appear normal.

IMPRESSION:

NORMAL STUDY.

Dr. Chirag K. Patel

MBBS-DMPD

Reg. No. G-23509

DR. CHIRAG K. PATEL
Revival Diagnostic
RADIOLOGIST

4th Floor, Aqua Corridor,
Hazira Main Road,
Surat-395009.
Phone: 0261 2747788

Laboratory Test Result are Subject to technical limitation and should be clinically correlate for final diagnosis

R

NAME : NIKETA D WALA
AGE : 33 YRS / FEMALE
REF BY: MEDI WHEEL





NAME	NIKETA WALA	DATE	28-May-22
REFERRED BY	MEDI WHEEL	AGE / SEX	33 YRS / F

Thanks for the reference

USG ABDOMEN AND PELVIS

LIVER: is normal in size and shows homogenous echotexture.

No evidence of intrahepatic biliary radicles dilatation / focal space occupying lesion.

The portal vein and common bile duct shows normal caliber.

GALL BLADDER: is distended and shows smooth walls. Wall thickness is normal.

No evidence of sludge / calculus. No evidence of pericholecystic collection.

SPLEEN: Is normal in size and shows normal echo pattern.

PANCREAS: shows normal echo anatomy and its relationship with splenic vein is normal.

KIDNEYS: Both the kidneys are normal in size, shape and location and show normal cortico-medullary differentiation.

Right kidney measures- 9.4 x 4.5 cms.

Left kidney measures- 9.7 x 4.4 cms.

No evidence of hydronephrosis or calculus.

URINARY BLADDER: is distended with smooth walls.

No evidence of diverticulum or calculus.

UTERUS: is anteverted and shows normal endometrial echo reflectivity.

IUCD noted

OVARY: Both ovaries are normal in size and appear normal.

No evidence of ascites or pleural effusion.

Fluid and gas filled bowel loops with normal wall thickness and peristalsis noted.

IMPRESSION:

No significant abdominal pathology noted....

Dr. Chirag K. Patel
MBBS-DMPD
Reg. No. 7-23509
DR. CHIRAG K. PATEL
RADIOLOGIST
4th Floor, Aqua Corridor,
Nr. Star Bazar, Hazira Main Road,
Adajan, Surat-395009.
Mo. 97266 726683

Laboratory Test Result are Subject to technical limitation and should be clinically correlate for final diagnosis

4th Floor, Aqua Corridor, Hazira Road, Adajan Paal, Surat-395009.

0261 2747788

revivaldiagnostics.surat@gmail.com

www.revivaldiagnostics.com

This medical report is not intended for medico-legal purposes.