

DAKSH HOSPITAL

396 - 397, Gandhi Nagar, Scheme No. 8, ALWAR -301001

Ref. No.

Date.....

MEDICAL EXAMINATION REPORT

Mediwheel (BOB)

Name: Mr Santosh Kumar

Age: 32 yrs Sex: Male

Date: 08/04/2023

General Physical Examination

Height	:	168cm	Weight	:	58 kg
Pulse	:	88/m	BP	:	124/84
Temp.	:	N	Respiration	:	14/m
BMI	:	20.5			

Systemic Exam:-

NORMAL

Dental Check up :-

NORMAL

Eye check-up :-

NORMAL

Skin Check up:-

NORMAL

ENT Check up:-

NORMAL

Gynae Check up:-


N/A

Impression:-

left kidney has separate cyst with septa

Recommendation:-

CT- KUB


 Dr. Mukesh Kumar Gupta
 MD Gen. Medicine

 डॉ. मुकेश गुप्ता
 M.D. F.C.C.S.

 फिजिशियन एवं मधुमेह रोग विशेषज्ञ
 दक्ष हॉस्पिटल, अलवर
 रजि. नं. 5423/16202

Results

Run Date 08/04/2023 10:46:21 AM

Operator DAKSH

Last Name

Sample ID 4

First Name MR SANTOSH KUMAR

Department

Gender Male Age

Physician DR. MUKESH GUPTA M.D

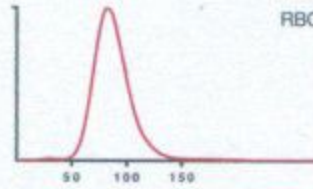
Patient ID AUTO_PID12891

Type Man

Date of birth

Sample comments

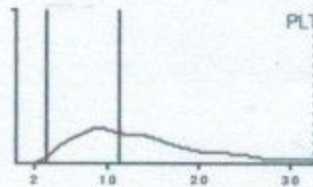
				Range
RBC	4.90	*	10 ⁶ /μL	3.80 - 5.50
HGB	14.0		g/dL	13.0 - 17.0
HCT	45.4	*	%	39.0 - 52.0
MCV	92.5	*	μm ³	76.0 - 100.0
MCH	28.5		pg	26.0 - 34.0
MCHC	30.8	L	g/dL	32.0 - 35.0
RDW-CV	17.6	H	%	11.0 - 16.0
RDW-SD	60.4	H	μm ³	37.0 - 49.0



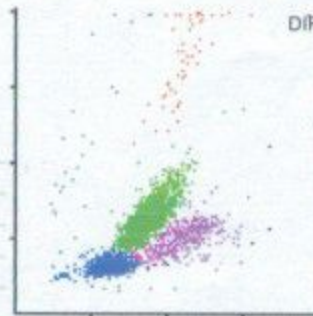
Recommended actions

Slide review
Susp. Pathologies
Anisocytosis
Macroplatelets

				Range
PLT	201	*	10 ³ /μL	150 - 450
PCT	0.26	*	%	0.15 - 0.40
MPV	13.1	H*	μm ³	8.0 - 11.0
PDW	26.0	H*	μm ³	11.0 - 22.0
P-LCC	111		10 ³ /μL	44 - 140
P-LCR	55.2	h	%	18.0 - 50.0



			Range
WBC	5.34		10 ³ /μL 3.50 - 10.00
	#	Range	% Range
NEU	3.01	1.60 - 7.00	56.5 40.0 - 75.0
LYM	1.98	1.00 - 3.00	37.1 20.0 - 45.0
MON	0.19	0.20 - 0.80	3.6 2.0 - 10.0
EOS	0.09	0.00 - 0.50	1.6 1.0 - 6.0
BAS	0.06	0.00 - 0.15	1.2 h 0.0 - 1.0
LIC	0.01	0.00 - 0.10	0.2 0.0 - 1.0



डॉ० मुकेश गुप्ता
M.D. F.C.C.S.

फिजिशियन एवं मधुमेह रोग विशेषज्ञ
दक्ष हॉस्पिटल, अलवर
रजि. नं. 5423/16262

08/04/2023 10:47:33 AM

Doctor

Printed by : DAKSH

S/N107YOXH041 TECHNOLOGIST

All investigation have their own limitations regarding the sensitivity & specificity of individual assay procedures, isolated laboratory investigations never confirm the final diagnosis of the disease. They only help in arriving at a diagnosis in conjunction with clinical presentation and other related investigations. Report is not valid for medico-legal purpose subject to ALWAR jurisdiction only.

Date :-08/04/2023

Name :- MR. SANTOSH KUMAR MEENA

Age & Sex :- 33Yrs/ male

Refd. :- Dr Mukesh Gupta M.D.

	TEST NAME	RESULT	REFERENCE RANGE	
	ESR	10	00 -20 mm/hrs	
	Blood Group & Rh Factor	O * POSITIVE		
	HbA1C	4.5	4 - 5.6%	
	Blood Sugar (F)	79.2	< 70 - 100 mg/dl	
	Blood Sugar (PP)	97.2	< 140 mg/dl	
	Urine Sugar (F)	NIL	-	
	Urine Sugar (PP)	NIL	-	
LIVER	S.Bilirubin Total	1.00	0.30 - 1.20 mg/dl	
	S.Bilirubin Direct	0.30	0.10 - 0.30 mg/dl	
	S.Bilirubin Indirect	0.70	0.30 - 0.90 mg/dl	
	S.G.O.T.	22	u/l	
	S.G.P.T.	29	u/l	
	S.Alk. Phosp.	191	u/l	
	G.G.T.	30	5 -40 u/l	
	Total Protein	6.8	6.5 - 8.5 gm/dl	
	Albumin	3.7	3.8 - 5.4 gm/dl	
	Globulin	3.1	2.3 - 3.5 gm/dl	
	A/G Ratio	1.2	-	
	AST/ALT Ratio	0.9	-	
KIDNEY	Blood Urea	30.1	15 -45 mg/dl	
	S.Creatinine	1.1	0.60 - 1.30 mg/dl	
	BUN	20.0	6 -24 mg/dl	
	S.Uric Acid	4.7	M 3.1 - 7.0, F 2.5 - 5.6 mg/dl	
	BUN/Creatinine Ratio	18.1	-	
LIPID PROFILE	Total Cholesterol	145.1	Up to 200 mg/dl	
	S.HDL	43.1	30 - 70 mg/dl	
	S.LDL	80.1	Up to 170 mg/dl	
	S.VLDL	22.1	5.0 - 40 mg/dl	
	S. Triglycerides	110.1	Up to 170 mg/dl	
	LDL/HDL Ratio	1.8	-	
	Total Cholesterol/ HDL Ratio	3.3	-	
THYROID	T3	85.2	1.2 - 2.8 nmol/L	
	T4	7.2	77 -155 nmol/L	
	TSH	2.16	0.30 - 5.0 mU/L	
		URINE EXAMINATION	<i>Microscopic Examination :</i>	
General/Chemical Examination:			RBC	Absent
	Colour	Pale Yellow	WBC	0 - 1
	Reaction	Acidic	Epithelial Cells	Absent
	Specific Gravity	QNS	Cast	Absent
	Appearance	Clear	Crystal	Absent
	Albumin	Nil	Spermatozoa	Absent
	Sugar	Nil	Amorphous Sediments	Absent
			Other	Absent
X-RAY CHEST	NORMAL STUDY			
		STOOL EXAMINATION	<i>Microscopic Examination :</i>	
General/ Chemical Examination:			RBC	-
	Colour	-	WBC	-
	Consistency	-	Ova & Parasites	-
	PH	-		
	Reducing Substances	-		

Doctor

डॉ. मुकेश गुप्ता

M.D. F.C.C.S.

एजिनियर एवं मधुमेह रोग विशेषज्ञ

TECHNOLOGIST

All investigation have their own limitations regarding the sensitivity & specificity of individual assay procedures, isolated laboratory investigations never confirm the final diagnosis of the disease. They only help in arriving at a diagnosis in conjunction with clinical presentation and other related investigations. Report is not valid for medico-legal purpose subject to ALWAR jurisdiction only.



दक्ष हॉस्पिटल

396, गाँधी नगर स्कीम नं.8, अलवर (राज०) ☎ 0144-2703340

Sonography / 2D Echo Cardiography / Doppler Report

2D/ ECHO REPORT

Name: - Mr. Santosh Kumar

Age: - 32 Yrs

Date: - 8-Apr-23

Reg. No.: - Alw/2009/04
BOB health checkup

PROCEDURES:

M-MODE/2D/DOPPLER/COLOR/CONTRAST B.A.S. M²

MEASUREMENT:		DOPPLER:	
AOD	22	NORMAL	NORMAL (cm/sec.)
LA	24	(20- 37mm)	MV 0.4 (0.8- 1.3) MR No
AVO	18	(19- 40mm)	AV 1.3 (1.2- 1.8) AR No
RVDd.	16	(12- 25mm)	TV 0.6 (0.3- 0.8) TR No
		(03- 09mm)	PV 0.8 (0.7- 1.1) PR No
LVDd	45	(37- 56mm)	MITRAL VALVE-
LVDs	29	(22- 40mm)	AML Normal
IVS d	11	(06- 12mm)	PML Normal
IVS s	9		
PWd	5	(05- 10mm)	AORTIC VALVE Normal
LV FUNCTION		TV & PV are normal.	
M- E- S Separation		<0.9cm	
Minor		24.42%	
LV Ejection Fraction	91%	65 +/- 12%	

LV WALL MOTION: NO RWMA
ALL CARDIAC CHAMBERS ARE NORMAL
ALL VALVES ARE NORMAL
NO CLOT, VEGETATION, PERICARDIAL EFFUSION

FINAL DIAGNOSIS: NORMAL STUDY

Adv: - Follow up/ review at higher center for confirmation

Note:- Please Correlate clinically. Due to technical limitations as well as inaccuracies inherent in the laboratory and statistical analysis of biological process. Diagnostic accuracy of ECHO is up to 95% only
Report is not valid for medico-legal purpose.


Dr. Mukesh Kumar Gupta
DR. MUKESH GUPTA
Physician & Sonologist
PHYSICIAN
RM 5423/16262



भ्रूण लिंग परीक्षण की शिकायत
104 टोल फ्री सेवा पर भी की
जा सकती है

भ्रूण लिंग परीक्षण की शिकायत 104 टोल फ्री सेवा पर भी की जा सकती है।



दक्ष हॉस्पिटल

396, गाँधी नगर स्कीम नं.8, अलवर (राज०) ☎ 0144-2703340

Sonography / 2D Echo Cardiography / Doppler Report

Name: MR. Santosh Kumar /M/32 YRS

BOB HEALTH CHECK UP

Date: 8-Apr-23

U.S.G. OF ABDOMEN & PELVIS

LIVER

Liver is normal in size shape with normal echo-texture. Intra hepatic biliary radicals are not dilated.
No evidence of focal or diffuse lesion.

GALL BLADDER

Gall bladder is normal dilated. Lumen clear. Wall thickness normal. CBD normal

PANCREAS

Pancreas is normal in size, shape & echo-texture.

SPLEEN

Normal in size with normal shape & echo- texture.

BOTH KIDNEY

Left kidney has 7.1x3.9 cystic area with septa & renal pelvic stone of about 9 mm without hydronephrosis.
Right kidney is normal.

PROSTATE & URINARY BLADDER is normal shape, size & echo texture..

Advice- X Ray KUB / URINE EXAM

Please correlate clinically. USG accuracy is 95 % due to technical limitations as well as inaccuracies inherent in the laboratory and statistical analysis biological process.

This report is not valid for medico-legal cases.

DR. MUKESH GUPTA
SONOLOGIST
Physician & Sonologist
RM 5423/16262



एक लिंग परीक्षण की शिकायत
एक टोल फ्री सेवा पर भी की
जा सकती है

भ्रूण लिंग परीक्षण की शिकायत 104 टोल फ्री सेवा पर भी की जा सकती है।

ID: 583

08-04-2023 13:30:00

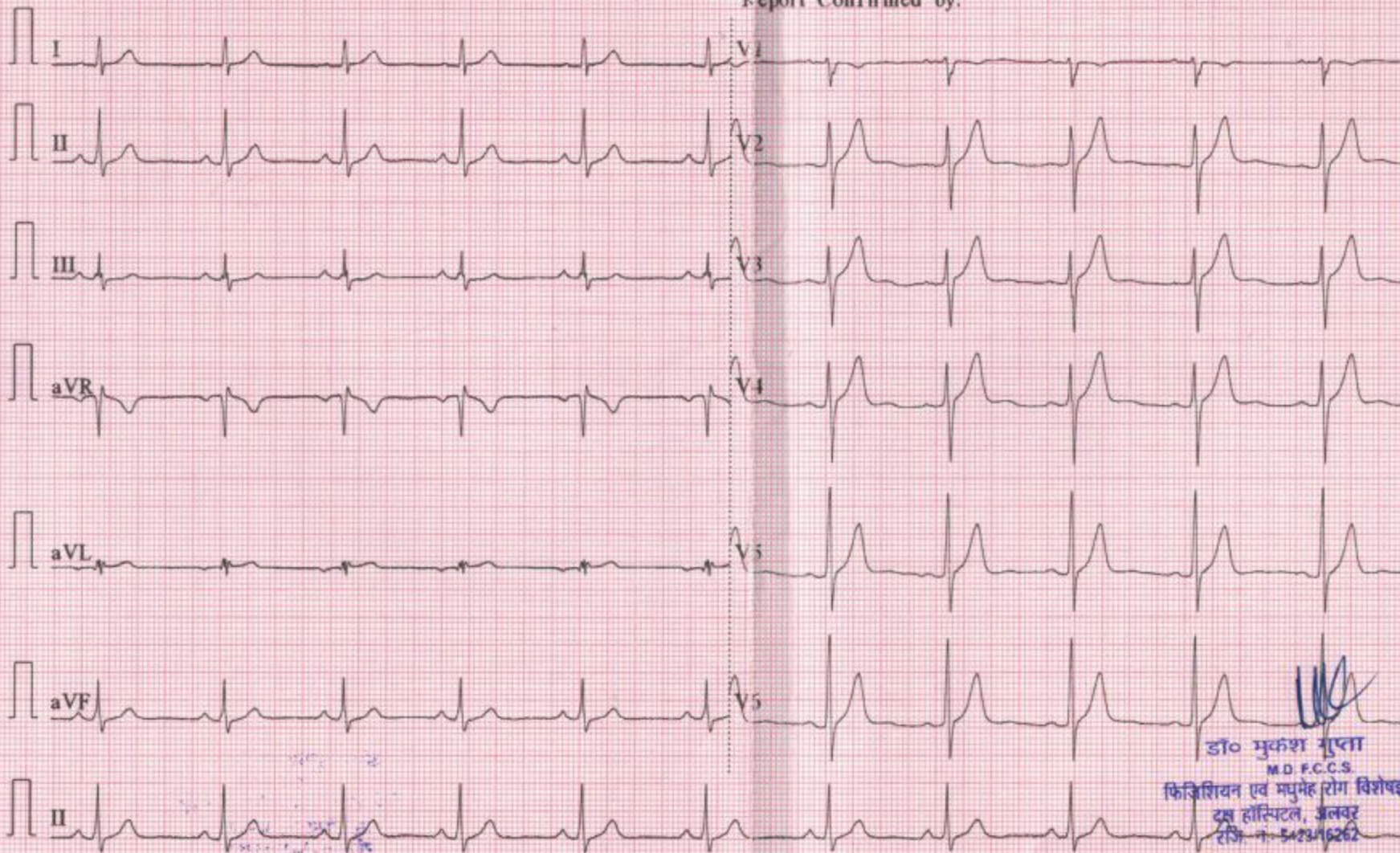
Male Years
Req. No. :

HR : 66 bpm
 P : 100 ms
 PR : 154 ms
 QRS : 94 ms
 QT/QTcBz : 352/369 ms
 P:QRS:T : 77/57/44 °
 RV5/SV1 : 1.542/0.431 mV

Diagnosis Information:

Sinus rhythm
 Tall T waves - consider acute ischemia or hyperkalemia
 Borderline ECG

Report Confirmed by:



डॉ० मुकेश गुप्ता
 M.D. F.C.C.S.

फिजिशियन एवं मधुमेह रोग विशेषज्ञ
 दक्ष हॉस्पिटल, अलवर
 रजि. नं. 5423/16262

R

