



Park Hospital
GROUP SUPER SPECIALITY HOSPITAL

28/1/23



670719

Mr Deepanshu

31y/M

Routine eyes checkup

VV { G/GP
G/GP = glasses

NV { NV
NV

NCT { 23
20

Colour vision - Normal (DE)

fundus - Normal



[Handwritten signature]

(This is only professional opinion and not the diagnosis. Please correlate clinically)

Q Block South City 11, Sohna Road, Main Sector-47, Gurgaon, Haryana

Ph.: 0124-4900000 (100 Lines) Fax : 0124-2218733 E-mail : parkmedicenters@gmail.com

PARK GROUP OF HOSPITALS : West Delhi • South Delhi • Gurgaon • Karnal • Panipat • Hodai • Ambala • Behror

the health care providers

the health care providers



Scanned with OKEN Scanner



BP 120/70
wt 83 kg
HT - 5.7 feet

Go generalised
wallow
to neck

Asw

Revised Report



[Handwritten Signature]

(This is only professional opinion and not the diagnosis, Please correlate clinically)

Q Block South City 11, Sohna Road, Main Sector-47, Gurgaon, Haryana
Ph.: 0124-4900000 (100 Lines) Fax : 0124-2218733 E-mail : parkmedicenters@gmail.com

PARK GROUP OF HOSPITALS : West Delhi • South Delhi • Gurgaon • Karnal • Panipat • Hodal • Ambala • Behror



DEPARTMENT OF PATHOLOGY

Patient Name : Mr. DEEPANSHU
MR No : 670719
Age/Sex : 31 Years 5 Months 29 Days / Male
Type : OPD
TPA/Corporate : MEDIWHEEL PVT LTD

Bill Date : 28/01/2023
Reporting Date : 28/01/2023
Sample ID : 92833
Bill/Req. No. : 24031694
Ref Doctor : Dr.RMO

Test	Result	Blo. Ref. Interval	Units	Method
CBC				
HAEMOGLOBIN	15.6	12 - 16	gm/dL	COLORIMETRY
TOTAL LEUCOCYTE COUNT	5300	4000-11000	/ μ L	ELECTRICAL
DIFFERENTIAL COUNT				
NEUTROPHILS	50	40.0 - 80.0	%	FLOW CYTOMETRY
LYMPHOCYTES	45	<i>H</i> 20.0 - 40.0	%	FLOW CYTOMETRY
MONOCYTES	03	2.0 - 10.0	%	FLOW CYTOMETRY
EOSINOPHILS	02	0.0 - 5.0	%	FLOW CYTOMETRY
BASOPHILS	00	0.0 - 2.0	%	FLOW CYTOMETRY
RED BLOOD CELL COUNT	5.1	3.5 - 5.5	millions/ μ L	ELECTRICAL
PACKED CELL VOLUME	45.4	35.0 - 50.0	%	ELECTRICAL
MEAN CORPUSCULAR VOLUME	88.7	83 - 101	fL	ELECTRICAL
MEAN CORPUSCULAR HAEMOGLOBIN	30.5	27 - 31	Picograms	CALCULATED
MEAN CORPUSCULAR HB CONC	34.4	33 - 37	g/dl	CALCULATED
PLATELET COUNT	258	150 - 450	thou/ μ L	ELECTRICAL
RDW	12.5	11.6 - 14.5	%	CALCULATED

***** END OF THE REPORT *****



Sample no.

Dr. SONIA KUMARI
MBBS, MD (PATHOLOGY) Gold medalist

Dr. PRADIP KUMAR
Consultant (Microbiology)

Dr. NISHA TIWARI
MBBS, MD (Microbiology)

USER NM SONU

(This is only professional opinion and not the diagnosis. Please correlate clinically)

Q Block South City 11, Sohna Road, Main Sector-47, Gurgaon, Haryana
Ph.: 0124-4900000 (100 Lines) Fax : 0124-2218733 E-mail : parkmedicenters@gmail.com

PARK GROUP OF HOSPITALS : West Delhi • South Delhi • Gurgaon • Karnal • Panipat • Hodal • Ambala • Behror

the health care providers

the health care providers





DEPARTMENT OF PATHOLOGY

Patient Name : Mr. DEEPANSHU	Bill Date : 28/01/2023
MR No : 670719	Reporting Date : 30/01/2023
Age/Sex : 31 Years 5 Months 29 Days / Male	Sample ID : 92833
Type : OPD	Bill/Req. No. : 24031694
TPA/Corporate : MEDIWHEEL PVT LTD	Ref Doctor : Dr.RMO

Test	Result	Bio. Ref. Interval	Units	Method
URINE C/S				
NAME OF SPECIMEN	URINE			
ORGANISM IDENTIFIED	NO GROWTH SEEN IN CULTURE AFTER 48 HRS OF INCUBATION AT 37 C DEGREE.			Aerobic culture
Method :				
Note :				

***** END OF THE REPORT *****



Sample no.

Dr. SONIA KUMARI
MBBS, MD (PATHOLOGY) Gold medalist

Dr. PRADIP KUMAR
Consultant (Microbiology)

Dr. NISHA TIWARI
MBBS, MD (Microbiology)

USER NM ANJALIPA911

(This is only professional opinion and not the diagnosis, Please correlate clinically)

Q Block South City 11, Sohna Road, Main Sector-47, Gurgaon, Haryana
Ph.: 0124-4900000 (100 Lines) Fax : 0124-2218733 E-mail : parkmedicenters@gmail.com

PARK GROUP OF HOSPITALS : West Delhi • South Delhi • Gurgaon • Karnal • Panipat • Hodal • Ambala • Behror

the **health** care providers

the **health** care providers



DEPARTMENT OF PATHOLOGY

Patient Name : Mr. DEEPANSHU
MR No : 670719
Age/Sex : 31 Years 5 Months 29 Days / Male
Type : OPD
TPA/Corporate : MEDIWHEEL PVT LTD

Bill Date : 28/01/2023
Reporting Date : 29/01/2023
Sample ID : 92833
Bill/Req. No. : 24031694
Ref Doctor : Dr.RMO

Test	Result	Blo. Ref. Interval	Units	Method
THYROID PROFILE				
TRI-IODOTHYRONINE (T3)	1.90	<i>H</i> 0.60 - 1.81	ng/ml	Chemiluminescence
THYROXINE (T4)	11.9	5.01 - 12.45	µg/dL	Chemiluminescence
THYROID STIMULATING HORMONE	1.70	0.5-5.50	µIU/ml	
SPECIMEN TYPE	SERUM			
Method : chemiluminescent immunoassay				

Note : Clinical Significance:

Thyroid function tests (TFTs) is a collective term for blood tests used to check the function of the thyroid. TFTs may be requested if a patient is thought to suffer from hyperthyroidism (overactive thyroid) or hypothyroidism (underactive thyroid), or to monitor the effectiveness of either thyroid-suppression or hormone replacement therapy. It is also requested routinely in conditions linked to thyroid disease, such as atrial fibrillation and anxiety disorder. A TFT panel typically includes thyroid hormones such as thyroid-stimulating hormone (TSH, thyrotropin) and thyroxine (T4), and triiodothyronine (T3) depending on local laboratory policy.

Note: Please correlate with clinical condition

***** END OF THE REPORT *****



Sample no.

Dr. SONIA KUMARI
MBBS, MD (PATHOLOGY) Gold medalist

Dr. PRADIP KUMAR
Consultant (Microbiology)

Dr. NISHA TIWARI
MBBS, MD (Microbiology)

USER NM : DINESH

(This is only professional opinion and not the diagnosis. Please correlate clinically)

Q Block South City 11, Sohna Road, Main Sector-47, Gurgaon, Haryana
Ph.: 0124-4900000 (100 Lines) Fax : 0124-2218733 E-mail : parkmedicenters@gmail.com



DEPARTMENT OF PATHOLOGY

Patient Name : Mr. DEEPANSHU
MR No : 670719
Age/Sex : 31 Years 5 Months 29 Days / Male
Type : OPD
TPA/Corporate : MEDIWHEEL PVT LTD

Bill Date : 28/01/2023
Reporting Date : 28/01/2023
Sample ID : 92833
Bill/Req. No. : 24031694
Ref Doctor : Dr.RMO

Test	Result	Bio. Ref. Interval	Units	Method
LFT (LIVER FUNCTION TEST)				
LFT				
TOTAL BILIRUBIN	0.8	0 - 1.2	mg/dL	DIAZO
DIRECT BILIRUBIN	0.3	0 - 0.4	mg/dL	DIAZO
INDIRECT BILIRUBIN	0.5	0.10 - 0.6	mg/dL	CALCULATED
SGOT (AST)	122	H 0 - 45	U/L	IFCC WITHOUT
SGPT (ALT)	340	H 0 - 45	U/L	IFCC WITHOUT
ALKALINE PHOSPHATASE	106	30 - 170	IU/L	MODIFIED IFCC
TOTAL PROTEINS	7.9	6.4 - 8.0	g/dL	BIURET
ALBUMIN	4.4	3.3 - 5.5	g/dL	BCG DYE
GLOBULIN	3.5	2.3 - 4.5	g/dL	CALCULATED
A/G RATIO	1.26	1.1 - 2.2		CALCULATED

***** END OF THE REPORT *****



Sample no.

Dr. SONIA KUMARI
MBBS, MD (PATHOLOGY) Gold medalist

Dr. PRADIP KUMAR
Consultant (Microbiology)

Dr. NISHA TIWARI
MBBS, MD (Microbiology)

USER NM SONU

(This is only professional opinion and not the diagnosis. Please correlate clinically.)

Q Block South City 11, Sohna Road, Main Sector-47, Gurgaon, Haryana
Ph.: 0124-4900000 (100 Lines) Fax : 0124-2218733 E-mail : parkmedicenters@gmail.com

PARK GROUP OF HOSPITALS : West Delhi • South Delhi • Gurgaon • Karnal • Panipat • Hodal • Ambala • Behror

the health care providers the health care providers





Cert. No. MC - 4830



Cert. No. H-2016-0385

DEPARTMENT OF PATHOLOGY

Patient Name : Mr. DEEPANSHU
MR No : 670719
Age/Sex : 31 Years 5 Months 29 Days / Male
Type : OPD
TPA/Corporate : MEDIWHEEL PVT LTD

Bill Date : 28/01/2023
Reporting Date : 28/01/2023
Sample ID : 92833
Bill/Req. No. : 24031694
Ref Doctor : Dr.RMO

Test	Result	Bio. Ref. Interval	Units	Method
KFT (RENAL PROFILE)				
KFT				
SERUM UREA	25	10 - 45	mg/dL	UREASE-GLDH
SERUM CREATININE	1.0	0.4 - 1.4	mg/dL	MODIFIED JAFFES
SERUM URIC ACID	6.0	2.5 - 7.0	mg/dL	URICASE
SERUM SODIUM	145	136 - 148	mmol/L	ISE
SERUM POTASSIUM	4.1	3.5 - 5.5	meq/l	ISE
SERUM CALCIUM	8.6	8.5 - 10.5	mg/dL	ARSENazo III
SERUM PHOSPHORUS	2.5	2.5 - 4.5	mg/dL	AMMONIUM

**** END OF THE REPORT ****



Sample no.

Dr. SONIA KUMARI
MBBS, MD (PATHOLOGY) Gold medalist

Dr. PRADIP KUMAR
Consultant (Microbiology)

Dr. NISHA TIWARI
MBBS, MD (Microbiology)

USER NM SONU

(This is only professional opinion and not the diagnosis. Please correlate clinically)

Page 1 of 1

Q Block South City 11, Sohna Road, Main Sector-47, Gurgaon, Haryana
Ph.: 0124-4900000 (100 Lines) Fax : 0124-2218733 E-mail : parkmedicenters@gmail.com

PARK GROUP OF HOSPITALS : West Delhi • South Delhi • Gurgaon • Karnal • Panipat • Hodal • Ambala • Behror

the health care providers

the health care providers



Scanned with OKEN Scanner



DEPARTMENT OF PATHOLOGY

Patient Name : Mr. DEEPANSHU
MR No : 670719
Age/Sex : 31 Years 5 Months 29 Days / Male
Type : OPD
TPA/Corporate : MEDIWHEEL PVT LTD

Bill Date : 28/01/2023
Reporting Date : 28/01/2023
Sample ID : 92833
Bill/Req. No. : 24031694
Ref Doctor : Dr.RMO

Test	Result	Blo. Ref. Interval	Units	Method
LIPID PROFILE				
LIPID PROFILE				
TOTAL CHOLESTEROL	121	0 - 250	mg/dL	CHOD -Trinder
SERUM TRIGLYCERIDES	123	60 - 165	mg/dl	GPO-TRINDER
HDL-CHOLESTEROL	30	30 - 70	mg/dl	DIRECT
VLDL CHOLESTEROL	24	6 - 32	mg/dL	calculated
LDL	67	50 - 135	mg/dl	calculated
LDL CHOLESTEROL/HDL RATIO	2.2	1.0 - 3.0	mg/dL	calculated
TOTAL CHOLESTEROL/HDL RATIO	4.0	2.0 - 5.0	mg/dl	calculated

***** END OF THE REPORT *****



Sample no.

Dr. SONIA KUMARI
MBBS, MD (PATHOLOGY) Gold medalist

Dr. PRADIP KUMAR
Consultant (Microbiology)

Dr. NISHA TIWARI
MBBS, MD (Microbiology)

USER NM SONU

(This is only professional opinion and not the diagnosis. Please correlate clinically)

Page 1 of 1

Q Block South City 11, Sohna Road, Main Sector-47, Gurgaon, Haryana
Ph.: 0124-4900000 (100 Lines) Fax : 0124-2218733 E-mail : park.medicenters@gmail.com

PARK GROUP OF HOSPITALS : West Delhi • South Delhi • Gurgaon • Karnal • Panipat • Hodal • Ambala • Behror

the **health** care providers

the **health** care providers





DEPARTMENT OF PATHOLOGY

Patient Name : Mr. DEEPANSHU
MR No : 670719
Age/Sex : 31 Years 5 Months 29 Days / Male
Type : OPD
TPA/Corporate : MEDIWHEEL PVT LTD

Bill Date : 28/01/2023
Reporting Date : 28/01/2023
Sample ID : 92833
Bill/Req. No. : 24031694
Ref Doctor : Dr.RMO

Test	Result	Blo. Ref. Interval	Units	Method
ESR (WESTERGREN)				
E.S.R. - II HR.	30		mm II Hr.	Westergren

***** END OF THE REPORT *****



Sample no.

Dr. SONIA KUMARI
MBBS, MD (PATHOLOGY) Gold medalist

Dr. PRADIP KUMAR
Consultant (Microbiology)

Dr. NISHA TIWARI
MBBS, MD (Microbiology)

USER NM SONU

(This is only professional opinion and not the diagnosis. Please correlate clinically)

Page 1 of 1

Q Block South City 11, Sohna Road, Main Sector-47, Gurgaon, Haryana
Ph.: 0124-4900000 (100 Lines) Fax : 0124-2218733 E-mail : parkmedicenters@gmail.com

PARK GROUP OF HOSPITALS : West Delhi • South Delhi • Gurgaon • Karnal • Panipat • Hodal • Ambala • Behror

the **health** care providers

the **health** care providers





DEPARTMENT OF PATHOLOGY

Patient Name : Mr. DEEPANSHU
MR No : 670719
Age/Sex : 31 Years 5 Months 29 Days / Male
Type : OPD
TPA/Corporate : MEDIWHEEL PVT LTD

Bill Date : 28/01/2023
Reporting Date : 28/01/2023
Sample ID : 92833
Bill/Req. No. : 24031694
Ref Doctor : Dr.RMO

Test	Result	Bio. Ref. Interval	Units	Method
BLOOD GROUPING AND RH FACTOR				
BLOOD GROUP	" O " RH POSITIVE			MATRIX GEL

***** END OF THE REPORT *****



Sample no.

Dr. SONIA KUMARI
MBBS, MD (PATHOLOGY) Gold medalist

Dr. PRADIP KUMAR
Consultant (Microbiology)

Dr. NISHA TIWARI
MBBS, MD (Microbiology)
USER NM SONU

(This is only professional opinion and not the diagnosis, Please correlate clinically)

Q Block South City 11, Sohna Road, Main Sector-47, Gurgaon, Haryana
Ph.: 0124-4900000 (100 Lines) Fax : 0124-2218733 E-mail : parkmedicenters@gmail.com

PARK GROUP OF HOSPITALS : West Delhi • South Delhi • Gurgaon • Karnal • Panipat • Hodal • Ambala • Behror

the health care providers the health care providers





DEPARTMENT OF PATHOLOGY

Patient Name : Mr. DEEPANSHU
MR No : 670719
Age/Sex : 31 Years 5 Months 29 Days / Male
Type : OPD
TPA/Corporate : MEDIWHEEL PVT LTD

Bill Date : 28/01/2023
Reporting Date : 28/01/2023
Sample ID : 92833
Bill/Req. No. : 24031694
Ref Doctor : Dr.RMO

Test	Result	Bio. Ref. Interval	Units	Method
URINE ROUTINE AND MICROSCOPY				
PHYSICAL CHARACTERISTICS				
QUANTITY	30ml	5 - 100	ml	Vishal
COLOUR	Pale Yellow	Pale Yellow		
TURBIDITY	Clear	clear		urinometer
SPECIFIC GRAVITY	1.020	1.000-1.030		PH PAPER
PH	Acidic	Acidic/Alkaline		
CHEMICAL EXAMINATION-1				
UROBILINOGEN	NIL	NIL	mg/dl	Ehrlich Protein error indicator
URINE PROTEIN	NIL	NIL		
BLOOD	NIL	NIL	mg/dL	GOD-POD/Benedicts SOD.
GLUCOSE	NIL	NIL		
URINE KETONE	NIL	NIL		
MICRO.EXAMINATION				
PUS CELL	2-4	0-5	cells/hpf	Microscopic
RED BLOOD CELLS	Nil	0-2	cells/hpf	
EPITHELIAL CELLS	1-2	0-5	cells/hpf	
CASTS	NIL	NIL	/lpf	
CRYSTALS	NIL	NIL	/hpf	
OTHER	NIL			

***** END OF THE REPORT *****



Sample no.

Dr. SONIA KUMARI
MBBS, MD (PATHOLOGY) Gold medalist

Dr. PRADIP KUMAR
Consultant (Microbiology)

Dr. NISHA TIWARI
MBBS, MD (Microbiology)

USER NM NEERAJPA752

(This is only professional opinion and not the diagnosis, Please correlate clinically)

Q Block South City 11, Sohna Road, Main Sector-47, Gurgaon, Haryana
Ph.: 0124-4900000 (100 Lines) Fax : 0124-2218733 E-mail : parkmedcenters@gmail.com

Page 1 of 1

PARK GROUP OF HOSPITALS : West Delhi • South Delhi • Gurgaon • Karnal • Panipat • Hodal • Ambala • Behror

the health care providers

the health care providers





DEPARTMENT OF PATHOLOGY

Patient Name : Mr. DEEPANSHU	Bill Date : 28/01/2023 9.48 AM
MR No : 670719	Sample Col Dt/Tm : 28/01/2023 10:38 am
Age/Sex : 31 Years 5 Months 29 Days / Male	Sample Rec Dt/Tm : 28/01/2023 10:38 am
Type : OPD	Reporting Date : 2023-01-28 00:23:00-01 12:36:
TPA/Corporate : MEDIWHEEL PVT LTD	Sample ID : 92833
Ref Doctor : Dr.RMO	Bill/Req. No. : 24031694

Test	Result	Bio. Ref. Interval	Units	Method
BLOOD SUGAR FASTING				
PLASMA GLUCOSE FASTING	100	60 - 110	mg/dl	GOD TRINDERS

***** END OF THE REPORT *****



Dr. PRADIP KUMAR
Consultant (Microbiology)

Dr. SONIA KUMARI
MD Pathology (Gold Medalist)

Dr. NISHA TIWARI
MBBS, MD (Microbiology)
USER NM SONU

(This is only professional opinion and not the diagnosis, Please correlate clinically)

G Block South City 11, Sohna Road, Main Sector-47, Gurgaon, Haryana
Ph.: 0124-4900000 (100 Lines) Fax : 0124-2218733 E-mail : parkmedicenters@gmail.com

PARK GROUP OF HOSPITALS : West Delhi • South Delhi • Gurgaon • Karnal • Panipat • Hodal • Ambala • Behror

the health care providers

the health care providers





DEPARTMENT OF PATHOLOGY

Patient Name : Mr. DEEPANSHU
MR No : 670719
Age/Sex : 31 Years 5 Months 29 Days / Male
Type : OPD
TPA/Corporate : MEDIWHEEL PVT LTD

Bill Date : 28/01/2023
Reporting Date : 28/01/2023
Sample ID : 92833
Bill/Req. No. : 24031694
Ref Doctor : Dr.RMO

Test	Result	Bio. Ref. Interval	Units	Method
BLOOD SUGAR 2 HR. PP				
BLOOD SUGAR P.P.	136	80 - 150	mg/dl	

***** END OF THE REPORT *****



Sample no.

Dr. SONIA KUMARI
MBBS, MD (PATHOLOGY) Gold medalist

Dr. PRADIP KUMAR
Consultant (Microbiology)

Dr. NISHA TIWARI
MBBS, MD (Microbiology)

USER NM SHOAIBPA166

(This is only professional opinion and not the diagnosis. Please correlate clinically)

Page 1 of 1

Q Block South City 11, Sohna Road, Main Sector-47, Gurgaon, Haryana
Ph.: 0124-4900000 (100 Lines) Fax : 0124-2218733 E-mail : parkmedicenters@gmail.com

PARK GROUP OF HOSPITALS : West Delhi • South Delhi • Gurgaon • Karnal • Panipat • Hodal • Ambala • Behror

the **health** care providers

the **health** care providers



ПАРК НОСЬПІАГ, СОЛН СІТІ ІІ, СУРСАОН, НАРҮАНА
DEEBVIZHUN 31X M516

Срст BY

BEQ-5403108102033 VM

Р





DEPARTMENT OF RADIOLOGY

Patient Name	Mr DEEPANSHU	Billed Date	: 28/01/2023	9.48 AM
Reg No	670710	Reported Date	: 28/01/2023	
Age/Sex	31 Years 5 Months 29Days / Male	Req. No.	: 24031694	
Type	OPD	Consultant Doctor	: Dr. RMO	

USG WHOLE ABDOMEN

The Real time, B mode, gray scale sonography of the abdominal organs was performed.

LIVER : The liver is **enlarged in size, 15.0cm with fatty infiltration**. No evidence of any focal lesion. IHBR is NOT dilated.

GALL BLADDER : The gall bladder is partially distended. No evidence any calculus or mass seen. No evidence of pericholecystic fluid is seen.

BILE DUCT : The common bile duct is normal in caliber. No evidence of calculus is noted in common bile duct.

SPLEEN : The spleen is normal in size 9.0cm and shape. Its echotexture is homogeneous. No evidence of focal lesion is noted.

PANCREAS : The pancreas is normal in size, shape, contours and echotexture. No evidence of solid or cystic mass lesion is noted. MPD is not dilated. No evidence of peripancreatic collection.

KIDNEYS : The bilateral kidneys are normal in size and echotexture. Cortico-medullary differentiation is maintained. There is no evidence of obvious calculus or hydronephrosis.

URINARY BLADDER : The urinary bladder is well distended. Wall thickness within normal limits. No evidence of calculus is seen. No evidence of mass or diverticulum is noted.

PROSTATE: Prostate appears normal in shape, size and echotexture.

No evidence of ascites or interbowel free fluid is seen.

No evidence of obvious retroperitoneal or mesantric lymphadenopathy is seen.

Bowel loop distended with gas.

IMPRESSION- **Hepatomegaly with fatty liver grade-I**

To be correlated clinically

Dr. ANSHU K. SHARMA
MBBS, MD
CONSULTANT RADIOLOGIST

Dr. MANJEET SEHRAWAT
MBBS, MD, PDCC
CONSULTANT RADIOLOGIST

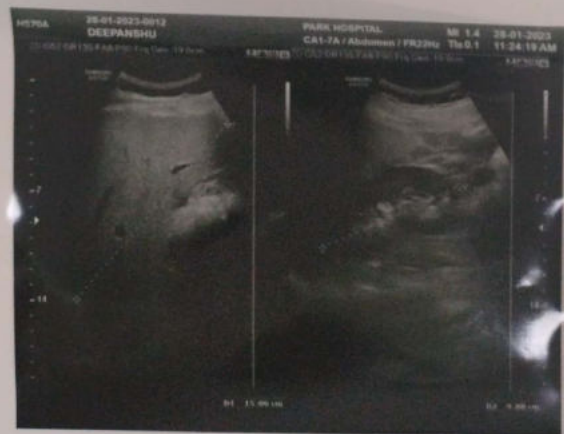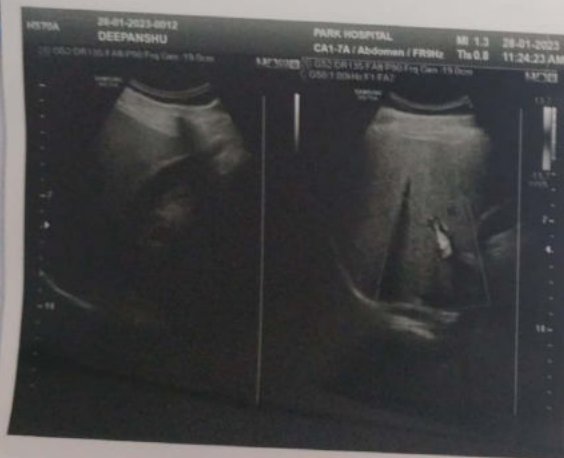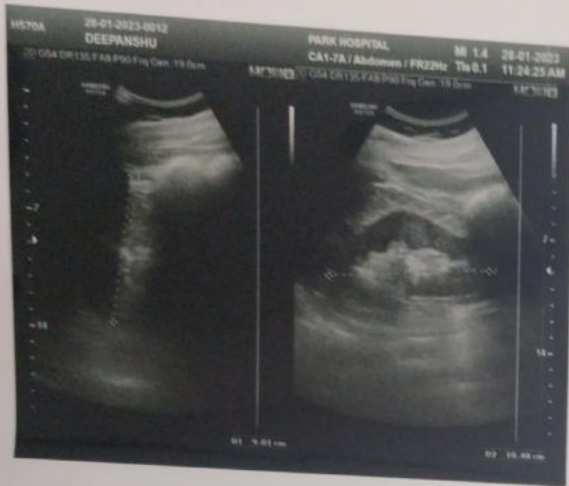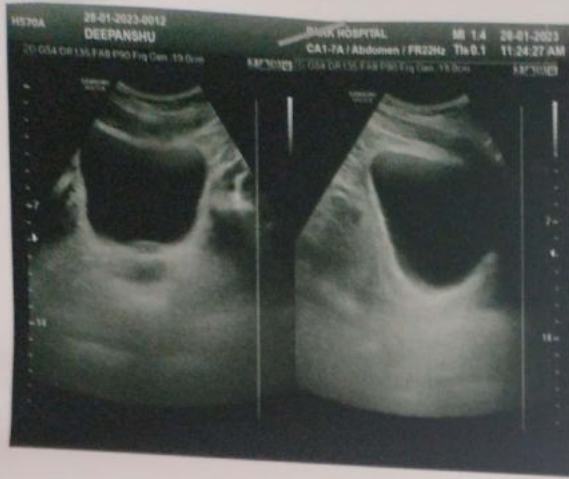
Dr. NEENA SIKKA
MBBS, DNB
CONSULTANT RADIOLOGIST



(This is only professional opinion and not the diagnosis, Please correlate clinically)

Q Block South City 11, Sohna Road, Main Sector-47, Gurgaon, Haryana
Ph.: 0124-4900000 (100 Lines) Fax : 0124-2218733 E-mail : parkmedicenters@gmail.com

PARK GROUP OF HOSPITALS : West Delhi • South Delhi • Gurgaon • Karnal • Panipat • Hodal • Ambala • Behror





Patient Name	Mr DEEPANSHU	Billed Date	: 28/01/2023	9 48 AM
Reg No	670719	Reported Date	: 28/01/2023	
Age/Sex	31 Years 5 Months 29Days / Male	Req. No.	: 24031694	
Type	OPD	Consultant Doctor	: Dr. RMO	

X-RAY CHEST AP/PA

X-RAY CHEST P.A. VIEW

Bilateral lungs appears normal.

No focal lung lesion seen.

No evidence of free fluid is seen.

Both hila are normal in size, have equal density and bear normal relationship.

The heart and trachea are central in position and no mediastinal abnormality is visible.

The cardiac size is normal for patient age and view.

The domes of the diaphragms are normal in position, and show smooth outline.

To be correlated clinically



Dr. ANSHU K. SHARMA
MBBS, MD
CONSULTANT RADIOLOGIST

Dr. MANJEET SEHRAWAT
MBBS, MD, PDCC
CONSULTANT RADIOLOGIST

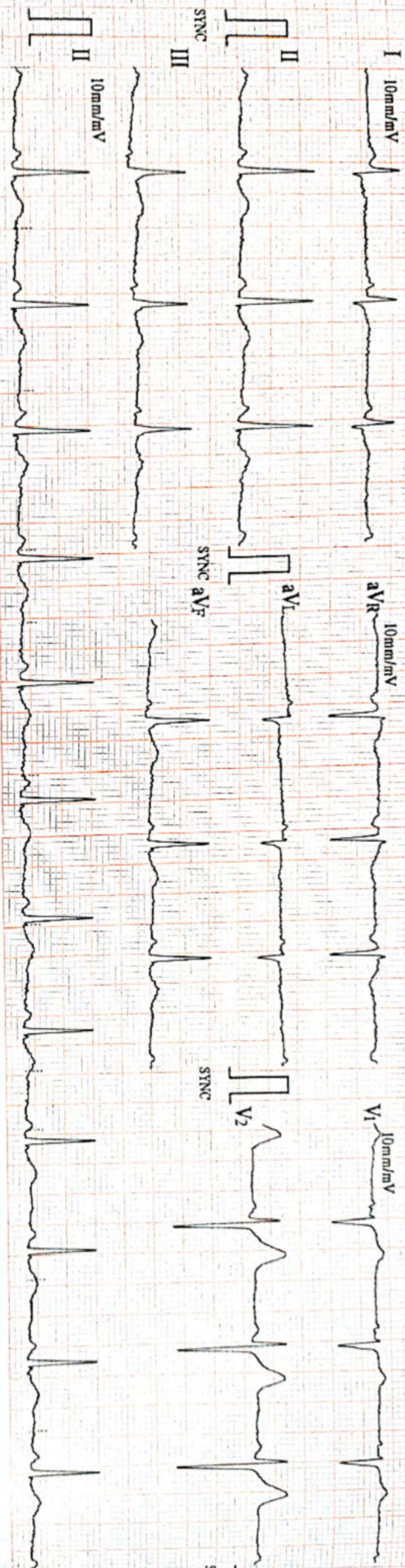
Dr. NEENA SIKKA
MBBS, DNB
CONSULTANT RADIOLOGIST

(This is only professional opinion and not the diagnosis; Please correlate clinically)

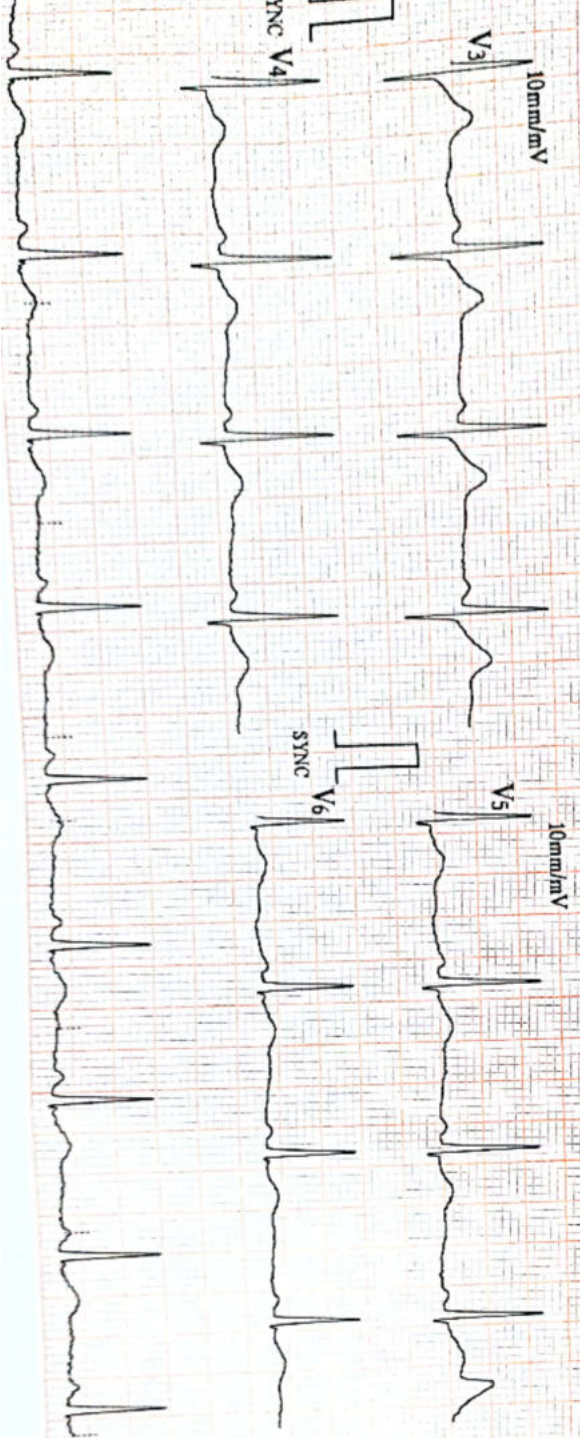
Q Block South City 11, Sohna Road, Main Sector-47, Gurgaon, Haryana
Ph.: 0124-4900000 (100 Lines) Fax : 0124-2218733 E-mail : parkmedcenters@gmail.com

PARK GROUP OF HOSPITALS : West Delhi • South Delhi • Gurgaon • Karnal • Panipat • Huda • Ambala • Behror

25mm/s 0.5-25Hz



ECG-1203 V2:000(BIOS:V2:000;AMP:V1:001) 2016-01-01 00:38



ID : 0319 HR : 76 bpm

Name: Deepanshu P-R : 783 ms

Sex : male QRS : 128 ms

Age : 31y QT/QTc : 335/378 ms

2811123 P/QRS/T : 29/79/61 °

RV5/SV1 : 1.240/0.650 mV

RV5-SV1 : 1.890 mV

----- Sinus Rhythm

----- T Abnormality (Flat T)

Unconfirmed report Verified by: _____