



# MURUGAN HOSPITALS

HEALING HANDS



## LAB REPORT

Patient Name : Mrs. THENMOZHID  
 Age / Gender : 47-Years / Female  
 UHID ID : MH20160002515  
 Doctor Name : Dr. ARUN PRAKASH

OP Report No. : INVA2108225  
 Bill No. : INV2206306  
 Sample Date : 24/12/2022 - 10:00 AM  
 Report Date : 24/12/2022 - 04:46 PM

Test Name	Result	Units	Reference Interval
-----------	--------	-------	--------------------

### HAEMATOLOGY

#### Complete Blood Cell Count(CBC)

HAEMOGLOBIN	<u>11.8</u>	gms/dl	male :13.0 - 17.0 female :12.0 - 15.0
PACKED CELL VOLUME	38.2	%	male : 40 - 50 female : 36 - 46
RBC COUNT	5.03	millions cells/cu.mm	female: 3.8 - 4.8 male : 4.5 - 5.5
TOTAL WBC	7,000	Cells/Cumm	4,000 - 11,000
<b>Differential Count</b>			
NEUTROPHILS	64	%	40 - 65
LYMPHOCYTES	30	%	30-50
EOSINOPHILS	04	%	01-06
MONOCYTES	02	%	1-10
BASOPHILS	00	%	0-2
ESR 60 MTS	15	mm	5 - 20
PLATELET COUNT	3.84	Lakhs/cumm	1.5 - 4.5
MCV	76.1	fL	76 - 96
MCH	<u>23.4</u>	pg	27 - 32
MCHC	30.8	gms/dl	30 - 36

INTERPRETATION: Test done on automated three part cell counter, all abnormal results are reviewed and confirmed microscopically.

BLOOD GROUPING & RH TYPING " O " positive

Page 1 of 4

Healing Hearts and Lives

264/125, Kilpauk Garden Road, Kilpauk, Chennai - 600 010.  
 Phone : +91 44 4644 8989 / 75500 53335 | Email : muruganhosp@gmail.com  
 Website : www.muruganhospitals.in

# MURUGAN HOSPITALS

HEALING HANDS



## LAB REPORT

Patient Name : Mrs. THENMOZHID  
Age / Gender : 47-Years / Female  
UHID ID : MH20160002515  
Doctor Name : Dr. ARUN PRAKASH

OP Report No. : INVA2108225  
Bill No. : INV2206306  
Sample Date : 24/12/2022 - 10:00 AM  
Report Date : 24/12/2022 - 04:46 PM

Test Name	Result	Units	Reference Interval
<b>BIO CHEMISTRY</b>			
BLOOD SUGAR FASTING	109	mgs/dl	70-110
BLOOD SUGAR POST PRANDIAL	<u>181</u>	mgs/dl	80- 160
SERUM URIC ACID	2.7	mg/dl	male 3.1-7.0 , female 2.5-5.6
SERUM CREATININE	0.7	mg/dl	0.6-1.4
<b>LIPID PROFILE</b>			
TOTALCHOLESTEROL	190	mg/dl	< 200
TRIGLYCERIDE	70	mg/dl	< 150
HDL	49	mg/dl	35 - 80
VLDL	14	mg/dl	2 to 30
LDL	127	mg/dl	<130
CHOLESTEROL/ HDL RATIO	3.8	mg/dl	

Healing Hearts and Lives

264/125, Kilpauk Garden Road, Kilpauk, Chennai - 600 010.  
Phone : +91 44 4644 8989 / 75500 53335 | Email : muruganhosp@gmail.com  
Website : www.muruganhospitals.in



**LAB REPORT**

Patient Name : Mrs. THENMOZHID  
Age / Gender : 47-Years / Female  
UHID ID : MH20160002515  
Doctor Name : Dr. ARUN PRAKASH

OP Report No. : INVA2108225  
Bill No. : INV2206306  
Sample Date : 24/12/2022 - 10:00 AM  
Report Date : 24/12/2022 - 04:46 PM

Test Name	Result	Units	Reference Interval
<b>LIVER FUNCTION TEST</b>			
BILLIRUBIN(TOTAL)	0.4	mg/dl	0.0 - 1.0
BILLIRUBIN(DIRECT)	0.2	mg/dl	0.1 - 0.30
BILLIRUBIN(INDIRECT)	0.2	mg/dl	0.2-0.8
SGOT	20	IU/L	0-38
SGPT	16	IU/L	0.0-40
ALKALINE PHOSPHATASE	80	IU/L	40-140
			4-6Years 93-309
			13-15Years 74-390
TOTAL PROTEIN	7.2	gm/dl	6.6-8.7
ALBUMIN	4.0	gm/dl	3.5 - 5.5
AG RATIO	1.2		
GAMMA G T	22	U/L	male<49
			female<32
BLOOD UREA NITROGEN	7.0	mg/dl	7-21
HBA1C	5.8	%	normal: <6.0
			good control: 6.1-7.0
			fair control: 7.1- 8.0
			poor control:8.1 -10.0
			unsatisfactory: >10.0



# MURUGAN HOSPITALS

HEALING HANDS



## LAB REPORT

Patient Name : Mrs. THENMOZHID  
 Age / Gender : 47-Years / Female  
 UHID ID : MH20160002515  
 Doctor Name : Dr. ARUN PRAKASH

OP Report No. : INVA2108225  
 Bill No. : INV2206306  
 Sample Date : 24/12/2022 - 10:00 AM  
 Report Date : 24/12/2022 - 04:46 PM

Test Name	Result	Units	Reference Interval
-----------	--------	-------	--------------------

### CLINICAL PATHOLOGY

URINE SUGAR (F)	Nil		
<b>URINE ROUTINE</b>			
COLOUR	Pale yellow		
APPEARANCE	Clear		
REACTION	Acidic		
SUGAR	Nil		
ALBUMIN	Nil		
<b>DEPOSITES</b>			
PUS CELLS	2 - 3	/ HPF	
EPI CELLS	3 - 5	/ HPF	
RBC COUNT	Nil	/ HPF	
CAST	Nil		
CRYSTALS	Nil		
OTHERS	Nil		

MALATHI  
 Verified by

\*\*\* End of Report \*\*\*



Healing Hearts and Lives

264/125, Kilpauk Garden Road, Kilpauk, Chennai - 600 010.  
 Phone : +91 44 4644 8989 / 75500 53335 | Email : muruganhosp@gmail.com  
 Website : www.muruganhospitals.in



# MURUGAN HOSPITALS

HEALING HANDS



## LAB REPORT

Patient Name : Mrs. THENMOZHID  
 Age / Gender : 47-Years / Female  
 UHID ID : MH20160002515  
 Doctor Name : Dr. ARUN PRAKASH

OP Report No. : INVA2108225  
 Bill No. : INV2206306  
 Sample Date : 24/12/2022 - 10:00 AM  
 Report Date : 24/12/2022 - 10:32 PM

Test Name	Result	Units	Reference Interval
<b>ENDOCRINOLOGY</b>			
T3	<u>0.396</u>	ng/ml	0.52-1.85
T4	4.997	ug/dl	5.0 -13.0 ug/dl
TSH	8.070	uIU/ml	0.39 - 6.16 uiu/ml

KAVIYARASAN  
 Verified by

\*\*\* End of Report \*\*\*





# MURUGAN HOSPITALS

HEALING HANDS

9790996743



## LAB REPORT

NAME :	MRS. TENMOZHI	SAMPLE NO :	3822131848
PIN :	AND22380199885	COLLECTED ON :	22/12/2022 06:07 PM
AGE/GENDER :	56 Year(s)/Female	RECEIVED ON :	22/12/2022 06:08 PM
REFERRED BY :	Dr. ARUN PRAKASH	REPORTED ON :	24/12/2022 09:14 AM
CLIENT NAME :	MURUGAN HOSPITAL	REPRINT DATE :	24/12/2022 09:14 AM

### Liquid PAP smear (by Liquid Based Cytology)

#### CYTOLOGY NO.

C 17727 / 2022

#### SPECIMEN

Liquid based pap smear

#### MICROSCOPIC FINDINGS

Moderately cellular smear showing predominantly parabasal cells and scattered superficial squamous cells, intermediate squamous cells and admixed with inflammatory cells in the background.

#### INTERPRETATION :

- Adequacy of the Smear - Satisfactory for evaluation.
- Cellular components of transformation zone are - Present.
- Reactive cellular changes - Absent.
- Infective organisms - Absent.
- Squamous cell abnormalities - Nil.
- Glandular cell abnormalities - Nil.
- Other cells (Endometrial & mesenchymal) - Nil.

#### IMPRESSION

Atrophic and inflammatory smear. Negative for intraepithelial lesion or malignancy. (Mode of reporting : Bethesda system 2014)

-- End of Report --

Prof. Geetha Devadas DCP, MD path  
 Prof. Chandramouleswari MD path  
 Dr. Indumathi DCP, MD path, DNB path  
 Dr. Arun Prabhakaran MD  
 Dr. Varsha DCP., DNB (Pathology)  
 Dr. Anshulekha patel, M.D.,PDF (Oncopathology)

Dr. Kavvya R  
 M.D Pathology

Healing Hearts and Lives

264/125, Kilpauk Garden Road, Kilpauk, Chennai - 600 010.  
 Phone : +91 44 4644 8989 / 75500 53335 | Email : muruganhosp@gmail.com  
 Website : www.muruganhospitals.in



**MURUGAN HOSPITALS**  
HEALING HANDS

NAME :MSR.THENMOZHI.D  
AGE /GENDER:47YRS/ FEMALE  
CONSULTANT: DR.ARUNPRAKASH

UHID : MH20160002515  
IP/OP : OP  
DATE : 24.12.2022

**X-RAY CHEST (PA VIEW)**

- The cardio thoracic ratio is normal
- The heart size and configuration are within normal limits
- The aortic arch is normal
- The lung fields show normal broncho- Vascular markings
- Both the pulmonary hila are normal in size
- The costophrenic and cardiophrenic recesses and the domes of diaphragm are normal
- The bones and soft tissues of the chest wall show no abnormality

**IMPRESSION:**

Normal Study



264/125, Kilpauk Garden Road, Kilpauk, Chennai - 600 010.

☎ : +91 44 4644 8989 / 75500 53335 email : muruganhosp@gmail.com

Website : www.muruganhospitals.in



**MURUGAN HOSPITALS**  
HEALING HANDS



**ECHO CARDIOGRAM REPORT**

NAME : MRS.THENMOZHI.D UHIDNO:MH20160002515  
 AGE&SEX : 47Y /FEMALE IP/OP : OUTPATIENT  
 CONSULTANT: DR. ARUN PRAKASH DATE : 24-12-2022

**2D PLAX (mm)**

RV - 32 mm  
 AO - 26 mm  
 LA - 39 mm

**COLOR DOPPLER**

Normal

**M-Mode (mm)**


IVS - 09 mm  
 PW - 10 mm  
 LVD - 44 mm  
 LVS - 28 mm  
 EF - 65 %  
 FS - 35 %

**DOPPLER (m/sec)**

MITRAL E - 0.8 m/s  
 MITRAL A - 0.5 m/s  
 PULMONARY - 1.3 m/s  
 AORTIC - 1.2 m/s  
 TRICUSPID - 0.4 m/s

**IMPRESSION:**

No RWMA  
 Normal biventricular function  
 No pulmonary hypertension  
 No pericardial effusion  
 No clot/ Vegetation.

  
 Dr. SIDHARTHAN, MD.,DM.,  
 Consultant Cardiologist

**Healing Hearts and Lives**

264/125, Kilpauk Garden Road, Kilpauk, Chennai - 600 010.  
 Phone : +91 44 4644 8989 / 75500 53335 | Email : muruganhosp@gmail.com  
 Website : www.muruganhospitals.in





# MURUGAN HOSPITALS

HEALING HANDS



## SCAN REPORT

NAME	: MRS.THENMOZHI.D	PATIENT ID	: MH20160002515
AGE/SEX	: 47 Years / FEMALE	IP / OP NO	: OP21037651
CONSULTANT	: DR.ARUN PRAKASH	DATE	: 24/12/2022

### ULTRA SOUND SCAN OF ABDOMEN

**LIVER:** Normal in size and normal in echotexture. No focal lesions are seen. No dilatation of intra-hepatic biliary radicals present. Hepatic veins and IVC appear normal. Portal vein is normal in caliber. Common bile duct is normal in caliber.

**GALL BLADDER:** Normal in size and wall thickness. No evidence of any calculus or mass present. No evidence of pericholecystic collections.

**PANCREAS:** Normal in size and echotexture. No focal lesions are seen. No evidence of calculi or calcifications. No evidence of pancreatic duct dilation.

**PARA AORTIC AREAS:** Aorta and IVC appear normal. No evidence of para aortic lymphadenopathy.

**SPLEEN:** Normal in size and measures-11.2 cm. Normal in echotexture. No evidence of focal lesions.

**RIGHT KIDNEY:** Measures 9.9 x 4.3 cm and is normal in size and echotexture. Cortico medullary differentiation is well maintained. There is no hydronephrosis or mass. **Microliths noted in mid and lower pole of right kidney.**

**LEFT KIDNEY:** Measures 9.5 x 4.8 cm and is normal in size and echotexture. Cortico medullary differentiation is well maintained. There is no calculus or hydronephrosis or mass.

about:blank

**Healing Hearts and Lives**

264/125, Kilpauk Garden Road, Kilpauk, Chennai - 600 010. Phone : +91 44 4644 8989 / 75500 53335  
Email : muruganhosp@gmail.com | Website : www.muruganhospitals.in

**URINARY BLADDER:** Normal in size, contour and wall thickness. There is no evidence of calculus or mass. No vesical diverticulum present.

**UTERUS AND OVARIES :** Normal in size and measures- 5.5 X 4.5 cm echotexture. ET- 5.5 mm.

Right ovary measures- 2.8 x 2.6 cm.

Left ovary measures- 3.0 x 2.6 cm.

No ascites present. No retroperitoneal lymphadenopathy present.

**IMPRESSION:**

- Right renal microliths.
- No other significant abnormality detected in the visualized abdominal organs.



DR. SAKTHI, MDRD.,

CONSULTANT RADIOLOGIST,

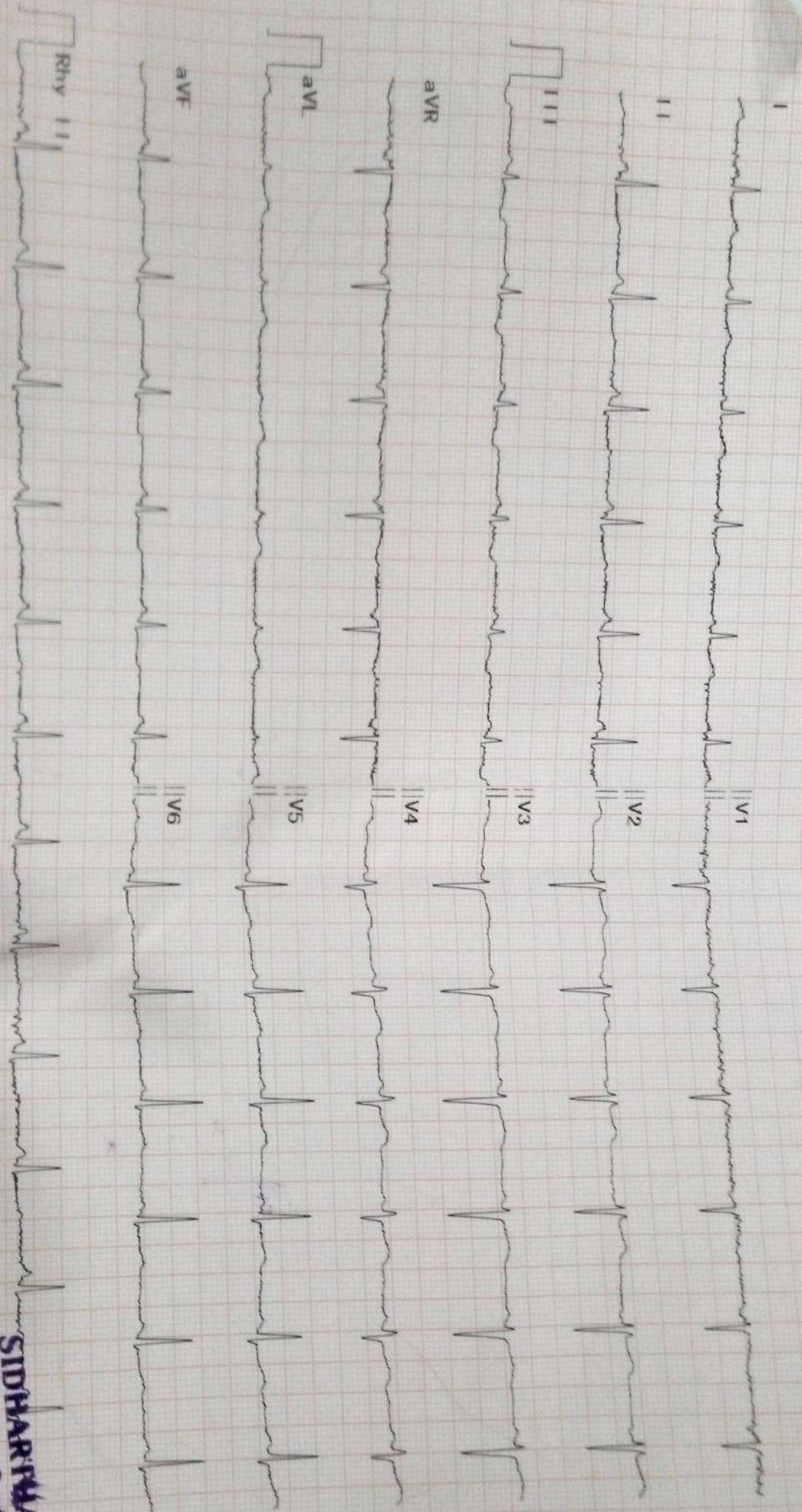
ID : 2212240012  
Name : MRS THENNMOZHI D  
Sex : Female  
Divisions :

DateTime : 2022-12-24 11:08  
Age : 47  
BP :  
Bed No. :  
mmHg

PatientID : 147  
Height : 49 cm  
Weight : kg  
Hospital No. :  
Minnesota Code :  
4-5-0(11)  
5-4-0(V6)  
9-4-2(V4)

Hospital : MURUGAN HOSPITALS  
Diagnosis Info :  
800: Sinus Rhythm  
611: Flat T (V6)

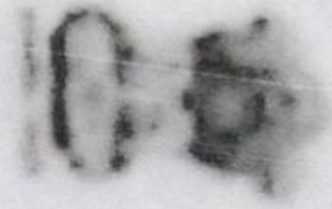HR : 78 bpm  
P Dur PR int 84 / 117ms  
QRS Dur 91 ms  
QT QTc int 381 / 436 ms  
P QRS T axis 58 / 36 / -28 °



Diagnosis for reference. ask your doctor to confirm  
AUTO PRINT 6X2+1R 78bpm 10 mm/mV 0.20Hz-45Hz AD 60Hz 25 mm/sec

Confirmed By :

**SIDHARTHAN MD DKT**  
Consultant Cardiologist  
Reg No. 62978



भारत सरकार  
GOVERNMENT OF INDIA



தேவ்மொழி

D. Thenmozhi

பிறந்த நாள்/ DOB: 14/07/1975

பெண் / FEMALE

8309 6638 9028



எனது ஆதார், எனது அடையாளம்.

*<P. Shankar*