

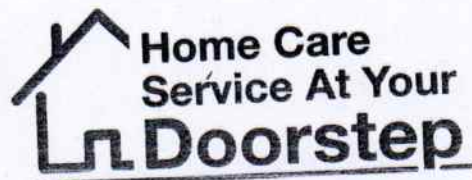Consult. PHYSIO/DIET/DENTAL

Blood Pressure : 100/60 mm of Hg

Height : 146 cm

Weight : 33 Kg

Body Mass Index : 15.7



Medicine Delivery at Your Doorstep Call.:
07720965555

Home Sample Collection No.:

Home Physiotherapy No.:

Patient Name : MRS. SANGITA MANGESH GEDAM
 Age / Sex : 32 Years / Female
 UHID : WHN2.0000335489
 Primary Consultant : DR. WOCKHARDT DOCTOR
 Order No. : 7991
 Bill No. : OCR3/23/0002305
 Order Date : 11/03/2023 09:56 AM
 Sample Collection : 11/03/2023 10:01 AM
 Report Date : 11/03/2023 01:01 PM
 Specimen : EDTA Blood

PARAMETER	METHOD	RESULT	UNIT	B.R.I
MEDIWHEEL FULL BODY HCU MALE AND FEMALE BELOW 40				
Complete Blood Count (With ESR)- EDTA Blood				
Haemoglobin	SLS Method	6.5	g%	11-15
Haematocrit	RBC Pulse Height Detection	22.0	%	40 - 50
MCV	Calculated	62.5	fl	83-101
MCH	Calculated	18.5	pg	27-32
MCHC	Calculated	29.5	g/dl	32-35
RBC Count	DC Detection	3.52	Million/ul	3.8-4.8
RDW-CV	Calculated	17.9	%	12-14
WBC Total Count (TLC)	Electrical Impedance	4570	Cells/cumm	4000 - 10000
Neutrophils	Hydrodynamic Focussing And Microscopy	52	%	40-80
Lymphocytes	Hydrodynamic Focussing And Microscopy	42	%	28-48
Monocytes	Hydrodynamic Focussing And Microscopy	04	%	2-10
Eosinophils	Hydrodynamic Focussing And Microscopy	02	%	0-6
Basophils		0	%	0-2
Platelet Count	Hydrodynamic Focusing DC	277	Thou/Cumm	150-450
MPV		8.9	Calculated	9.4-12.3
Neutrophil Lymphocyte Ratio		1.23		
Erythrocytes		Microcytic, hypochromic		



Patient Name : MRS. SANGITA MANGESH GEDAM
 Age / Sex : 32 Years / Female
 UHID : WHN2.0000335489
 Primary Consultant : DR. WOCKHARDT DOCTOR
 Order No. : 7991
 Bill No. : OCR3/23/0002305
 Order Date : 11/03/2023 09:56 AM
 Sample Collection : 11/03/2023 10:01 AM
 Report Date : 11/03/2023 01:01 PM
 Specimen : EDTA Blood


PARAMETER	METHOD	RESULT	UNIT	B.R.I
-----------	--------	--------	------	-------

MEDIWHEEL FULL BODY HCU MALE AND FEMALE BELOW 40**Complete Blood Count (With ESR)- EDTA Blood**

Leucocytes		Lymphocytosis		
Blood ESR	Westergren Method	15	mm/hr	0-20
Remark:		Advice-Iron study		

--- END OF REPORT ---

SONAL BHAIASARE
Verified By


Dr. ALKA THOOL
Consultant Pathologist
M.B.B.S, MD PATH

Partial Reproduction of Report not permitted. This Report Relates to Sample received by Laboratory
 * B.R.I. BIOLOGICAL REFERENCE INTERVAL ** Test not in Scope of Accreditation




Patient Name : MRS. SANGITA MANGESH GEDAM
 Age / Sex : 32 Years / Female
 UHID : WHN2.0000335489
 Primary Consultant : DR. WOCKHARDT DOCTOR
 Order No. : 7991
 Bill No. : OCR3/23/0002305

Order Date : 11/03/2023 09:56 AM
 Sample Collection : 11/03/2023 10:01 AM
 Report Date : 11/03/2023 11:45 AM
 Specimen : EDTA Blood

PARAMETER	METHOD	RESULT	UNIT	B.R.I
MEDIWHEEL FULL BODY HCU MALE AND FEMALE BELOW 40				
Glycosylated Haemoglobin- EDTA Blood				
Glycosylated Haemoglobin	HPLC	5.2	%	Action required: 7.0-8.0% Good control: 6.5-7.0% Normal control: 4.8-6.4% Poor control: >8.0%
Estimated Mean glucose	Calculated	107.82	mg/dL	

--- END OF REPORT ---

SONAL BHAIKARE
Verified By


Dr. ALKA THOOL
Consultant Pathologist
M.B.B.S, MD PATH

Partial Reproduction of Report not permitted. This Report Relates to Sample received by Laboratory
 * B.R.I - BIOLOGICAL REFERENCE INTERVAL ** Test not in Scope of Accreditation




BIOCHEMISTRY

Patient Name : MRS. SANGITA MANGESH GEDAM
 Age / Sex : 32 Years / Female
 UHID : WHN2.0000335489
 Primary Consultant : DR. WOCKHARDT DOCTOR
 Order No. : 7991
 Bill No. : OCR3/23/0002305
 Order Date : 11/03/2023 09:56 AM
 Sample Collection : 11/03/2023 01:11 PM
 Report Date : 11/03/2023 02:12 PM
 Specimen : Fluoride Plasma

PARAMETER	METHOD	RESULT	UNIT	B.R.I
MEDIWHEEL FULL BODY HCU MALE AND FEMALE BELOW 40				
Plasma Glucose - Fasting.	Enzymatic Hexokinase	82.71	mg/dL	74-109
Urine Sugar Fasting	Double Sequential Enzyme Reaction - GOD/ POD	Absent		
Plasma Glucose- Post Glucose		83	mg/dL	70-140
Urine Sugar Post Prandial	Double Sequential Enzyme Reaction - GOD/ POD	NA		

--- END OF REPORT ---

PRAKASH SHAHU
Verified By


Dr. ALKA THOOL
Consultant Pathologist
M.B.B.S, MD PATH

Partial Reproduction of Report not permitted. This Report Relates to Sample received by Laboratory
 * B.R.I. BIOLOGICAL REFERENCE INTERVAL ** Test not in Scope of Accreditation



BIOCHEMISTRY

Patient Name : MRS. SANGITA MANGESH GEDAM
Age / Sex : 32 Years / Female
UHID : WHN2.0000335489
Primary Consultant : DR. WOCKHARDT DOCTOR
Order No. : 7991
Bill No. : OCR3/23/0002305
Order Date : 11/03/2023 09:56 AM
Sample Collection : 11/03/2023 10:01 AM
Report Date : 11/03/2023 12:01 PM
Specimen : Serum

PARAMETER	METHOD	RESULT	UNIT	B.R.I
MEDIWHEEL FULL BODY HCU MALE AND FEMALE BELOW 40				
Serum Urea	Urease-GLDH	14	mg/dL	1-50
Blood Urea Nitrogen	Calculated	6.7	mg/dL	6-20
Creatinine- Serum				
Creatinine	Enzymatic colorimetric	0.62	mg/dL	0.51-0.95
Plasma Glucose				
Plasma Glucose - Fasting.	Enzymatic Hexokinase	95	mg/dL	74-109
Urine Sugar Fasting	Double Sequential Enzyme Reaction - GOD/ POD	Absent		
Uric Acid- Serum				
Uric Acid	Enzymatic colorimetric	2.1	mg/dL	2.4-5.7
Cholesterol	Colorimetric - Cholesterol Oxidase	137	mg/dL	0-200
Triglycerides	Enzymatic colorimetric	44	mg/dL	0-150
HDL Cholesterol - Direct	Direct Homogenous Enzymatic Colorimetric	76.4		>65: No risk 45-65: Moderate risk <45: High risk
LDL-Cholesterol -Direct	Direct Homogenous Enzymatic Colorimetric	51.8	mg/dL	0-100
VLDL Cholesterol	Calculated	8.8	mg/dL	10-35



Patient Name : MRS. SANGITA MANGESH GEDAM
 Age / Sex : 32 Years / Female
 UHID : WHN2.0000335489
 Primary Consultant : DR. WOCKHARDT DOCTOR
 Order No. : 7991
 Bill No. : OCR3/23/0002305
 Order Date : 11/03/2023 09:56 AM
 Sample Collection : 11/03/2023 10:01 AM
 Report Date : 11/03/2023 12:01 PM
 Specimen : Serum

PARAMETER	METHOD	RESULT	UNIT	B.R.I
-----------	--------	--------	------	-------

MEDIWHEEL FULL BODY HCU MALE AND FEMALE BELOW 40


Chol/HDL Ratio		1.79		0-3
----------------	--	------	--	-----

Liver Function Test (L.F.T.)

Alkaline Phosphatase	Colorimetric IFCC	39.2	U/L	35-104
S.G.O.T (AST)	IFCC Without Pyridoxal 5 Phosphate	14.6	U/L	0-32
S.G.P.T (ALT)	IFCC Without Pyridoxal 5 Phosphate	4.7	U/L	0-35
Total Protein (Serum)	Colorimetric - Biuret Method	7.37	g/dL	6.4-8.3
Albumin, BCG	Colorimetric - Bromo-Cresol Green	4.38	g/dL	3.5-5.2
Globulin	Calculated	2.99	g/dL	1.9-3.5
Albumin/Globulin Ratio	Calculated	1.46		0.9-2
Serum Total Bilirubin	Colorimetric Diazo	0.37	mg/dL	0-1.2
Serum Direct Bilirubin	Colorimetric Diazo	0.19	mg/dL	0-0.4
Serum Indirect Bilirubin	Calculated	0.18	mg/dL	0-1

--- END OF REPORT ---

SONAL BHAIASARE
Verified By


Dr. ALKA THOOL
Consultant Pathologist
M.B.B.S, MD PATH

Partial Reproduction of Report not permitted. This Report Relates to Sample received by Laboratory
 * B.R.I - BIOLOGICAL REFERENCE INTERVAL ** Test not in Scope of Accreditation



IMMUNOLOGY


Patient Name : MRS. SANGITA MANGESH GEDAM
 Age / Sex : 32 Years / Female
 UHID : WHN2.0000335489
 Primary Consultant : DR. WOCKHARDT DOCTOR
 Order No. : 7991
 Bill No. : OCR3/23/0002305

Order Date : 11/03/2023 09:56 AM
 Sample Collection : 11/03/2023 10:01 AM
 Report Date : 11/03/2023 11:45 AM
 Specimen : Serum

PARAMETER	METHOD	RESULT	UNIT	B.R.I
MEDIWHEEL FULL BODY HCU MALE AND FEMALE BELOW 40				
TOTAL T3	ECLIA	96.20	ng/dl	80-200
TOTAL T4	ECLIA	8.89	ug/dl	4.5-11.7
TSH	ECLIA	1.24	μIU/mL	0.27-4.2

--- END OF REPORT ---

SONAL BHAIASARE
Verified By


Dr. ALKA THOOL
Consultant Pathologist
M.B.B.S, MD PATH

Partial Reproduction of Report not permitted. This Report Relates to Sample received by Laboratory
 * B.R.I : BIOLOGICAL REFERENCE INTERVAL ** Test not in Scope of Accreditation




Patient Name	: MRS. SANGITA MANGESH GEDAM	Order Date	: 11/03/2023 09:56 AM
Age / Sex	: 32 Years / Female	Sample Collection	: 11/03/2023 10:01 AM
UHID	: WHN2.0000335489	Report Date	: 11/03/2023 11:50 AM
Primary Consultant	: DR. WOCKHARDT DOCTOR	Specimen	: Urine
Order No.	: 7991		
Bill No.	: OCR3/23/0002305		

<u>PARAMETER</u>	<u>METHOD</u>	<u>RESULT</u>	<u>UNIT</u>	<u>B.R.I</u>
<u>MEDIWHEEL FULL BODY HCU MALE AND FEMALE BELOW 40</u>				
Urine Routine				
Physical Examination				
Colour		yellow		
Appearance		Slightly Hazy		
Urinalyser (Roche UriSys 1100)				
Specific Gravity		1.025		1.003 - 1.035
Reaction (pH)		5		
Leukocytes, microscopy		04	/hpf	
Erythrocytes, microscopy		00	/hpf	
Nitrite, urinalyser		neg		
Protein, urinalyser		Present (trace)		
Glucose, urinalyzer		neg		
Ketone, urinalyser		neg		
Urobilinogen urinalyser		neg		
Bilirubin urinalyser		neg		
Epithelial Cells		8-10		

--- END OF REPORT ---

SOMAI BHAI SARE
Verified By


Dr. ALKA THOOL
Consultant Pathologist
M.B.B.S, MD PATH

Partial reproduction of Report not permitted. This Report Relates to Sample received by Laboratory
* B.R.I. BIOLOGICAL REFERENCE INTERVAL ** Test not in Scope of Accreditation

Page 7 of 8



WOCKHARDT HOSPITALS, NAGPUR

1643, North Ambazari Road, Nagpur - 440 010. Tel : (0712) 6624444, 6624100

Fax : (0712) 2261266 Website : www.wockhardthospitals.com

Registered Office Address :- Wockhardt Towers , BKC , Bandra (East) Mumbai 400051

CIN: U85100MH1991PLC063036

Patient Name : MRS. SANGITA MANGESH GEDAM

Age/Sex : 32 Yrs / Female

Order Date : 11/03/2023 09:56 AM

UHID : WHN2.0000335489

Referred by :

Reporting Date : 11/03/2023 01:22 PM

Order No. : 3055

Bill No. : OCR3/23/0002305

CHEST X-RAY PA VIEW :

Both lung fields are clear.

The costophrenic angles and domes of diaphragm appear normal.

No hilar or mediastinal lesion seen.

Cardiac silhouette is within normal limits.

Visualised bony thorax and soft tissues appear normal.

Impression:

Normal Chest X-Ray.

Dr. NITIN DEVKATE
M.B.B.S., M.D.
RADIOLOGIST



WOCKHARDT HOSPITALS, NAGPUR

1643, North Ambazari Road, Nagpur - 440 010. Tel : (0712) 6624444, 6624100

Fax : (0712) 2261266 Website : www.wockhardthospitals.com

Registered Office Address :- Wockhardt Towers , BKC , Bandra (East) Mumbai 400051

CIN: U85100MH1991PLC063096

Patient Name : MRS. SANGITA MANGESH GEDAM
Age/Sex : 32 Yrs / Female
UHID : WHN2.0000335489
Reporting Date : 11/03/2023 01:08 PM
Bill No. : OCR3/23/0002305

Order Date : 11/03/2023 09:56 AM
Referred by :
Order No. : 3055

USG ABDOMEN WITH PELVIS :

Real time sonography of the abdomen and pelvis was performed using the 3.5 MHz transducer.

The liver is normal in size and shows bright echotexture suggesting fatty infiltration. No focal parenchymal lesion noted. Intrahepatic biliary tree and venous radicles are normal.

The portal vein and CBD appear normal in course and calibre.

The gall bladder is normal in size with a normal wall thickness and there are no calculi noted within.

The pancreas is normal in size and echotexture. No evidence of focal lesion or calcification or duct dilatation seen.

The spleen is normal in size and echotexture.

Both kidneys are normal in size, position and echogenecity.

Cortical thickness and corticomedullary differentiation are normal.

No hydronephrosis or calculi noted.

The bladder is normal in contour, capacity and wall thickness.

No vesical calculi noted.

The uterus is normal in size and anteverted in position.

Myometrial echotexture is homogenous. No focal lesions seen.

Endometrial echocomplex is central in position and 9.2 mm in thickness.

Right ovary appears mildly bulky. It measures 10 cc in volume. Multiple peripherally arranged follicles are noted. Possibility of early changes of polycystic ovarian disease (Needs consideration).

Left ovary obscured.

There is no evidence of ascites.

Impression :

Grade I fatty infiltration of liver.

Possibility of early changes of polycystic right ovarian disease (Needs consideration).

Suggested clinical correlation and follow up.



Dr. NITIN DEVKATE
M.B.B.S., M.D.
RADIOLOGIST

**WOCKHARDT HOSPITALS, NAGPUR**

1643, North Ambazari Road, Nagpur - 440 010, Tel : (0712) 6624444, 6624190

Fax : (0712) 2261266 Website : www.wockhardthospitals.com

Registered Office Address :- Wockhardt Towers , BKC , Bandra (East) Mumbai 400051

CIN: U85100MH1991PLC063096

2D ECHOCARDIOGRAPHY & DOPPLER REPORT

Name : Mrs. Sangita Gedam

Age / Sex : 32 yrs / Female

Done by : Dr. Dinesh Padole

Date : March 11, 2023

UHID NO : 335489

OPD

2D Echo :

CHAMBERS → Normal in size
RWMA → No RWMA
LVEF → 63 %
VALVES → Normal
SEPTAE → Intact
PERICARDIUM → No pericardial effusion
CLOTS/VEGETATIONS → Absent
IVC → Normal

DOPPLER

E > A

Flow across valves → Normal

CONCLUSION :

Good LV systolic function
LVEF – 62 %
No regional wall motion abnormality is present
No LV diastolic dysfunction
No pulmonary hypertension

Dr. Dinesh Padole

MBBS, MD (Gen. Med.), DNB (Cardiology)

Consultant – Interventional Cardiologist

**WOCKHARDT HOSPITALS, NAGPUR**

1643, North Ambazan Road, Nagpur - 440 010. Tel : (0712) 6624444, 6624100

Fax : (0712) 2261266 Website : www.wockhardthospitals.com

Registered Office Address :- Wockhardt Towers, BKC, Bandra (East) Mumbai 400051

CIN: U85100MH1991PLC063096

Rate 66 . Age not entered, assumed to be 50 years old for purpose of ECG interpretation
 . Sinus rhythm.....normal P axis, V-rate 50- 99
 . Baseline wander in lead(s) V2,V3

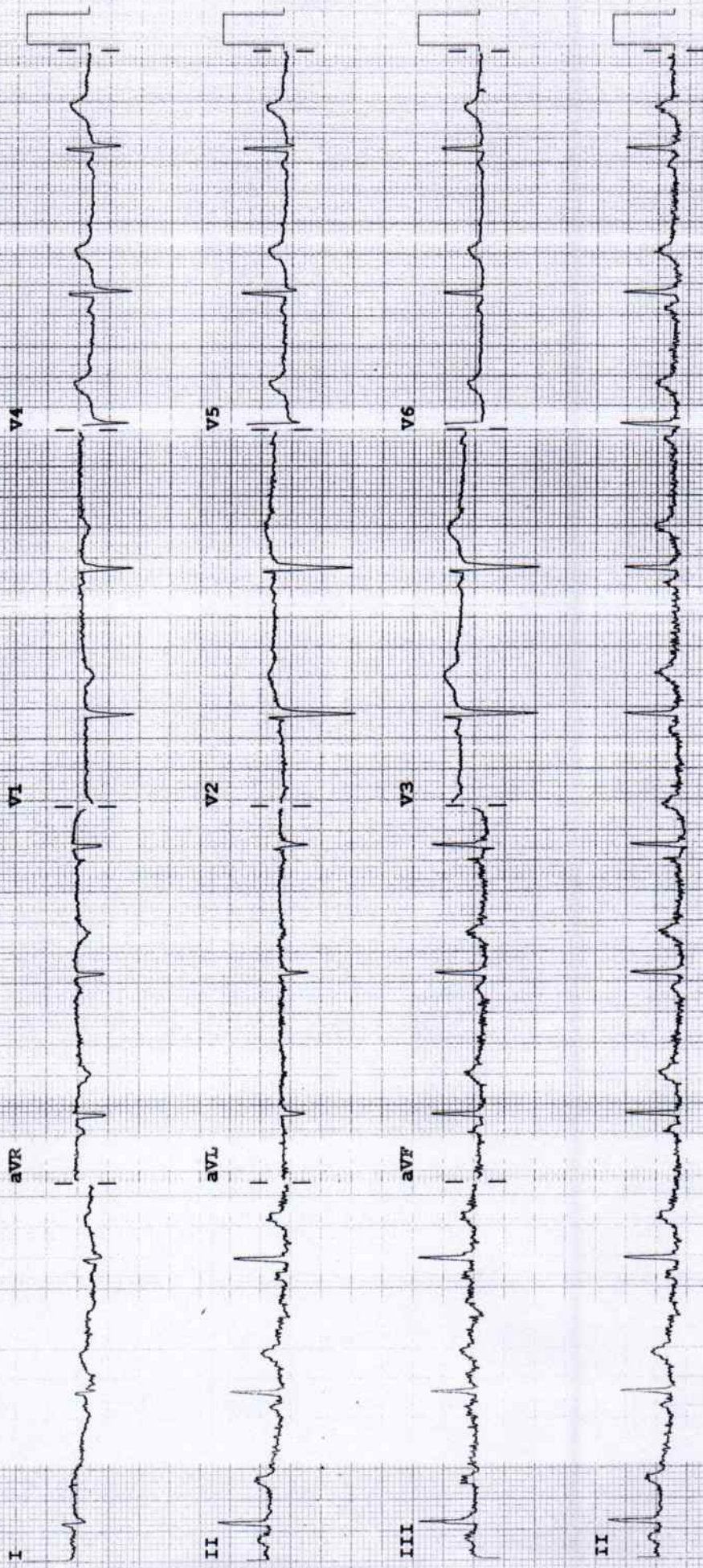
PR 165
 QRSD 73
 QT 374
 QTc 392

--AXIS--
 P 77
 QRS 80
 T 61

- NORMAL ECG -

12 Lead; Standard Placement

Unconfirmed Diagnosis



Dr. Vaibhav Parekh.
B.D.S., Cert. In Implantology.
Consultant - Dentist
M.S.D.C Reg No. A-19780

WOCKHARDT
HOSPITALS

LIFE
WINS

Date: 11/3/23

Name: Mrs. Sangita. Gedam

UHID: 32/F

Primary Diagnosis:

Chief Complaints: Dental checkup.

T-Afebrile / Febrile ____ OF
P-____ / min
R-____ / min
B.P.-____ / ____ mmHg
Pain - Yes / No ____
Fall Risk : Yes / No ____

Rx o/f Mobile 0 $\frac{21}{12}$

Rest piece 0 $\frac{65}{12}$

Cariou 0 $\frac{6}{12}$

Adv. Extraction 0 $\frac{65}{21 \ 12}$

Rest canal 0 $\frac{6}{12}$

FOLLOW UP AFTER

DAYS

[Signature]



WOCKHARDT HOSPITALS, NAGPUR

1643, North Ambazari Road, Nagpur - 440 010. Tel : (0712) 6624444, 6624100

Fax : (0712) 2261266 Website : www.wockhardthospitals.com

Registered Office Address :- Wockhardt Towers , BKC , Bandra (East) Mumbai 400051

CIN: U85100MH1991PLC063096

Name : Sangita Gudani

Age/ Sex : yrs /

Date: 4/3/23

Fundus Examination
(Direct Ophthalmoscopy)

Right

Left

Media

(Res Neystagen)

—
No f.

Optic Disc

Colour
Size
Shape
Margin
NRR
C:D

Mat (Res & Reson)

lu

Blood Vessels

A:V ratio
Abnormalities

Macula

FR
Abnormalities

Periphery

Impression

Dr. NITIN DHOK
9096377550
Consultant Ophthalmology



WOCKHARDT HOSPITALS, NAGPUR

1643, North Ambazari Road, Nagpur - 440 010, Tel : (0712) 6624444, 6624100

Fax : (0712) 2261266 Website : www.wockhardthospitals.com

Registered Office Address :- Wockhardt Towers, BKC, Bandra (East) Mumbai 400051

CIN: U85100MH1991PLC063096