



बैंक ऑफ़ बड़ौदा
Bank of Baroda



नाम

उत्कर्ष कृ. मिश्रा

Name

Utkarsh K. Mishra

कर्मचारी कूट क्र.

E.C. No.

199977

[Handwritten signature]

जारीकर्ता प्राधिकारी

Issuing Authority

[Handwritten signature]

धारक के हस्ताक्षर

Signature of Holder

9/9/2023

Mr. Vitkarash Mishra

32/M

Ht - 167 cm
Wt - 86 kg
BMI - 30.8 kg/m²
obese class 1
B.p. - 130/80

no any major illness
no any allergy
no medical illness

ECG - normal

USG Abd - normal
2D Echo - normal

Adv
Blood test

Uric acid - 7.4

HbA1c - 6.1

slightly dehydrated DM

• CXR

↓
consult & physician

pt fit & can resume his usual activities.





ECHOCARDIOGRAM

NAME	MR. UTKARSH MISHRA
AGE/SEX	32 YRS/M
REFERRED BY	SIDDHIVINAYAK HOSPITAL
DOCTOR	DR. ANANT MUNDE, DNB, DM (CARDIOLOGY)
DATE OF EXAMINATION	09/09/2023

2D/M-MODE ECHOCARDIOGRAPHY

VALVES: MITRAL VALVE: <ul style="list-style-type: none"> • AML: Normal • PML: Normal • Sub-valvular deformity: Absent AORTIC VALVE: Normal <ul style="list-style-type: none"> • No. of cusps: 3 PULMONARY VALVE: Normal TRICUSPID VALVE: Normal	CHAMBERS: LEFT ATRIUM: Normal LEFT VENTRICLE: Normal <ul style="list-style-type: none"> • RWMA: No • Contraction: Normal RIGHT ATRIUM: Normal RIGHT VENTRICLE: Normal <ul style="list-style-type: none"> • RWMA: No • Contraction: Normal
GREAT VESSELS: <ul style="list-style-type: none"> • AORTA: Normal • PULMONARY ARTERY: Normal 	SEPTAE: <ul style="list-style-type: none"> • IAS: Intact • IVS: Intact
CORONARIES: Proximal coronaries normal CORONARY SINUS: Normal	VENACAVAE: <ul style="list-style-type: none"> • SVC: Normal • IVC: Normal and collapsing >20% with respiration
PULMONARY VEINS: Normal	PERICARDIUM: Normal

MEASUREMENTS:

AORTA		LEFT VENTRICLE STUDY		RIGHT VENTRICLE STUDY	
PARAMETER	OBSERVED VALUE	PARAMETER	OBSERVED VALUE	PARAMETER	OBSERVED VALUE
Aortic annulus	22 mm	Left atrium	33 mm	Right atrium	mm
Aortic sinus	mm	LVIDd	52.7 mm	RVd (Base)	mm
Sino-tubular junction	mm	LVIDs	33.8 mm	RVEF	%
Ascending aorta	mm	IVSd	9.6 mm	TAPSE	mm
Arch of aorta	mm	LVPWd	9.6 mm	MPA	mm
Desc. thoracic aorta	mm	LVEF	65 %	RVOT	mm
Abdominal aorta	mm	LVOT	mm	IVC	15.1 mm



OPHTHAL CHECK UP SCREENING

NAME OF EMPLOYEE UTKARSH MISHRA

AGE 32 DATE - 09.09.2023

Spects : Without Glasses

	RT Eye	Lt Eye
NEAR	N/6	N/6
DISTANT	6/6	6/6
Color Blind Test	NORMAL	



SIDDHIVINAYAK HOSPITALS

ID: 1845 Utkarsh Mishra 09-09-2023 10:33:20 AM

Male Years 32
Req. No. :
BP-130/80
SpO2-98
PR-94

HR : 74 bpm
P : 93 ms
PR : 136 ms
QRS : 103 ms
QT/QTcBz : 360/400 ms
P/QRS/T : 20/58/20 °
RV5/SV1 : 0.979/1.116 mV

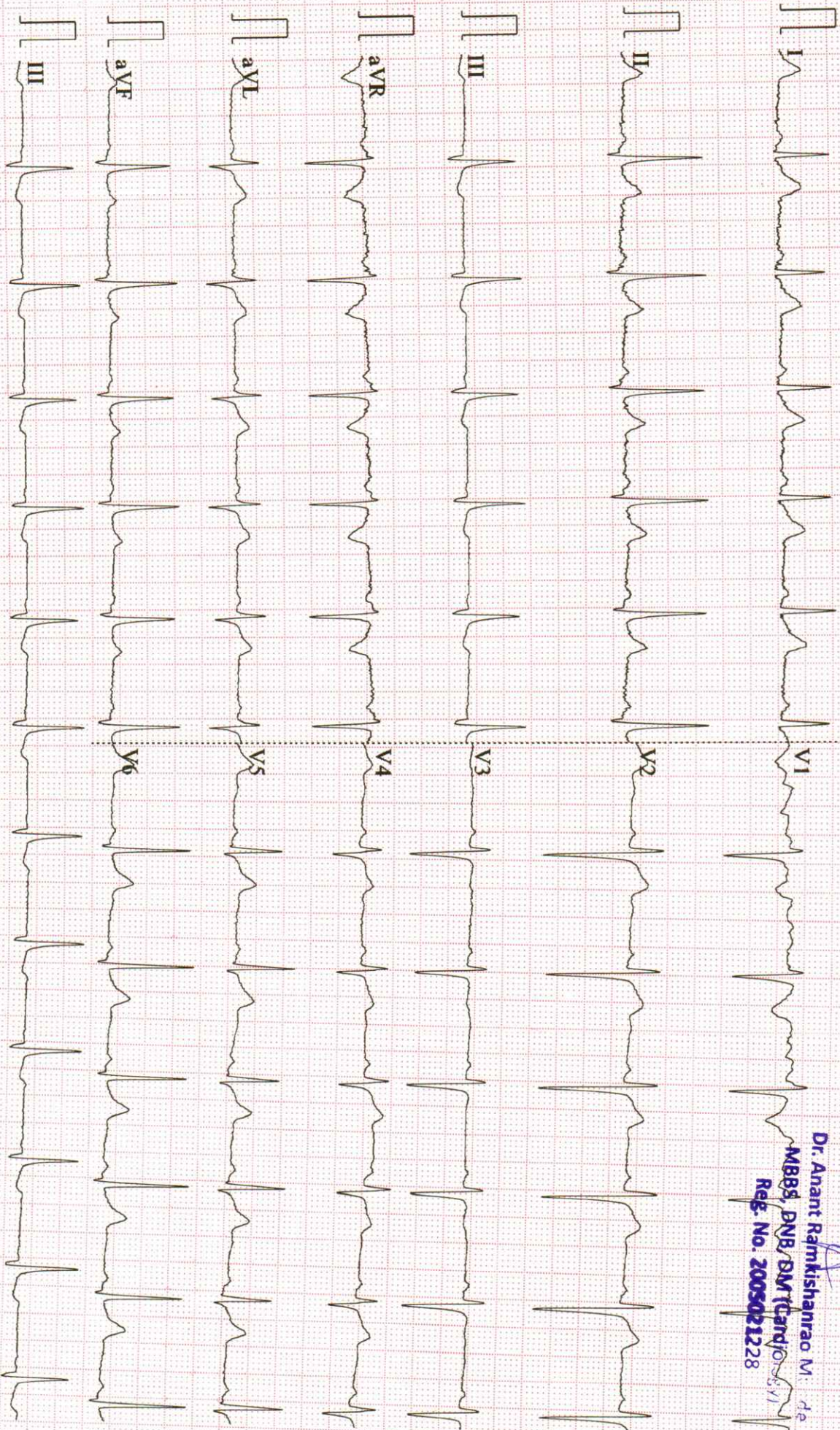
Diagnosis Information:

Sinus Rhythm
Normal ECG

NSR
No Significant ST-T changes
Atrial No definite intervention
required right now

Report Confirmed by:

Dr. Anant Ramkishanrao M. De
MBBS, DNB, DM (Cardiology)
Reg. No. 2005021228



0.25~35Hz AC50 25mm/s 10mm/mV 2*5.0s+1r V2.21 SEMIP V1.92 Siddhivinayak Hospital



Name - Mr. Utkarsh Mishra	Age - 32 Y/M
Ref by Dr.- Siddhivinayak Hospital	Date - 09/09/2023

USG ABDOMEN & PELVIS

Clinical details:- Routine

The Liver is normal in size and shows raised echogenicity. There is no obvious abnormal focal lesion seen. There is no IHBR dilatation seen in both the lobes of the liver.

The CBD and the Portal vein appear normal.

The Gall bladder is well distended & appears normal. No calculi or filling defects are seen. No evidence of Pericholecystic collection. The wall thickness is normal.

Right Kidney measures 10.3 x 4.8 cm & appears normal in shape and position. There is no evidence of hydronephrosis or any calculi seen. Cortico-medullary differentiation is maintained.

Left Kidney measures 10.6 x 4.6 cm & appears normal in shape and position. There is no evidence of hydronephrosis or any calculi seen. Cortico-medullary differentiation is maintained.

The Pancreas is normal in size & shows homogenous echopattern. It shows no focal lesion.

The Spleen is normal in size (9.7 cm) with homogenous echotexture.

The urinary bladder is adequately distended and appears normal. There is no evidence of any obvious calculi or any mass lesion seen. Both Uretero-vesical junctions appear clear. No abnormal intraluminal lesion noted.

Prostate appears normal in size. The echotexture pattern is normal. there is no obvious focal lesion seen.

No free fluid or obvious lymphadenopathy is seen in abdomen and pelvis.

IMPRESSION:

- Fatty liver

Adv.: Clinical and lab correlation.


DR. MOHAMMAD SOHAIB
MBBS; DMRE
CONSULTANT RADIOLOGIST

Note: The above report represents interpretation of various radiographic / sonographic shadows, and hence has its own limitations. This report has to be co-related clinic-pathologically by the referring / physician and it does NOT represent the sole diagnosis. Second opinion is always advisable.



Name	: Mr. UTKARSH MISHRA	Collected On	: 09-Sep-2023 10:33 AM
Lab ID.	: 166892	Received On	: 09-Sep-2023 10:43 AM
Age/Sex	: 32 Years /Male	Reported On	: 10-Sep-2023 5:53 PM
Ref By	: SIDDHIVINAYAK HOSPITAL CGHS /ESIS	Report Status	: FINAL



***LIPID PROFILE**

TEST NAME	RESULTS	UNIT	REFERENCE RANGE
TOTAL CHOLESTEROL (CHOLESTEROL OXIDASE, ESTERASE, PEROXIDASE)	145.0	mg/dL	Desirable blood cholesterol: - <200 mg/dl. Borderline high blood cholesterol: - 200 - 239 mg/dl. High blood cholesterol: - >239 mg/dl.
S.HDL CHOLESTEROL (DIRECT MEASURE - PEG)	35.3	mg/dL	Major risk factor for heart : <30 mg/dl. Negative risk factor for heart disease: >=80 mg/dl.
S. TRIGLYCERIDE (ENZYMATIC, END POINT)	96.8	mg/dL	Desirable level : <161 mg/dl. High : >= 161 - 199 mg/dl. Borderline High : 200 - 499 mg/dl. Very high : >499mg/dl.
VLDL CHOLESTEROL (CALCULATED VALUE)	19	mg/dL	UPTO 40
S.LDL CHOLESTEROL (CALCULATED VALUE)	90	mg/dL	Optimal: <100 mg/dl. Near Optimal: 100 - 129 mg/dl. Borderline High: 130 - 159 mg/dl. High : 160 - 189mg/dl. Very high : >= 190 mg/dl.
LDL CHOL/HDL RATIO (CALCULATED VALUE)	2.55		UPTO 3.5
CHOL/HDL CHOL RATIO (CALCULATED VALUE)	4.11		<5.0

Above reference ranges are as per **ADULT TREATMENT PANEL III** recommendation by NCEP (May 2015).

Result relates to sample tested, Kindly correlate with clinical findings.

----- END OF REPORT -----

Checked By
SHAISTA Q



DR. SMITA RANVEER,
M.B.B.S.M.D. Pathology(Mum)
Consultant Histocytopathologist



Main Center :- 2-3, 'Silver Plaza' E.S.I.S. Hospital Road, Opp. Suryadarshan Tower, Thane (W)-400 604. ☎ +91 91363 56284

Collection Center 1 :- Dr. Ajay Vijay Singh, Clinic : Shop No. 19, Jupiter 3, Cosmos Regency CHS Ltd. Waghbil Road, G. B. Road, Thane (W)-400 615.

Collection Center 2 :- Dantazone, Shop No. 6, Wadhawa Elite Platina 19, Kolshet Road, Thane (W) ☎ : +91 91363 56284

E-mail : radiancediagnosticcentre@gmail.com • Web : www.radianceclinicaldiagnostic.com

Dr. Smita Ranveer's



CLINICAL DIAGNOSTIC CENTRE
COMPLETE PATHOLOGICAL SOLUTION

Name : Mr. UTKARSH MISHRA
Lab ID. : 166892
Age/Sex : 32 Years /Male
Ref By : SIDDHIVINAYAK HOSPITAL CGHS /ESIS

Collected On : 09-Sep-2023 10:33 AM
Received On : 09-Sep-2023 10:43 AM
Reported On : 10-Sep-2023 5:53 PM
Report Status : FINAL



HEMATOLOGY

TEST NAME	RESULTS	UNIT	REFERENCE RANGE
<u>ESR</u>			
ESR	06	mm/1hr.	0 - 20

METHOD - WESTERGREN

Result relates to sample tested, Kindly correlate with clinical findings.

----- END OF REPORT -----

Checked By
SHAISTA Q

DR. SMITA RANVEER.
M.B.B.S.M.D. Pathology(Mum)
Consultant Histocytopathologist



Main Center :- 2-3, 'Silver Plaza' E.S.I.S. Hospital Road, Opp. Suryadarshan Tower, Thane (W)-400 604. ☎ +91 91363 56284

Collection Center 1 :- Dr. Ajay Vijay Singh, Clinic : Shop No. 19, Jupiter 3, Cosmos Regency CHS Ltd. Waghbil Road, G. B. Road, Thane (W)-400 615.

Collection Center 2 :- Dantazone, Shop No. 6, Wadhawa Elite Platina 19, Kolshet Road, Thane (W) ☎ : +91 91363 56284

E-mail : radiancediagnosticcentre@gmail.com • Web : www.radianceclinicaldiagnostic.com

Dr. Smita Ranveer's
RadianceTM
CLINICAL DIAGNOSTIC CENTRE
COMPLETE PATHOLOGICAL SOLUTION

Name : Mr. UTKARSH MISHRA
Lab ID. : 166892
Age/Sex : 32 Years /Male
Ref By : SIDDHIVINAYAK HOSPITAL CGHS /ESIS

Collected On : 09-Sep-2023 10:33 AM
Received On : 09-Sep-2023 10:43 AM
Reported On : 10-Sep-2023 5:53 PM
Report Status : FINAL



URINE ROUTINE EXAMINATION

TEST NAME	RESULTS	UNIT	REFERENCE RANGE
EPITHELIAL	0-2	/ HPF	0 - 5
CASTS	Absent		
CRYSTALS	Absent		
BACTERIA	Absent		Absent
YEAST CELLS	Absent		Absent
ANY OTHER FINDINGS	Absent		
REMARK	Result relates to sample tested. Kindly correlate with clinical findings.		

Result relates to sample tested, Kindly correlate with clinical findings.

----- END OF REPORT -----

Checked By
Pathologist

DR. SMITA RANVEER.
M.B.B.S.M.D. Pathology(Mum)
Consultant Histocytopathologist



Page 5 of 13

Dr. Smita Ranveer's



CLINICAL DIAGNOSTIC CENTRE
COMPLETE PATHOLOGICAL SOLUTION

Name : Mr. UTKARSH MISHRA
Lab ID. : 166892
Age/Sex : 32 Years /Male
Ref By : SIDDHIVINAYAK HOSPITAL CGHS /ESIS

Collected On : 09-Sep-2023 10:33 AM
Received On : 09-Sep-2023 10:43 AM
Reported On : 10-Sep-2023 5:53 PM
Report Status : FINAL



HAEMATOLOGY

TEST NAME	RESULTS	UNIT	REFERENCE RANGE
BLOOD GROUP			
SPECIMEN	WHOLE BLOOD		
* ABO GROUP	'O'		
RH FACTOR	POSITIVE		
Method: Slide Agglutination and Tube Method (Forward grouping & Reverse grouping)			
Result relates to sample tested, Kindly correlate with clinical findings.			
----- END OF REPORT -----			

Checked By
SHAISTA Q

DR. SMITA RANVEER.
M.B.B.S.M.D. Pathology(Mum)
Consultant Histocytopathologist



Main Center :- 2-3, 'Silver Plaza' E.S.I.S. Hospital Road, Opp. Suryadarshan Tower, Thane (W)-400 604. ☎ +91 91363 56284

Collection Center 1 :- Dr. Ajay Vijay Singh, Clinic : Shop No. 19, Jupiter 3, Cosmos Regency CHS Ltd. Waghbil Road, G. B. Road, Thane (W)-400 615.

Collection Center 2 :- Dantazone, Shop No. 6, Wadhawa Elite Platina 19, Kolshet Road, Thane (W) ☎ : +91 91363 56284

E-mail : radiancediagnosticcentre@gmail.com • Web : www.radianceclinicaldiagnostic.com

Dr. Smita Ranveer's



CLINICAL DIAGNOSTIC CENTRE
COMPLETE PATHOLOGICAL SOLUTION

Name : Mr. UTKARSH MISHRA
Lab ID. : 166892
Age/Sex : 32 Years /Male
Ref By : SIDDHIVINAYAK HOSPITAL CGHS /ESIS

Collected On : 09-Sep-2023 10:33 AM
Received On : 09-Sep-2023 10:43 AM
Reported On : 10-Sep-2023 5:53 PM
Report Status : FINAL



***BIOCHEMISTRY**

TEST NAME	RESULTS	UNIT	REFERENCE RANGE
BLOOD UREA (Urease UV GLDH Kinetic)	26.0	mg/dL	19 - 45
BLOOD UREA NITROGEN (Calculated)	12.15	mg/dL	5 - 20
S. CREATININE (Enzymatic)	0.69	mg/dL	0.6 - 1.4
S. URIC ACID (Uricase)	7.4	mg/dL	3.5 - 7.2
S. SODIUM (ISE Direct Method)	142.0	mEq/L	137 - 145
S. POTASSIUM (ISE Direct Method)	3.51	mEq/L	3.5 - 5.1
S. CHLORIDE (ISE Direct Method)	107.0	mEq/L	98 - 110
S. PHOSPHORUS (Ammonium Molybdate)	3.36	mg/dL	2.5 - 4.5
S. CALCIUM (Arsenazo III)	9.40	mg/dL	8.6 - 10.2
PROTEIN (Biuret)	7.17	g/dl	6.4 - 8.3
S. ALBUMIN (BGC)	4.47	g/dl	3.2 - 4.6
S.GLOBULIN (Calculated)	2.70	g/dl	1.9 - 3.5
A/G RATIO calculated	1.66		0 - 2

NOTE

BIOCHEMISTRY TEST DONE ON FULLY AUTOMATED (EM 200)
ANALYZER.

Checked By
SHAISTA Q

DR. SMITA RANVEER.
M.B.B.S.M.D. Pathology(Mum)
Consultant Histocytologist



Main Center :- 2-3, 'Silver Plaza' E.S.I.S. Hospital Road, Opp. Suryadarshan Tower, Thane (W)-400 604. ☎ +91 91363 56284

Collection Center 1 :- Dr. Ajay Vijay Singh, Clinic : Shop No. 19, Jupiter 3, Cosmos Regency CHS Ltd. Waghbil Road, G. B. Road, Thane (W)-400 615.

Collection Center 2 :- Dantazone, Shop No. 6, Wadhawa Elite Platina 19, Kolshet Road, Thane (W) ☎ : +91 91363 56284

E-mail : radiancediagnosticcentre@gmail.com • Web : www.radianceclinicaldiagnostic.com

Dr. Smita Ranveer's



CLINICAL DIAGNOSTIC CENTRE
COMPLETE PATHOLOGICAL SOLUTION

Name : Mr. UTKARSH MISHRA
Lab ID. : 166892
Age/Sex : 32 Years /Male
Ref By : SIDDHIVINAYAK HOSPITAL CGHS /ESIS

Collected On : 09-Sep-2023 10:33 AM
Received On : 09-Sep-2023 10:43 AM
Reported On : 10-Sep-2023 5:53 PM
Report Status : FINAL



Result relates to sample tested, Kindly correlate with clinical findings.

----- END OF REPORT -----



Checked By
SHAISTA Q

DR. SMITA RANVEER.
M.B.B.S.M.D. Pathology(Mum)
Consultant Histocytopathologist



Main Center :- 2-3, 'Silver Plaza' E.S.I.S. Hospital Road, Opp. Suryadarshan Tower, Thane (W)-400 604. ☎ +91 91363 56284

Collection Center 1 :- Dr. Ajay Vijay Singh, Clinic : Shop No. 19, Jupiter 3, Cosmos Regency CHS Ltd. Waghbil Road, G. B. Road, Thane (W)-400 615.

Collection Center 2 :- Dantazone, Shop No. 6, Wadhawa Elite Platina 19, Kolshet Road, Thane (W) ☎ : +91 91363 56284

E-mail : radiancediagnosticcentre@gmail.com • Web : www.radianceclinicaldiagnostic.com

Dr. Smita Ranveer's



CLINICAL DIAGNOSTIC CENTRE
COMPLETE PATHOLOGICAL SOLUTION

Name : Mr. UTKARSH MISHRA
Lab ID. : 166892
Age/Sex : 32 Years /Male
Ref By : SIDDHIVINAYAK HOSPITAL CGHS /ESIS

Collected On : 09-Sep-2023 10:33 AM
Received On : 09-Sep-2023 10:43 AM
Reported On : 10-Sep-2023 5:53 PM
Report Status : FINAL



Peripheral smear examination

TEST NAME	RESULTS
SPECIMEN RECEIVED	Whole Blood EDTA
RBC	Normocytic Normochromic
WBC	Total leucocyte count is normal on smear.
	Neutrophils:55 % Lymphocytes:38 % Monocytes:04 % Eosinophils:03 % Basophils:00 %
PLATELET	Adequate on smear.
HEMOPARASITE	No parasite seen.
Result relates to sample tested, Kindly correlate with clinical findings.	
----- END OF REPORT -----	

Checked By
SHAISTA Q

DR. SMITA RANVEER.
M.B.B.S.M.D. Pathology(Mum)
Consultant Histocytopathologist



Main Center :- 2-3, 'Silver Plaza' E.S.I.S. Hospital Road, Opp. Suryadarshan Tower, Thane (W)-400 604. ☎ +91 91363 56284

Collection Center 1 :- Dr. Ajay Vijay Singh, Clinic : Shop No. 19, Jupiter 3, Cosmos Regency CHS Ltd. Waghbil Road, G. B. Road, Thane (W)-400 615.

Collection Center 2 :- Dantazone, Shop No. 6, Wadhawa Elite Platina 19, Kolshet Road, Thane (W) ☎ : +91 91363 56284

E-mail : radiancediagnosticcentre@gmail.com • Web : www.radianceclinicaldiagnostic.com

Name : Mr. UTKARSH MISHRA
Lab ID. : 166892
Age/Sex : 32 Years /Male
Ref By : SIDDHIVINAYAK HOSPITAL CGHS /ESIS

Collected On : 09-Sep-2023 10:33 AM
Received On : 09-Sep-2023 10:43 AM
Reported On : 10-Sep-2023 5:53 PM
Report Status : FINAL



LIVER FUNCTION TEST

TEST NAME	RESULTS	UNIT	REFERENCE RANGE
TOTAL BILLIRUBIN (Method-Diazo)	0.66	mg/dL	0.0 - 2.0
DIRECT BILLIRUBIN (Method-Diazo)	0.24	mg/dL	0.0 - 0.4
INDIRECT BILLIRUBIN Calculated	0.42	mg/dL	0 - 0.8
SGOT(AST) (UV without PSP)	18.9	U/L	0 - 37
SGPT(ALT) UV Kinetic Without PLP (P-L-P)	22.4	U/L	UP to 40
ALKALINE PHOSPHATASE (Method-ALP-AMP)	103.0	U/L	53 - 128
S. PROTIEN (Method-Biuret)	7.17	g/dl	6.4 - 8.3
S. ALBUMIN (Method-BCG)	4.47	g/dl	3.5 - 5.2
S. GLOBULIN Calculated	2.70	g/dl	1.90 - 3.50
A/G RATIO Calculated	1.66		0 - 2

Result relates to sample tested, Kindly correlate with clinical findings.

----- END OF REPORT -----

Checked By
SHAISTA Q

DR. SMITA RANVEER.
M.B.B.S.M.D. Pathology(Mum)
Consultant Histocytopathologist



Name	: Mr. UTKARSH MISHRA	Collected On	: 09-Sep-2023 10:33 AM
Lab ID.	: 166892	Received On	: 09-Sep-2023 10:43 AM
Age/Sex	: 32 Years /Male	Reported On	: 10-Sep-2023 5:53 PM
Ref By	: SIDDHIVINAYAK HOSPITAL CGHS /ESIS	Report Status	: FINAL



BIOCHEMISTRY

TEST NAME	RESULTS	UNIT	REFERENCE RANGE
GAMMA GT	14.3	U/L	13 - 109
<u>BLOOD GLUCOSE FASTING & PP</u>			
BLOOD GLUCOSE FASTING	113.1	mg/dL	70 - 110
BLOOD GLUCOSE PP	115.3	mg/dL	70 - 140

Method (GOD-POD). DONE ON FULLY AUTOMATED ANALYSER (EM200).

1. Fasting is required (Except for water) for 8-10 hours before collection for fasting specimen. Last dinner should consist of bland diet.
2. Don't take insulin or oral hypoglycemic agent until after fasting blood sample has been drawn

INTERPRETATION

- Normal glucose tolerance : 70-110 mg/dl
- Impaired Fasting glucose (IFG) : 110-125 mg/dl
- Diabetes mellitus : ≥ 126 mg/dl

POSTPRANDIAL/POST GLUCOSE (75 grams)

- Normal glucose tolerance : 70-139 mg/dl
- Impaired glucose tolerance : 140-199 mg/dl
- Diabetes mellitus : ≥ 200 mg/dl

CRITERIA FOR DIAGNOSIS OF DIABETES MELLITUS

- Fasting plasma glucose ≥ 126 mg/dl
- Classical symptoms +Random plasma glucose ≥ 200 mg/dl
- Plasma glucose ≥ 200 mg/dl (2 hrs after 75 grams of glucose)
- Glycosylated haemoglobin $> 6.5\%$

***Any positive criteria should be tested on subsequent day with same or other criteria.

GLYCOCELATED HEMOGLOBIN (HBA1C)

HBA1C (GLYCOSALATED HAEMOGLOBIN)	6.1	%	Hb A1c > 8 Action suggested < 7 Goal < 6 Non - diabetic level
----------------------------------	------------	---	--

Checked By
SHAISTA Q



DR. SMITA RANVEER.
 M.B.B.S.M.D. Pathology(Mum)
 Consultant Histocytopathologist



Dr. Smita Ranveer's



CLINICAL DIAGNOSTIC CENTRE
COMPLETE PATHOLOGICAL SOLUTION

Name : Mr. UTKARSH MISHRA
Lab ID. : 166892
Age/Sex : 32 Years /Male
Ref By : SIDDHIVINAYAK HOSPITAL CGHS /ESIS

Collected On : 09-Sep-2023 10:33 AM
Received On : 09-Sep-2023 10:43 AM
Reported On : 10-Sep-2023 5:53 PM
Report Status : FINAL



BIOCHEMISTRY

TEST NAME	RESULTS	UNIT	REFERENCE RANGE
AVERAGE BLOOD GLUCOSE (A. B. G.)	128.4	mg/dL	NON - DIABETIC : <=5.6 PRE - DIABETIC : 5.7 - 6.4 DIABETIC : >6.5

METHOD

Particle Enhanced Immunoturbidimetry

HbA1c : Glycosylated hemoglobin concentration is dependent on the average blood glucose concentration which is formed progressively and irreversibly over a period of time and is stable till the life of the RBC/erythrocytes. Average Blood Glucose (A.B.G) is calculated value from HbA1c : Glycosylated hemoglobin concentration in whole Blood. It indicates average blood sugar level over past three months.

Result relates to sample tested, Kindly correlate with clinical findings.

----- END OF REPORT -----

Checked By
SHAISTA Q

DR. SMITA RANVEER.
M.B.B.S.M.D. Pathology(Mum)
Consultant Histocytopathologist



Page 13 of 13

Main Center :- 2-3, 'Silver Plaza' E.S.I.S. Hospital Road, Opp. Suryadarshan Tower, Thane (W)-400 604. ☎ +91 91363 56284

Collection Center 1 :- Dr. Ajay Vijay Singh, Clinic : Shop No. 19, Jupiter 3, Cosmos Regency CHS Ltd. Waghbil Road, G. B. Road, Thane (W)-400 615.

Collection Center 2 :- Dantazone, Shop No. 6, Wadhawa Elite Platina 19, Kolshet Road, Thane (W) ☎ : +91 91363 56284

E-mail : radiancediagnosticcentre@gmail.com • Web : www.radianceclinicaldiagnostic.com



Name - Mr. Utkarsh Mishra	Age - 32 Y/M
Ref by Dr.- Siddhivinayak Hospital	Date - 09/09/2023

X- Ray chest (PA VIEW)

No obvious active parenchymal lesion seen in both lungs.

Cardiac and aortic shadows appear normal

No evidence of pleural of effusion is seen.

Both domes of diaphragm appear normal.

No obvious bony lesion is seen.

IMPRESSION:

- No significant abnormality seen.

Adv.: Clinical and lab correlation.

DR. MOHAMMAD SOHAIB

MBBS; DMRE

CONSULTANT RADIOLOGIST

Note: The above report represents interpretation of various radiographic / sonographic shadows, and hence has its own limitations. This report has to be co-related clinic-pathologically by the referring / physician and it does NOT represent the sole diagnosis.

