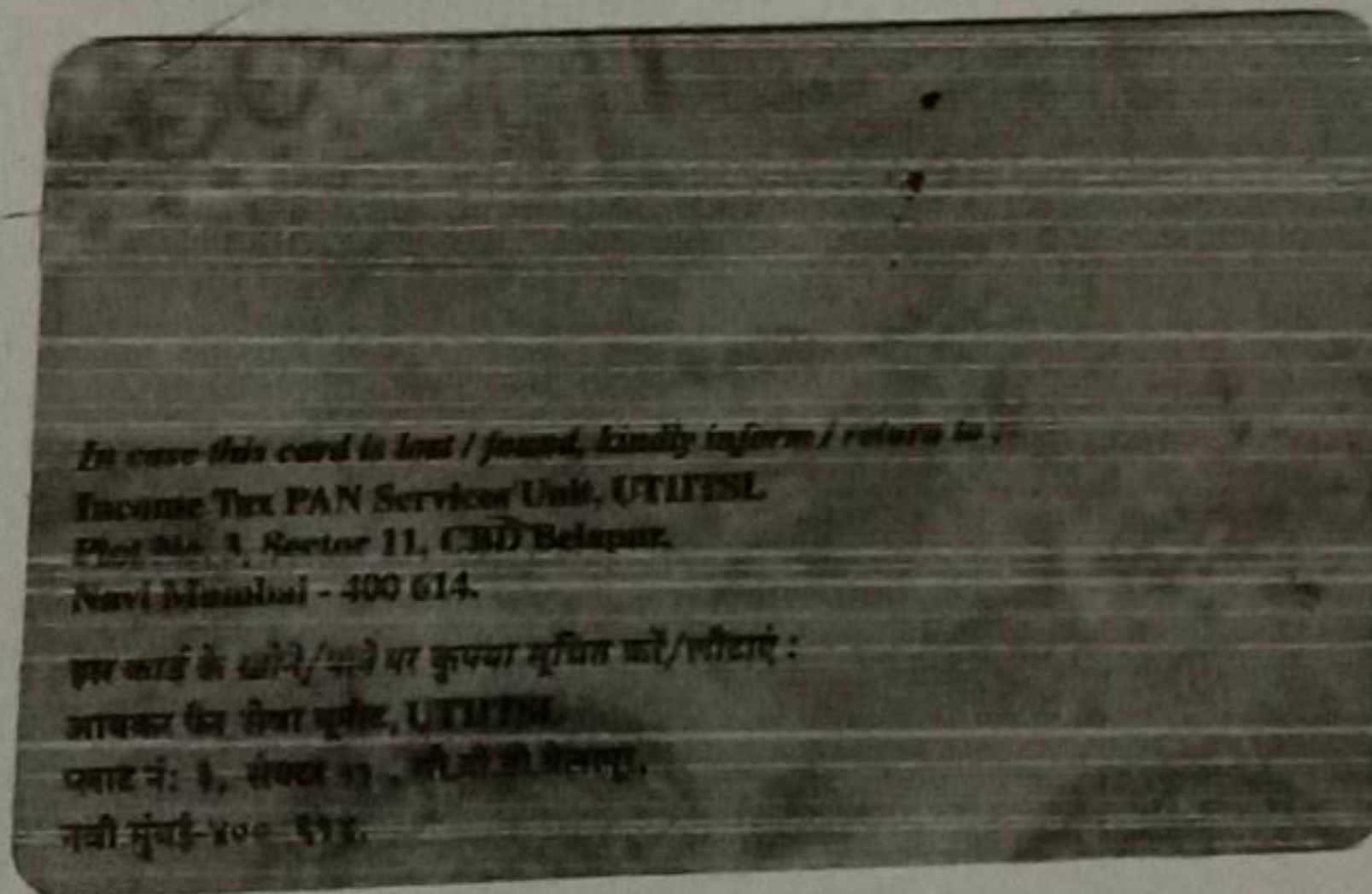
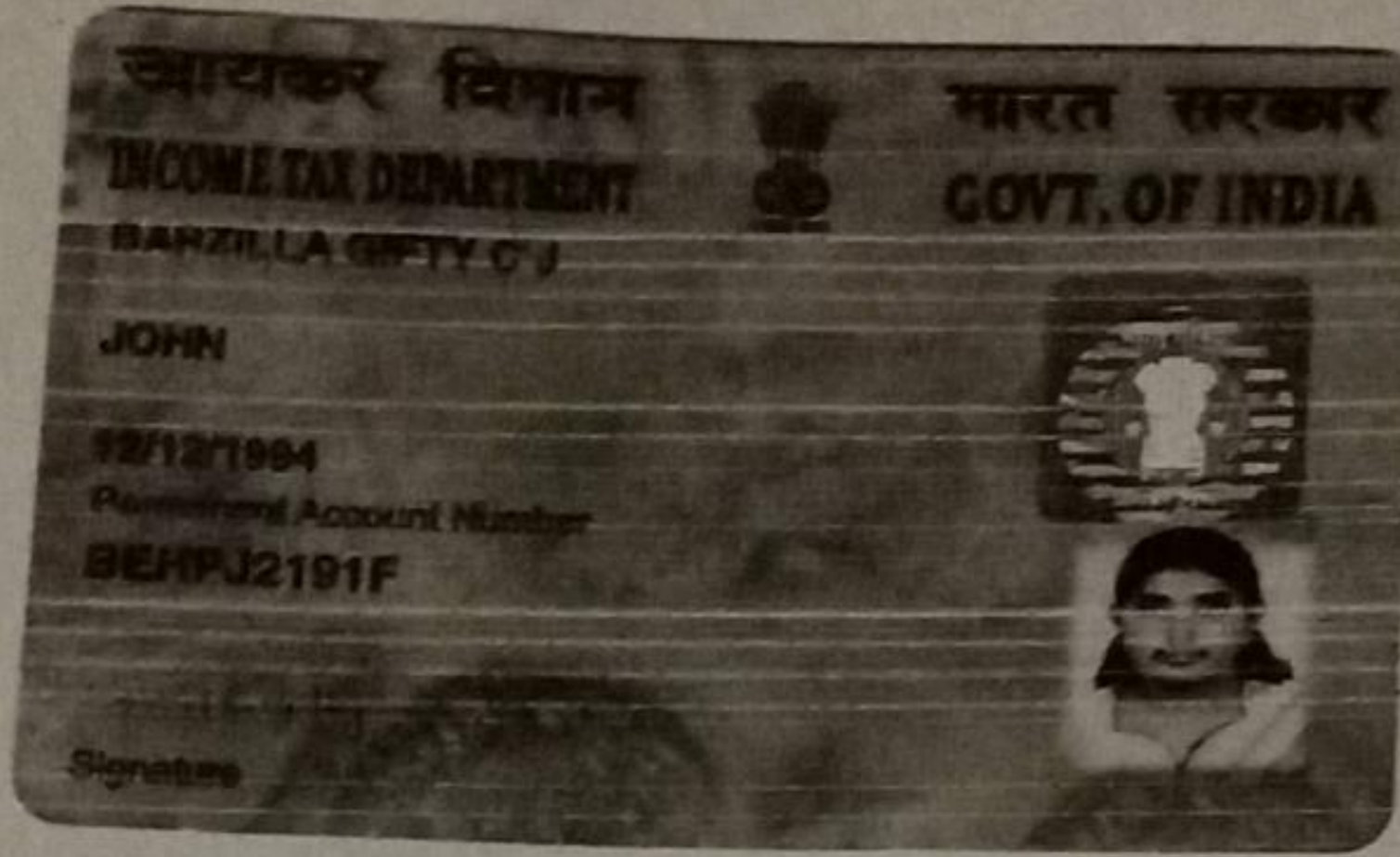


BARZILLA GIFTY.

Stool sample analysis - Not interested.

Barzilla Gifty,



Barzilla Gifty



MURUGAN HOSPITALS

HEALING HANDS



LAB REPORT

Patient Name : Mrs. BARZILLA GIFTY.CJ
 Age / Gender : 27-Years / Female
 UHID ID : MH20220035815
 Doctor Name : Dr. ARUN PRAKASH

OP Report No. : INVA2104919
 Bill No. : INV2108804
 Sample Date : 26/03/2022 - 01:07 PM
 Report Date : 26/03/2022 - 05:15 PM

| Test Name | Result | Units | Reference Interval |
|---------------------------------------|-------------|----------------------|--|
| HAEMATOLOGY | | | |
| Complete Blood Cell Count(CBC) | | | |
| HAEMOGLOBIN | <u>11.1</u> | gms/dl | male :13.0 - 17.0 female :12.0 - 15.0 |
| PACKED CELL VOLUME | 36.0 | % | male : 40 - 50 female : 36 - 46 |
| RBC COUNT | <u>4.50</u> | millions cells/cu.mm | female: 3.8 - 4.8 male : 4.5 - 5.5 |
| TOTAL WBC | 6,200 | Cells/Cumm | 4,000 - 11,000 |
| Differential Count | | | |
| NEUTROPHILS | 63 | % | 40 - 65 |
| LYMPHOCYTES | 32 | % | 30-50 |
| EOSINOPHILS | 05 | % | 01-06 |
| MONOCYTES | <u>00</u> | % | 1-10 |
| BASOPHILS | 00 | % | 0-2 |
| ESR 60 MTS | 13 | mm | 5 - 20 |
| PLATELET COUNT | 3.30 | Lakhs/cumm | 1.5 - 4.5 |
| MCV | 80.2 | fL | 76 - 96 |
| MCH | <u>24.6</u> | pg | 27 - 32 |
| MCHC | 30.8 | gms/dl | 30 - 36 |

INTERPRETATION: Test done on automated three part cell counter, all abnormal results are reviewed and confirmed microscopically.

BLOOD GROUPING & RH TYPING " O " POSITIVE

Healing Hearts and Lives

264/125, Kilpauk Garden Road, Kilpauk, Chennai - 600 010.
 Phone : +91 44 4644 8989 / 75500 53335 | Email : muruganhosp@gmail.com
 Website : www.muruganhospitals.in



MURUGAN HOSPITALS

HEALING HANDS



LAB REPORT

Patient Name : Mrs. BARZILLA GIFTY,CJ
Age / Gender : 27-Years / Female
UHID ID : MH20220035815
Doctor Name : Dr. ARUN PRAKASH

OP Report No. : INVA2104919
Bill No. : INV2108804
Sample Date : 26/03/2022 - 01:07 PM
Report Date : 26/03/2022 - 05:15 PM

| Test Name | Result | Units | Reference Interval |
|---------------------------|------------|--------|----------------------------------|
| BIO CHEMISTRY | | | |
| BLOOD SUGAR FASTING | 90 | mgs/dl | 70-110 |
| BLOOD SUGAR POST PRANDIAL | 113 | mgs/dl | 80- 160 |
| SERUM URIC ACID | 5.5 | mg/dl | male 3.1-7.0 , female 2.5-5.6 |
| SERUM CREATININE | <u>0.6</u> | mg/dl | 0.7-1.4 |
| LIPID PROFILE | | | |
| TOTALCHOLESTEROL | 210 | mg/dl | < 200 |
| TRIGLYCERIDE | 121 | mg/dl | < 150 |
| HDL | 53 | mg/dl | 35 - 80 |
| VLDL | 24 | mg/dl | 2 to 30 |
| LDL | 133 | mg/dl | <130 |
| CHOLESTEROL/ HDL RATIO | 3.9 | mg/dl | |

Healing Hearts and Lives

264/125, Kilpauk Garden Road, Kilpauk, Chennai - 600 010.
Phone : +91 44 4644 8989 / 75500 53335 | Email : muruganhosp@gmail.com
Website : www.muruganhospitals.in



MURUGAN HOSPITALS

HEALING HANDS



LAB REPORT

Patient Name : Mrs. BARZILLA GIFTY.CJ
 Age / Gender : 27-Years / Female
 UHID ID : MH20220035815
 Doctor Name : Dr. ARUN PRAKASH

OP Report No. : INVA2104919
 Bill No. : INV2108804
 Sample Date : 26/03/2022 - 01:07 PM
 Report Date : 26/03/2022 - 05:15 PM

| Test Name | Result | Units | Reference Interval |
|----------------------------|--------|-------|------------------------|
| LIVER FUNCTION TEST | | | |
| BILLIRUBIN(TOTAL) | 0.5 | mg/dl | 0.0 -1.0 |
| BILLIRUBIN(DIRECT) | 0.2 | mg/dl | 0.1- 0.30 |
| BILLIRUBIN(INDIRECT) | 0.3 | mg/dl | 0.2-0.8 |
| SGOT | 15 | IU/L | 0-38 |
| SGPT | 14 | IU/L | 0.0-40 |
| ALKALINE PHOSPHATASE | 71 | IU/L | 40-140 |
| | | | 4-6Years 93-309 |
| | | | 13-15Years 74-390 |
| TOTAL PROTEIN | 7.7 | gm/dl | 6.6-8.7 |
| ALBUMIN | 4.6 | gm/dl | 3.5 - 5.5 |
| GLOBULIN | 3.1 | gm/dl | 2.0-3.5 |
| AG RATIO | 1.4 | | |
| GAMMA G T | 13 | U/L | male<49 |
| | | | female<32 |
| BLOOD UREA NITROGEN | 7.0 | mg/dl | 7-21 |
| HBA1C | 4.7 | % | normal: <6.0 |
| | | | good control: 6.1-7.0 |
| | | | fair control: 7.1-8.0 |
| | | | poor control:8.1 -10.0 |
| | | | unsatisfactory: >10.0 |

Healing Hearts and Lives

264/125, Kilpauk Garden Road, Kilpauk, Chennai - 600 010.

Phone : +91 44 4644 8989 / 75500 53335 | Email : muruganhosp@gmail.com

Website : www.muruganhospitals.in



MURUGAN HOSPITALS

HEALING HANDS



LAB REPORT

Patient Name : Mrs. BARZILLA GIFTY.CJ
 Age / Gender : 27-Years / Female
 UHID ID : MH20220035815
 Doctor Name : Dr. ARUN PRAKASH

OP Report No. : INVA2104919
 Bill No. : INV2108804
 Sample Date : 26/03/2022 - 01:07 PM
 Report Date : 26/03/2022 - 05:15 PM

| Test Name | Result | Units | Reference Interval |
|---------------------------|-------------|-------|--------------------|
| CLINICAL PATHOLOGY | | | |
| URINE SUGAR (PP) | NIL | | |
| URINE ROUTINE | | | |
| COLOUR | PALE YELLOW | | |
| APPEARANCE | CLEAR | | |
| REACTION | ACIDIC | | |
| SUGAR | NIL | | |
| ALBUMIN | NIL | | |
| DEPOSITES | | | |
| PUS CELLS | 2 - 3 | / HPF | |
| EPI CELLS | 1 - 2 | / HPF | |
| RBC COUNT | NIL | / HPF | |
| CAST | NIL | | |
| CRYSTALS | NIL | | |
| OTHERS | NIL | | |

NITHYALAB

Verified by

*** End of Report ***



Healing Hearts and Lives

264/125, Kilpauk Garden Road, Kilpauk, Chennai - 600 010.
 Phone : +91 44 4644 8989 / 75500 53335 | Email : muruganhosp@gmail.com
 Website : www.muruganhospitals.in



MURUGAN HOSPITALS

HEALING HANDS



SCAN REPORT

NAME : Mrs.C.J.BARZILLA GIFTY
AGE / SEX: 27 YEARS /FEMALE
9+7 CONSULTANT: DR. ARUN PRAKASH

UHID NO : MH20220035815
DATE : 26-03-2022
OP/IP :OUT PATIENT

CHEST XRAY PA VIEW

- Trachea is in midline.
- Hila appear Normal.
- Mediastinal shadow appears normal.
- Costophrenic&Cardiophrenic angles appear free.
- Cardiothoracic ratio is within normal limits.
- Lungs fields appear clear
- Bony thorax and soft tissue appear normal

IMPRESSION:

- **No significant abnormality noted.**



CONSULTANT RADIOLOGIST

Healing Hearts and Lives

264/125, Kilpauk Garden Road, Kilpauk, Chennai - 600 010. Phone : +91 44 4644 8989 / 75500 53335
Email : muruganhosp@gmail.com | Website : www.muruganhospitals.in



MURUGAN HOSPITALS

HEALING HANDS

Date : 26/03/2022

NAME OF PATIENT : Mrs.BARZILLA GIFTY

AGE : 27 / FEMALE

Nil visual complaints

O/E

V/A

OD : 6/6 N6

OS : 6/6 N6

Within normal limits in both eyes.

IMPRESSION :

- Nil ophthalmic problem



Medical Officer

264/125, Kilpauk Garden Road, Kilpauk, Chennai - 600 010.

☎ : +91 44 4644 8989 / 75500 53335 email : muruganhosp@gmail.com

Website : www.muruganhospitals.in

ID 2203260017
Name MRS BARZILLA GIFTY
Sex Female
Divisions:

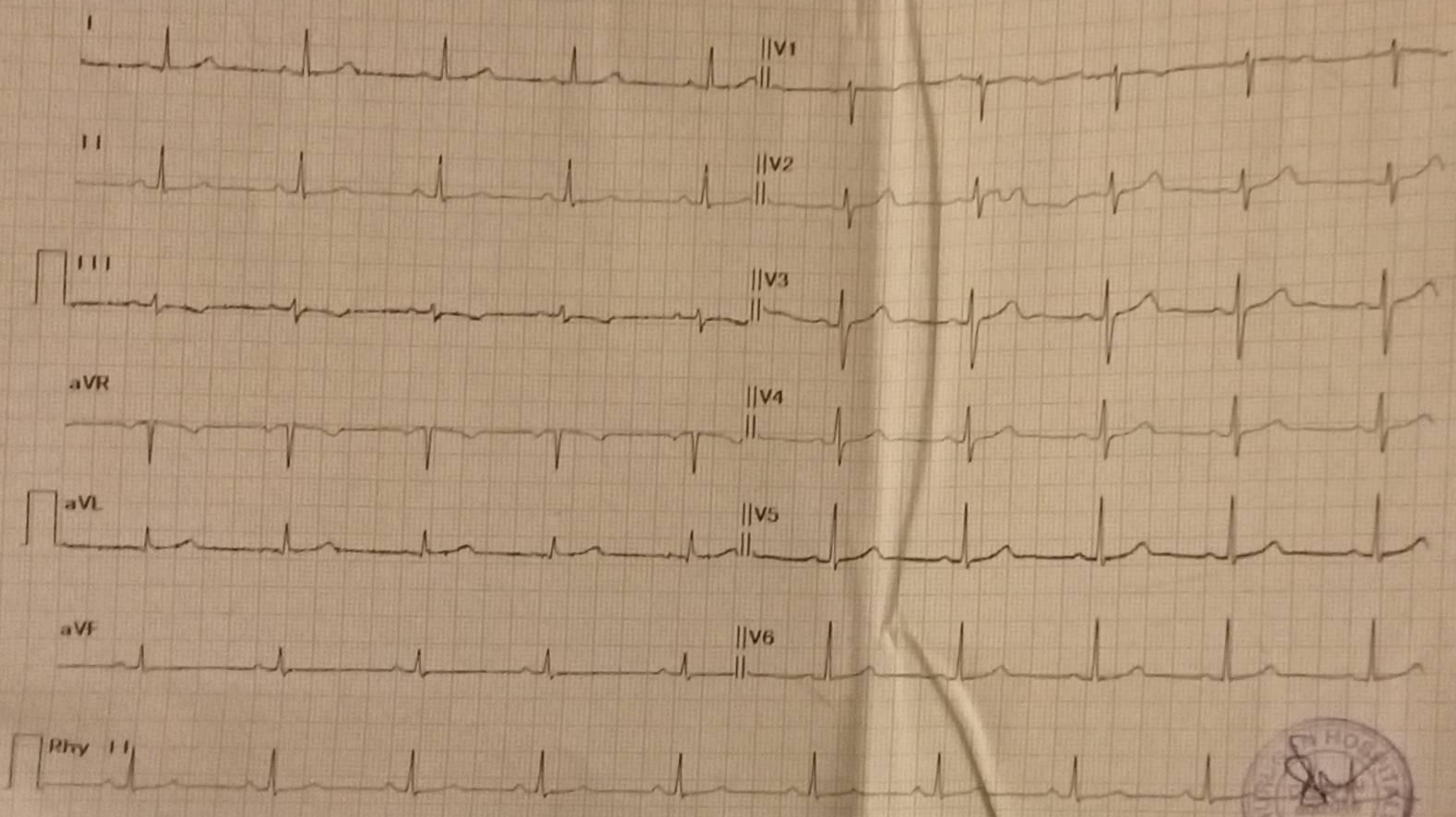
Date/Time 2022-03-26 11:12
Age 27
BP 100/80 mmHg
Bed No.

Hospital MURUGAN HOSPITALS
Height 162 cm
Weight 76 kg
Hospital No.
Minnesota Code

HR 62 bpm
P Dur/PR int 107/157ms
QRS Dur 89 ms
QT/QTc int 402/410 ms
P/QRS/T axis 52/27/1°

RV5/SV1 amp 1.210/0.720mV
RV5+SV1 amp 1.930mV
RV6/SV2 amp 1.186/0.391mV

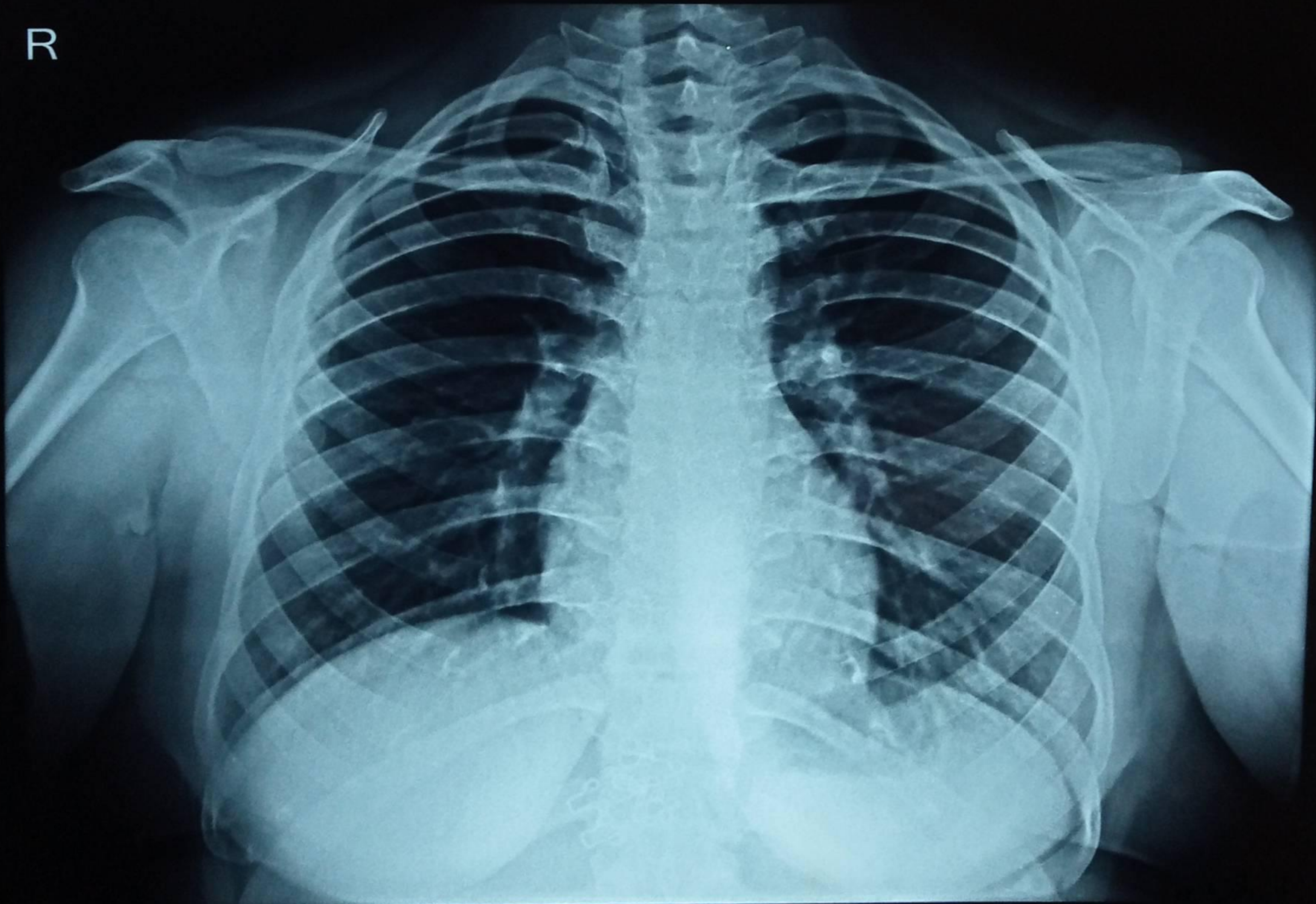
Diagnosis Info
800 Sinus Rhythm
Normal ECG



Diagnosis for reference, ask your doctor to confirm
AUTO PRINT 6X2+1R 62bpm 10 mm/mV 0.50Hz-45Hz AC 60Hz 25 mm/sec Confirmed By:



R



MRS.BARZILLA GIFTY.CJ 27YRS 35815 CHEST-PA 26-03-2022

MURUGAN HOSPITALS, KILPAUK CHENNAI-10 PH NO: 7550053335 / 46448989



MURUGAN HOSPITALS

HEALING HANDS



ECHO CARDIOGRAM REPORT

NAME : MRS.BARZILLA GIFTY.CJ

UHID NO: MH20220035815

AGE&SEX : 27Y /FEMALE

IP/OP :OUTPATIENT

CONSULTANT: DR. ARUN PRAKASH

DATE : 26-03-2022

2D PLAX (mm)

RV - 32 mm
AO - 27 mm
LA - 30 mm

COLOR DOPPLER

Normal

M-Mode (mm)

IVS - 10 mm
PW - 10 mm
LVD - 45 mm
LVS - 26 mm
EF - 70 %
FS - 38 %

DOPPLER (m/sec)

MITRAL E - 0.5 m/s
MITRAL A - 0.8 m/s
PULMONARY - 1.1 m/s
AORTIC - 0.9 m/s
TRICUSPID - 0.4 m/s

IMPRESSION:

No RWMA
Normal LV Systolic function
Grade I left ventricular diastolic dysfunction
Normal RV function
No pulmonary hypertension
No pericardial effusion
No clot/ Vegetation.



DR.SIDHARTHAN MD.,DM.,
CONSULTANT CARDIOLOGIST

Healing Hearts and Lives

264/125, Kilpauk Garden Road, Kilpauk, Chennai - 600 010.

Phone : +91 44 4644 8989 / 75500 53335 | Email : muruganhosp@gmail.com

Website : www.muruganhospitals.in



MURUGAN HOSPITALS

HEALING HANDS



SCAN REPORT

NAME : MRS.BARZILLA GIFTY.CJ UHID NO : MH20220035815
AGE / SEX : 27Y/FEMALE IP / OP NO: OUTPATIENT
CONSULTANT: DR. ARUN PRAKASH DATE : 26.03.2022

ULTRA SOUND SCAN OF ABDOMEN

LIVER: Normal in size and measures- 16.4 cm and **increased in echotexture**. No focal lesions are seen. No dilatation of intra-hepatic biliary radicals present. Hepatic veins and IVC appear normal. Portal vein is normal in caliber. Common bile duct is normal in caliber.

GALL BLADDER: Normal in size and wall thickness. No evidence of any calculus or mass present. No evidence of pericholecystic collections.

PANCREAS: Normal in size and echotexture. No focal lesions are seen. No evidence of calculi or calcifications. No evidence of pancreatic duct dilation.

PARA AORTIC AREAS: Aorta and IVC appear normal. No evidence of para aortic lymphadenopathy.

SPLEEN: Normal in size and measures 9.6 cm. Normal in echotexture. No evidence of focal lesions.

RIGHT KIDNEY: Measures 10.8 x 4.6 cm and is normal in size and echotexture. Cortico medullary differentiation is well maintained. There is no calculus or hydronephrosis or mass.

LEFT KIDNEY: Measures 9.1 x 4.0 cm and is normal in size and echotexture. Cortico medullary differentiation is well maintained. There is no calculus or hydronephrosis or mass.

Healing Hearts and Lives

264/125, Kilpauk Garden Road, Kilpauk, Chennai - 600 010. Phone : +91 44 4644 8989 / 75500 53335
Email : muruganhosp@gmail.com | Website : www.muruganhospitals.in

URINARY BLADDER: Normal in size, contour and wall thickness. There is no evidence of calculus or mass. No vesical diverticulum present.

UTERUS: Measures 7.8 x 4.6cm normal size and echo texture. ET = 5.6mm.

RIGHT OVARY : Measures 2.5 x 2.6cm normal size and echotexture

LEFT OVARY : Measures 2.9 x 1.5 cm normal size and echotexture

No ascites present. No retroperitoneal lymphadenopathy present.

IMPRESSION:

- ❖ **Hepatomegaly with fatty infiltration.**
- ❖ **No other significant abnormality.**



Dr. SAKTHI, MDRD.
Consultant Radiologist.