

Dr. ARPITA AGARWAL

MBBS, MS, FVLPEI (GLAUCOMA AND CATARACT.)
 CATARACT, GLAUCOMA AND REFRACTIVE SURGEON
 EX FELLOW AND CONSULTANT LV PRASAD EYE INSTITUTE, HYDERABAD
 EX CONSULTANT PEOPLES'S HOSPITAL, BHOPAL
 EX CONSULTANT ASG EYE HOSPITAL, BHOPAL

NAME *M. Vishish* AGE *40/M* DATE *12/10/2022*

C/O. *Itching in BE & on 1 old*

Mem, Eye Pain

VN	UNAIDED	WITH GLASS	PINHOLE
RE	<i>6/6</i>	<i>—————</i>	<i>—————</i>
LE	<i>6/6</i>	<i>—————</i>	<i>—————</i>

AR	SPI	CYL	AXIS
RE	<i>-0.25</i>		
LE	<i>-0.25</i>		

REFRACTION;

PG

SUB	SPI	CYL	AXIS	VN
RE	<i>6/6</i>	<i>—————</i>	<i>—————</i>	<i>6/6</i>
LE	<i>6/6</i>	<i>—————</i>	<i>—————</i>	<i>6/6</i>
NV	<i>+1.00</i>	<i>W</i>	<i>OSP</i>	<i>NIG BE</i>

Handwritten notes:
glasses
for near
see eye pain
40
xm



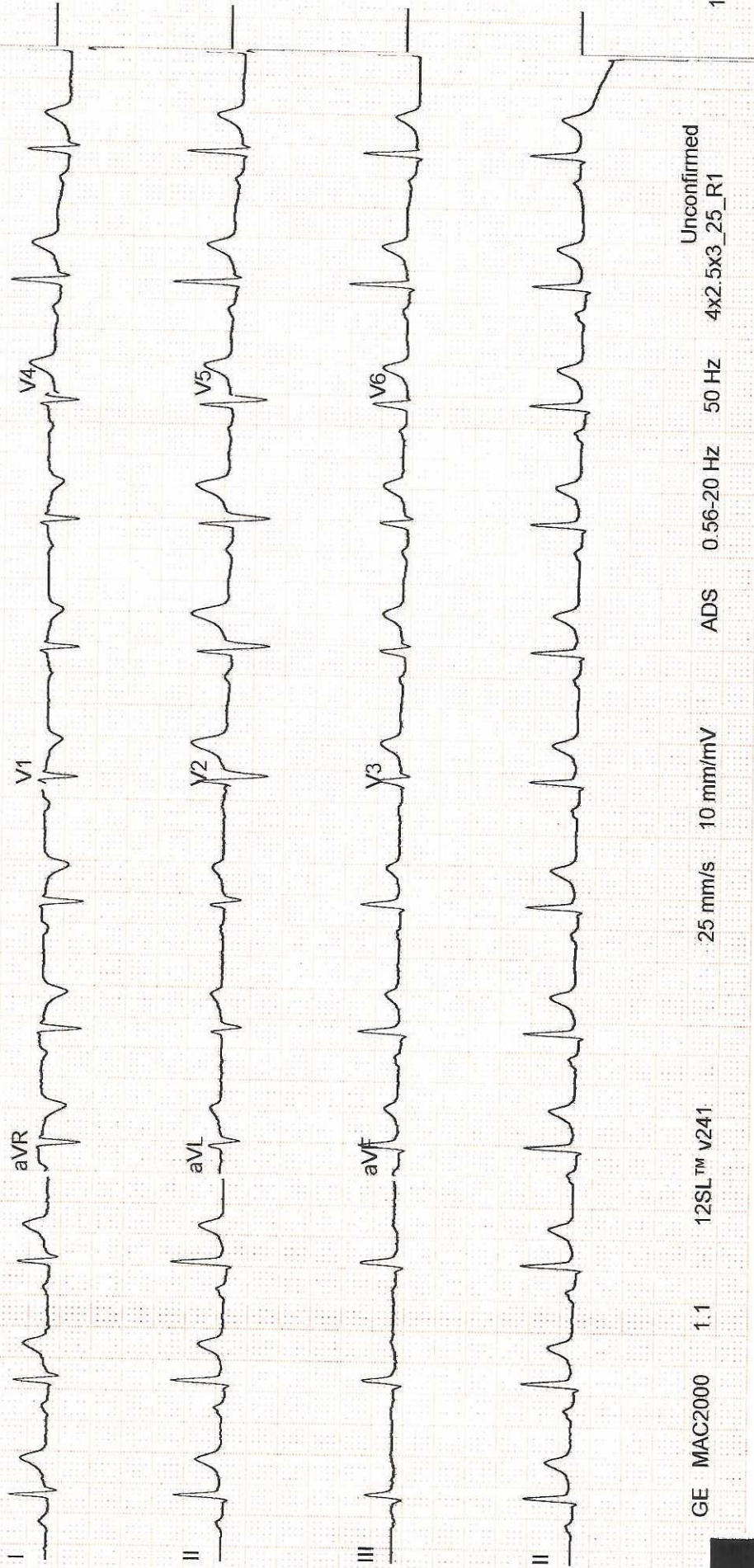
Male

QRS: 86 ms
QT / QTcBaz: 360 / 407 ms
PR: 182 ms
P: 92 ms
RR / PP: 774 / 779 ms
P / QRS / T: 38 / 62 / 33 degrees

*** Poor data quality, interpretation may be adversely affected
Sinus rhythm with occasional ventricular-paced complexes
Abnormal ECG

Technician:
Ordering Ph:
Referring Ph:
Attending Ph:

NR
[Signature]





ECHOCARDIOGRAPHY REPORT

Patient's Name	Grish Paroche	Date	12/10/2024
Age/Sex	40Y/M	UHID	HC -52633
Referred By	Health Check	Done By	Dr.Gaurav Khandelwal

-Left Ventricle : Normal Left Ventricular Size, Wall Thickness & Function.

-Left Ventricular Ejection Fraction is within Normal Limits (LVEF : 60%)

-Left Atrium : Normal Left Atrial Size & Functions.

-Right Ventricle : Normal Right Ventricular Size & Functions.

-Right Atrium : Normal Right Atrial Size & Function.

-Valvular Structures : Normal Mitral, Tricuspid, Pulmonic & Aortic Valve Structures.

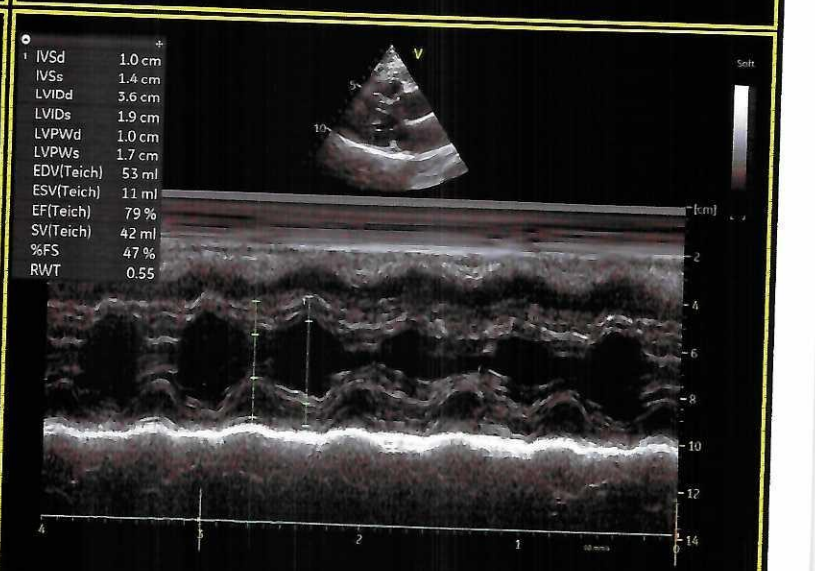
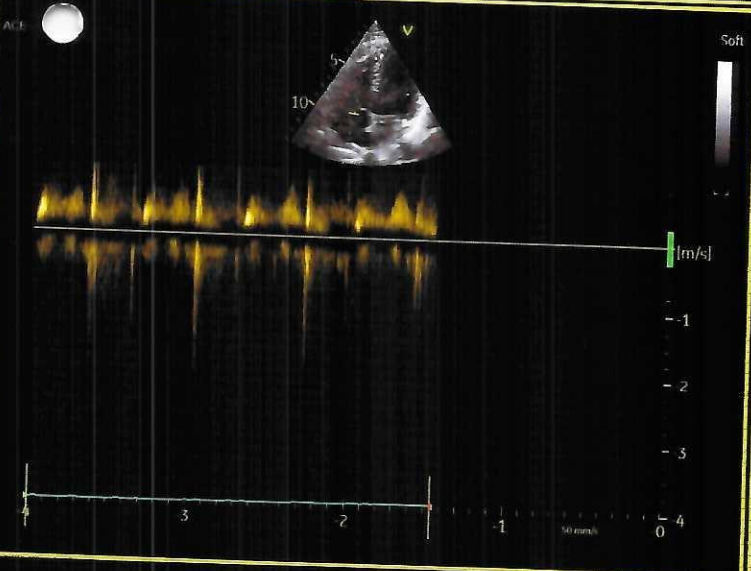
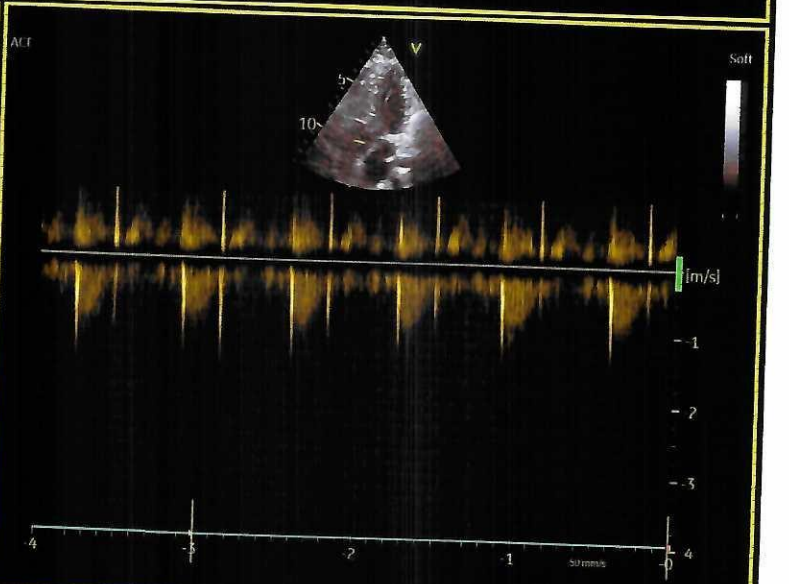
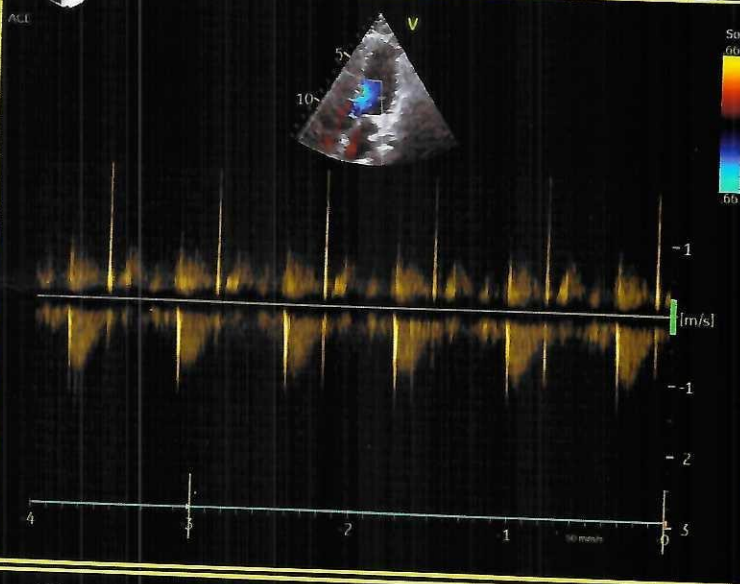
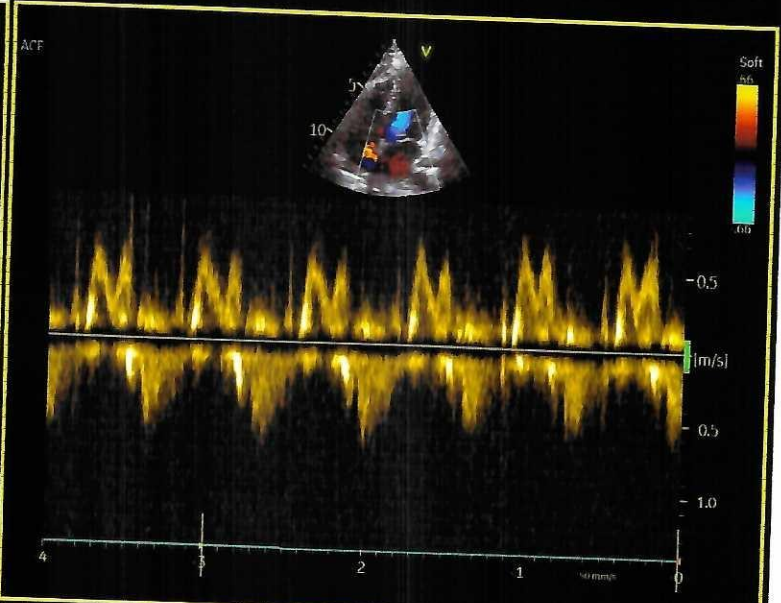
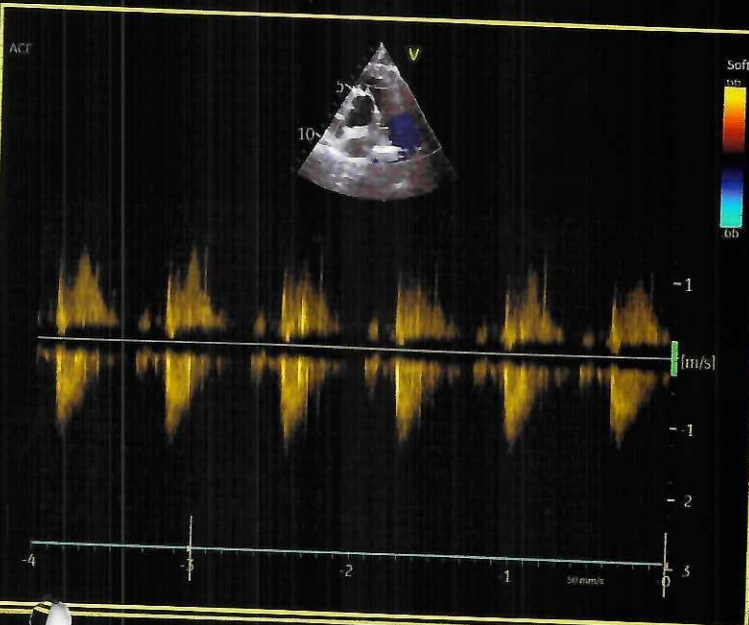
-Aortic Root is Normal.

-No Evidence of Pericardial Effusion.

-No LA / LV Clot

DR. GAURAV KHANDELWAL

**DM (Cardiology), FACC, FESC, FSCAI, FIC
INTERVENTIONAL CARDIOLOGIST**



ULTRA SONOGRAPHY ABDOMEN

Patient Name:	GIRISH PAROCHE	Patient ID:	ASHB.0000052633
Age:	40 Years	Sex:	M
Accession Number:	17101.224011819	Modality:	US
Referring Physician:	CoC Self	Study:	ULTRASOUND - WHOLE ABDOMEN
Study Date:	12-Oct-2024		

Liver:- is mildly enlarged in size (15.4cm) and shows mild increased in parenchymal echotexture with preserved periportal echoes. Portal and hepatic venous system appears normal. Intra and extra hepatic biliary radicals are not dilated.

Gall Bladder:- is normal in size and shape. Its lumen is echofree.

Pancreas is normal in size outline and echopattern.

Spleen is normal in size and echopattern.

Both kidneys are normal in size, shape and echogenicity. Central pelvicalyceal sinus and corticomedullary ratio are normal.

Right kidney measures:- 8.9x4.1cm

Left kidney measures:- 8.1x4.0cm

Urinary bladder is normal in shape and contour. Its wall is normal.

Prostate is normal in size and shape and echotexture. Estimated volume is- 11cc.

No evidence of ascites is seen.

IMPRESSION:- Sonography Study Reveals:-

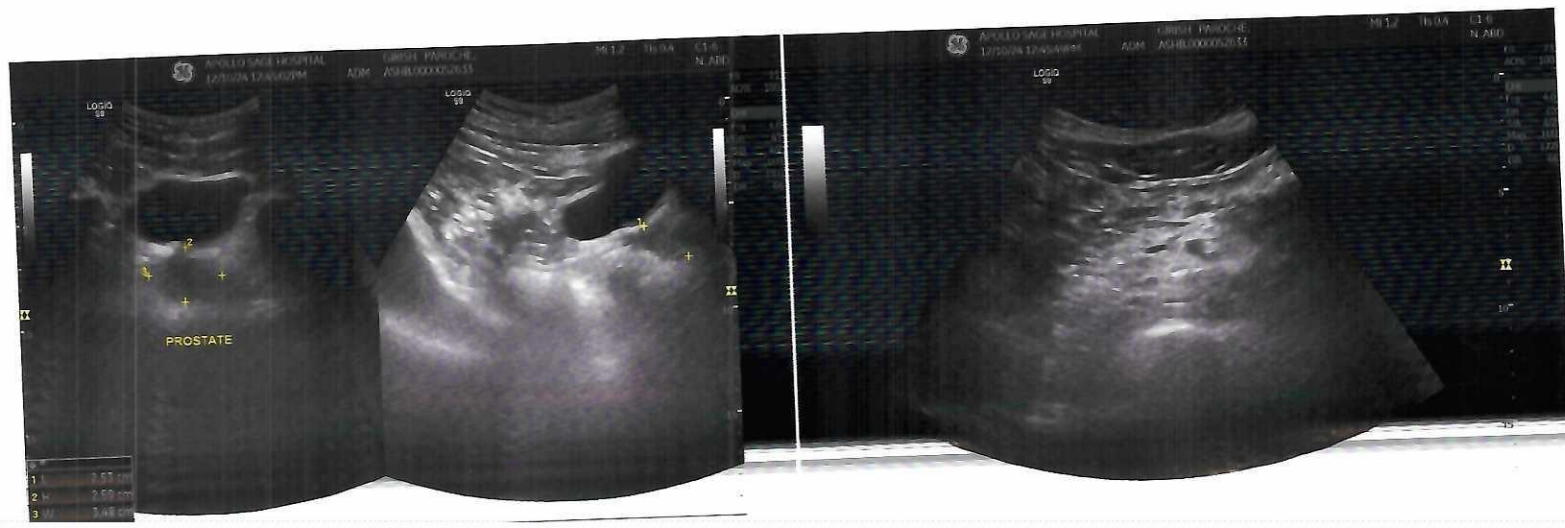
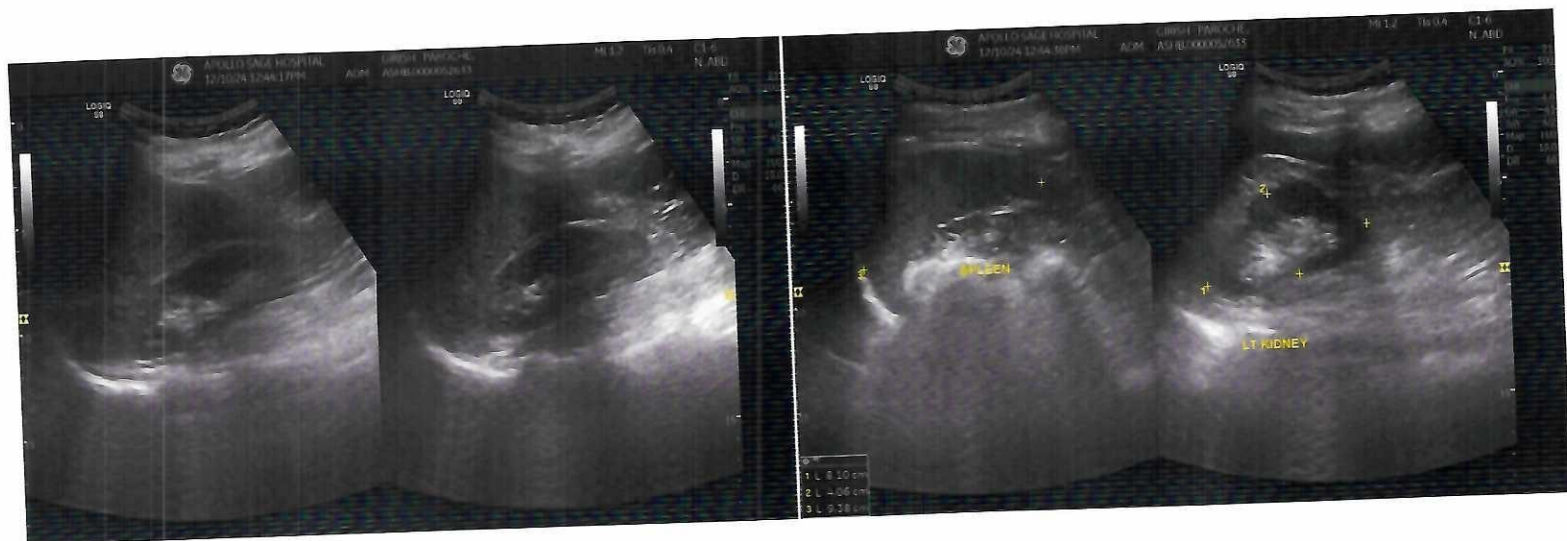
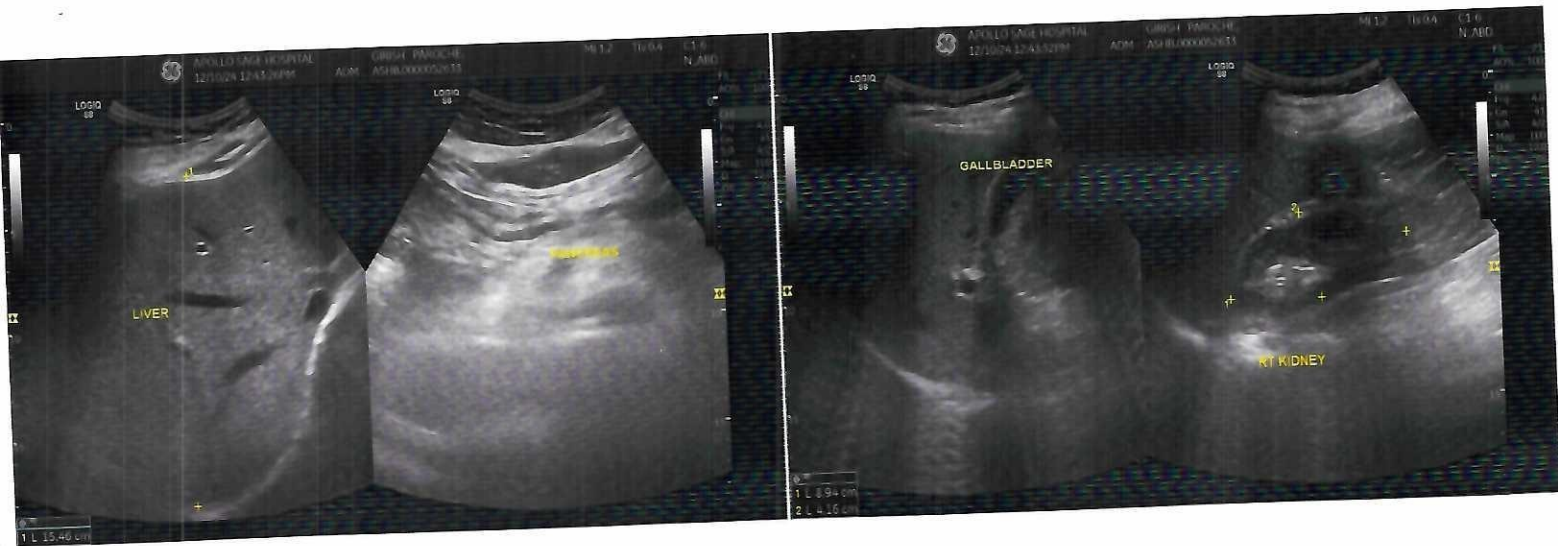
- Mild hepatomegaly with grade I fatty liver.

ADV:- Clinical Correlation.

Nohitas

DR. HARI SANTOSH
CONSULTANT RADIOLOGIST





Patient Name:	GIRISH PAROCHE	Patient ID:	ASHB.0000052633
Age:	40 Years	Sex:	M
Accession Number:	17101.124017421	Modality:	DX
Referring Physician:	CoC Self	Study:	CHEST
Study Date:	12-Oct-2024		

X-RAY CHEST (PA VIEW)

Both lung fields are clear. No active pleural or parenchymal lesion is seen.

The hila, mediastinum, bony thoracic cage and the diaphragmatic domes are normal.

The costophrenic and cardiophrenic angles are clear.

The cardiac silhouette is unremarkable.

IMP:- RADIOGRAPHIC IMAGE REVEALS:-

No significant abnormality detected.

Thanks for Ref



DR. HARI SANTOSH
CONSULTANT RADIOLOGIST

Date: 12-Oct-2024 10:25:47



--

Name : **Mr. GIRISH PAROCHE** Age : **40Yr 3Mth 1Days** Gender : **Male**
 UHID : ASHB.0000052633 /BPLAH11075 **W/BNo/RefNo: AHC**
 SIN \ LRN : 185488 \ 185489 \ 185490 \ 185491 \ 73460
 Specimen : Blood
 Ref Doctor : CoC Self



ASHB.0000052633

Collected on : 12-OCT-2024 09:45:44 AM Received on : 12-OCT-2024 10:55:22 AM Reported on : 12-OCT-2024 01:28:36 PM

MEDIWHEEL FULL BODY ANNUAL PLUS ABOVE 50 MALE

<u>TEST NAME</u>	<u>RESULT</u>	<u>BIOLOGICAL REFERENCE INTERVALS</u>	<u>UNITS</u>
GLUCOSE - SERUM / PLASMA (FASTING)			
GLUCOSE - PLASMA (FASTING)	93	70-100	mg/dL
GLUCOSE - SERUM / PLASMA (POST PRANDIAL)			
GLUCOSE - PLASMA - (POST PRANDIAL)	103	70-140	mg/dL
GLYCOSYLATED HEMOGLOBIN (HBA1C) - WHOLE BLOOD	5.3	4.0-5.6	%
CHOLESTEROL - SERUM / PLASMA	209 *	Desirable: <200 Borderline High: 200-239 High >240	mg/dL
HDL CHOLESTEROL - SERUM / PLASMA	57	>40	mg/dL
LDL CHOLESTEROL - SERUM / PLASMA	140 *	Optimal: <100 Above optimal: 100-129 Borderline high: 130-159 High: 160-189 Very high: >190	mg/dL
TRIGLYCERIDES - SERUM / PLASMA	113	Normal<150 Borderline high 150-199 High 200-499 Very high: ≥ 500	mg/dL

Name : **Mr. GIRISH PAROCHE** Age : **40Yr 3Mth 1Days** Gender : **Male**
 UHID : ASHB.0000052633 / BPLAH11075 W/BNo/RefNo : AHC
 SIN ILRN : 185487 \ 185493 \ 73460
 Specimen : Urine
 Ref Doctor : CoC Self



Collected on : 12-OCT-2024 09:45:44 AM Received on : 12-OCT-2024 11:13:19 AM Reported on : 12-OCT-2024 12:02:28 PM

MEDIWHEEL FULL BODY ANNUAL PLUS ABOVE 50 MALE

<u>TEST NAME</u>	<u>RESULT</u>	<u>BIOLOGICAL REFERENCE INTERVALS</u>	<u>UNITS</u>
CBC			
HAEMOGLOBIN	15.99	13.0-17.0	g/dL
Packed cell volume (Calculated)	48.5	38.3-48.6	%
RBC COUNT(Impedance)	5.84	4.50-5.90	Million/ul
MCV-	83.1	80-100	fl
MCH-	27.4	27-32	pg
MCHC-	33.0	32-36	g/dL
RDW (Derived from RBC histogram)	15.6 *	11.8 - 14.5	%
TLC COUNT	5.85	4.0-11.0	10 ³ /mm ³
DIFFERENTIAL COUNT			
Neutrophils	57	40-80	%
Lymphocytes	33	20-40	%
Monocytes	7	2-10	%
Eosinophils	3	1-6	%
Basophils	0	0-2	%
Platelet Count(Impedance)	341.0	150-450	10 ³ /mm ³
Mean Platelet Volume	8.36	6.5-12.0	fl
ERYTHROCYTE SEDIMENTATION RATE (ESR)	31 *	0-15	mm/1st hr
URINE ROUTINE (CUE)			

--

Name : **Mr. GIRISH PAROCHE** Age : **40Yr 3Mth 1Days** Gender : **Male**
 UHID : ASHB.0000052633 / BPLAH11075 W/BNo/RefNo : AHC
 SIN ILRN : 185487 \ 185493 \ 73460
 Specimen : Urine
 Ref Doctor : CoC Self



Collected on : 12-OCT-2024 09:45:44 AM Received on : 12-OCT-2024 11:13:19 AM Reported on : 12-OCT-2024 12:02:28 PM

MACROSCOPIC EXAMINATION

Specific Gravity(Automated – Reflectance Spectrometer)	1.025	1.005 - 1.025	
Colour:(Naked Eye Examination)	Pale-Yellow		
Transparency:(Naked Eye Examination)	Clear		
pH(Automated – Reflectance Spectrometer)	Acidic		
Protein :(Automated – Reflectance Spectrometer/Sulpho salicylic acid method)	Nil		
Sugar:(Automated - Reflectance Spectrometer/ Benedict's Test)	Nil		
Ketone(Automated – Reflectance Spectrometer/Rothera's test)	Nil		
Bilirubin: (Automated – Reflectance Spectrometer/Fouchet's method)	Nil		
Cells:			
RBC(Automated - Reflectance spectrometer/Microscopy/Flow cytometric)	Nil		
Pus Cells(Automated – Reflectance spectrometer/Microscopy/Flow	1-2	0.0 - 5.0/HPF	/hpf

--

Name : **Mr. GIRISH PAROCHE** Age : **40Yr 3Mth 1Days** Gender : **Male**
 UHID : ASHB.0000052633 / BPLAH11075 W/BNo/RefNo : AHC
 SIN \LRN : 185487 \ 185493 \ 73460
 Specimen : Urine
 Ref Doctor : CoC Self



Collected on : 12-OCT-2024 09:45:44 AM Received on : 12-OCT-2024 11:13:19 AM Reported on : 12-OCT-2024 12:02:28 PM

cytometric)
 Epithelial Cells(Microscopic /Flow **1-2** <20 /hpf
 cytometric)
 Yeast Cells **Absent**
 Bacteria: **Absent**
 Casts:(Microscopic /Flow cytometric) **Absent** ABSENT
 Crystals:(Microscopic /Flow cytometric) **Absent**
Report Status:Final

*** END OF REPORT ***

CHECKED BY : 154493
 727938



Dr. Shubhra Prasad
 Consultant Pathologist

Printed On : 18-OCT-2024 11:27:49 AM

Name : **Mr. GIRISH PAROCHE** Age : **40Yr 3Mth 1Days** Gender : **Male**
UHID : ASHB.0000052633 / BPLAH11075 W/BNo/RefNo : AHC
SIN \LRN : 185492 \ 73460
Specimen : Blood
Ref Doctor : CoC Self



Collected on : 12-OCT-2024 09:45:44 AM Received on : 12-OCT-2024 11:31:20 AM Reported on : 12-OCT-2024 11:35:01 AM

MEDIWHEEL FULL BODY ANNUAL PLUS ABOVE 50 MALE

TEST NAME **RESULT**

BLOOD GROUPING AND TYPING (ABO and Rh)

ABO Group: **O**
Rh (D) Type: **Positive**
Report Status:Final

* END OF REPORT *

CHECKED BY : 725449
725449

Dr. Samir Singh
Consultant Blood Bank

Printed On : 18-OCT-2024 11:28:16 AM