

Dr. S. Venkatesh (MD)
Periodontologist

OUT PATIENT DEPARTMENT



Patient Name	: Mr. POGARU ASWINI KUMAR	UMR No	: VZMU53591
Age/Gender	: 29Years, 2Months/Male	Bill No	: HC502408000688
Mobile	: 9492190320	Bill Dt	: 10-Aug-2
Organisation	:	Visit Dt	: /
		Visit Type	:

BPI	: mmHg
BPd	: mmHg
Weight	: kg
Height	: cms
HR	: /min
TEMP	: F
BMI	: kg/mm

OP RECORD

Informant :

Rx :

I. Initial Assessment :

C/C: Patient complains of bleeding gums.

II. Provisional Diagnosis :

O/E: Stomatitis of teeth.
C-I DC in #6/67

III. Investigations

IV. Treatment

Stain + (lower anterior)
Celt
Bleeding on probing post

Rx plan: Administ oral prophylaxis
Administ Ace fillings

Printed By : E Dhanalakshmi - 020538

Page 1

Printed On : 10-Aug-2024 11:05 AM

#6/67



[Signature]
10/8/24

For Appointments : Mobile No. : 9491759216 (9 AM to 6 PM)

TIRUMALA MEDICOVER HOSPITALS

(A Unit of Sahrudaya Health Care Vizianagaram Pvt. Ltd.)

తిరుమల మెడికవర్ హాస్పిటల్స్

8-24, P.S.R. Complex, Lower Tank Bunk Road,
VIZIANAGARAM - 535 003, ANDHRA PRADESH.

8-24, పి.ఎస్.ఆర్. కాంప్లెక్స్, లోవర్ ట్యాంక్ బండ్ రోడ్,
విజయనగరం-535 003, ఆంధ్రప్రదేశ్.

website : www.tirumalahospitals.com

info@medicoverhospitals.in

Dr. Taraka Ravikiran sv
medicover

OUT PATIENT DEPARTMENT

Tirumala | MEDICOVER
HOSPITALS

Patient Name	: Mr. POGARU ASWINI KUMAR	UMR No	: VZMU53591	Bill Dt	: 10-Aug-2
Age/Gender	: 29Years, 2Months/Male	Bill No	: HC502408000688	Visit Dt.	: /
Mobile	: 9492190320	Visit Type:			
Organisation	:				

BP ^s	: 120	mmHg
BP ^d	: 80	mmHg
Weight	: 68.7	kg
Height	: 171.9	cm
HR	: 78	min
TEMP	: 36.4	F
BMI	: 23.2	kg/mm

OP RECORD

Informant : SpO2 : 99% - pulse: 92

Rx :

I. Initial Assessment :

Routine heart check up.

II. Provisional Diagnosis :

III. Investigations

IV. Treatment

Grade I. Fatty liver.

LVE . 6-8 pus cell $\frac{1}{7}$ plenty of pus cells
①
② 30mls daily
as advised

Ch

Printed By : E Dhanalakshmi - 020538

Page 1

Printed On : 10-Aug-2024 11:05 AM

Dr.K.TARAKA RAVI KIRAN
Regd.No.76191 MBBS,MD
TIRUMALA MEDICOVER HOSPITALS
VIZIANAGARAM

For Appointments : Mobile No. : 9491759216 (9 AM to 6 PM)

TIRUMALA MEDICOVER HOSPITALS

(A Unit of Sahrudaya Health Care Vizianagaram Pvt. Ltd.)

తిరుమల మెడికల్ హాస్పిటల్స్

8-24, P.S.R. Complex, Lower Tank Bunk Road,
VIZIANAGARAM - 535 003, ANDHRA PRADESH.

website : www.tirumalahospitals.com

8-24, పి.ఎస్.ఆర్. కాంప్లెక్స్, లోవర్ ట్యాంక్ బండ్ రోడ్,
విజయనగరం-535 003, ఆంధ్రప్రదేశ్.

info@medicoverhospitals.in

Name	Mr.POGARU.ASWINI KUMAR AGE : 29Y/M	Date	10.08.2024.
Ref by	DR.K.TARAKA RAVI KIRAN	VZMU	53591

X – RAY CHEST PA VIEW

Trachea is central

Bony thorax and soft tissue shadows are normal.


Both lung fields is grossly normal.

Bilateral hilar regions are normal. No e/o. lymphadenopathy.

Bilateral C.P angle is clear.

IMPRESSION:

- **No Significant Abnormality.**


Dr. T.DIVYA
CONSULTANT RADIOLOGIST

తిరుమల మెడికల్ హాస్పిటల్స్

(A UNIT OF SAHRUDAYA HEALTH CARE VIZIANAGARM PVT. LTD.)

LABORATORY REPORT : BIOCHEMISTRY

Name	: Mr. POGARU ASWINI KUMAR	Age /Sex	: 29Y Y(s)/Male
Bill Date	: 10-Aug-2024 10:03 AM	UMR No.	: VZMU53591
Rec. Dt	: 10-Aug-2024 10:58 AM	Bill No.	: MCB50240802508
Rept. Dt	:	Result No	: RZN240804397
Ref By	: Dr. Taraka Ravi Kiran Komanapalli	Sample ID	: MCVZN8008826
Sample Type	: SERUM		

T3,T4 AND TSH

<u>Parameters</u>	<u>Result</u>	<u>Reference Range</u>	<u>Units</u>
T3 ECLIA	1.69	0.8 - 2.0	ng/mL
T4 ECLIA	9.44	5.1 - 14.1	ug/dL
TSH(THYROID STIMULATING HORMONE) ECLIA	1.23	0.270 - 4.20	uIU/mL

*** End Of Report ***

Suggested Clinical Correlation * If necessary, Please discuss

తిరుమల మెడికల్ హాస్పిటల్స్

(A UNIT OF SAHRUDAYA HEALTH CARE VIZIANAGARM PVT. LTD.)



Tirumala

MEDICOVER
HOSPITALS

LABORATORY REPORT : HAEMATOLOGY

Name	: Mr. POGARU ASWINI KUMAR	Age /Sex	: 29Y Y(s)/Male
Bill Date	: 10-Aug-2024 10:03 AM	UMR No.	: VZMU53591
Rec. Dt	: 10-Aug-2024 10:58 AM	Bill No.	: MCB50240802508
Rept. Dt	:	Result No	: RZN240804405
Ref By	: Dr. Taraka Ravi Kiran Komanapalli	Sample ID	: MCVZN8008829
Sample Type	:		

CBP(COMPLETE BLOOD PICTURE)

Parameters	Result	Reference Range	Units
HEMOGLOBIN <i>Photometric</i>	16.1	13.0 - 17.0	gms/dL
R B C COUNT <i>Electrical Impedance</i>	5.55 *	4.5 - 5.5 10 ¹² /L	10 ¹² /L
PCV/HCT <i>Calculated</i>	44.9	40 - 50	%
MCV <i>Calculated</i>	81 *	83 - 101	fl
MCH <i>Calculated</i>	29.0	27 - 32	pg
MCHC <i>Calculated</i>	35.9	31 - 37	g/dL
RDW(cv)	12.8	11.6 - 14.0 %	%
TLC (TOTAL LEUCOCYTE COUNT) <i>Impedance</i>	9.8	4.0 - 10.0	10 ³ /μl
DIFFERENTIAL COUNT			
NEUTROPHILS <i>DHSS/Microscopy</i>	58	40 - 80 %	
LYMPHOCYTES <i>DHSS/Microscopy</i>	32	20 - 40 %	
MONOCYTES <i>DHSS/Microscopy</i>	07	02 - 10 %	

తిరుమల మెడికవర్ హాస్పిటల్స్

(A UNIT OF SAHRUDAYA HEALTH CARE VIZIANAGARM PVT. LTD.)

8-24, P.S.R. Complex, Lower Tank Bund Road, Vizianagaram - 535 003, A.P. Tel : 08922 - 225850 / 223921, Fax : 08922-233558
visit us : www.medicoverhospitals.com

LABORATORY REPORT : HAEMATOLOGY

Name	: Mr. POGARU ASWINI KUMAR	Age /Sex	: 29Y Y(s)/Male
Bill Date	: 10-Aug-2024 10:03 AM	UMR No.	: VZMU53591
Rec. Dt	: 10-Aug-2024 10:58 AM	Bill No.	: MCB50240802508
Rept. Dt	:	Result No	: RZN240804405
Ref By	: Dr. Taraka Ravi Kiran Komanapalli	Sample ID	: MCVZN8008829
Sample Type	:		

EOSINOPHILS <i>DHSS/Microscopy</i>	03	00 - 06 %	
BASOPHILS <i>DHSS/Microscopy</i>	00	00 - 01 %	
PLATELET COUNT <i>Electrical Impedance</i>	229	150 - 400 10 ³ /μL	10 ³ /μL
MPV	7.3 *	7.5 - 11.5 fl	fl

PERIPHERAL SMEAR (Leishman's Stain /Microscopy)

*** End Of Report ***

Suggested Clinical Correlation * If necessary, Please discuss

తిరుమల మెడికల్ హాస్పిటల్స్

(A UNIT OF SAHRUDAYA HEALTH CARE VIZIANAGARM PVT. LTD.)

LABORATORY REPORT : HAEMATOLOGY

Name	: Mr. POGARU ASWINI KUMAR	Age /Sex	: 29Y Y(s)/Male
Bill Date	: 10-Aug-2024 10:03 AM	UMR No.	: VZMU53591
Rec. Dt	: 10-Aug-2024 10:58 AM	Bill No.	: MCB50240802508
Rept. Dt	:	Result No	: RZN240804406
Ref By	: Dr. Taraka Ravi Kiran Komanapalli	Sample ID	: MCVZN8008829
Sample Type	: WHOLE BLOOD		

ESR

<u>Parameters</u>	<u>Result</u>	<u>Reference Range</u>	<u>Units</u>
ESR MODIFIED WESTERGREN'S METHOD	15 *	0 - 10	mm/1st hour

*** End Of Report ***

Suggested Clinical Correlation * If necessary, Please discuss

తిరుమల మెడికల్ హాస్పిటల్స్

(A UNIT OF SAHRUDAYA HEALTH CARE VIZIANAGARM PVT. LTD.)

LABORATORY REPORT : CLINICAL PATHOLOGY

Name	: Mr. POGARU ASWINI KUMAR	Age /Sex	: 29Y Y(s)/Male
Bill Date	: 10-Aug-2024 10:03 AM	UMR No.	: VZMU53591
Rec. Dt	: 10-Aug-2024 10:58 AM	Bill No.	: MCB50240802508
Rept. Dt	:	Result No	: RZN240804404
Ref By	: Dr. Taraka Ravi Kiran Komanapalli	Sample ID	: MCVZN8008828
Sample Type	:		

CUE(COMPLETE URINE EXAMINATION)

<u>Parameters</u>	<u>Result</u>	<u>Reference Range</u>	<u>Units</u>
<u>PHYSICAL EXAMINATION</u>			
COLOUR	YELLOW	PALE YELLOW	
APPEARANCE	CLEAR	CLEAR	
<u>CHEMICAL EXAMINATION</u>			
SPECIFIC GRAVITY <i>Bromthymol blue</i>	1.010	1.000 - 1.030	
PH <i>Bromthymol blue</i>	6.5	5.0 - 8.0	
PROTEIN <i>Tetra-bromophenol blue/Heat coagulation test</i>	TRACES	NIL (<15 mg/dL)	
GLUCOSE <i>Glucose oxidase Peroxidase/Benedict's test</i>	NIL	NIL (<25 mg/dL)	
UROBILINOGEN <i>Diazonium salt</i>	NIL	NIL	
KETONE <i>Sodium nitroprusside/Rothera's test.</i>	NIL	NIL (<5 mg/dL)	
BILIRUBIN <i>Diazonium salt/Fouchets test</i>	NIL	NIL (<0.5 mg/dL)	
NITRITE <i>Sulfanilic acid</i>	NIL	NEGATIVE	

తిరుమల మెడికవర్ హాస్పిటల్స్

(A UNIT OF SAHRUDAYA HEALTH CARE VIZIANAGARM PVT. LTD.)

LABORATORY REPORT : CLINICAL PATHOLOGY

Name	: Mr. POGARU ASWINI KUMAR	Age /Sex	: 29Y Y(s)/Male
Bill Date	: 10-Aug-2024 10:03 AM	UMR No.	: VZMU53591
Rec. Dt	: 10-Aug-2024 10:58 AM	Bill No.	: MCB50240802508
Rept. Dt	:	Result No	: RZN240804404
Ref By	: Dr. Taraka Ravi Kiran Komanapalli	Sample ID	: MCVZN8008828
Sample Type	:		

MICROSCOPIC EXAMINATION

PUS CELLS	6-8	0 - 5 /hpf	
RBC	0-1	0 - 5 /hpf	
EPITHELIAL CELLS	1-2	0 - 5	hpf
CRYSTALS	NIL	NIL	
CASTS	NIL	NIL	

INTERPRETATION

The colour fields of chemicals correspond to the following values:

1. Proteins: neg (negative), 30-99 (+), 100-499 (++) , >500 (+++) mg/dl
2. Ketones: neg. (negative), 5 (Trace), 15-49 (+), 50-149 (++) , >150 (+++) mg/dl
3. Glucose: norm. (normal), 50-149 (+), 150-499 (++) , 500-999 (+++) , >1000 (++++) mg/dl
4. Bilirubin: neg (negative), 1 (+), 3 (++) , 6 (+++) mg/ dl
5. Urobilinogen: norm. (normal), 2 (+), 4 (++) , 8 (+++) , 12 (++++) mg/dl.

*** End Of Report ***

Suggested Clinical Correlation * If necessary, Please discuss

తిరుమల మెడికల్ హాస్పిటల్స్

(A UNIT OF SAHRUDAYA HEALTH CARE VIZIANAGARM PVT. LTD.)

LABORATORY REPORT : BLOOD BANK

Name	: Mr. POGARU ASWINI KUMAR	Age /Sex	: 29Y Y(s)/Male
Bill Date	: 10-Aug-2024 10:03 AM	UMR No.	: VZMU53591
Rec. Dt	: 10-Aug-2024 10:58 AM	Bill No.	: MCB50240802508
Rept. Dt	:	Result No	: RZN240804403
Ref By	: Dr. Taraka Ravi Kiran Komanapalli	Sample ID	: MCVZN8008827
Sample Type	: WHOLE BLOOD		

BLOOD GROUPING AND RH

Parameters	Result	Reference Range	Units
BLOOD GROUP Automated microcolumn gel method	B- VE		
RH TYPE	NEGATIVE		

INTERPRETATION

1. If Rh is Du positive it is best considered as Rh negative as recipient and Rh positive as donor. Proper Cross matching is recommended before transfusion.
2. In case of forward and reverse grouping discrepancy, clinical correlation and repeat sample analysis is recommended.
3. For Infants below 6 months only forward grouping is performed.
4. A sub-grouping is recommended after the age of 6 months.

*** End Of Report ***

Suggested Clinical Correlation * If necessary, Please discuss

తిరుమల మెడికవర్ హాస్పిటల్స్

(A UNIT OF SAHRUDAYA HEALTH CARE VIZIANAGARM PVT. LTD.)

LABORATORY REPORT : BIOCHEMISTRY

Name	: Mr. POGARU ASWINI KUMAR	Age /Sex	: 29Y Y(s)/Male
Bill Date	: 10-Aug-2024 10:03 AM	UMR No.	: VZMU53591
Rec. Dt	: 10-Aug-2024 10:58 AM	Bill No.	: MCB50240802508
Rept. Dt	:	Result No	: RZN240804402
Ref By	: Dr. Taraka Ravi Kiran Komanapalli	Sample ID	: MCVZN8008826
Sample Type	: SERUM		

BUN(BLOOD UREA NITROGEN)

Parameters	Result	Reference Range	Units
BLOOD UREA <i>Urease kinetic</i>	19	16.6 - 48.5	mg/dL
BUN (Blood Urea Nitrogen.)	9		

*** End Of Report ***

Suggested Clinical Correlation * If necessary, Please discuss

తిరుమల మెడికల్ హాస్పిటల్స్

(A UNIT OF SAHRUDAYA HEALTH CARE VIZIANAGARM PVT. LTD.)

LABORATORY REPORT : BIOCHEMISTRY

Name	: Mr. POGARU ASWINI KUMAR	Age /Sex	: 29Y Y(s)/Male
Bill Date	: 10-Aug-2024 10:03 AM	UMR No.	: VZMU53591
Rec. Dt	: 10-Aug-2024 10:58 AM	Bill No.	: MCB50240802508
Rept. Dt	:	Result No	: RZN240804394
Ref By	: Dr. Taraka Ravi Kiran Komanapalli	Sample ID	: MCVZN8008825
Sample Type	: PLASMA		

FBS (FASTING BLOOD GLUCOSE WITH URINE GLUCOSE)

Parameters	Result	Reference Range	Units
FASTING BLOOD GLUCOSE <i>Hexokinase</i>	83	Normal Range : 70 - 99 Impaired Glucose tolerance : 100 -125 Diabetes Mellitus : >=126	mg/dL

*** End Of Report ***

Suggested Clinical Correlation * If necessary, Please discuss

తిరుమల మెడికల్ హాస్పిటల్స్

(A UNIT OF SAHRUDAYA HEALTH CARE VIZIANAGARM PVT. LTD.)

LABORATORY REPORT : BIOCHEMISTRY

Name	: Mr. POGARU ASWINI KUMAR	Age /Sex	: 29Y Y(s)/Male
Bill Date	: 10-Aug-2024 10:03 AM	UMR No.	: VZMU53591
Rec. Dt	: 10-Aug-2024 10:58 AM	Bill No.	: MCB50240802508
Rept. Dt	:	Result No	: RZN240804396
Ref By	: Dr. Taraka Ravi Kiran Komanapalli	Sample ID	: MCVZN8008826
Sample Type	: SERUM		

LFT(LIVER FUNCTION TEST)

Parameters	Result	Reference Range	Units
TOTAL BILIRUBIN <i>DIAZO</i>	0.4	<1.2	mg/dL
DIRECT BILIRUBIN <i>DIAZO</i>	0.1	<=0.20	mg/dL
INDIRECT BILIRUBIN <i>Calculated</i>	0.3	<=1.0	mg/dL
SGPT (ALT) <i>UV without P5P</i>	22	<=41	U/L
SGOT (AST) <i>UV without P5P</i>	20	<=40	U/L
ALKALINE PHOSPHATASE (ALP) <i>[PNI]?, AMP Buffer - IFCC Ref.</i>	85	40-129 U/L	U/L
TOTAL PROTEINS <i>Biuret method</i>	8.0	6.0 - 8.0 g/dL	g/dL
SERUM ALBUMIN <i>Bromcresol Green (BCG)</i>	5.0	3.5 - 5.2 g/dL	g/dL
GLOBULINS <i>Calculated</i>	3.0	2.5 - 3.5 g/dL	g/dL
A/G RATIO <i>Calculation</i>	1.7	1.2 - 2.5	

*** End Of Report ***

Suggested Clinical Correlation * If necessary, Please discuss

తిరుమల మెడికవర్ హాస్పిటల్స్

(A UNIT OF SAHRUDAYA HEALTH CARE VIZIANAGARM PVT. LTD.)

LABORATORY REPORT : BIOCHEMISTRY

Name	: Mr. POGARU ASWINI KUMAR	Age /Sex	: 29Y Y(s)/Male
Bill Date	: 10-Aug-2024 10:03 AM	UMR No.	: VZMU53591
Rec. Dt	: 10-Aug-2024 10:58 AM	Bill No.	: MCB50240802508
Rept. Dt	:	Result No	: RZN240804398
Ref By	: Dr. Taraka Ravi Kiran Komanapalli	Sample ID	: MCVZN8008826
Sample Type	: SERUM		

BUN / CREATININE RATIO

<u>Parameters</u>	<u>Result</u>	<u>Reference Range</u>	<u>Units</u>
BUN / CREATININE RATIO CALCULATED	10	10-20 mg/dL	mg/dL

*** End Of Report ***

Suggested Clinical Correlation * If necessary, Please discuss

తిరుమల మెడికల్ హాస్పిటల్స్

(A UNIT OF SAHRUDAYA HEALTH CARE VIZIANAGARM PVT. LTD.)

LABORATORY REPORT : BIOCHEMISTRY

Name	: Mr. POGARU ASWINI KUMAR	Age /Sex	: 29Y Y(s)/Male
Bill Date	: 10-Aug-2024 10:03 AM	UMR No.	: VZMU53591
Rec. Dt	: 10-Aug-2024 10:58 AM	Bill No.	: MCB50240802508
Rept. Dt	:	Result No	: RZN240804401
Ref By	: Dr. Taraka Ravi Kiran Komanapalli	Sample ID	: MCVZN8008826
Sample Type	: SERUM		

HBA1C (GLYCOSYLATED HAEMOGLOBIN)

Parameters	Result	Reference Range	Units
HBA1C IPLC	5.2	" Normal : < 5.7% Pre diabetic : 5.7 % - 6.5 % Diabetic : > 6.5 %	
MPG (Mean Plasma Glucose) Derived from HBA1c value	103	" Excellent Control : 90 - 120 mg/dl Good Control : 121 - 150 "	mg/dl

*** End Of Report ***

Suggested Clinical Correlation * If necessary, Please discuss

తిరుమల మెడికల్ హాస్పిటల్స్

(A UNIT OF SAHRUDAYA HEALTH CARE VIZIANAGARM PVT. LTD.)

LABORATORY REPORT : BIOCHEMISTRY

Name	: Mr. POGARU ASWINI KUMAR	Age /Sex	: 29Y Y(s)/Male
Bill Date	: 10-Aug-2024 10:03 AM	UMR No.	: VZMU53591
Rec. Dt	: 10-Aug-2024 10:58 AM	Bill No.	: MCB50240802508
Rept. Dt	:	Result No	: RZN240804400
Ref By	: Dr. Taraka Ravi Kiran Komanapalli	Sample ID	: MCVZN8008826
Sample Type	: SERUM		

LIPID PROFILE

Parameters	Result	Reference Range	Units
TOTAL CHOLESTEROL <i>Enzymatic colorimetric</i>	142	Desirable : : < 200 mg/dL Borderline High : : 200 - 239 mg/dL High risk : > 240 mg/dL	mg/dL
HDL CHOLESTEROL <i>Homogeneous enzymatic colorimetric</i>	33	Low : : < 40 mg/dL High : : > 60 mg/dL	mg/dL
LDL CHOLESTEROL <i>Direct-Enzymatic colorimetric</i>	81	Very High : - > 190 mg/dL Optimal : - < 100 mg/dL Near Optimal : 100 - 129 mg/dL High : 160 - 189 mg/dL Borderline High:130-159 mg/dl	mg/dL
VLDL <i>Calculation</i>	28	2 - 30 mg/dL	mg/dL
SERUM TRYGLYCERIDES <i>Enzymatic colorimetric</i>	140	< 150 mg/dL Borderline High : 150 - 199 mg/dL High : 200 - 499 mg/dL	mg/dL

*** End Of Report ***

Suggested Clinical Correlation * If necessary, Please discuss

తిరుమల మెడికల్ హాస్పిటల్స్

(A UNIT OF SAHRUDAYA HEALTH CARE VIZIANAGARM PVT. LTD.)

LABORATORY REPORT : BIOCHEMISTRY

Name	: Mr. POGARU ASWINI KUMAR	Age /Sex	: 29Y Y(s)/Male
Bill Date	: 10-Aug-2024 10:03 AM	UMR No.	: VZMU53591
Rec. Dt	: 10-Aug-2024 10:58 AM	Bill No.	: MCB50240802508
Rept. Dt	:	Result No	: RZN240804399
Ref By	: Dr. Taraka Ravi Kiran Komanapalli	Sample ID	: MCVZN8008826
Sample Type	: SERUM		

SERUM CREATININE

Parameters	Result	Reference Range	Units
CREATININE <i>Jaffe</i>	0.9	0.7 - 1.2	mg/dL

*** End Of Report ***

Suggested Clinical Correlation * If necessary, Please discuss

తిరుమల మెడికల్ హాస్పిటల్స్

(A UNIT OF SAHRUDAYA HEALTH CARE VIZIANAGARM PVT. LTD.)

LABORATORY REPORT : BIOCHEMISTRY

Name	: Mr. POGARU ASWINI KUMAR	Age /Sex	: 29Y Y(s)/Male
Bill Date	: 10-Aug-2024 10:03 AM	UMR No.	: VZMU53591
Rec. Dt	: 10-Aug-2024 10:58 AM	Bill No.	: MCB50240802508
Rep. Dt	:	Result No	: RZN240804395
Ref By	: Dr. Taraka Ravi Kiran Komanapalli	Sample ID	: MCVZN8008826
Sample Type	: SERUM		

SERUM URIC ACID

Parameters	Result	Reference Range	Units
SERUM URIC ACID <i>uricas</i>	6.3	3.4-7.0	mg/dL

*** End Of Report ***

Suggested Clinical Correlation * If necessary, Please discuss

తిరుమల మెడికల్ హాస్పిటల్స్

(A UNIT OF SAHRUDAYA HEALTH CARE VIZIANAGARM PVT. LTD.)



SWAMY EYE HOSPITAL


Date: 10/08/2024

Place: Vizianagaram

EYE CHECK UP CERTIFICATE

This is to certify that I have examined **Mr. POGARU ASWINI KUMAR**, Aged: 29 yrs, male. In the outpatient card No: SEH/MC2 dated 10/08/2024 and the following are the findings.

Distance Vision in the right eye : 6/6
Distance Vision in the left eye : 6/6
NEAR VISION (BOTH EYE) : N6
Color vision : NORMAL
B.S.V : NORMAL
Anterior Segment
(Conjunctiva ,Cornea and Pupil) : NORMAL
Fundus : NORMAL
Fit for / unit : EYE
Date of issue : 10/08/2024
Diagnosis : NORMAL


Dr. M. Kumara Swamy
Dr. M. KUMARA SWAMY, MS; DO
Regd.No. 14323
SWAMY EYE HOSPITAL
Door No. 8-5-32, Balaji Nagar
Thotapalem, Vizianagaram-535002

Regd No. 18/DRA/VZM/09

Regd No. 281/DRA/DM & HO/VZM/19

Putchalaveedhi, Near Old Bus Stand,
VIZIANAGARAM - 535 001. ☎ : (08922) 225722

New Branch : Behind INOX Multiplex, Opp. RTC Complex,
VIZIANAGARAM - 535 003. ☎ : (08922) 223322

☉ Email : swamyeyehospital@gmail.com

☉ website : www.swamyeyehospital.com



SWAMY EYE HOSPITAL

Super Speciality NABH Accredited Eye Hospital

Dr. G.V. Prasad

M.D. Ophthalmology, (AIIMS)

Dr. Prathima .M

M.B.B.S., DNB, FAICO (Retina) FAIOL

Dr. M. Ravali

M.S. Ophthalmology, MD General Medicine Gold Medalist



Dr. M. Kumara Swamy

M.S. Ophthalmology

Age - 29

Pogaru Aswini Kumar

ARC -0.25 / -0.50 + 87
-0.50 / -0.25 + 27°

NCT \angle 10
9

dry metabolism

GM 3 use
10%

mal

cataract

12/12
12/12

fundus WNL
(conditata)

ecoleau eld BE
25/d - (1)

2

Rate 71 Sinus rhythm.....normal P axis, V-rate 50- 99
 . Baseline wander in lead(s) V6

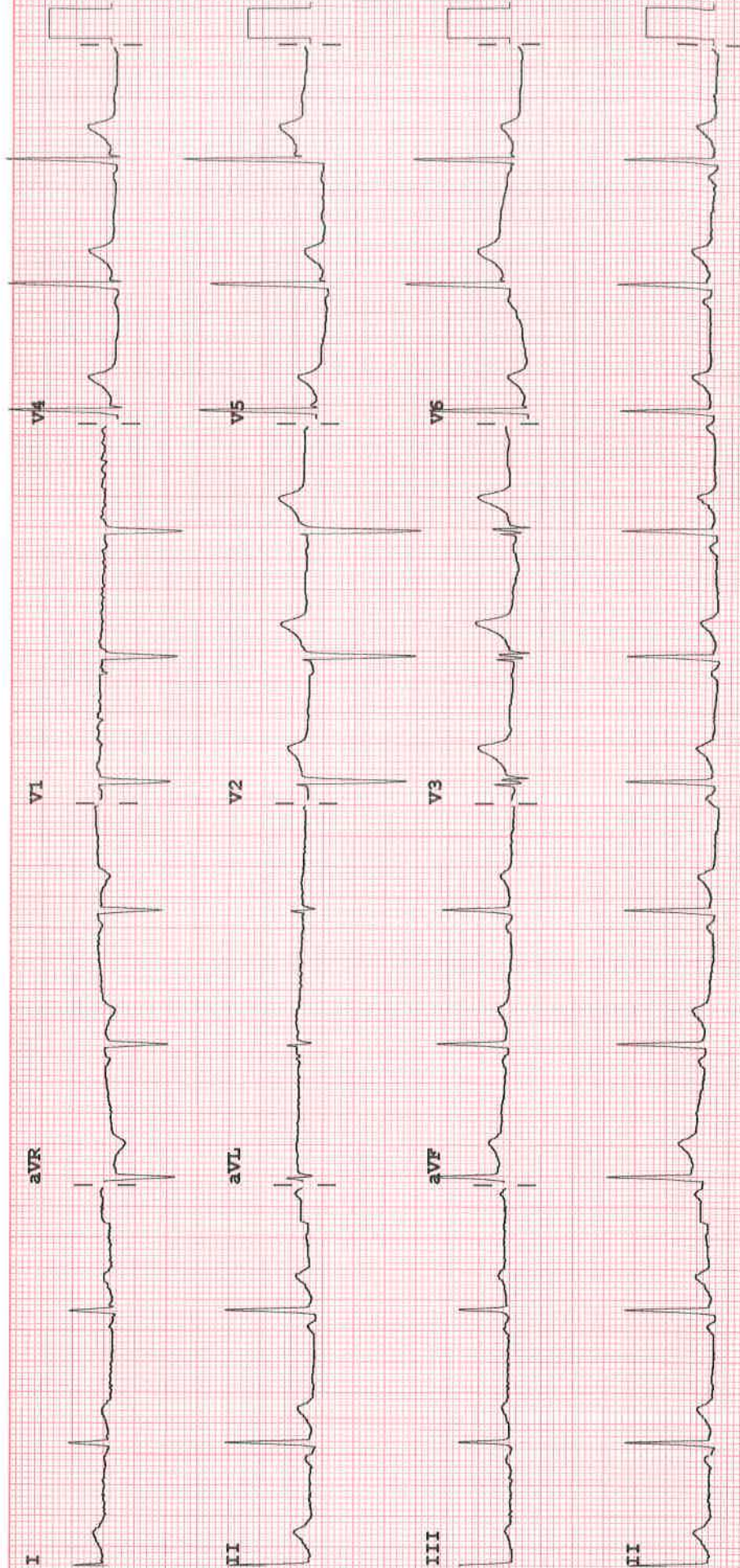
PR 129
 QRS 69
 QT 333
 QTc 362

--AXIS--
 P 62
 QRS 59
 T 53

12 Lead; Standard Placement

- NORMAL ECG -

Unconfirmed Diagnosis



Name	Mr.P.ASWINI KUMAR	29Y/M	Date	10.08.2024
Ref by	DR.K.TARAKA RAVI KIRAN	VZMU	53591	

ULTRA SOUND ABDOMEN

LIVER : Normal in size and increased echotexture. Smooth contours noted. No focal parenchymal lesion noted. Intrahepatic biliary tree and venous radicles are normal.

GALL BLADDER : Partially distended with a normal wall thickness. No calculi noted within.

PANCREAS : Head and body of pancreas are normal in size and echotexture. Rest obscured by bowel gas shadow.

SPLEEN : Normal in size and echotexture. Splenic vessels are normal. No focal lesions.

RIGHT KIDNEY : Normal in size, position and echogenicity. Cortical thickness and corticomedullary differentiation are normal. No hydronephrosis or calculi noted.

LEFT KIDNEY : Normal in size, position and echogenicity. Cortical thickness and corticomedullary differentiation are normal. No hydronephrosis or calculi noted.

URINARY BLADDER : Partially distended, normal in contour, capacity and wall thickness. No vesical calculi noted.

PROSTATE : It is normal in size and homogenous in echotexture.

IMPRESSION :

- **Grade-I Fatty liver.**



Dr.T.DIVYA
Radiologist.

తిరుమల మెడికల్ హాస్పిటల్స్

(A UNIT OF SAHRUDAYA HEALTH CARE VIZIANAGARM PVT. LTD.)



Tirumala MEDICOVER
HOSPITALS

Patient ID: VZMU53591

Patient Name: Mr. POGARU ASWINI

Age: 029Y

Sex: M

Accession Number: VZN240000004159

Modality: US

Referring Physician: Dr. Taraka Ravi Kiran Komanapalli

Study: 2D ECHO WITH COLOUR DOPPLER


Study Date: 10-Aug-2024

MITRAL VALVE : NORMAL
AORTIC VALVE : NORMAL
TRICUSPID VALVE : NORMAL
PULMONARY VALVE : NORMAL
RIGHT ATRIUM : NORMAL
RIGHT VENTRICLE : NORMAL
LEFT ATRIUM : NORMAL
LEFT VENTRICLE : NO LV RWMA
IVSD : 0.8 CM
LVPWD : 0.7 CM
LVDD : 4.1 CM
LVDS : 2.2 CM
LV EF : 60%
IAS : INTACT
IVS : INTACT
AORTA : NORMAL
PULMONARY ARTERY : NORMAL
PULMONARY VEINS : NORMAL
PERICARDIUM : NORMAL
SVC/IVC/CS : NORMAL
MITRAL FLOW : E>A
AORTIC FLOW : NORMAL
TRCUSPID FLOW : NORMAL

తిరుమల మెడికల్ హాస్పిటల్స్

(A UNIT OF SAHRUDAYA HEALTH CARE VIZIANAGARM PVT. LTD.)

CONCLUSION : NORMAL SIZED CARDIAC CHAMBERS
NO LV RWMA
NORMAL LV FUNCTION
NORMAL LV FILLING PATTERN
NO MR/AR/TR
NO CLOT/NO P.E
IVC-NORMAL


DR.A.SARAT KUMAR PATRA MD.DM
CONSULTANT CARDIOLOGIST

తిరుమల మెడికల్ హాస్పిటల్స్

(A UNIT OF SAHRUDAYA HEALTH CARE VIZIANAGARM PVT. LTD.)