

Patient MRN : 20110000014312
Patient Name : Mr Venkanna Boini
Sex/Age : Male, 36y 5m
Address : 5-46, TELANGANA, Tungaturthi, Nalgonda, Telangana, India, 508280
Visit Number : OP-001
Consultation Type : OP, New Visit
Mobile Number : 7893733331

Date :
Department : FAMILY MEDICINE
Consultant : Dr. Priya S
Ref. Hospital :
Ref. Doctor :
Sponsor Name : ARCOFEMI HEALTHCARE LIMITED

Vitals
BP (mmHg) : 130/78 mmHg
Weight (cm) : 167 cm
Respiratory Rate (brpm) :
Heart Rate (bpm) : 86 b/m
Weight (kg) : 69.8 kg
Fall Score :
Temp (*F) :
BMI :
Pain Score :

CHIEF COMPLAINTS AND HPI

GENERAL EXAMINATION

Allergies : Known/Unknown
Body Habitus : Cachectic/ Thin Built/ Average Built/ Obese/ Normal
Pertinent Family History : Negative/ Unknown
Psychological Assessment : Normal/Any Psychological Problem

SYSTEMIC EXAMINATION

NUTRITIONAL ASSESSMENT

INVESTIGATIONS

TREATMENT SUGGESTED

REVIEW ON

Generated By : Vimala M(300235)

Generated On : 14/01/2023 09:02 AM

One free consultation with the same doctor within next 6 days

SPO2 : 99%
No Complaints.
No known comorbidities.

UGU Abd => Gr 1 Fatty lines.
ⓐ Renal Calculus
ⓑ Renal simple cyst.

TMT - neg.

EKG - NSR.

Lab reports - awaited
Chest xray - normal.

8.Pi
Narayana Multispeciality

Eye check up done at Lenskart. #d. block
Jayanagar.

| | | |
|-----------|----------|----------|
| | <u>S</u> | <u>C</u> |
| Right eye | -0.25 | -0.5 |
| Left eye | 0 | -0.5 |

12/2022
HDFC BANK
D 12/2022
HDFC BANK
D 12/2022
HDFC BANK

NAME
4 JAN 2023 PM 01:01
NO. 3482
SN: 4665739

REF. DATA
VD: 12.00 CYL: (-)
<R> S C A
- 0.25 - 0.25 10
- 0.25 - 0.75 5
- 0.25 - 0.50 5
- 0.25 - 0.50 5
S. E. - 0.50
<L> S C A
- 0.00 - 0.50 155
- 0.00 - 0.50 150
- 0.00 - 0.25 145
- 0.00 - 0.50 150
S. E. - 0.25

S. Puri

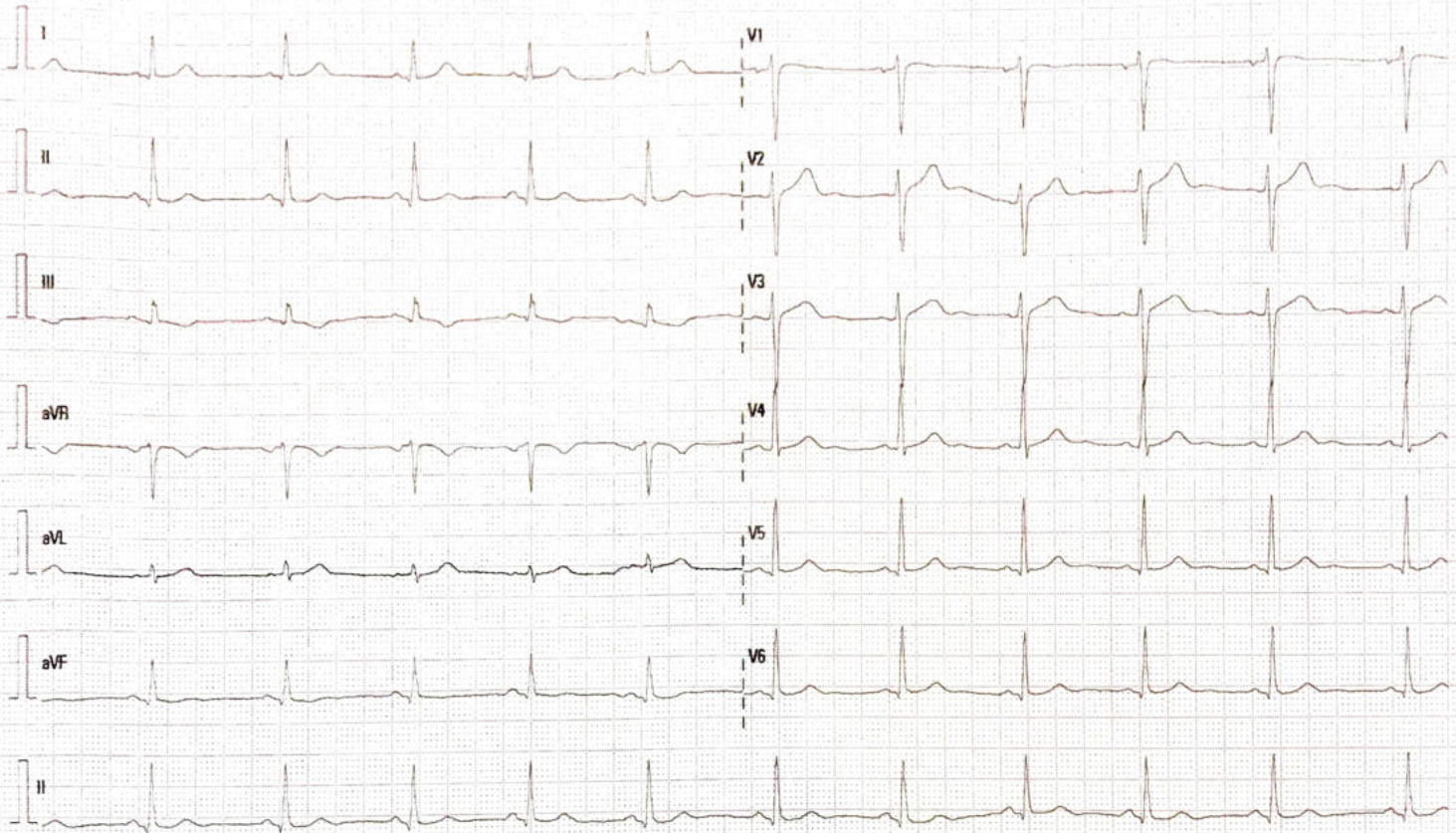PD: 65.5
TOPCON

ID: 2011-14132
Name: MR VENKANNA BOINI
Age: 36 Years
Gender: Male

14.01.2023 09:49:10 AM

| | |
|-----------------|-------------|
| Vent. Rate | 67 bpm |
| PR Interval | 132 ms |
| QRS Duration | 84 ms |
| QT/QTc Interval | 392/404 ms |
| P/QRS/T Axes | 60/51/0 deg |

QTc:Hodges



Patient Name : Mr.Venkanna Boini

Patient ID : 20110000014312

Age : 36Years

Sex : Male

Referring Doctor : EHP

Date : 14.01.2023

ULTRASOUND ABDOMEN AND PELVIS

FINDINGS:

Liver is normal in size and shows **diffuse increased** echopattern. No intra or extra hepatic biliary duct dilatation. No focal lesions.

Portal vein is normal in size, course and caliber. **CBD** is not dilated.

Gall bladder is normal without evidence of calculi, wall thickening or pericholecystic fluid.

Pancreas to the extent visualized, appears normal in size, contour and echogenicity.

Spleen is normal in size, shape, contour and echogenicity. No evidence of mass or focal lesions.

Right Kidney is normal in size (measures 9.1cm in length & 1.5cm in parenchymal thickness), position, shape and echopattern. Corticomedullary differentiation is maintained. No evidence of calculi or hydronephrosis.

Left Kidney is normal in size (measures 9.5cm in length & 1.6cm in parenchymal thickness), position, shape and echopattern. Corticomedullary differentiation is maintained. No evidence of hydronephrosis. **Shows a simple cyst measuring 2.1x1.7cm in the upper pole . Shows a calculus 3-4mm in the lower pole .**

Retroperitoneum – Obscured by bowel gas.

Urinary Bladder is well distended. Wall thickness is normal. No evidence of calculi, mass or mural lesion.

Prostate is normal in echopattern and normal in size, measures 3.0x3.6x3.0cm, Volume - 14cc.

Fluid - There is no ascites or pleural effusion.

IMPRESSION:

- **Grade I fatty Liver .**
- **Left Renal Simple cyst .**
- **Left Renal calculus.**



Dr B S Ramkumar 35772
Consultant Radiologist

Disclaimer:

Note: Investigations have their limitations. Solitary pathological/Radiological and other investigations never confirm the final diagnosis. They only help in diagnosing the disease in correlation to clinical symptoms and other related tests. Please interpret accordingly. This Report is not for Medico - Legal Purposes.



Narayana Multispeciality Clinic

17/1, 30th Cross, 8th 'B' Main Road, 4th Block, Jayanagar, Bangalore - 560 011

Clinic No. : 8884000991, 9513919615, Pharmacy No. : 9513919615

E-mail: info.jayanagar@narayanahealth.org, web : www.narayanahealth.org

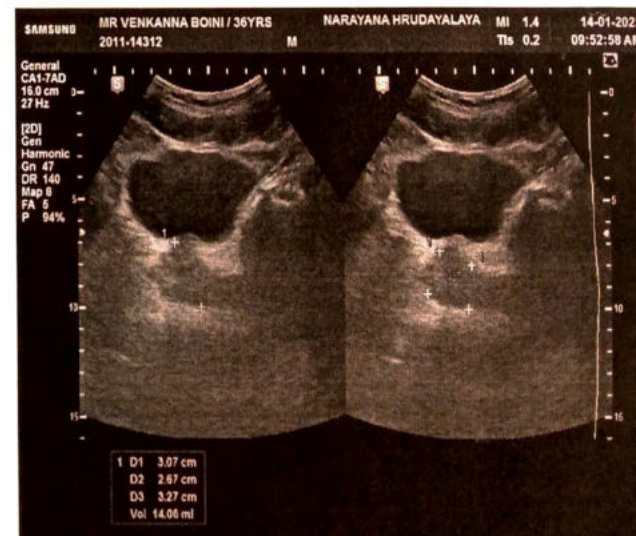
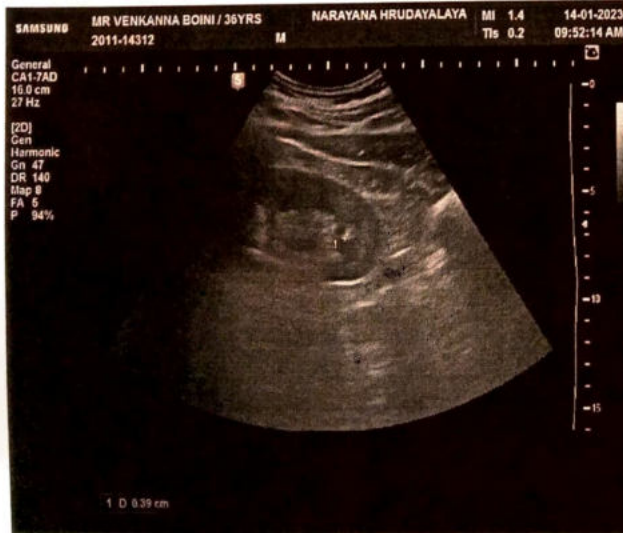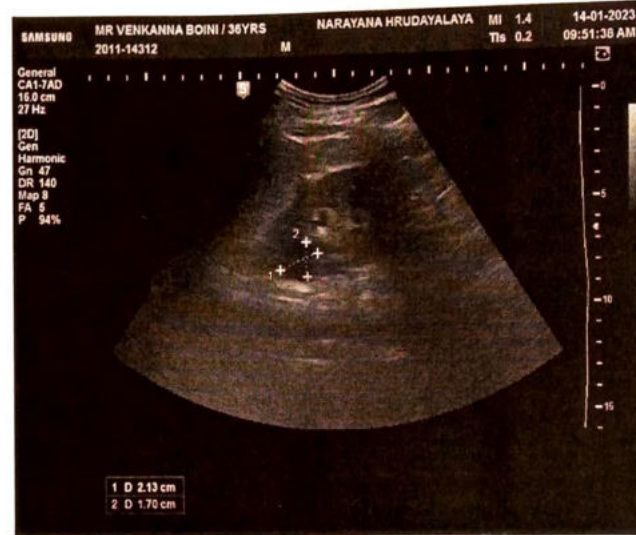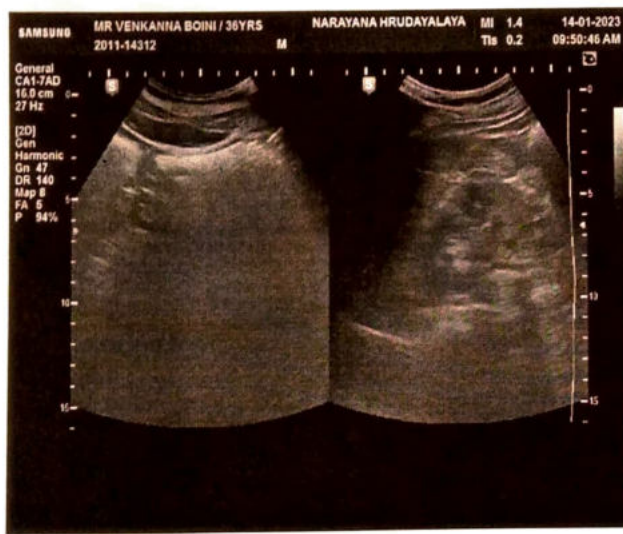
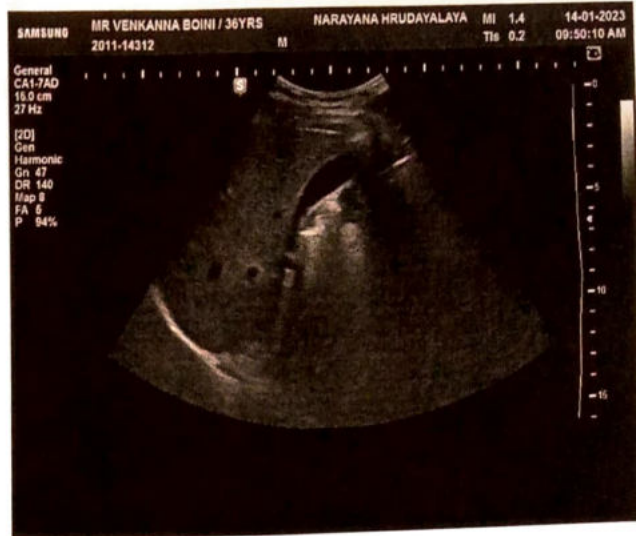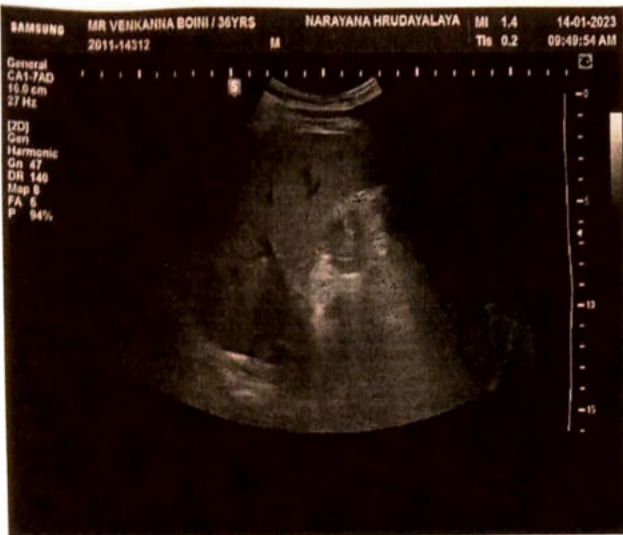Exam

Name
Birth Date
Gender

2011-14312
MR VENKANNA BOINI / 36YRS
Male

Accession #
Exam Date
Description
Operator

14-01-2023



Narayana Multispeciality Clinic
JAYANAGAR
BANGALORE

Station
Telephone:

EXERCISE STRESS TEST REPORT

Patient Name: MR VENKANNA BOINI,
Patient ID: 2011-14312
Height: 167 cm
Weight: 69 kg

DOB: 29.07.1986
Age: 36yrs
Gender: Male
Race:

Study Date: 14.01.2023
Test Type: Treadmill Stress Test
Protocol: BRUCE

Referring Physician: EHP
Attending Physician: DR PRIYA SUBBURAJ
Technician: MS GULSUM JAMEEL FATHIMA

Medications:
--

Medical History:
--

Reason for Exercise Test:
Screening for CAD

Exercise Test Summary

| Phase Name | Stage Name | Time in Stage | Speed (mph) | Grade (%) | HR (bpm) | BP (mmHg) | Comment |
|------------|------------|---------------|-------------|-----------|----------|-----------|---------|
| PRETEST | SUPINE | 01:44 | 1.20 | 0.00 | 78 | 130/78 | |
| EXERCISE | STAGE 1 | 03:00 | 1.70 | 10.00 | 120 | 136/78 | |
| | STAGE 2 | 03:00 | 2.50 | 12.00 | 142 | 140/80 | |
| | STAGE 3 | 01:25 | 3.40 | 14.00 | 166 | 140/80 | |
| RECOVERY | | 05:04 | 0.00 | 0.00 | 109 | 130/78 | |

The patient exercised according to the BRUCE for 7:24 min:s, achieving a work level of Max. METS: 9.10. The resting heart rate of 83 bpm rose to a maximal heart rate of 166 bpm. This value represents 90 % of the maximal, age-predicted heart rate. The resting blood pressure of 130/78 mmHg, rose to a maximum blood pressure of 160/80 mmHg. The exercise test was stopped due to Target heart rate achieved.

Interpretation

--

Conclusions

GOOD EFFORT TOLERANCE
NORMAL HR AND BP RESPONSE
NO ANGINA OR ARRHYTHMIAS
NO SIGNIFICANT ST-T CHANGES NOTED
IMP:STRESS TEST IS NEGATIVE FOR INDUCIBLE ISCHEMIA

Physician

S. Prinja


Technician

75 bpm
130/78 mmHg

Linked Medians
PRETEST
SUPINE
00:29

BRUCE
0.0 mph
0.0 %

Lead
ST Level (mV)
ST Slope (mV/s)



II
Raw Data

*III
0.00
-0.29

*II
0.02
0.24

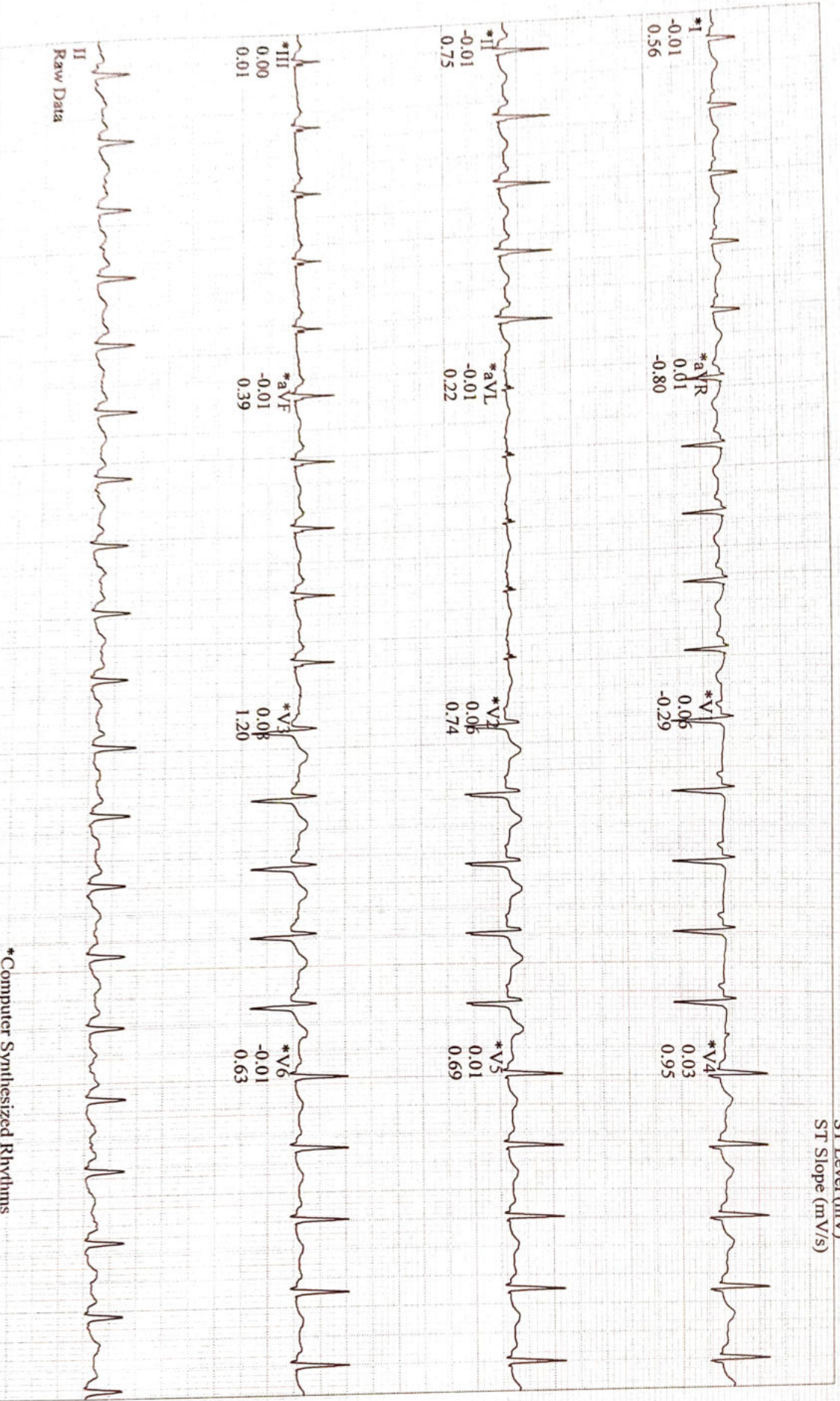
*Computer Synthesized Rhythms

118 bpm
136/78 mmHg

EXERCISE
STAGE 1
02:50

BRUCE
1.7 mph
10.0%

Lead
ST Level (mV)
ST Slope (mV/s)



Raw Data

*Computer Synthesized Rhythms

SR VENKANA BOINI,
Patient ID 2011-14312
14.01.2023
11.53:56

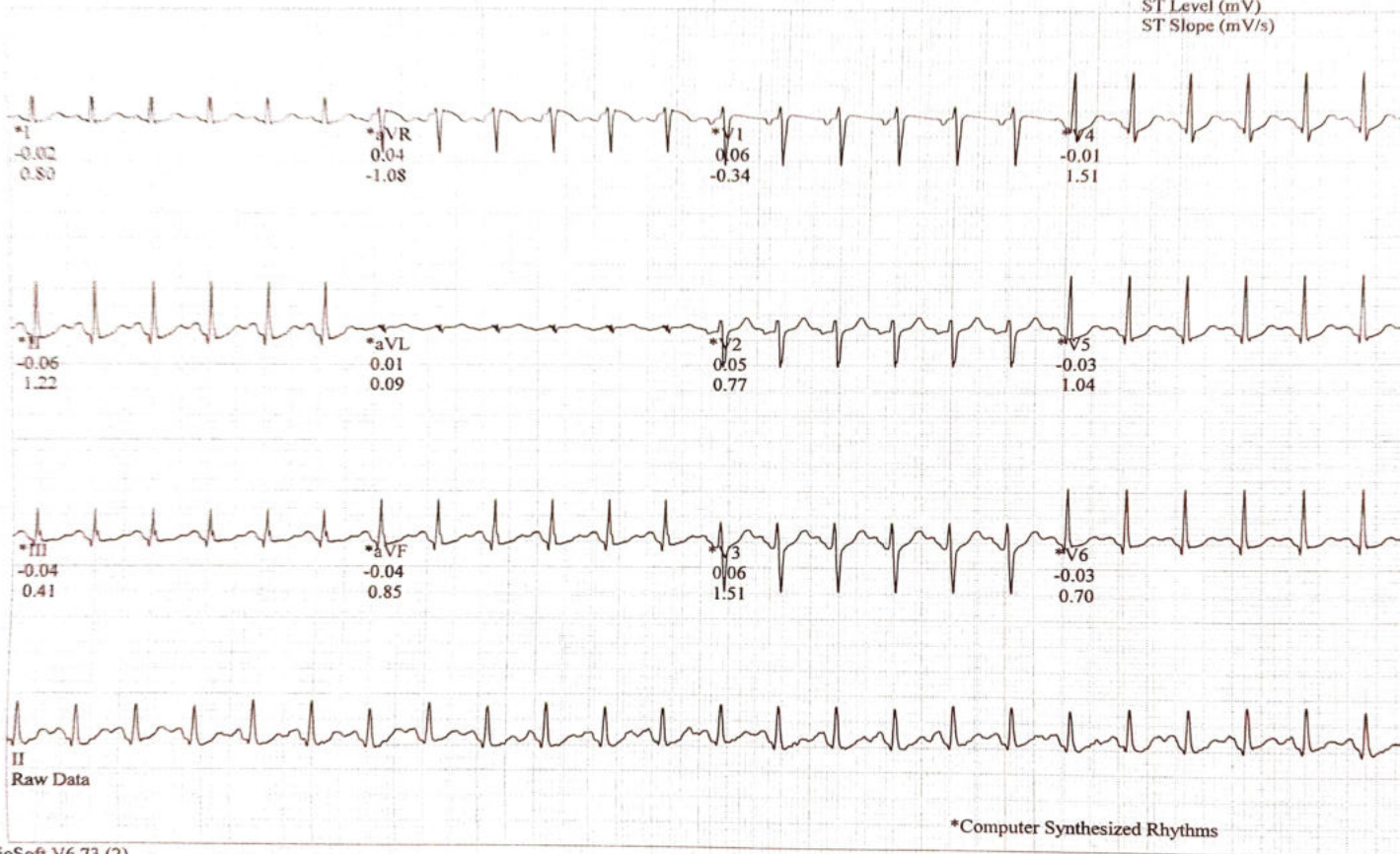
144 bpm
140/80 mmHg

Linked Medians
EXERCISE
STAGE 2
05:50

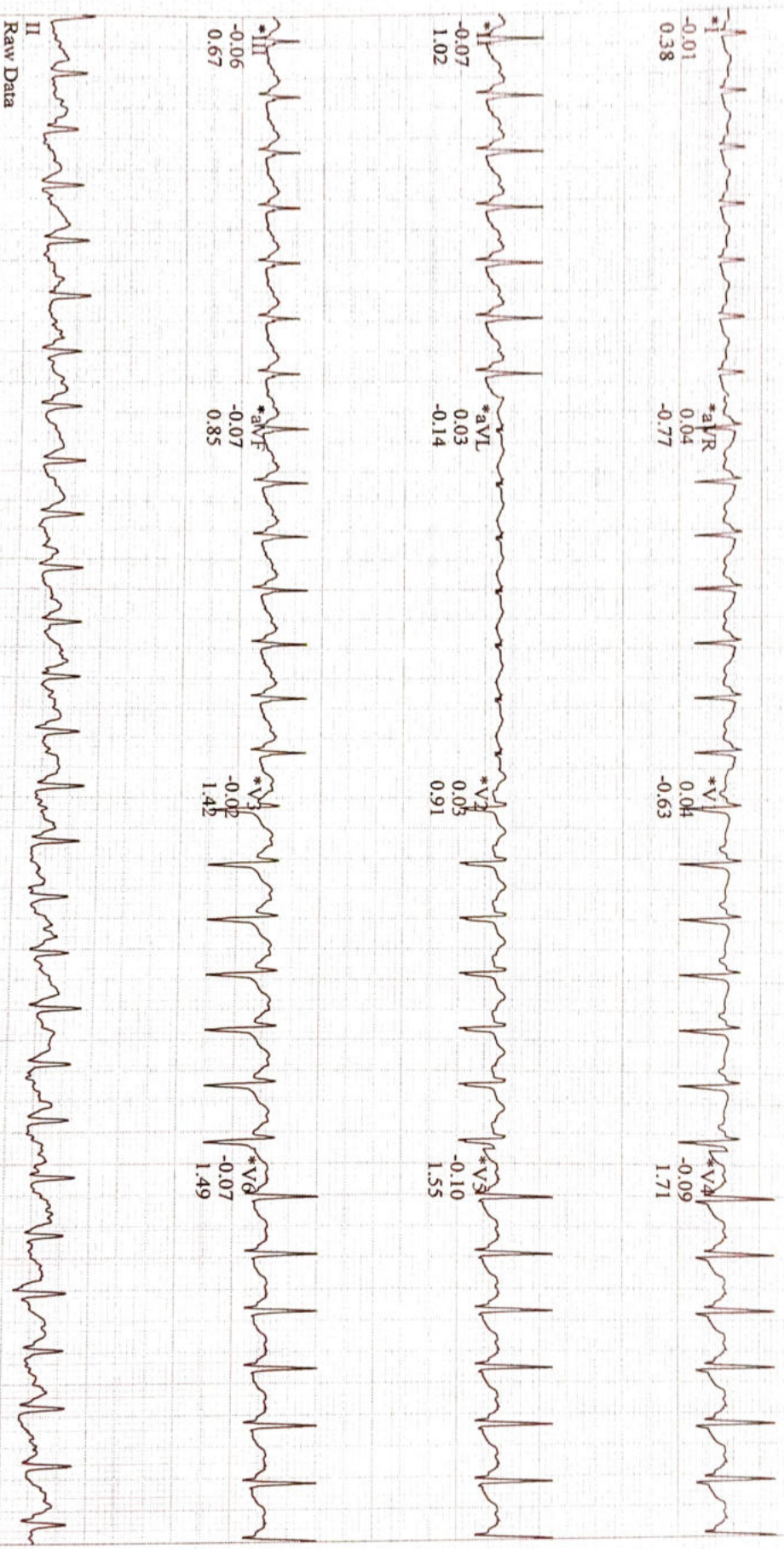
BRUCE
2.5 mph
12.0 %

Narayana Multispeciality Clinic

Lead
ST Level (mV)
ST Slope (mV/s)



Lead
 ST Level (mV)
 ST Slope (mV/s)



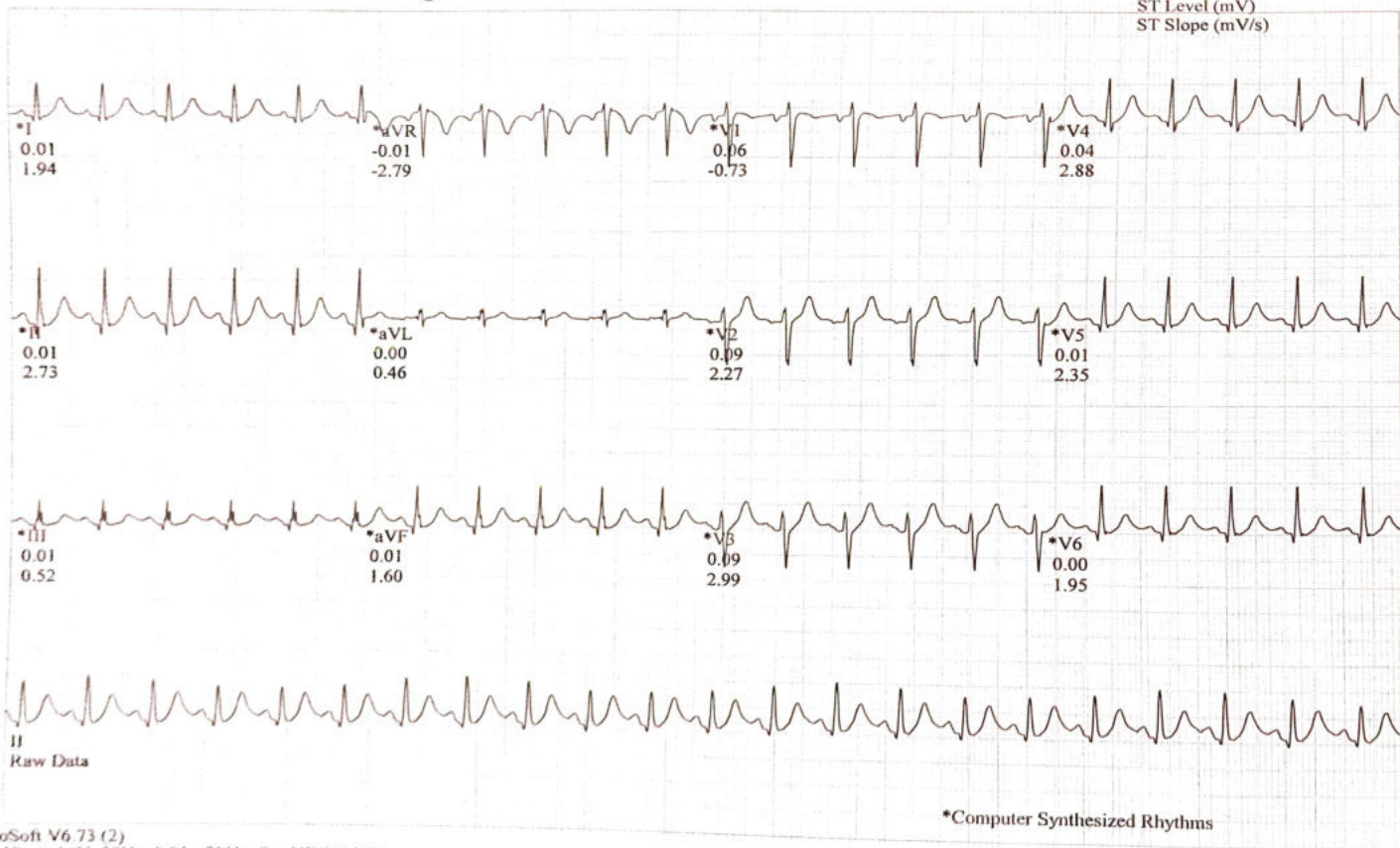
*Computer Synthesized Rhythms

131 bpm
150/80mmHg.

Linked Medians
RECOVERY
#1
01:00

BRUCE
0.0 mph
0.0 %

Lead
ST Level (mV)
ST Slope (mV/s)



DEVENKANA BOINI,
Patient ID: 2011-14312
14-01-2025
11:58:30

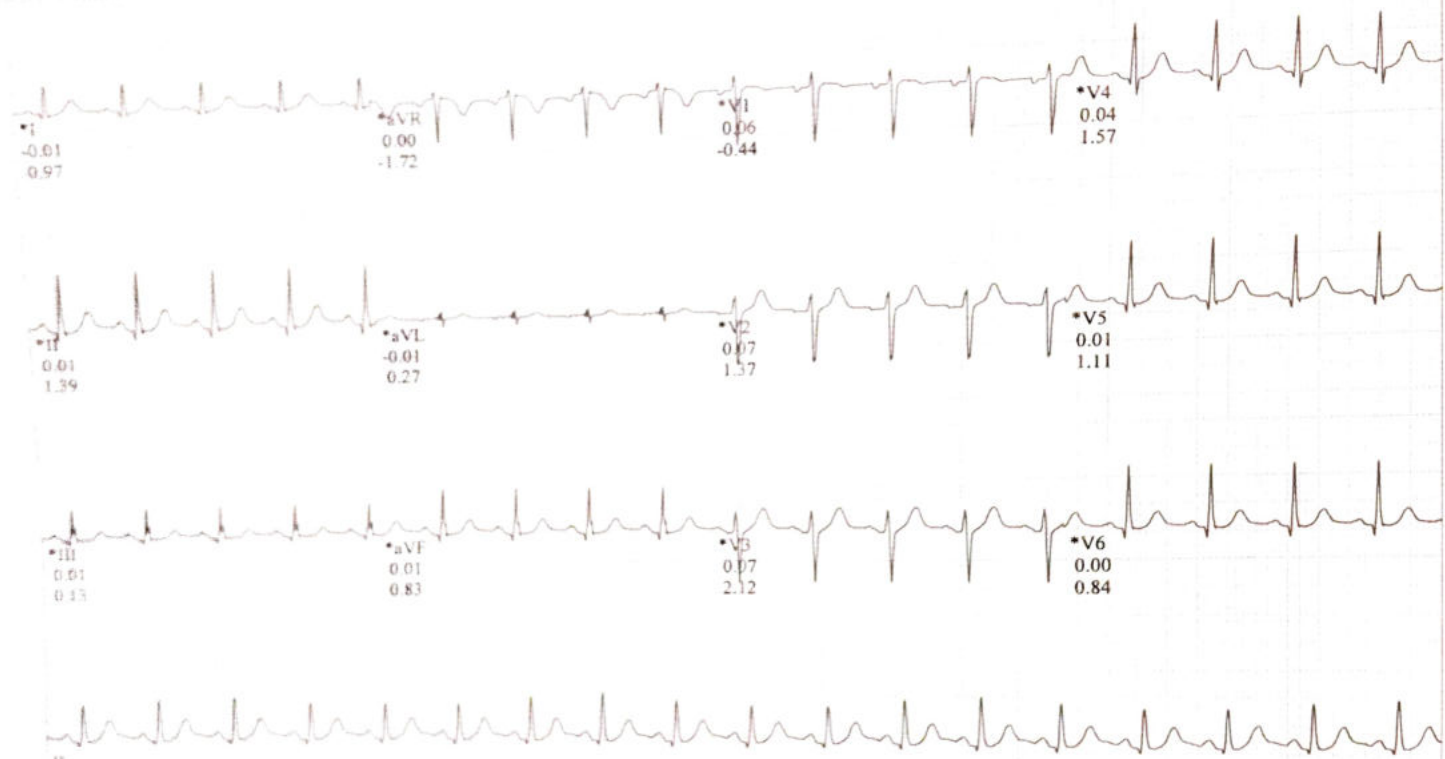Linked Medians

109 bpm
140/80 mmHg

RECOVERY
#1
03:00

BRUCE
0.0 mph
0.0 %

Lead
ST Level (mV)
ST Slope (mV/s)



II
Raw Data

*Computer Synthesized Rhythms

VENKATNA BOINI,
ID 2011-14312
11/01/2023
12:00:50

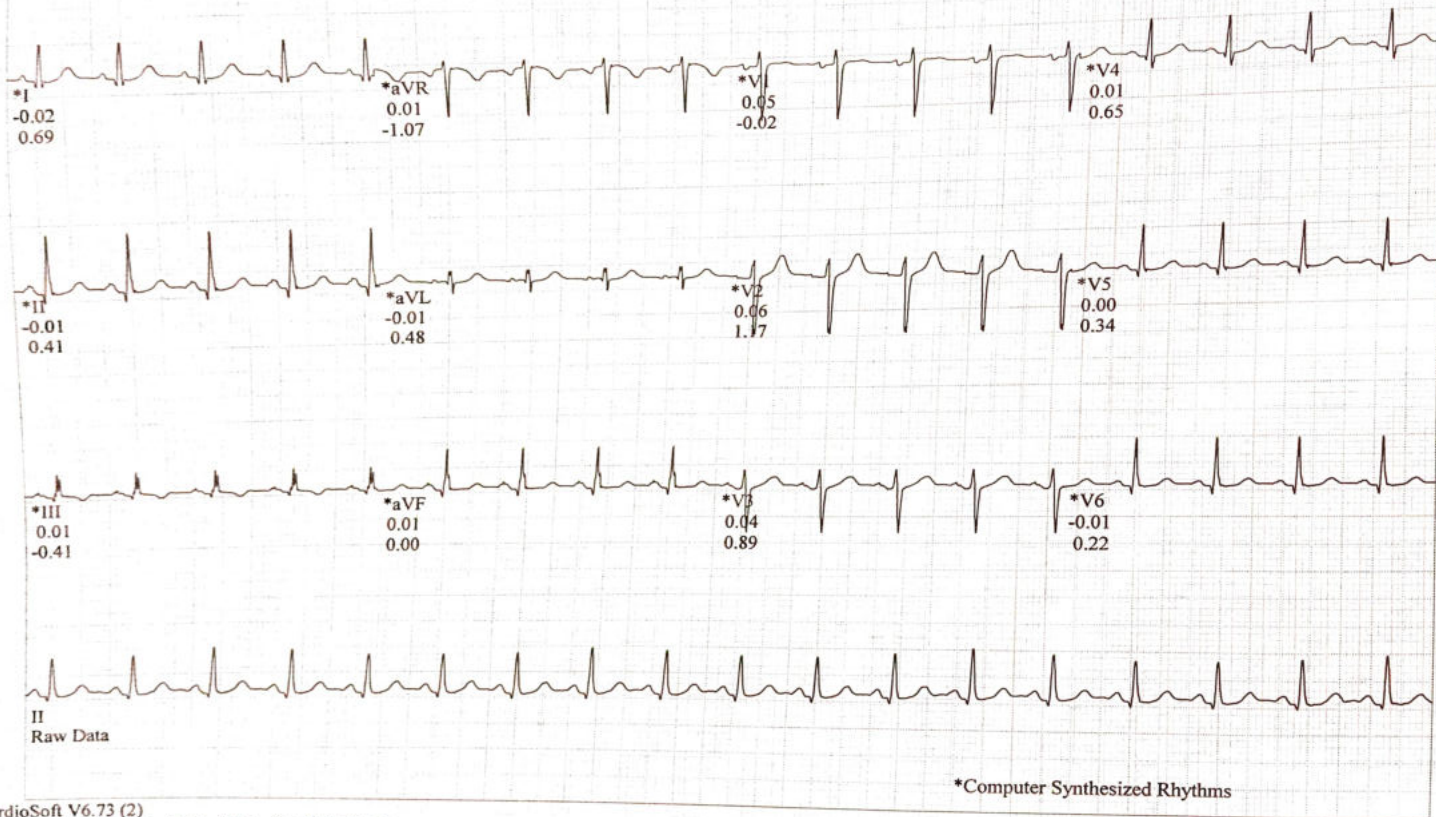
Linked Medians

108 bpm
130/78 mmHg

RECOVERY
#1
05:00

BRUCE
0.0 mph
0.0 %

Lead
ST Level (mV)
ST Slope (mV/s)



OP CASESHEET
Patient MRN : 20110000014312
Patient Name : Mr Venkanna Boini
Sex/Age : Male, 36y 5m
Address : 5-46, TELANGANA, Tungaturthi,
Nalgonda, Telangana, India, 508280
OP-001
OP, New Visit
7893733331

Date : -
Department : FAMILY MEDICINE
Consultant : Dr. Priya S
Ref. Hospital : -
Ref. Doctor : -
Sponsor Name : ARCOFEMI HEALTHCARE LIMITED

BP (mmHg) : 130/78 mmHg
Height (cm) : 167 cm
Respiratory Rate (bpm) : -

Heart Rate (bpm) : 86 bpm
Weight (kg) : 69.8 kg
Fall Score : -
Temp (*F) : -
BMI : -
Pain Score : -

SPO2 : 99%

No Complaints.

No known comorbidities.

- : Known/Unknown
- : Cachectic/ Thin Built/ Average Built/ Obese/ Normal
- : Negative/ Unknown
- : Normal/Any Psychological Problem

USG Abd -> Gr 1 Fatty liver.

Ⓛ Renal Calculus

Ⓛ Renal simple cyst.

TMT - neg.

ECG - NSR.

Lab reports - awaited

Generated By : Vimala M(300235)

Generated On : 14/01/2023 09:02 AM

One free consultation with the same doctor within next 6 days


Narayana Multispeciality Clinic

17/1, 30th Cross, 8th 'B' Main Road, 4th Block, Jayanagar, Bangalore - 560 011
Clinic No. : 8884000991, 9513919615, Pharmacy No. : 9513919615
E-mail: info.jayanagar@narayanahealth.org, web : www.narayanahealth.org

| | | | |
|--------------|--------------------|---------------------|-------------------|
| Patient Name | MR. VENKANNA BOINI | Requested By | EHP |
| MRN | 20110000014312 | Procedure Date Time | 14-01-2023, 11:14 |
| Age/Sex | 36Y 5M/Male | Hospital | NH-JAYANAGAR |

CHEST RADIOGRAPH (PA VIEW)

CLINICAL DETAILS: For health checkup.

FINDINGS:

- The lung fields and bronchovascular markings appear normal.
- The cardiac size is within normal limits.
- Mediastinum and great vessels are within normal limits.
- Trachea is normal and is central. The hilar shadows are unremarkable.
- The costo-phrenic angles are clear. No evidence of pleural effusion or pneumothorax.
- Mild degenerative changes are noted in the spine.
- Both the diaphragmatic domes appear normal.

IMPRESSION:

- No significant abnormality detected.



Dr Arpita Sanikop
Senior Registrar

* This is a digitally signed valid document. Reported Date/Time: 14-01-2023 12:51

This report has been generated from **NH Teleradiology 24/7**, a service of Narayana Health
-- End of Report --

Page 1 of 1

Narayana Multispeciality Clinic

17/1, 30th Cross, 8th 'B' Main Road, 4th Block, Jayanagar, Bangalore - 560 011

Clinic No. : 8884000991, 9513919615, Pharmacy No. : 9513919615

E-mail: info.jayanagar@narayanahealth.org, web : www.narayanahealth.org

