



# द्विवाकर डायग्नोस्टिक सेंटर

E-7/636, पंजाब नेशनल बैंक के पास, मैन रोड, अरेरा कॉलोनी भोपाल ( म.प्र. )

फोन: 0755-2465288, 0755-3520545 मो: 9826340190



*R*  
Dr. B. M. Agarwal  
MBBS, DCP  
Consultant Pathologist





# द्विवाकर डायग्नोस्टिक सेंटर

E-7/636, पंजाब नेशनल बैंक के पास, मैन रोड, अरेरा कॉलोनी भोपाल ( म.प्र. )

फोन: 0755-2465288, 0755-3520545 मो: 9826340190

Pt.Name :-	Mrs. Venu Nimje
Age :-	49y/M
Refd. By :-	BOB
Lab.pNo.:-	90
Date :-	29/03/2022

## EXAMINATION OF BLOOD

### Thyroid profile

<u>TEST</u>	<u>RESULT</u>	<u>NORMAL VALUE</u>
T3 - TOTAL	93.8	82-213 ng/dL
T4 - TOTAL	6.55	6.09-12.23 ug/dL
THYROID STIMULATING HORMONE (TSH)	2.68	0.45-4.25 ul/mL

#### Interpretation:

TSH Levels will be elevated in primary hypothyroidism, TSH levels will be low in Hyperthyroidism there is decreased production of thyroid hormones by the thyroid hence the person may experience symptoms such as weight gain, constipation, cold intolerance and fatigue. Iodine deficiency and Hashimoto thyroiditis is the most common cause of hypothyroidism It makes Thyroid stimulating hormone. If TSH levels are abnormally high it could mean you have an underactive thyroid or hypothyroidism.



Dr. B. M. Agarwal  
Pathologist  
MBBS, DCP  
Consultant Pathologist



# दिवाकर डायग्नोस्टिक सेंटर

E-7/636, पंजाब नेशनल बैंक के पास, मैन रोड, अरेरा कॉलोनी भोपाल ( म.प्र. )

फोन: 0755-2465288, 0755-3520545 मो: 9826340190

Pt.Name :-	Mrs. Venu Nimje
Age :-	49y/
Refd. By :-	BOB
Lab.pNo.:-	90
Date :-	29/03/2022

## EXAMINATION OF BLOOD

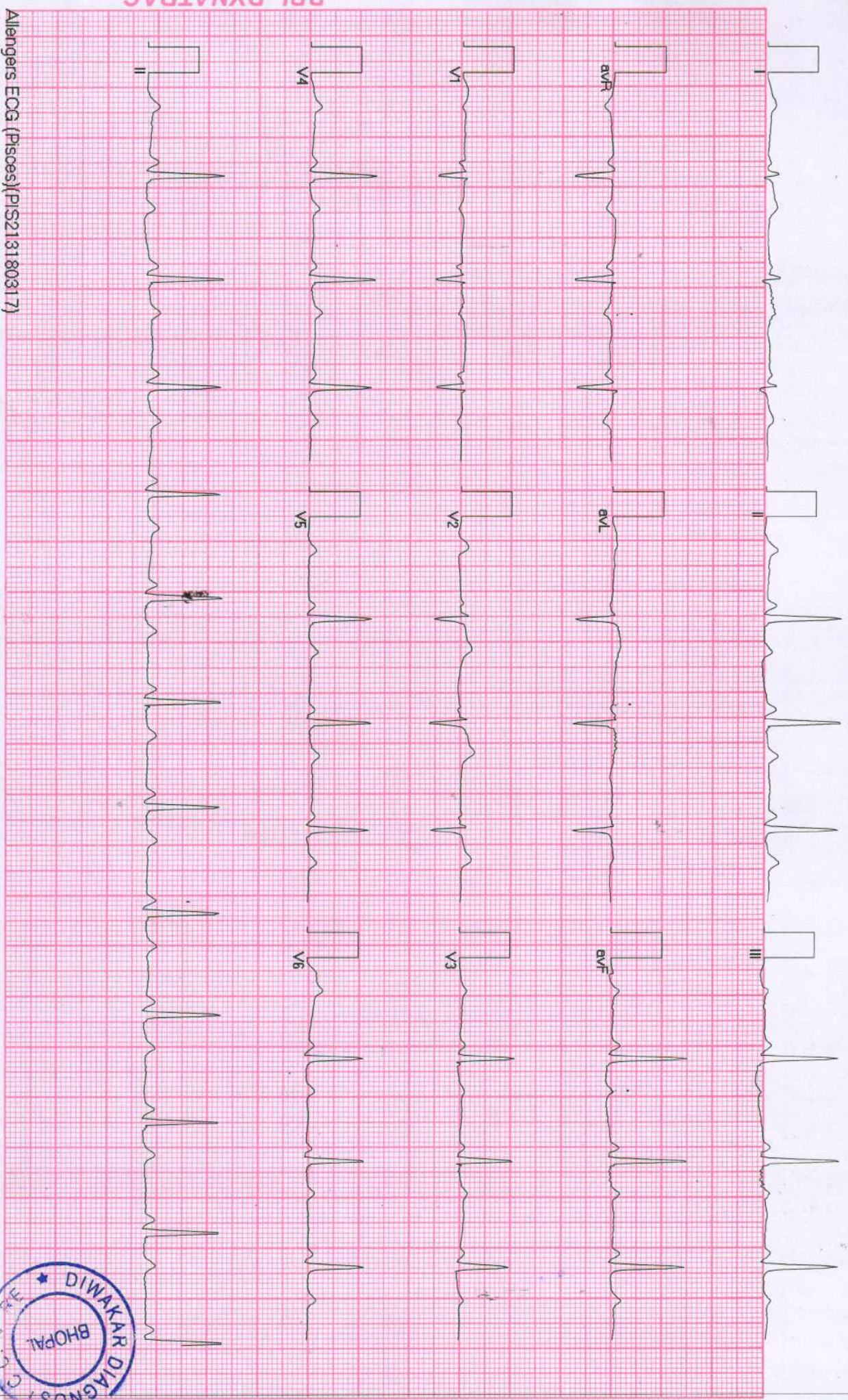
TEST	RESULT	NORMAL VALUE
Haemoglobin	11.1mgs%	Female 12-16gms%, Male 14-18gms%
Red Cell count	4.6	4.5-5.6 million /cumm
Platelet Count	1.96	1.5-5.6 Lac/cumm
Leucocytes per.cu.mm	7600/cumm	5000-11000/cumm
Neutrophils	57%	50-70%
Lymphocytes	33%	20-40%
Eosinophils	06%	0-7%
Monocytes	04%	2-8%
PCV	36.3	37-47
MCV	77.3	76-96
MCH	28.5	27-32
MCHC	30.6	31-35
ESR	12	Male 0-9, Female 0-20mm/FHR
S.Bilirubin(Total)	0.73	0.2-1.0mg/dl
Direct	0.32	0.0-0.25mg/dl
Indirect	0.41	
SGOT	22.8	5-35U/L
SGPT	26.0	8-40U/L
Alk Phosphatase	8.7	3-13 KA units
S. Protein(Total)	6.8	6.0-8.0mg%
Albumin	3.8	3.7-5.3mg%
Globulin	3.2	1.5 to 3.5 mg%
AG Ratio	1.28	1.-2.0
Blood Urea Nitrogen (BUN)	12.0	7-20 mg/dl
S.Creatine	1.0	0.5-1.4mg/dl
S. Uric Acid	4.9	3.5-7.5mg%
Calcium	8.4	8.5-10.5 gm/dl
GGTP	30.3	5-35 UL/dl
Fasting Blood Sugar	87.8	70 to 110mg/dl
Post Prandial Blood Sugar	135.3	Up to 150mg/dl
Total Serum Cholesterol	158.2	100-250 mg%
Serum Triglyceride	111.3	Up to 160 mg%
Serum Cholesterol HDL	40.0	Up to 65 mg%
Serum Cholesterol LDL	95.6	Up to 125 mg%
VLDL	22.2	Up to 30 mg%
TC/HDL Ratio	3.42	
Glycosylated Hemoglobin HBA1c	5.6	Below - 6.0 % -Non Diabetic control 6-7 % -Excellent control Above- 8 % -Poor control

All test have technical limitation. Collaborative clinic pathological interpretation is mandatory. In case of disparity test may be repeated immediately. Typographical mistakes should be get correct instantly. This report is not valid for medico legal purpose



Pathologist  
R. M. Agarwal  
MBBS, DCP  
Consultant Pathologist

BPL-DYNATRAC



Allengers ECG (Piscos)(PIS213180317)





# दिवाकर डायग्नोस्टिक सेंटर

E-7/636, पंजाब नेशनल बैंक के पास, मैन रोड, अरेा कॉलोनी भोपाल ( म.प्र. )

फोन: 0755-2465288, 0755-3520545 मो: 9826340190

Pt.Name :-	Mrs. Venu Nimje
Age :-	49y/F
Refd. By :-	BOB
Lab.pNo.:-	90
Date :-	29/03/2022

## URINE ANALYSIS

<u>A. PHYSICALEXAMINATION</u>		<u>C. MICROSCOPIEXAMINATION</u>	
1. Colour	Pale Yellow	Pus Cells	2-4/HPF
2. Appearance	Clear	R.B.C.	Nil
3. Specific Gravity	Q.N.S.	Epithelial Cell	1-2/HPF
<u>B. CHEMICAL EXAMINATION</u>		Cast	Nil
1.Reaction	Acidic	Crystals(Cal.Oxa)	Nil
2.Albumin	Nil	Bacteria	Nil
3.Sugar	Nil	Amorphous	Nil
4.Bile Salts	Absent	T. Vaginitis	Nil

URINE COTININE	Negative	By Card method
----------------	----------	----------------



*Dr. B. M. Anarwal*  
Pathologist, DCP  
Consultant Pathologist

All test have technical limitation. Collaborative clinic pathological interpretation is mandatory. In case of disparity test may be repeated immediately. Typographical mistakes should be get correct instantly. This report is not valid for medico legal purp



# दिवकर डायग्नोस्टिक सेंटर

E-7/636, पंजाब नेशनल बैंक के पास, मैन रोड, अरेरा कॉलोनी भोपाल ( म.प्र. )

फोन: 0755-2465288, 0755-3520545 मो: 9826340190

Pt.Name :-	Mrs. Venu Nimje
Age :-	49y/F
Refd. By :-	BOB
Lab.pNo.:-	90
Date :-	29/03/2022

## REPORT

Tricia Central

Thoracic cage normal

Both Lungs Field Clear.

Both hilers normal

Cardiac border normal

Both cp angles clear

Both domes and diaphragm normal

## IMPRESSION

\*\*\*\*\*

-NO CARDIO PULMONARY PATHOLOGY

-COORELATE WITH CLINICAL FINDINGS.

*h*  
Dr. B. M. Agarwal  
MD, Radiology  
Consultant Radiologist  
**Radiologist**





# डॉ. सविता क्लिनिक



34, भूतल, मोहिनी अदिति आर्केड, शाहपुरा मस्जिद के पास  
भरत नगर रोड, ई-7/194, अरेरा कॉलोनी, भोपाल - 462038

Mob. : 8989649694, 9516333619

Clinic Registration : CL/5392/Jun/2017

PNDT Registration : MPPCPNDT/BPL/2017/206

Name : Mrs. Yenu Nimje. Age 49 YRS./F

R/B Health check up No. \_\_\_\_\_ Date 29/3/2022

## WHOLE ABDOMES ULTRASOUND REPORT

### Indication:

Liver appears normal in size and shape with normal outline. Normal/  
~~increased~~ perenchymal echogenicity is noted. No E/O focal lesion/ IHBR  
dilatation is sen. Hepatic veins and portal veins appear normal.

No E/O subdiaphragmatic Collection.

Gall Blader is physiologically well distended. No. E/O echogenic foci in GB  
lumen. GB wall is normal / ~~thickened~~. No E/O pericholecystic collection.  
Common duct reveals normal course and caliber.

Pancreas appear normal in size, shape and echo texture with smooth  
contour. No peripancreatic pathology seen. (Not seen due to gases)

Spleen is normal in size and echo texture.

IVC and aorta appear to be normal.

No evidence of lymphadenopathy is noted.

No evidence of free fluid is noted.

Right Kidney is normal in size. size, shape and position. Corticomedullary  
defferentiation (CMD) is well maintained. Normal cortical thickness is  
noted. No E/O hydronephrosis or calculus is noted.

PTO



राजस्थान चिकित्सा विश्वविद्यालय  
राजस्थान चिकित्सा विश्वविद्यालय  
राजस्थान चिकित्सा विश्वविद्यालय  
राजस्थान चिकित्सा विश्वविद्यालय  
राजस्थान चिकित्सा विश्वविद्यालय

**Left Kidney** is normal is size, shape and position. CMD is well maintained. Normal cortical thickness is noted. No E/O hydronephrosis or calculus is noted.

**Urinary Bladder** is well distended (physiological). its contents are echo free. No E/O bladder wall thickening is noted. ~~Post-void residue is insignificant.~~

~~**Prostate** is normal in size. Shape and echo texture with smooth outline. No E/O focal lesion is noted.~~

**Uterus** is ante/ retro verted and normal in size, shape and echotexture with smooth outline. No E/O focal lesion is noted. Endometrial echo appear normal. Cervical and vaginal shadows appear normal.

**Right Ovary** appears ~~enlarged~~ / Normal in size, shape and echo texture.

**Left Ovary** appears ~~enlarged~~ / Normal in size, shape and echo texture.

**Impression : Normal study.**

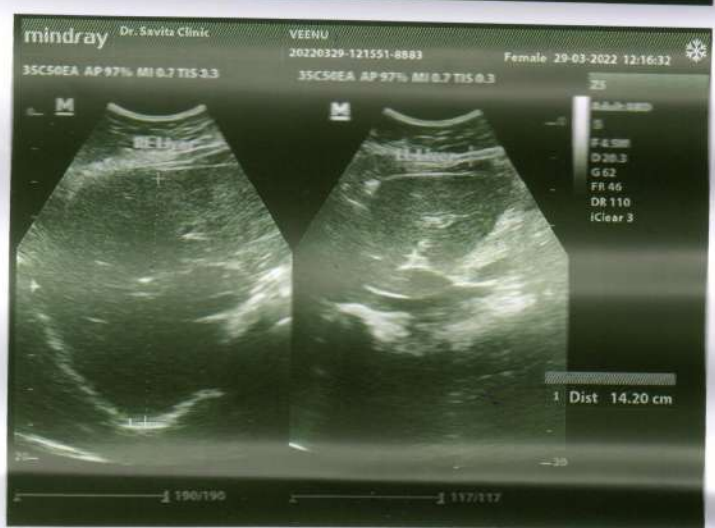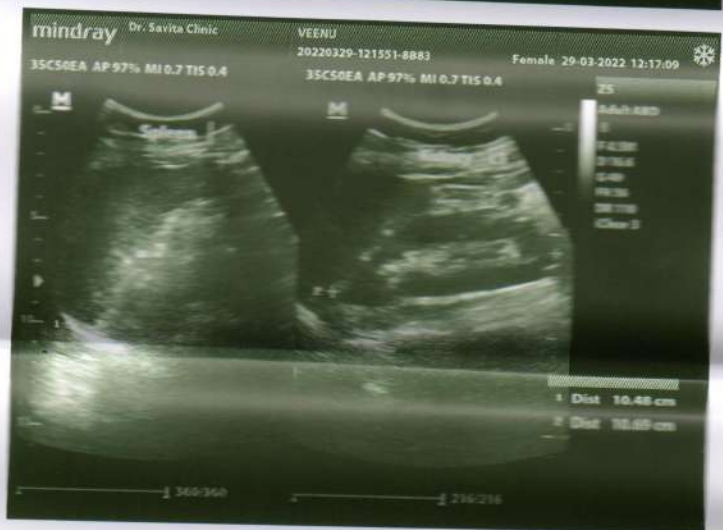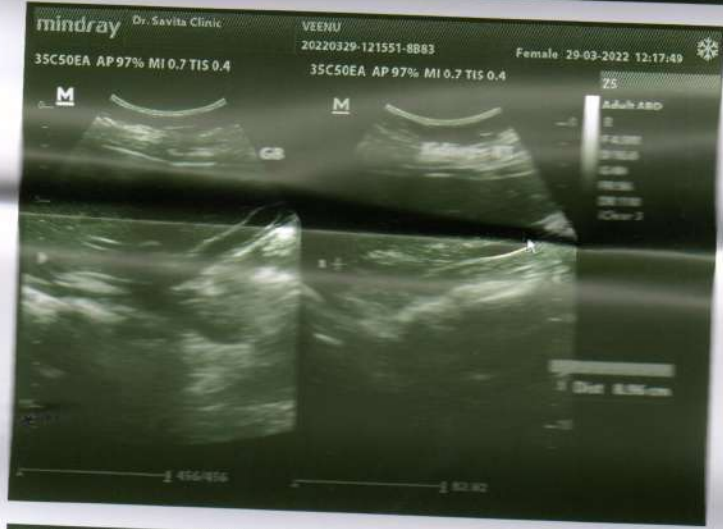
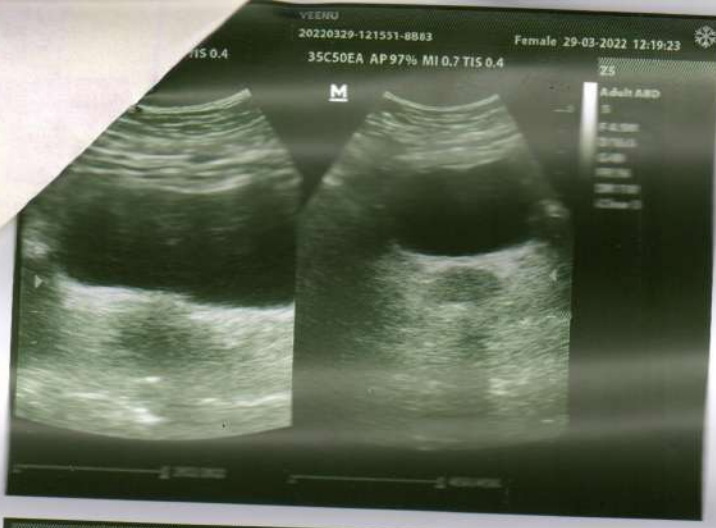**Advised clinical Correlation.**

Dr. P. Savita, MD  
MBBS, MD (O&G) Reg. No. 9971  
स्त्री रोग विशेषज्ञ

Dr. Jayant Yadav, MD  
MBBS, MD (Radiologist) Reg. No. 4166  
रेडियोलॉजिस्ट



taind.  
culus is



**Diwakar Diagnostic Centre**  
E-7/636, Near Punjab National Bank Bhopal(M.P.)

324 / MRS. VENU NIMJE / 49 Yrs / F / 150 Cms / 60 Kg Date: 29-Mar-2022 Technician : NIL

**Report**


(GEM213180307)(R)Allengers



**Report :**

TEST OBJECTIVE	: ROUTINE CHECK UP
RISK FACTOR	: AGE
ACTIVITY	: MODERATE ACTIVE
OTHER INVESTIGATION	: ROUTINE BLOOD INVESTIGATION
REASON FOR TERMINATION	: FATIGUE. HEART RATE ACHIEVED
EXERCISE TOLERANCE	: AVERAGE
EXERCISE INDUCED ARRHYTHMIAS	: NO
HAEMODYNAMIC RESPONSE	: NORMAL
CHRONOTROPIC RESPONSE	: NORMAL
FINAL IMPRESSION	: STRESS TEST IS NEGATIVE FOR EXERCISE INDUCED ISCHAEMIC HEART DISEASE

**BPL-DYNATRAC**



Doctor : CARDIOLOGIST

324 / MRS. VENU NIMJE / 49 Yrs / F / 150 Cms / 60 Kg Date: 29-Mar-2022 Technician : NIL

(GEM213180307)(R)Allengers

Stage	Time	Duration	Belt Speed (mph)	Elevation	METS	Rate	%THR Achieved	BP	RPP	PVC	Comments
Supine	00:22	0:01	00.0	00.0	01.0	68	40%	120/80	081	00	
Supine	00:22	0:01	00.0	00.0	01.0	68	40%	120/80	081	00	
Standing	00:33	0:01	00.0	00.0	01.0	066	39%	120/80	079	00	
HY	00:48	0:01	00.0	00.0	01.0	068	40%	120/80	081	00	
Warm Up	01:13	0:02	01.7	10.0	01.0	074	43%	120/80	088	00	
ExStart	01:17	0:06	01.7	10.0	01.1	074	43%	120/80	088	00	
BRUCE Stage 1	04:17	3:00	01.7	10.0	04.7	129	75%	140/90	180	00	
PeakEx	05:13	0:56	02.5	12.0	05.5	140	82%	140/90	196	00	
Recovery	06:12	1:00	01.1	00.0	01.0	124	73%	146/96	181	00	
Recovery	07:12	2:00	00.0	00.0	01.0	073	43%	136/80	099	00	
Recovery	07:21	2:08	00.0	00.0	01.0	074	43%	136/80	100	00	

**Findings :**

Exercise Time : 03:57  
 Max HR Attained : 140 bpm 82% of Target 171  
 Max BP Attained : (Sys) 146/96  
 Max Workload Attained : 5.5 Fair response to induced stress  
 Max ST Dep Lead & Value : Max ST Dep Lead & Value  
 Test End Reasons : Fatigue, Heart Rate Achieved

BPL-DYNATRAC

Doctor : CARDIOLOGIST



PAS. VENU NIMLE / 49 Yrs / F / 150 Cms / 60 Kg / HR : 68

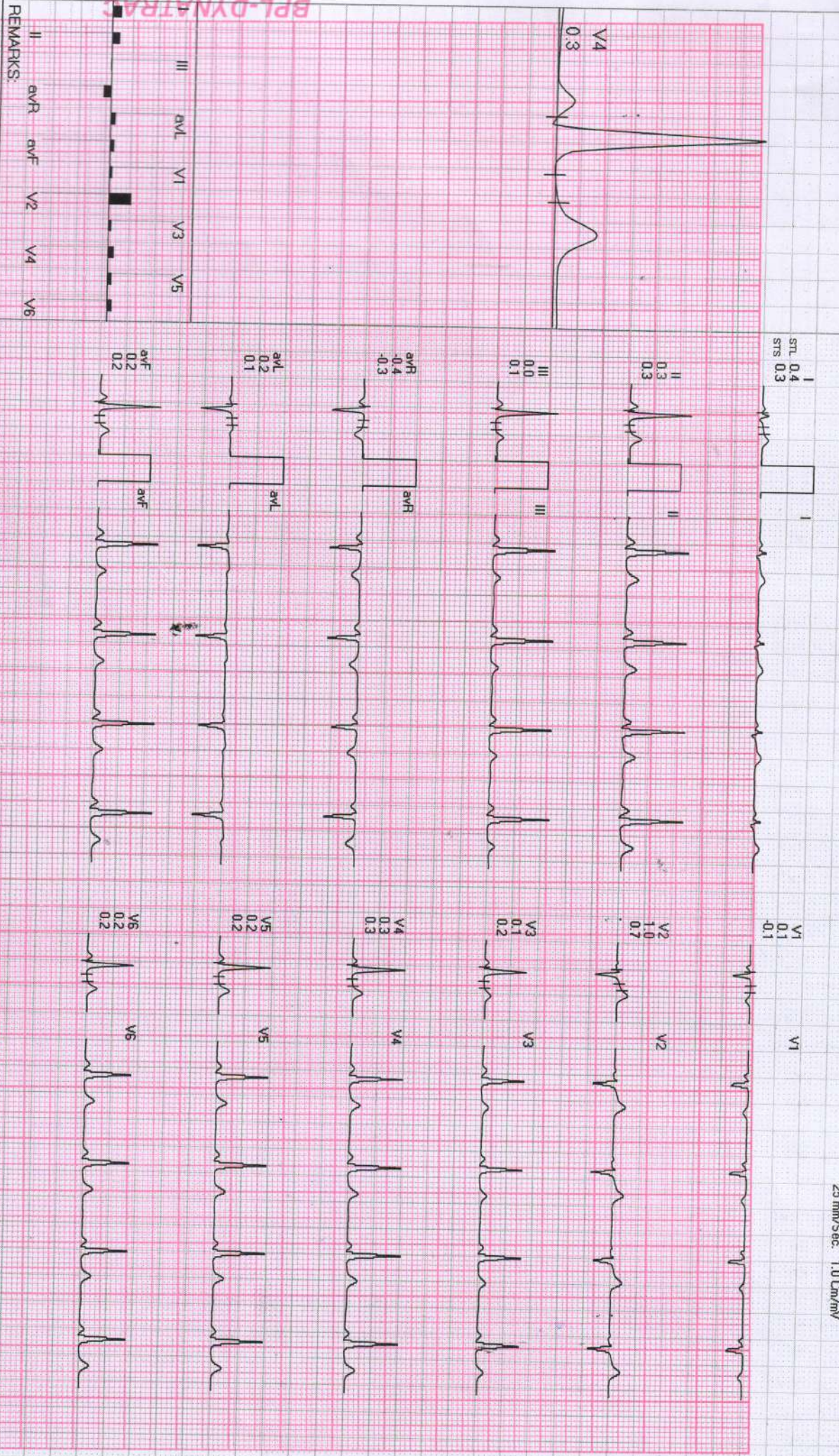
Date: 29-Mar-2022 10:19:50 AM

METS: 1.0/ 68 bpm 39% of THR BP: 120/80 mmHg

Raw ECG/BLC On/ Notch On/ HF 0.05 Hz/LF 20 Hz

4X 80 mS Post J

EXTime: 00:21 0.0 mph, 0.0%  
25 mm/Sec. 1.0 Cm/mV



REMARKS: II aVR aVF V2 V4 V6

BPL-DYNATRAC

MRS. VENU NIMJE / 49 Yrs / F / 150 Cms / 60 Kg / HR : 68

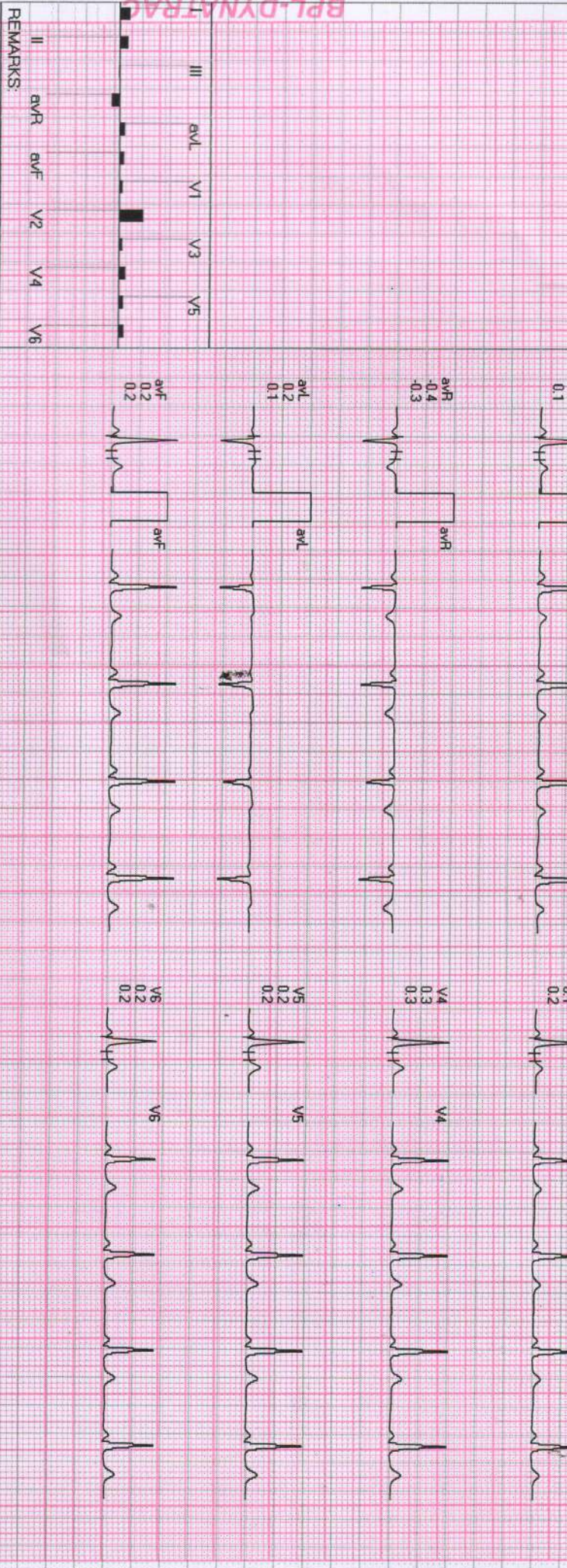
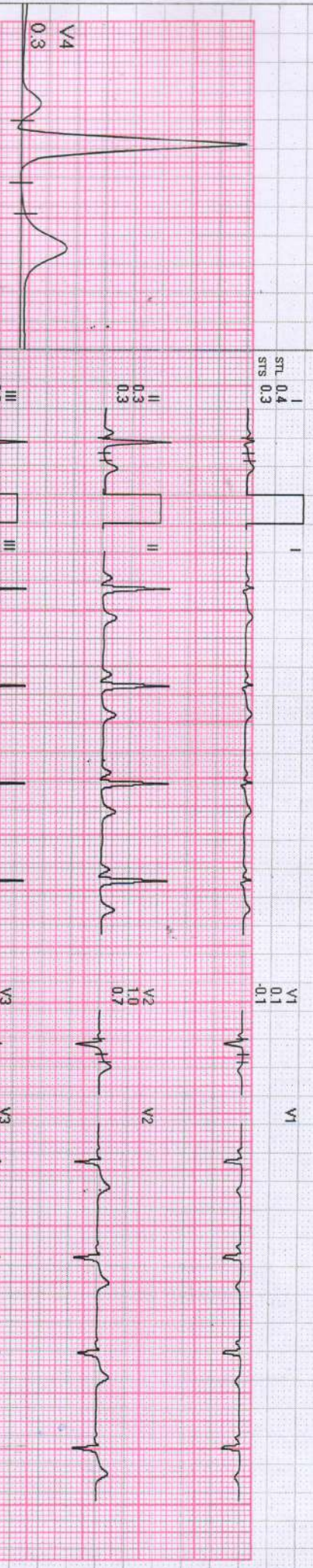Date: 29-Mar-2022 10:19:50 AM

METS: 1.0/68 bpm 39% of THR BP: 120/80 mmHg Raw ECG/ BLC On/ Natch On/ HF 0.05 Hz/LF 20 Hz

EXTime: 00:21 0.0 mph, 0.0%

4X 80 mS Post J

25 mm/Sec. 1.0 Cm/mV



REMARKS: II aVR aVL aVF V1 V2 V3 V4 V5 V6

BPL-DYNITRAC

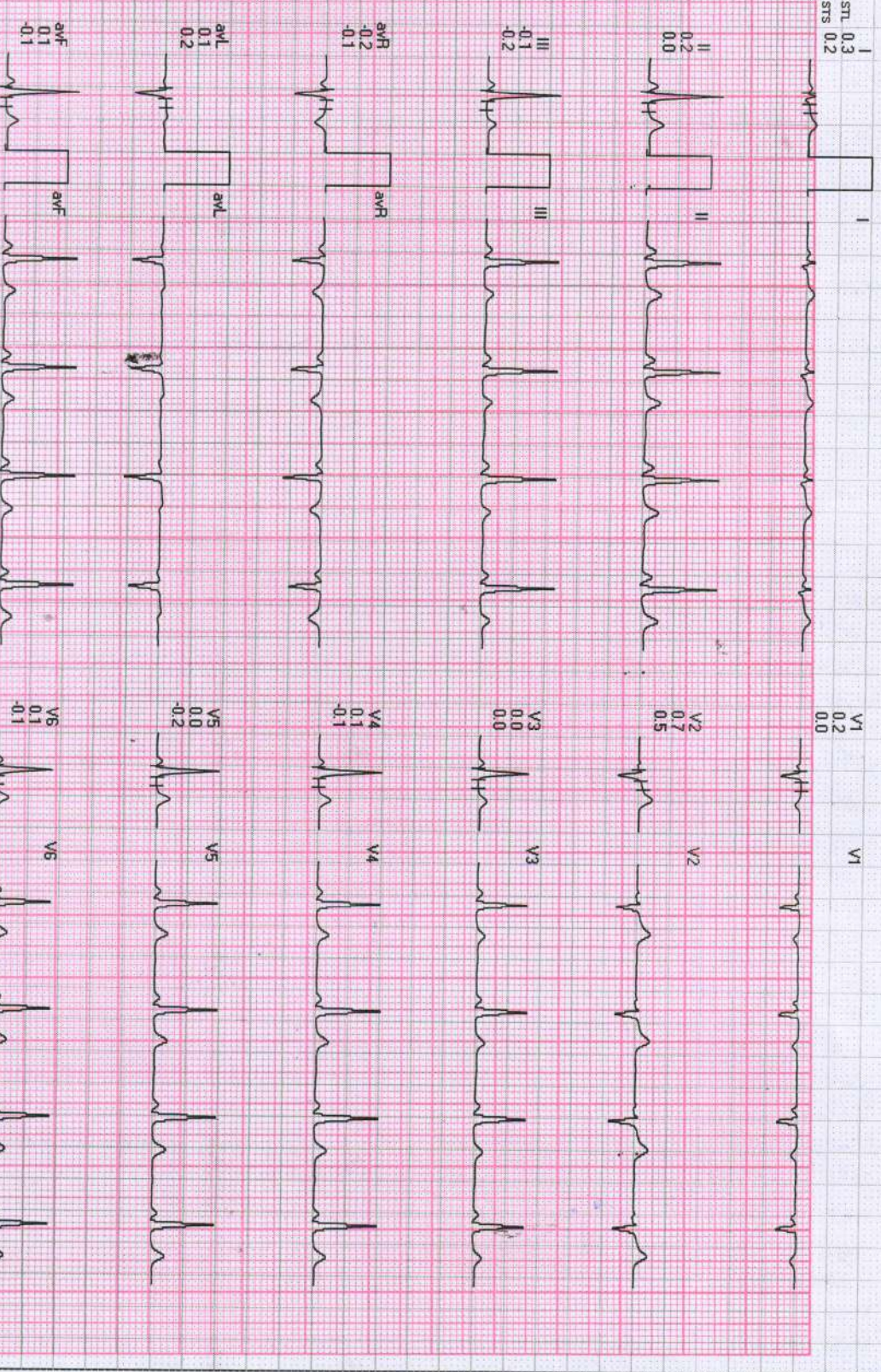
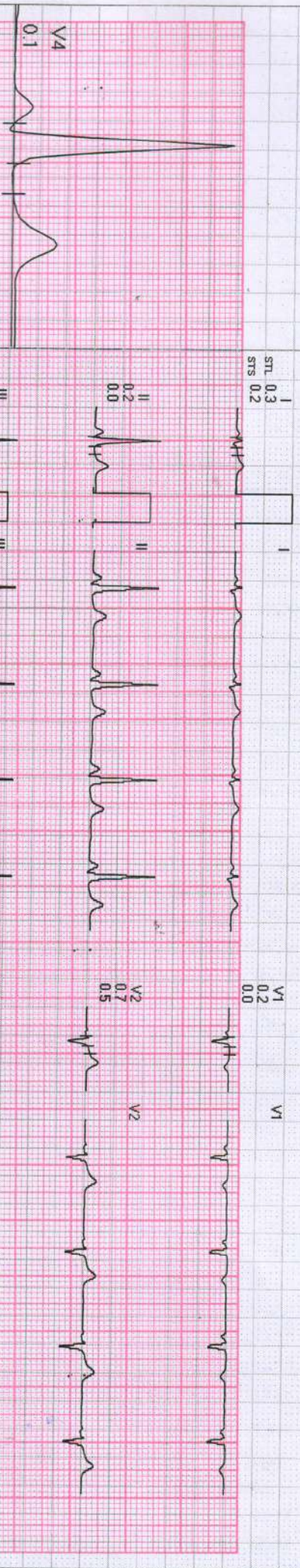
MRS. VENU NIMJE / 49 Yrs / F / 150 Cms / 60 Kg / HR : 66

Date: 29-Mar-2022 10:19:50 AM METS: 1.0/ 66 bpm 38% of THR BP: 120/80 mmHg Raw ECG/ BLC On/ Natch On/ HF 0.05 Hz/LF 20 Hz

ExTime: 00:32 0.0 mph, 0.0%

4X 80 mS Post J

25 mm/Sec 1.0 Cm/mV



BPL-DYNMTRAC

REMARKS: II aVR aVF V2 V4 V6

MRS. VENU NIMUE / 49 Yrs / F / 150 Cms / 60 Kg / HR : 68

Date: 29-Mar-2022 10:19:50 AM

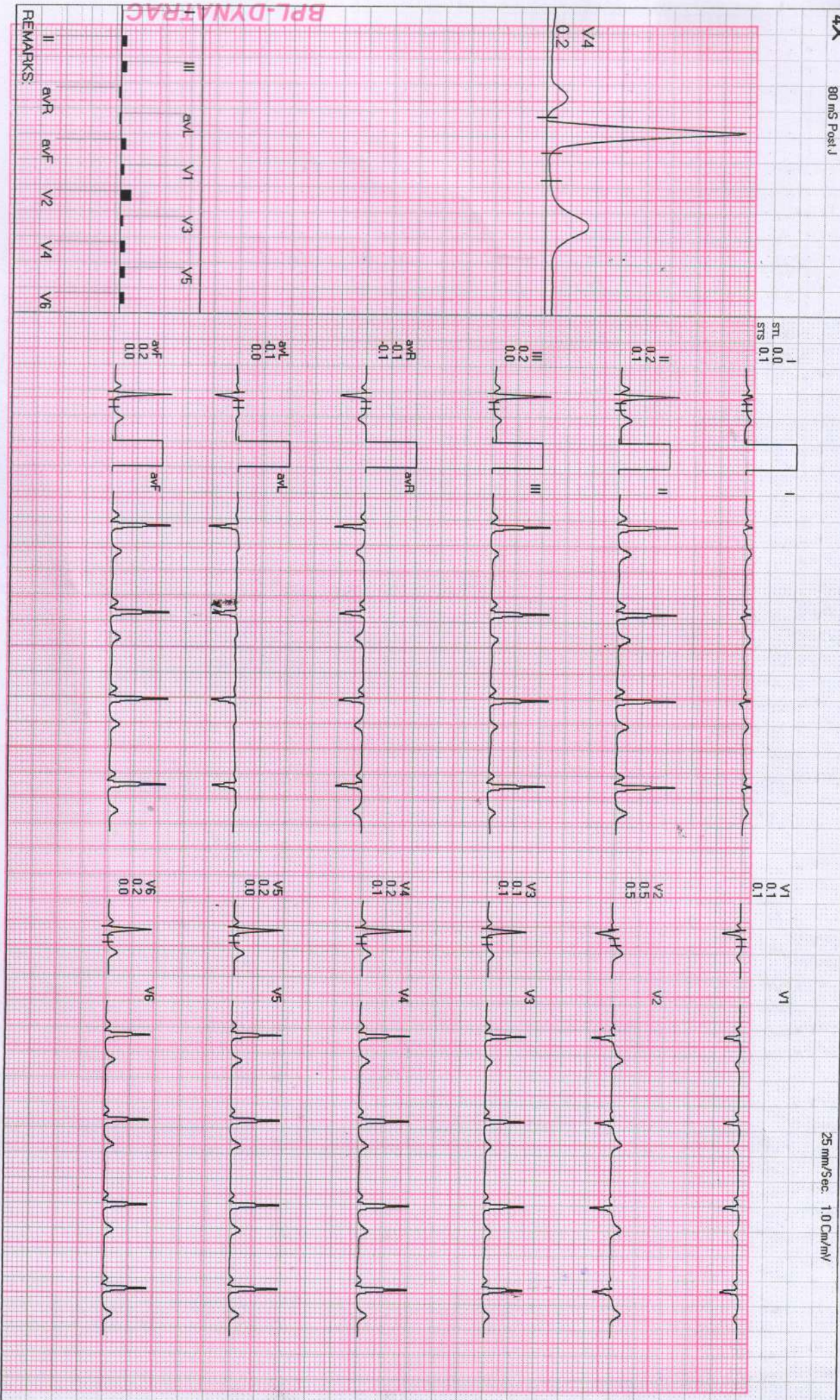
METS: 1.0 / 68 bpm 39% of THR BP: 120/80 mmHg

Raw ECG/ BLC On/ Notch On/ HF 0.05 Hz/LF 20 Hz

EXTime: 00:47 0.0 mps, 0.0%

4X 80 mS Post J

25 mm/Sec 1.0 Cm/mV



BPL-DYNAMI-RAC

REMARKS: II aVR aVL V1 V2 V3 V4 V5 V6

MRS. VENU NIMJE / 49 Yrs / F / 150 Cms / 60 Kg / HR : 74

Date: 29-Mar-2022 10:19:50 AM

METS: 1.0/ 74 bpm 43% of THR BP: 120/80 mmHg

Raw ECG/ BLC On/ Notch On/ HF 0.05 Hz/LF 20 Hz

EXTime: 00:00 0.0 mph, 0.0%

25 mm/Sec. 1.0 Cm/mV

4X

80 ms Post J

I  
STL 0.0  
STS 0.1

V1  
0.5  
0.0

II  
-0.1  
0.1

V2  
0.7  
0.4

V4  
-0.1

III  
-0.1  
0.0

V3  
-0.1  
0.1

avR  
0.1  
-0.1

V4  
-0.1  
0.2

avL  
0.1  
0.1

V5  
-0.1  
0.1

avF  
-0.1  
0.0

V6  
0.0  
0.0

III aVL V1 V3 V5

II avR avF V2 V4 V6

REMARKS:

BPL-DYNATRAC





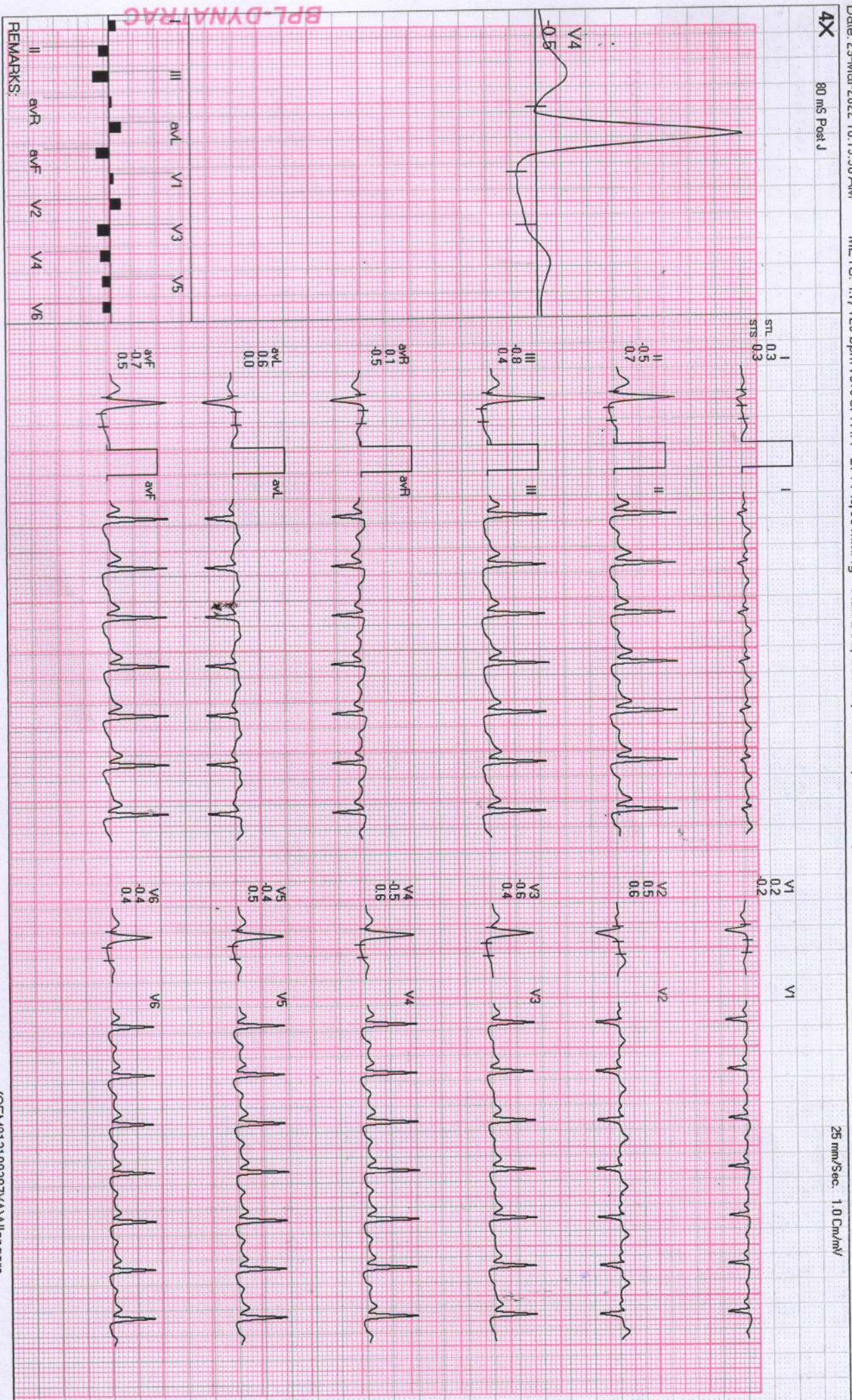
MRS. VENU NIMJE / 49 Yrs / F / 160 Cms / 60 Kg / HR : 129

Date: 29-Mar-2022 10:13:50 AM METS: 4.7/129 bpm 75% of THR BP: 140/90 mmHg Raw ECG/ BLC On/ Natch On/ HF 0.05 Hz/LF 20 Hz

ExTime: 03:00 1.7 mph. 10.0%

4X 80 ms Post J

25 mm/Sec. 1.0 Cm/mV



BPL-DYNATRAC

REMARKS:  
II aVR aVL V1 V2 V3 V4 V5 V6

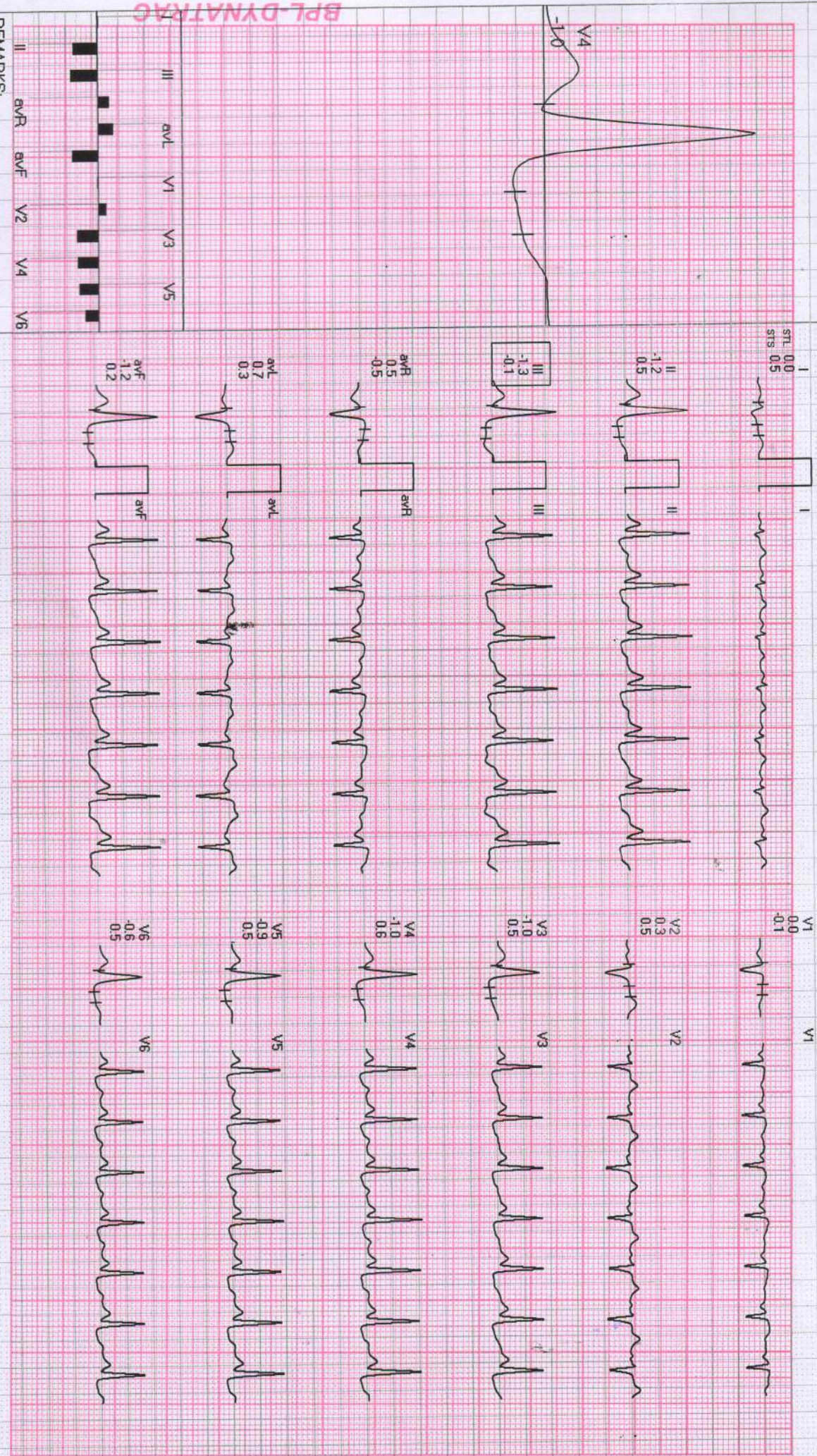
324 / MRS. VENU NIKHILE / 49 Yrs / F / 150 Cms / 60 Kg / HR : 140

Date: 29-Mar-2022 10:19:50 AM METS: 5.5 / 140 bpm 81% of THR BP: 140/90 mmHg Raw ECG/ BLC On/ Notch On/ HF 0.05 Hz/ LF 20 Hz

ExTime: 03:56 2.5 mph, 12.0%

25 mm/Sec. 1.0 Cm/mV

4X 60 ms Post J



BPL-DYNATRAC

REMARKS:



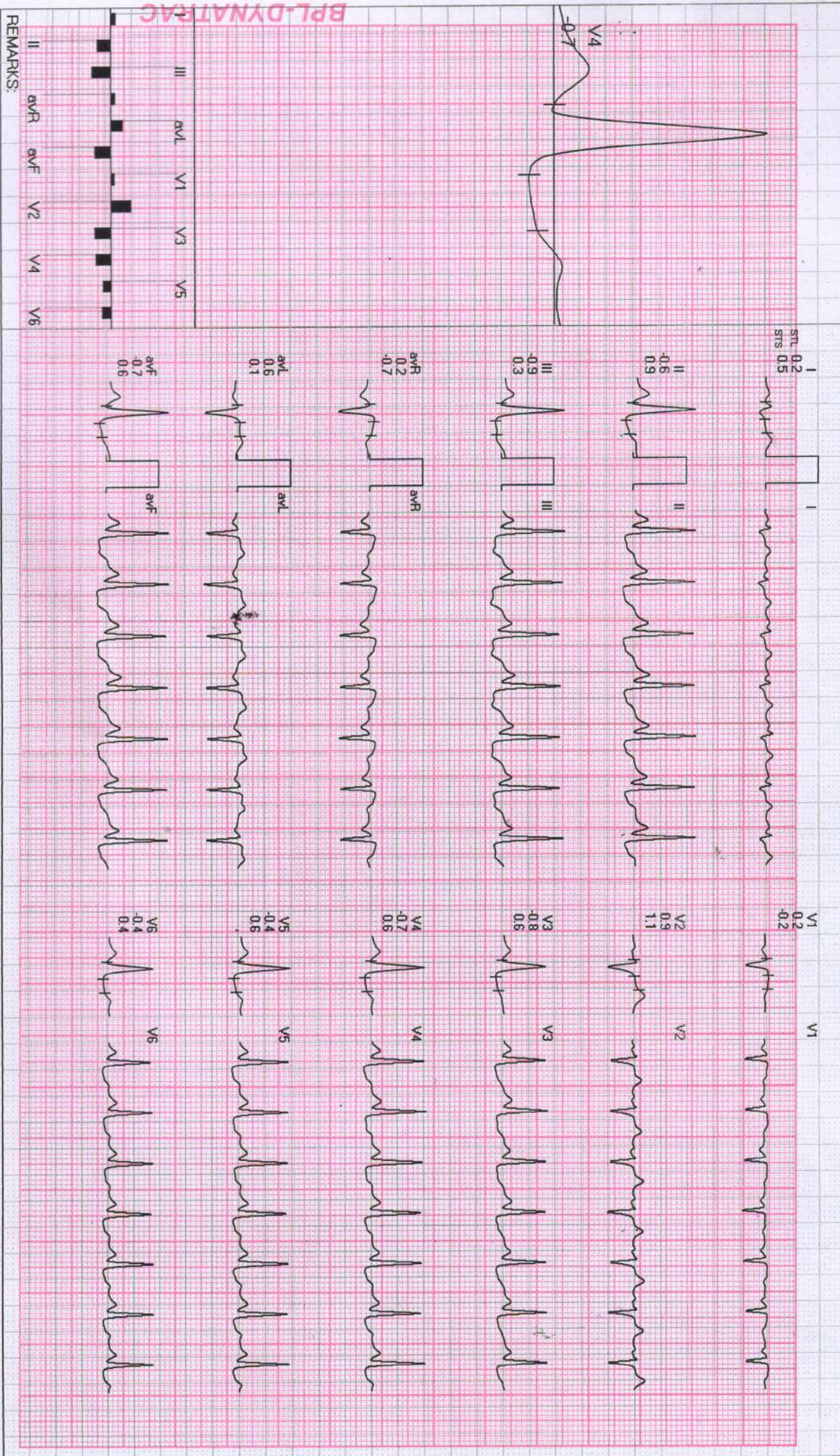
324 / MRS. VENU NIMLE / 49 Yrs / F / 150 Cms / 60 Kg / HR : 124

Date: 29-Mar-2022 10:19:50 AM METS: 1.0/124 bpm 72% of THR BP: 146/96 mmHg Raw ECG/ BLC On/ Notch On/ HF 0.05 Hz/LF 20 Hz

EXTime: 03:56 0.0 mph, 0.0%

4X 80 mS Post J

25 mm/Sec 1.0 Cm/mV



BPL-DYNATAC

REMARKS: II aVR aVL V1 V2 V3 V4 V5 V6



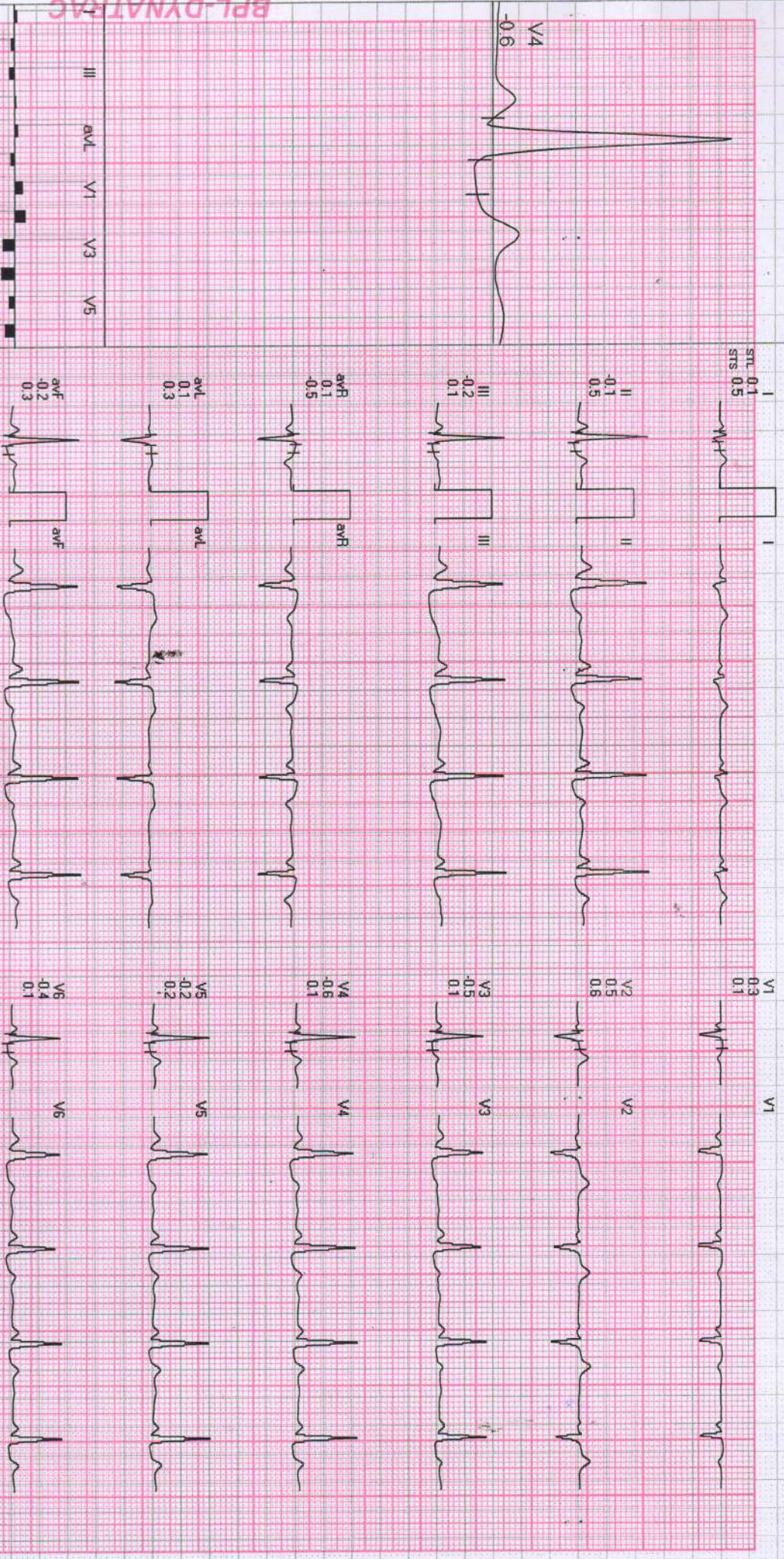
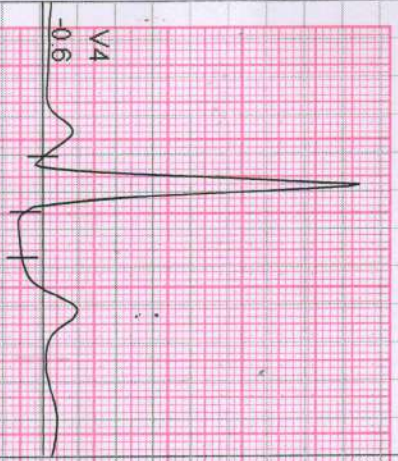
324 / MRS. VENU NIKME / 49 Yrs / F / 150 Cms / 60 Kg / HR : 73

Date: 29-Mar-2022 10:13:50 AM METS: 1.0/ 73 bpm 42% of THR BP: 136/80 mmHg Rew ECG/ BLC On/ Notch On/ HF 0.05 Hz/LF 20 Hz

ExTime: 03:56 0.0 mph, 0.0%

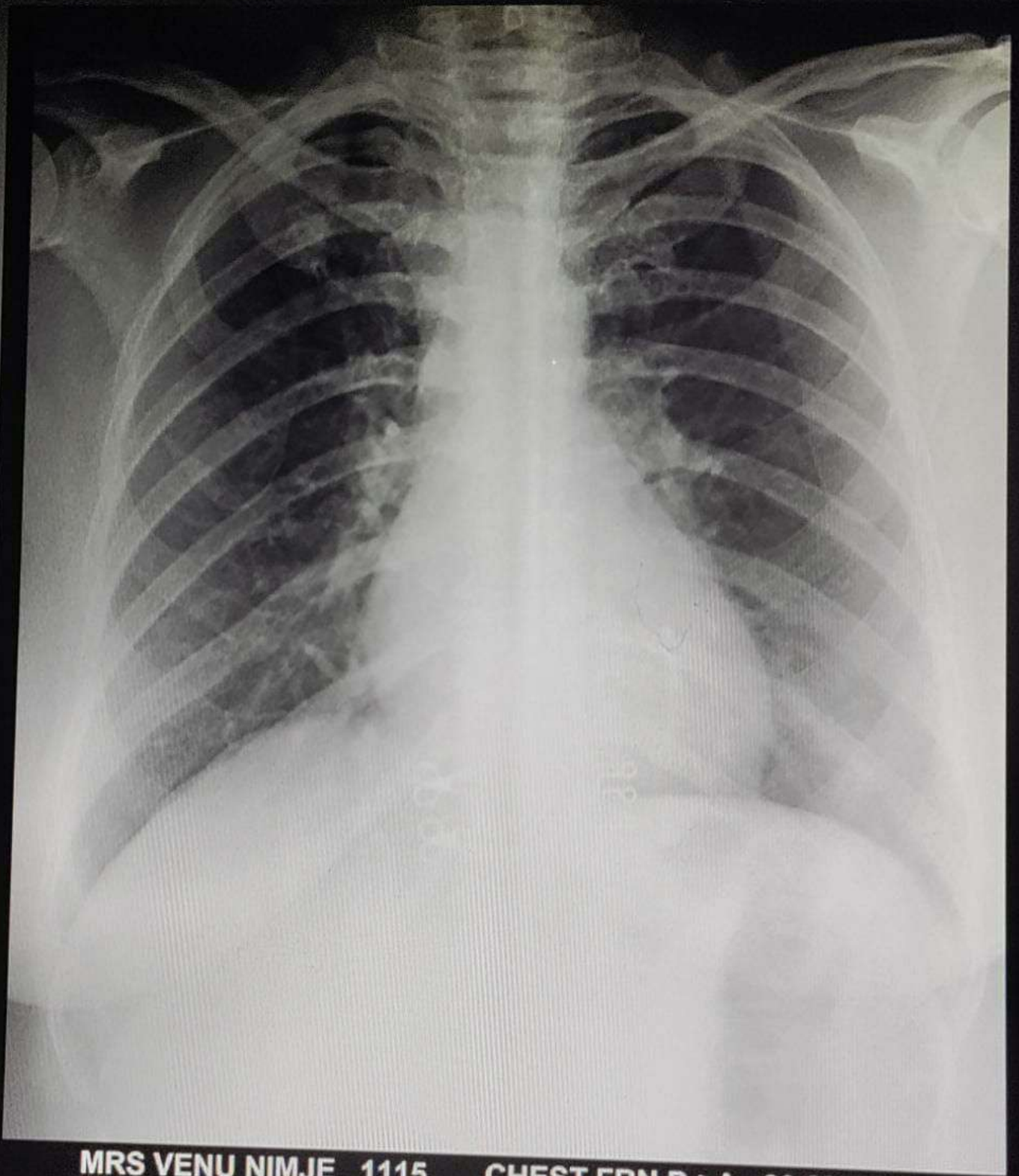
4X 80 ms Post J

25 mm/Sec. 1.0 Cm/mV



BPL-DYNATAC

REMARKS:



**MRS VENU NIMJE 1115 CHEST,FRN P->A 29-Mar-22  
DIWAKAR DIAGNOSTIC CENTRE , ARERA COLONY ,BHOPAL**



# Diwakar Diagnostic Centre

पैथोलोजी | टी.एँम.टी. | एक्स-रे | ई .सी.जी. | एको कार्डियो ग्राफी | सोनोग्राफी



Shot on OnePlus

By 🤖