



Mediwheel
...Your wellness partner

Arcofemi Healthcare Pvt Ltd

(Formerly known as Arcofemi Healthcare Ltd)

F-701A, Lado Sarai, Mehrauli, New Delhi - 110030

Email: wellness@mediwheel.in, Website: www.mediwheel.in

Tel: +91-11-41195959, Fax: +91-11-29523020

CIN: U24240DL2011PTC216307

MEDICAL FITNESS CERTIFICATE

(To be signed by a registered medical practitioner holding a Medical degree)

This is to certify that **Mr. Vijay Kumar** aged, **37yr**. Based on the examination, I certify that he is in good mental and physical health and it is free from any physical defects such as deafness, colour blindness, and any chronic or contagious diseases.

Place: **Bhatinda**

Date: 27/06/2024

Mr. Vijay Kumar
MBBS
RCMR 47093
Name & Signature of

Medical officer

Name- *Vijay kumar*

Date: *27/06/2024*
Age: *37/Male*

CBC

Test Name	Result	Range
WBC	5.16 10^3 /ul	4.0-11.0 /ul
RBC	4.53 10^6 /ul	3.80-5.30 /ul
Haemoglobin	12.9 Gm/dl	12.0-16.0 gm/dl
HCT	38.5 %	34.0- 56.0 %
MCV	85.1 fl	80-100 fl
MCH	28.4 Pg	27.0-32.0 pg
MCHC	33.4 g/dl	32.0-36.0 g/dl
PLATELET COUNT	289 10^3 /u	120-380 /u
LYMPHOCYTES	20.5 %	25.0-125.0 %
MONOCYTES	11.3H %	0.0-9.0 %
GRANULOCYTES	68.2 %	42.0-85.0 %

Urine routine

	Observed values	Unit
Cal Oxalate	Nil	
Physical examination	-	-
colour	-	YELLOW
appearance	-	CLEAR
volume	-	30ML
PH	-	-
Specific Gravity	-	1.121
Chemical examination	-	-
albumin	NIL	-
sugar	NIL	-
Microbiology Examination	normal	-
Pus cell	2-3	/HPF
Epithelial cells	NIL	-
RBCS	NIL	-
CASTA	NIL	-
CRYSTALS	NIL	-

Dr. HPK Nagpa

M.D.Medicine PMC 33621


Nagpal Superspeciality Hospital

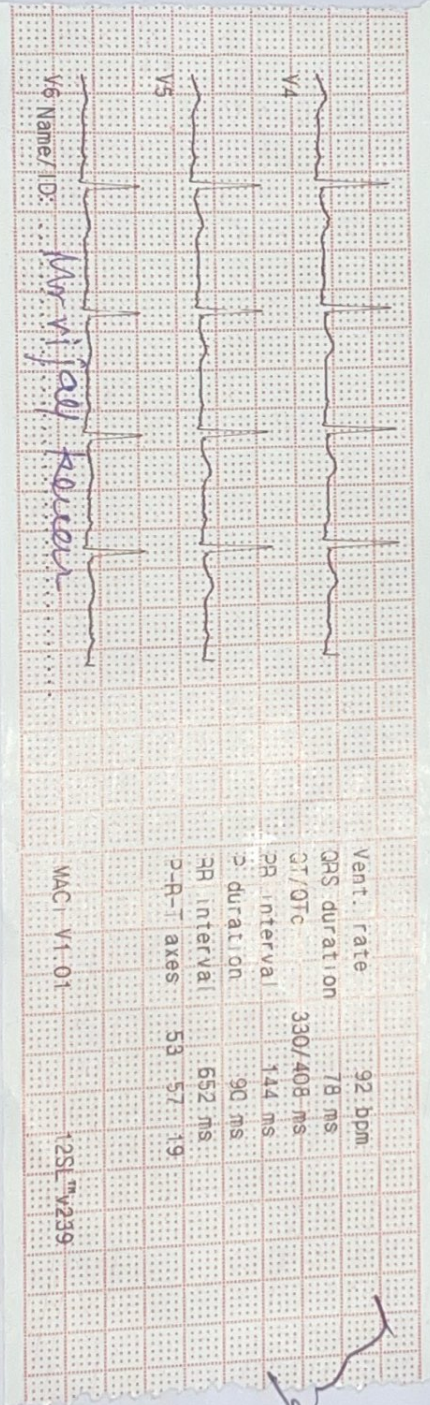
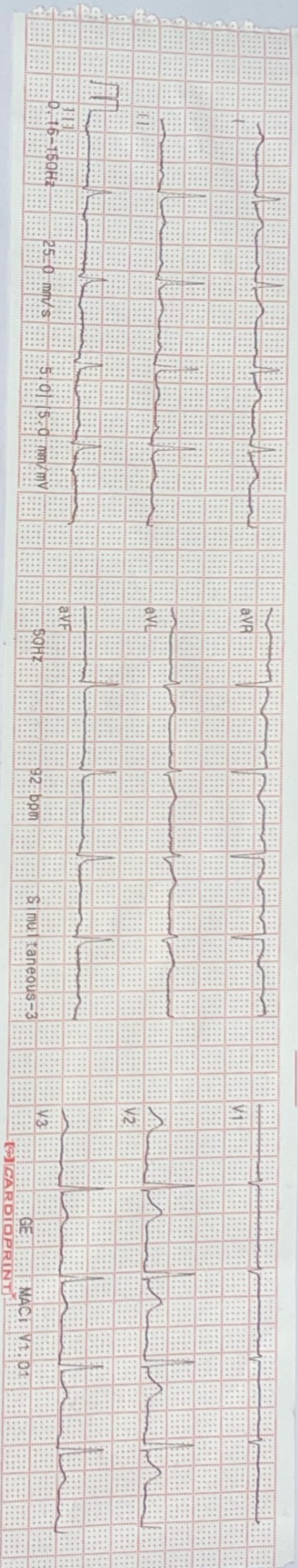
Name-Vijay kumar

Date: 27/06/2024

Age: 37/Male

S. Creatnine	1.0	Mg/dl	0.50-1.40 mg/dl
BLOOD UREA	28	Mg/dl	10-50 mg/dl
<i>Blood group</i>	<i>A+VE</i>		
TOTAL CHOLESTROL	210	Mg/dl	0-200 mg/dl
SGPT	38	U\L	0-45 U\L
E.S.R	09	Mm 1 hr	0-20 mm 1hr
FBS	85	Mg/dl	60-110mg/dl


Dr. HPK Nagpal
M.D. Medicine PMC 33621
Nagpal Superspeciality Hospital



Dr. HPK Nagpal
 M.D. Medicine PMC 33621
 Nagpal Superspeciality Hospital

Nagpal Superspeciality Hospital

Name.vijay kumar
Ref.By: Dr. H.P.K . Nagpal


Age/Sex-37y/M
Date-27-06-2024

REPORT

X-RAY CHEST (P.A VIEW)

- SOFT TISSUE AND BONY CAGE IS NORMAL.
- BOTH C.P. ANGLES ARE CLEAR
- BOTH CARDIOPHRENIC ANGLES ARE NORMAL
- BOTH LUNG FIELD ARE CLEAR.
- BOTH HILA ARE NORMAL
- NO MEDIASTINAL WIDENING/SHIFT SEEN
- HEART SHADOW IS WITHIN NORMAL LIMIT

IMPRESSION:-NORMAL STUDY



Dr. HPK Nagpal
M.D.Medicine PMC 33621
Nagpal.Superspeciality Hospital

Dr. H.P.K Nagpal
MD Medicine



Case ID: PA
C. B. NAGPAL SUPERSPECIALITY HOSPITAL
1001, ROAD BATHINDA

VIJAY KUMAR VERMA Male 37

27/03/2024 10:08:33 A

011-2253195, 9850242300, 9810778834