



Pathology Department

Patient's name : PARIKH TUSHAR
Age/Sex : 33 Years/Male
Referred by : MEDI WHEEL
Collection Time : 09:35

Reg. ID : P-6509-23
Accession : 23583
Order Dt/time : 08/03/2024 09:35

Complete Blood Count

Sample Type: EDTA

Test Name	Result	Units	Biological Reference Interval
<u>Blood Counts</u>			
Haemoglobin :	14.8	Gms%	13.5 - 18.0
Total R.B.C. :	5.23	mill/c.mm	4.7 - 6.0
Total W. B. C. :	8640	/cu mm	4000 - 10500
Platelet Count :	294000	/cu.mm	1,50,000 - 4,50,000
<u>Differential Count</u>			
Neutrophils :	67	%	40 - 70
Lymphocytes :	28	%	20 - 40
Eosinophils :	03	%	1 - 4
Monocytes :	02	%	2 - 6
Basophils :	00	%	0 - 01
<u>Blood Indices</u>			
P. C. V :	44.9	%	42 - 52
M. C. V. :	85.9	fL	78 - 100
M.C.H :	28.4	pg	27 - 31
M. C. H. C :	33.1	%	32 - 36
R.D.W :	13.2	%	11.5 - 14.0

E.S.R.(Westergren Method)

After one hour : 06 mm/hr 1 - 7

TESTS DONE ON FULLY AUTOMATED HEMATOLOGY ANALYZER.

Dr. Gayatri M. Mehita
M. D. (Patho)

Reg. No. G-32215
DR GAYATRI MEHTA
MD(PATHOLOGY)

DR. ANAND D. PARIKH
MD(PATHOLOGY)

LAB USE ONLY (Entered by : GM Enter Date/Time 08/03/2024 17:25:00) (Verify by : GM Verify Date/Time 08/03/2024 17:25:00)



Vidhi Diagnostics | Pathology Department

L-86, Swatantra Senani Nagar, Opp. Akhbarnagar Petrol Pump, Nr. Akhbarnagar Circle, Nava-Vadaj, Ahmedabad - 380 013.

M. - Pathology : 8849893954, Ph. : 079-27621406, M. 98799 29406, 98250 09406, E-mail : vidhidiagnostics@gmail.com, Web. : www.vidhidiagnostics.com

Time (Pathology) : Mon. to Sat. 8.30 am to 8.00 pm, Sunday 9 am to 12 Noon

Pathology means science behind medicine

CT SCAN & CBCT FACILITY NOW AVAILABLE



Pathology Department



Patient's name : PARIKH TUSHAR
Age/Sex : 33 Years/Male
Referred by : MEDI WHEEL
Collection Time : 09:35

Reg. ID : P-6509-23
Accession : 23583
Order Dt/time : 08/03/2024 09:35

Blood Group

Sample Type: EDTA sample.

Test Name	Result
BG :	" B "
RH :	POSITIVE
Remarks:	Done by forward grouping method.

Blood Glucose

Sample Type: Serum

Test Name	Result	Units	Biological Reference Interval
Fasting Blood Glucose :	99.4	mg/dl	70 - 110
Urine Sugar :	NIL		Absent
<i>GOD-POD Method.</i>			

Blood Glucose

Sample Type: Serum

Test Name	Result	Units	Biological Reference Interval
Post Prandial Blood Glucose After 2hr. :	125.9	mg/dl	80 - 140
Urine Sugar :	NIL		Absent
<i>GOD-POD Method.</i>			

Dr. Gayatri M. Mehta

M. D. (Patho)

DR GAYATRI MEHTA
MD(PATHOLOGY) G-32215

DR. ANAND D. PARIKH
MD(PATHOLOGY)

LAB USE ONLY (Entered by :GM Enter Date/Time:08/03/2024 17:26:00) (Verify by :GM Verify Date/Time:08/03/2024 17:26:00)



Vidhi Diagnostics | Pathology Department

L-86, Swatantra Senani Nagar, Opp. Akhbarnagar Petrol Pump, Nr. Akhbarnagar Circle, Nava-Vadaj, Ahmedabad - 380 013.

M. - Pathology : 8849803954, Ph. : 079-27621406, M. 98799 29406, 98250 09406, E-mail : vidhidiagnostics@gmail.com, Web. : www.vidhidiagnostics.com

Time (Pathology) : Mon. to Sat. 8.30 am to 8.00 pm, Sunday 9 am to 12 Noon

Pathology means science behind medicine

CT SCAN & CBCT FACILITY NOW AVAILABLE



Pathology Department



Patient's name : PARIKH TUSHAR
 Age/Sex : 33 Years/Male
 Referred by : MEDI WHEEL
 Collection Time : 09:35

Reg. ID : P-6509-23
 Accession : 23583
 Order Dt/time : 08/03/2024 09:35

Lipid Profile

Sample Type: Serum

Test Name	Result	Units	Biological Reference Interval
S. Cholesterol : <small>Oxidase-esterase method.</small>	188	mg/dl	0 - 200
S. Triglyceride : <small>Enzymatic Colorimetry method</small>	124.3	mg/dL	0 - 200
S. HDL - Cholesterol : <small>Serum by Enzymatic method.</small>	44.8	mg/dL	35 - 65
S. LDL - Cholesterol : <small>Serum by Enzymatic method</small>	118.34	mg/dL	0 - 130
S. VLDL - Cholesterol :	24.86	mg/dL	0 - 30
S. Chole/HDL.Ratio :	4.2		1 - 6
S. LDL / HDL Cholesterol Ratio :	2.64		0 - 3.5

Dr. Gayatri M. Mehta

M. D. (Patho)

Reg. No. G-32215

DR. GAYATRI MEHTA
 MD(PATHOLOGY)

DR. ANAND D. PARIKH
 MD(PATHOLOGY)

LAB USE ONLY (Entered by :GM Enter Date/Time:08/03/2024 17:26:00) (Verify by :GM Verify Date/Time:08/03/2024 17:26:00)



Vidhi Diagnostics | Pathology Department

L-86, Swatantra Senani Nagar, Opp. Akhbarnagar Petrol Pump, Nr. Akhbarnagar Circle, Nava-Vada, Ahmedabad - 380 013.

M. - Pathology : 8849893954, Ph. : 079-27621406, M. 98799 29406, 98250 09406, E-mail : vidhidiagnostics@gmail.com, Web. : www.vidhidiagnostics.com
 Time (Pathology) : Mon. to Sat. 8.30 am to 8.00 pm, Sunday 9 am to 12 Noon

Pathology means science behind medicine

CT SCAN & CBCT FACILITY NOW AVAILABLE



Pathology Department



Patient's name : PARIKH TUSHAR
Age/Sex : 33 Years/Male
Referred by : MEDI WHEEL
Collection Time : 09:35

Reg. ID : P-6509-23
Accession : 23583
Order Dt/time : 08/03/2024 09:35

HbA1C

Sample Type: EDTA

Test Name	Result	Units	Biological Reference Interval
HbA1C :	5.3	%	Non-diabetic: 4.2-6.2 Pre-diabetic : 6.3-7.2 Diabetic : 7.3-8.2
Mean Blood Glucose of Last 03 months.	105	mg/dl	

Comment *As per the new 2009 update of American Diabetes Association regarding HbA1C & Mean Blood Glucose relationship.
NOTE: This test is used to monitor diabetic patients compliance with the therapeutic regimen and logo It's level is proportional to both the average blood glucose concentration and the life span of the red blood cells (RBC) in circulation. HbA1c values are free of day to day glucose fluctuations and are unaffected by exercise or recent food intake.

Dr. Gayatri M. Mehta
M. D. (Patho)

Reg. No. G-32215

DR GAYATRI MEHTA
MD(PATHOLOGY)

DR. ANAND D. PARIKH
MD(PATHOLOGY)

LAB USE ONLY (Entered by :GM Enter Date/Time:08/03/2024 17:28:00) (Verify by :GM Verify Date/Time:08/03/2024 17:28:00)



Vidhi Diagnostics | Pathology Department

L-86, Swatantra Senani Nagar, Opp. Akhbarnagar Petrol Pump, Nr. Akhbarnagar Circle, Nava-Vadaj, Ahmedabad - 380 013.

M. - Pathology : 8849893954, Ph. : 079-27621406, M. 98799 29406, 98250 09406, E-mail : vidhidiagnostics@gmail.com, Web. : www.vidhidiagnostics.com
Time (Pathology) : Mon. to Sat. 8.30 am to 8.00 pm, Sunday 9 am to 12 Noon

Pathology means science behind medicine

CT SCAN & CBCT FACILITY NOW AVAILABLE



Pathology Department



Patient's name : PARIKH TUSHAR
 Age/Sex : 33 Years/Male
 Referred by : MEDI WHEEL
 Collection Time : 09:35

Reg. ID : P-6509-23
 Accession : 23583
 Order Dt/time : 08/03/2024 09:35

BIOCHEMISTRY

Sample type :Serum

Test Name	Result	Units	Biological Reference Interval
Urea, (Serum by GLDH method):	18.0	mg/dl	10 - 50
S.Uric acid, (Serum by Uricase method):	<u>9.0</u>	mg/dl	3.4 - 7.0
Bun :	8.4	mg/dl	6-20
Creatinine, (Serum by Enzymatic reaction):	0.76	mg/dl	0.5-1.2
S.G.P.T (ALT) : (Serum by IFCC method)	27.6	U/L	0 - 40
S.G.O.T (AST) : (Serum by IFCC method)	16.7	U/L	0 - 37
ALK.PHOSPHATASE : (Serum by PNP method)	90	U/L	40-129
G.G.T :	55.0	U/L	8 - 78
<u>BILIRUBIN</u>			
Total :	0.68	mg/dl	Up to 1.2
Direct :	0.28	mg/dl	0-0.7
Indirect :	0.4	mg/dl	0 - 0.5
<u>SERUM PROTEINS</u>			
Total Protein (Serum by Biuret method):	7.46	gms/dl	6.4 - 8.5
Albumin (Serum by BCG method):	4.24	gms/dl	3.97-4.94
Globulins :	3.22	gms/dl	2.3 - 3.5
A/G Ratio :	1.317		0.9 - 2.9

Dr. Gayatri M. Mehta
 M. D. (Patho)
 Reg. No. G-32215

DR GAYATRI MEHTA
 MD(PATHOLOGY)

DR. ANAND D. PARIKH
 MD(PATHOLOGY)

LAB USE ONLY (Entered by :GM Enter Date/Time:08/03/2024 17:25:00) (Verify by :GM Verify Date/Time:08/03/2024 17:25:00)



Vidhi Diagnostics | Pathology Department

L-86, Swatantra Senani Nagar, Opp. Akharnagar Petrol Pump, Nr. Akharnagar Circle, Nava-Vadaj, Ahmedabad - 380 013.

M. - Pathology : 8849893954, Ph. : 079-27621406, M. 98799 29406, 98250 09406, E-mail : vidhidiagnostics@gmail.com, Web. : www.vidhidiagnostics.com
 Time (Pathology) : Mon. to Sat. 8.30 am to 8.00 pm, Sunday 9 am to 12 Noon

Pathology means science behind medicine

CT SCAN & CBCT FACILITY NOW AVAILABLE



Pathology Department

VIDHI
DIAGNOSTICS



Patient's name : PARIKH TUSHAR
Age/Sex : 33 Years/Male
Referred by : MEDI WHEEL
Collection Time : 09:35

Reg. ID : P-6509-23
Accession : 23583
Order Dt/time : 08/03/2024 09:35

Thyroid Function Test

Sample Type: Serum

Test Name	Result	Units	Biological Reference Interval
TOTAL T3 :	1.80	ng/ml	1.1 - 1.84
TOTAL T4 :	11.50	µg/dL	6.09 - 12.23
TSH(Ultra sensitive) :	9.65	µIU/mL	0.4001 - 4.049

Dr. Gayatri M. Mehta
M. D. (Pathology)

Reg. No. G-32215
DR GAYATRI MEHTA
MD(PATHOLOGY)

DR. ANAND D. PARIKH
MD(PATHOLOGY)

LAB USE ONLY (Entered by :GM Enter Date/Time:08/03/2024 17:26:00) (Verify by :GM Verify Date/Time:08/03/2024 17:27:00)



Vidhi Diagnostics | Pathology Department

L-86, Swatantra Senani Nagar, Opp. Akharnagar Petrol Pump, Nr. Akharnagar Circle, Nava-Vadaj, Ahmedabad - 380 013.

M. - Pathology : 8849893954, Ph. : 079-27621406, M. 98799 29406, 98250 09406, E-mail : vidhidiagnostics@gmail.com, Web. : www.vidhidiagnostics.com
Time (Pathology) : Mon. to Sat. 8.30 am to 8.00 pm, Sunday 9 am to 12 Noon

Pathology means science behind medicine

CT SCAN & CBCT FACILITY NOW AVAILABLE



Patient's name : PARIKH TUSHAR
Age/Sex : 33 Years/Male
Referred by : MEDI WHEEL
Collection Time : 09:35

Reg. ID : P-6509-23
Accession : 23563
Order Dt/time : 08/03/2024 09:35

Urine Analysis

Sample Type: Urine

Test Name	Result	Units	Biological Reference Interval
Physical Examination			
Quantity :	30	ml	0 - 500 ml
Colour :	Yellow		Pale Yellow
Transparency :	Slight Turbid.		Clear
Reaction :	Acidic		4.6 - 8.0
Specific Gravity :	1.013		1.016 - 1.022
Sediment :	Present		
Chemical Examination			
Albumin :	Present (Faint Trace)		Absent
Sugar :	NIL		Absent
Acetone :	Absent		Absent
Bile Salts :	Absent		Absent
Bile Pigments :	Absent		Absent
Urobilogen :	Absent		Absent
Nitrites :	Absent		Absent
Microscopic Examination			
Red blood Cells :	Occasional	/h.p.f	Absent
Pus Cells :	2-3	/h.p.f	Absent
Epithelial Cells :	1-2	/h.p.f	< 10.0
Amorphous :	Absent	/h.p.f	Absent
Bacteria :	Absent	/h.p.f	Absent
Crystals :	Absent	/h.p.f	Absent
Casts :	Absent	/h.p.f	Absent
Fungus :	Not seen	/h.p.f	Absent

Dr. Gayatri M. Mehta
M. D. (Patho)

Reg. No. G-32215

DR GAYATRI MEHTA
MD(PATHOLOGY)

DR. ANAND D. PARIKH
MD(PATHOLOGY)



Generated by: GM Enter Date/Time: 08/03/2024 17:28:00 (Verify by: GM Verify Date/Time: 08/03/2024 17:28:00)

Vidhi Diagnostics | Pathology Department

L-86, Swatantra Senani Nagar, Opp. Akharnagar Petrol Pump, Nr. Akharnagar Circle, Nava-Vadaj, Ahmedabad - 380 013.

M. - Pathology : 8549893954, Ph. : 079-27621406, M. 98799 29406, 98250 09406. E-mail : vidhidiagnostics@gmail.com, Web. : www.vidhidiagnostics.com

Time (Pathology) : Mon. to Sat. 8.30 am to 8.00 pm, Sunday 9 am to 12 Noon

Pathology means science behind medicine

CT SCAN & CBCT FACILITY NOW AVAILABLE

Health Check up Booking Request(bobE12338), Beneficiary Code-133959

1 message

Mediwheel <wellness@mediwheel.in>

29 February 2024 at 18:02

To: vidhidiagnostics@gmail.com

Cc: customercare@mediwheel.in

**Mediwheel**
...Your wellness partner**011-41195959**

Dear VIDHI DIAGNOSTICS

We have received a booking request with the following details. Provide your confirmation by clicking on the Yes button.

You confirm this booking? Yes No**Name** : MR. PARIKH TUSHAR JASHVANTBHAI**Hospital Package Name** : Mediwheel Full Body Health Checkup Male Below 40**Name of Diagnostic/Hospital** : VIDHI DIAGNOSTICS**Address of Diagnostic/Hospital-** : L-86 Swatantra - Senani Nagar , Opp- Akhbarnagar Bus Terminals, New Wadaj , Ahmedabad -13**Appointment Date** : 08-03-2024**Member Information**

Booked Member Name	Age	Gender
MR. PARIKH TUSHAR JASHVANTBHAI	32 year	Male

Tests included in this Package -

- Stool Test
- Thyroid Profile
- ESR
- Blood Glucose (Fasting)
- General Physician Consultation
- TMT OR 2D ECHO
- Blood Group
- Blood Glucose (Post Prandial)
- Chest X-ray
- ECG
- USG Whole Abdomen
- Eye Check-up consultation
- Urine Sugar Fasting
- Urine Sugar PP
- Dental Consultation
- Urine analysis
- CBC
- HbA1c
- Lipid Profile
- Kidney Profile
- Liver profile



ભારત સરકાર
Government of India

ભારતીય વિશિષ્ટ ઓળખ પ્રાધિકરણ
Unique Identification Authority of India

નંબર / Enrollment No.: 0648/00146/22255


To
પરીખ તુષાર
Parikh Tushar
S/O. Jashvantbhai,
05, amardep bunglow,
hariom-3 motera, sabarmati,
VTC: Ahmedabad City,
PO: Sabarmati,
Sub District: Ahmadabad City, District: Ahmedabad,

65722060

State: Gujarat,
PIN Code: 380005,
Mobile: 9825012575



MF657220606F1



આપનો આધાર નંબર / Your Aadhaar No. :

3738 0099 4836

મારો આધાર, મારી ઓળખ



ભારત સરકાર
Government of India



Issue Date : 01/09/2012



પરીખ તુષાર
Pankh Tushar
જન્મ તારીખ / DOB : 06/02/1991
પુરુષ / Male

Vidhi Diagnostics
I-63, Sankhvi-Sarvani Nagar,
Opp. Akhbarnagar Bus Terminal,
Nr. Akhbarnagar Circle,
New Wadaj, Ahmedabad-13.

3738 0099 4836

મારો આધાર, મારી ઓળખ

માહિતી

- આધાર ઓળખનો પુરાવો છે, નાગરિકતાનો નથી.
- ઓળખ ચકાસવા માટે સુરક્ષિત QR કોડ / ઓફલાઇન XML / ઓનલાઇન પ્રમાણીકરણનો ઉપયોગ કરવો.

INFORMATION

- Aadhaar is a proof of identity, not of citizenship.
- Verify identity using Secure QR Code / Offline XML / Online Authentication.

- આધાર સમગ્ર દેશમાં માન્ય છે.
- આધાર આપને સરકારી અને બિન સરકારી વિવિધ સેવાઓને સરળતાથી મેળવવામાં મદદરૂપ થાય છે.
- આધારમાં તમારો મોબાઇલ નંબર અને ઈમેલ આઈડી અદ્યતન રાખો.
- તમારા સ્માર્ટફોનમાં આધાર રાખો - mAadhaar એપ્લિકેશનનો ઉપયોગ કરો.
- Aadhaar is valid throughout the country.
- Aadhaar helps you avail various Government and non-Government services easily.
- Keep your mobile number & email ID updated in Aadhaar.
- Carry Aadhaar in your smart phone – use mAadhaar App.




ભારતીય વિશિષ્ટ ઓળખ પ્રાધિકરણ
Unique Identification Authority of India



સરનામું: S/O: જશવંતભાઈ, 05, અમરદેપ
બંગલો, હરિઓમ-3 મોટેરા, સાબરમતી,
અમદાવાદ શહેર, અમદાવાદ, ગુજરાત,
380005

Print Date: 12/03/2021
Address: S/O: Jashvantbhai, 05, amardep
bungalow, hanom 3 motera, sabarmati,
Ahmedabad City, Ahmedabad, Gujarat,
380005



3738 0099 4836



1947



help@uidai.gov.in



www.uidai.gov.in

Tushar



Vidhi Diagnostics
L-86, Swatantra Senani Nagar,
Opp. Akhbarnagar Bus Terminala,
Nr. Akhbarnagar Circle,
New Wadaj, Ahmedabad-12

Dr. Dinesh S. Modh

M.D., D.M.R.E. (Radiodiagnosis)
Consultant Radiologist & Sonologist
Ex. Junior Lecturer, B.J. Medical College, Civil Hospital, A'bad.



08/03/2024

Pastikh Tushar
33 yr / male

Height! - 278 cm.

Weight! - 92 kg

BP! - 128/82 mmHg

Pulse! - 68 Per min

T! - @

Rg } @
Cvs }

SpO2! - 98

Asymptomatic

No H1O DM, HIV or TB

H1O Throid since 7yr

★ Eye check-up!

- Color vision! - Normal
- Distance! - 6/6 normal in eye
- Near! - 6/6 with Spectacles in left eye
- Near! - N/6.

★ Dental!

- oral Hygiene Normal
- No H1O Cavities & Caries is seen.

ADV! - He is medically fit

Vidhi Diagnostics

1st Floor, Swatantra Sarani Nagar,
Opp. Akhbarnagar Bus Terminal,
Nr. Akhbarnagar Circle,
L-86, Swatantra Sarani Nagar, Opp. 100 Gallan Oil Petrol Pump, Akhbarnagar Circle, Nava Vada, Ahmedabad - 380 013.

Dr. Vidhi D. Modh
MBBS
Reg. No.: G-74540

Phone : (Radiology) 079-2762 1406 | M. 98799 29406, 98250 09406 | Time (Radiology) : Mon. to Sat. 9 am to 2 pm, 5 to 9 pm, Sunday 9 am to 12 Noon
E-mail : vidhidiagnostics@gmail.com, Website : www.vidhidiagnostics.com

Multislice CT Scan | CBCT-Dental Scan | Live 3D-4D Sonography | Colour Doppler | Echo Cardiography | Interventional Radiology | Maxillofacial Radiology | Fetal Medicine
Digital X-Ray | Digital Mammography | Digital DPG/TMJ | ECG/TMT/PFT/EEG/EMG | Audiometry | Pathology Laboratory | Health Check Up Plans | Pre Employment Check Up

CT SCAN & CBCT FACILITY NOW AVAILABLE

HR : 69 bpm
 PR : 120 ms
 QRS : 102 ms
 QT/QTc : 374/400 ms
 PQRS/T : 34/-62 deg
 RV5/SV1 : 1.820/-0.349 mv
 RV5+SV1 : 2.169 mv

ID: 12891

Name: Ishaq Parikh

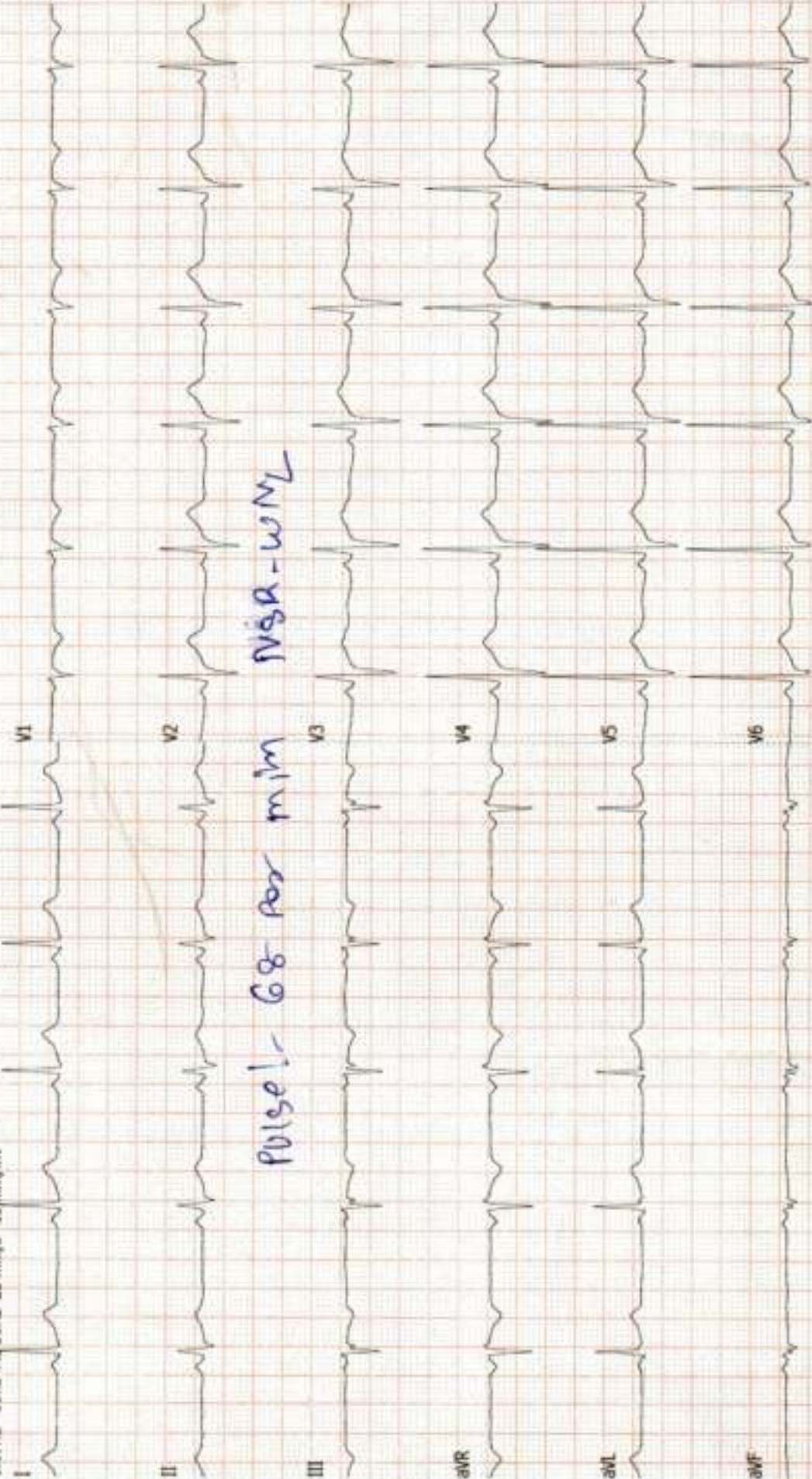Age: 33yrs

Sex: Male

Hospital:

Department:

0.67Hz - 35Hz AC 50Hz 25 mm/s 10 mm/mv



Need to be confirmed by doctor. Doctor Name: _____

Vidhi Diagnostics

L-65, Symbiosis-Secund Nagar,
 Opp. Akbarnagar Bus Terminal,
 Nr. Akbarnagar Circle,
 New Wadi, Ahmedabad-13.

Dr. Avinash Parikh
 MBBS DCC
 G-4594G

Dr. Dinesh S. Modh

M.D., D.M.R.E. (Radiodiagnosis)
Consultant Radiologist & Sonologist
Ex. Junior Lecturer, B.J. Medical College, Civil Hospital, Abad.



Patient's name : PARIKH TUSHAR
Reg. ID : R-14091-23
Referred by : MEDI WHEEL

Age/Sex : 33 Years/Male
Accession : 23593
Date : 08/03/2024

2D- ECHO REPORT

FINAL CONCLUSION:

LV IS NORMAL SIZE. GOOD LV SYSTOLIC FUNCTION NO RWMA.
LVEF - 60%. NO CONCENTRIC LVH.
NORMAL LV COMPLIANCE.
LA IS NORMAL SIZE. NO LA CLOT.
RV IS NORMAL SIZE. GOOD RV SYSTOLIC FUNCTION.
RA IS NORMAL SIZE.
MITRAL VALVE IS NORMAL. NO MS. MILD MR (10%). NO MVP.
AORTIC VALVE IS NORMAL. NO AS. NO AR.
TRICUSPID VALVE IS NORMAL. NO TR. RVSP-20 mmHg. NO PAH.

NO CLOT, NO VEGETATION, NO PERICARDIAL EFFUSION.

DIMENSIONS:

AORTA	2.5 C.M
LEFT ATRIUM	2.6 C.M
LVDD	4.0 C.M.
IVSD	1.0 C.M
PWD	1.0 C.M
LVDS	2.6 C.M.

COLOUR DOPPLER FINDING:

STRUCTURE	VELOCITY m/sec
	Max
PULMONARY VALVE	0.7
MITRAL VALVE	E : 0.8 A: 0.5
AORTIC VALVE	1.0


Dr. Avinash Bhaskar
MBBS D-Cardio
G-45946

DR AVINASH BHASKAR
CLINICAL CARDIOLOGIST
9924836431

ISO 9001:2015 Certified Diagnostics Center

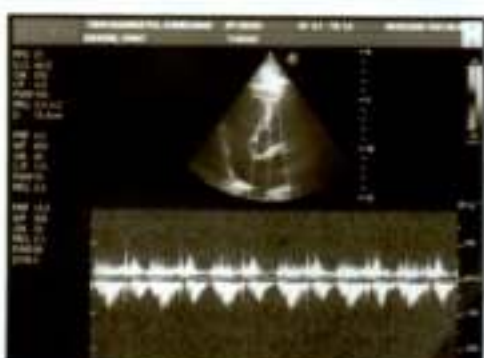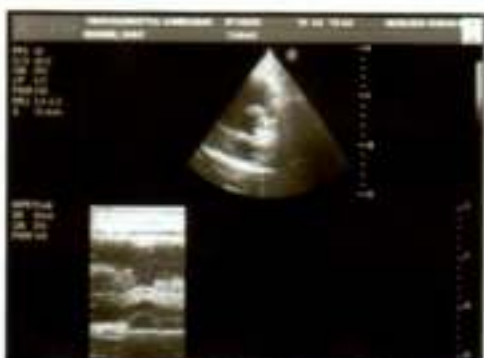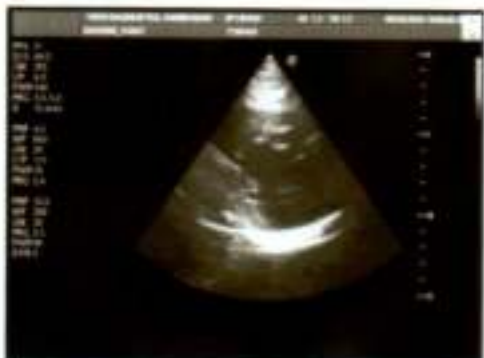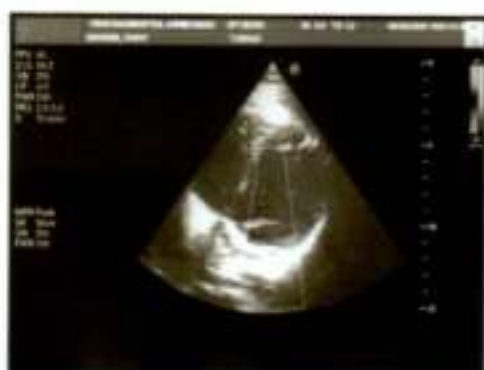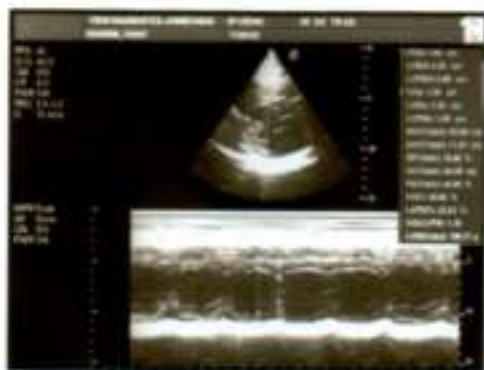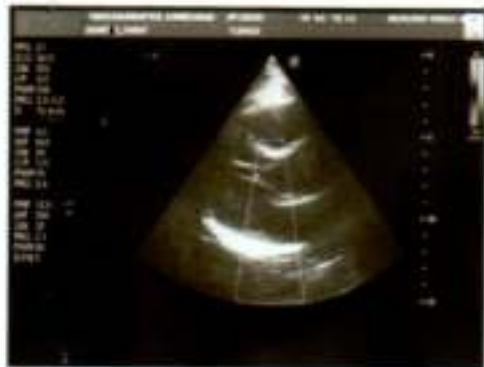Vidhi Imaging Center

L-86, Swatantra Senani Nagar, Opp. Indian Oil Petrol Pump, Akhbarnagar Circle, Nava Vada, Ahmedabad - 380 013.

Phone : (Radiology) 079-2762 1406 | M. 98799 29406, 98250 09406 | Time (Radiology) : Mon. to Sat. 9 am to 2 pm, 5 to 9 pm, Sunday 9 am to 12 Noon
E-mail : vidhidiagnostics@gmail.com, Website : www.vidhidiagnostics.com

Multislice CT Scan | CBCT-Dental Scan | Live 3D-4D Sonography | Colour Doppler | Echo Cardiography | Interventional Radiology | Maxillofacial Radiology | Fetal Medicine
Digital X-Ray | Digital Mammography | Digital OPG / TMJ | ECG / TMT / PFT / EEG / EMG | Audiometry | Pathology Laboratory | Health Check Up Plans | Pre Employment Check Up

CT SCAN & CBCT FACILITY NOW AVAILABLE



Dr. Dinesh S. Modh

M.D., D.M.R.E. (Radiodiagnosis)

Consultant Radiologist & Sonologist

Ex. Junior Lecturer, B.J. Medical College, Civil Hospital, A'bad.

VIDHI
DIAGNOSTICS



Patient's name : PARIKH TUSHAR
Reg. ID : R-14091-23
Referred by : MEDI WHEEL

Age/Sex : 33 Years/Male
Accession : 23593
Date : 08/03/2024

USG ABDOMEN

LIVER: Liver is normal in size and bright in echotexture s/o fatty liver grade1. Intrahepatic biliary radicals appear normal.

Portal vein is normal in caliber. Common Bile duct is normal in course & caliber. No e/o calculus is seen in biliary tree.

GALL BLADDER: is distended & appear normal. No e/o calculus or cholecystitis is seen. GB wall thickness appears normal. No evidence of pericholecystic fluid is seen.

SPLEEN: Spleen is normal in size & shows normal echo texture. No evidence of diffuse or focal lesion is seen. Splenic vein appears normal.

PANCREAS: Pancreas appears normal in size & echotexture. No evidence of diffuse or focal lesion is seen. Main pancreatic duct is normal.

KIDNEY: Both kidneys appear normal in size and echopattern. Corticomedullary differentiation is maintained.

No evidence of calculus or hydronephrosis is seen on both sides.

Both supra renal region appear normal.

No evidence of pre & para aortic lymphadenopathy is seen.

Gas filled non-dilated bowel loops are seen in abdomen.

No evidence of free fluid is seen in abdomen.

No evidence of dilated or thickened bowel loops is seen.

Urinary bladder appears normal. No e/o calculus or mass lesion is seen.

Prostate appears normal in size & echopattern.

Thanks for reference.

Dr. Dinesh S. Modh
MD DMRE (Radiodiagnosis)

G-23825

DR DINESH S. MODH

M.D. DMRE(RADIODIAGNOSIS)

ISO 9001:2015 Certified Diagnostics Center

Vidhi Imaging Center

L-86, Swatantra Senani Nagar, Opp. Indian Oil Petrol Pump, Akhbaragar Circle, **Nava Vadaj**, Ahmedabad - 380 013.

Phone : (Radiology) 079-2762 1406 | M. 98799 29406, 98250 09406 | Time (Radiology) : Mon. to Sat. 9 am to 2 pm, 5 to 9 pm, Sunday 9 am to 12 Noon

E-mail : vidhidiagnostics@gmail.com, Website : www.vidhidiagnostics.com

Multislice CT Scan | CBCT-Dental Scan | Live 3D-4D Sonography | Colour Doppler | Echo Cardiography | Interventional Radiology | Maxillofacial Radiology | Fetal Medicine
Digital X-Ray | Digital Mammography | Digital DPG/TMJ | ECG/TMT/PFT/EEG/EMG | Audiometry | Pathology Laboratory | Health Check Up Plans | Pre Employment Check Up

CT SCAN & CBCT FACILITY NOW AVAILABLE

Dr. Dinesh S. Modh

M.D., D.M.R.E. (Radiodiagnosis)

Consultant Radiologist & Sonologist

Ex. Junior Lecturer, B.J. Medical College, Civil Hospital, A'bad.

VIDHI
DIAGNOSTICS

Creating Life in Images

Patient's name : PARIKH TUSHAR
Reg. ID : R-14091-23
Referred by : MEDI WHEEL

Age/Sex : 33 Years/Male
Accession : 23593
Date : 08/03/2024

X-RAY CHEST (PA VIEW)

Both lung fields appear normal.
No e/o consolidation or cavitations is seen.
Both costo-phrenic angles appear clear.
Cardiac size is with in normal limits.
Both domes of diaphragm appear normal.
Bony thoracic cage appears normal.

Thanks for reference.

Dr. Dinesh S. Modh
MD DMRE (Radiodiagnosis)

DR DINESH S. MODH

M.D. DMRE(RADIODIAGNOSIS)

ISO 9001:2015 Certified Diagnostics Center

Vidhi Imaging Center

L-86, Swatantra Senani Nagar, Opp. Indian Oil Petrol Pump, Akhbarnagar Circle, Nava Vadaaj, Ahmedabad - 380 013.

Phone : (Radiology) 079-2762 1406 | M. 98799 29406, 98250 09406 | Time (Radiology) : Mon. to Sat. 9 am to 2 pm, 5 to 9 pm, Sunday 9 am to 12 Noon

E-mail : vidhidiagnostics@gmail.com, Website : www.vidhidiagnostics.com

Multislice CT Scan | CBCT-Dental Scan | Live 3D-4D Sonography | Colour Doppler | Echo Cardiography | Interventional Radiology | Maxillofacial Radiology | Fetal Medicine
Digital X-Ray | Digital Mammography | Digital DPG / TMJ | ECG / TMT / PFT / EEG / EMG | Audiometry | Pathology Laboratory | Health Check Up Plans | Pre Employment Check Up

CT SCAN & CBCT FACILITY NOW AVAILABLE