



## BANK OF BARODA MEDICAL EXAMINATION REPORT

Client name :- Sneha Sharma

Ref. No. :- .....

Date of birth :- 07.08.1997 Sex :- Male /  Female

Identification mark on the body :- Birth mark of left fore arm.

Photo ID Xerox :- Adhar Nr. 3349 8649 8629

Date & place of medical examination :- 08.09.21 As.

Request for medical exam. of **BANK OF BARODA** through Medi Assist Health Care India (Pvt.) Ltd.

- A) 1. Height :- 164 cm.                      2. Weight :- 87 kgs.  
 3. Chest Inspiration :- 103 cm.      4. Chest Expiration :- 101 cm.  
 5. Abdomen Girth :- 86 cm.  
 6. Blood Pressure :- I) ..... mm. of Hg. II) ..... mm. of Hg.  
 7. Pulse Rate :- ..... / minute.      Character of pulse :- 74

- B) 1. Are you now in good health ? ..... Yes  
 2. Are you currently taking any medicine ? ..... No  
 3.) Are you married ? ..... Yes  
 4. Have you ever had a positive test for HIV / AIDS / Malignancy ? ..... No  
 5. Have you ever suffering from sexually transmitted disease or Hepatitis B or C ?  
 ..... No  
 6. Have you any congenital disorders ? ..... No  
 7. Have you any respiratory disorders ? ..... No  
 8. Have you any musculo skeletal disorders ? ..... No  
 9. Have you CVS disorders ? ..... No  
 10. Have you GI system disorders ? ..... No  
 11. Have you urinary system disorders ? ..... No  
 12. Have you reproductive system disorders ? ..... No



# ANUBIKSHAN

Diagnostic Centre

Near Asansol District Hospital(Main Gate)  
S.B. Gorai Road, Asansol-713301  
Email ID : anubikshan.dc@gmail.com  
Ph. : 0341-2221195, M. : 9732362727, 7872772680



ANUBIKSHAN DIAGNOSTIC CENTRE ANUBIKSHAN DIAGNOSTIC CENTRE ANUBIKSHAN DIAGNOSTIC CENTRE  
ANUBIKSHAN DIAGNOSTIC CENTRE ANUBIKSHAN DIAGNOSTIC CENTRE ANUBIKSHAN DIAGNOSTIC CENTRE  
ANUBIKSHAN DIAGNOSTIC CENTRE ANUBIKSHAN DIAGNOSTIC CENTRE ANUBIKSHAN DIAGNOSTIC CENTRE  
ANUBIKSHAN DIAGNOSTIC CENTRE ANUBIKSHAN DIAGNOSTIC CENTRE ANUBIKSHAN DIAGNOSTIC CENTRE  
ANUBIKSHAN DIAGNOSTIC CENTRE ANUBIKSHAN DIAGNOSTIC CENTRE ANUBIKSHAN DIAGNOSTIC CENTRE  
ANUBIKSHAN DIAGNOSTIC CENTRE ANUBIKSHAN DIAGNOSTIC CENTRE ANUBIKSHAN DIAGNOSTIC CENTRE

- 13. Have you Diabetes / Hypertension / Endocrine disorders? ..... NO
- 14. Have you ever done any surgical operation? ..... NO
- 15. Have you any ear problem? ..... NO
- 16. Have you any eye problem? ..... NO
- 17. Have you nervous system disorders? ..... NO
- 18. Have you any abnormal growth? ..... NO
- 19. Have you any blood disorders? ..... NO
- 20. What is general appearance of the client? ..... Healthy
- 21. Does the appearance correspond with the age? ..... Yes
- 22. Is there any personal peculiarities? ..... NO
- 23. Tobacco (Stick / gms)- Panmasala/Cigar / Cigarette / Bidi / Gutkha Yes No  
Alcohol (ml)- Beer / Wine / Hard Liquor :- Qty./ Day For No. of Yrs

24. Family History	Age if living	Age at death	Present state of health or cause of death
Father	54Y	Alm	
Mother	48Y	Alm	
Brother (s)	21Y,	Alm	
Sister (s)	✓		

25. ANY REMARK BY THE MEDICAL EXAMINAR: - On US G report show hepatosplenomegaly and cholelithiasis other are normal. Adv. Surgeon consultation

Sneha Sharma  
Signature of the Client

Sanjeev Shah  
Name of the Doctor  
Sanjeev Shah 08/9/21  
Dr. Sanjeev Kevin Shah  
M.B.B.S., MD (Med.)  
Reg. No. 16138  
Signature & Seal of the Doctor

Date: - 08.9.21

Dr. Sanjeev Kevin Shah  
M.B.B.S., MD (Med.)  
Reg. No. 16138  
08/09/21

*Signature*

*Sanjeev Shah*



भारतीय विश्वविद्यालय परिषद  
भारत सरकार  
Liquor Identification Authority of India  
Government of India

Enrollment No. 10261313403024

To:  
Sonia Sharma  
SAC, Sobor, Dharma  
NEARATEPUR  
TARANAD WARD, TEMAR  
Kath (M)  
Sudhanshu Bandopadhyay, Bhabhanagar  
West Bengal 711005

REGISTRATION No. 10261313403024  
SE:38251745577

भारत आभार भारता आभार  
3349 8649 8629

आभार - आम आदमी का अधिकार

आभार - आम आदमी का अधिकार

3349 8649 8629

आभार - आम आदमी का अधिकार

# Dr. Rajib Banerjee

B.Sc., B.H.M.S., DOS (Kol)  
Consultant Homoeopathic Physician  
and optometric Eye Specialist

## ADDRESS :

1 No. Mohishila Colony  
Bottala Bazar  
Asansol - 3  
Mob. : 9832197360

Rx

Sneha Sharma

Rt. Eye		Lt. Eye	
Sph	Cyl	Sph	Cyl
0	0	0	↑
Near Add. →	0	Near Add. →	0

VA  $\leftarrow$  6/6  
VA  $\leftarrow$  6/6

Near vision - Normal

CV - Normal

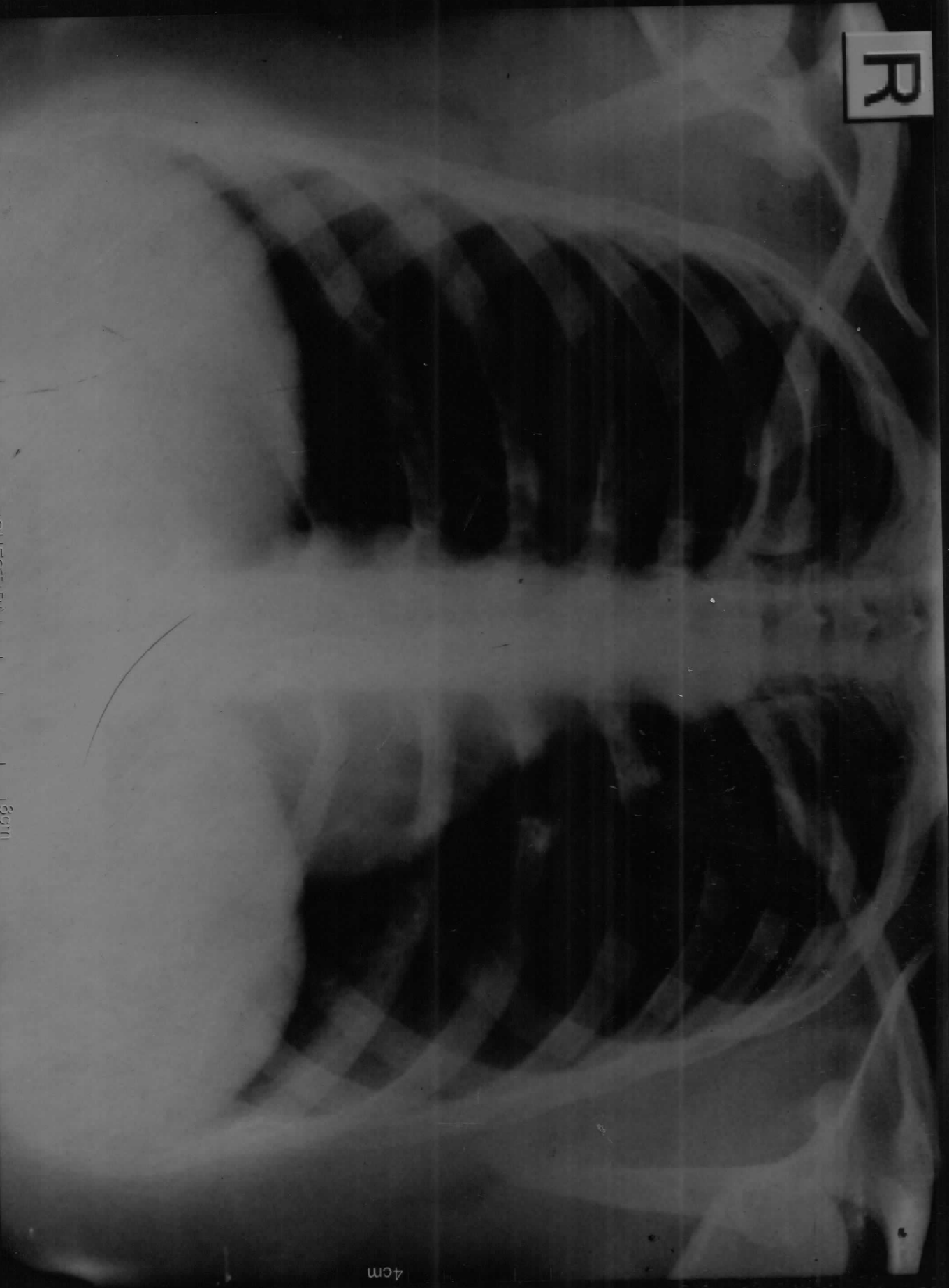
*[Signature]*  
8/9/21



**Chamber**  
Balananda Homoeo Clinic  
Khejurtala More  
Mohishila - 2, Asansol

Morning : 8.00 a.m. to 9.00 a.m.  
Evening : 6.00 p.m. to 9.30 p.m.  
Saturday Evening Closed  
& Sunday Morning Closed

R



CHEST/PAL 3911

4cm

ACCNO003764

SNEHA SHARMA 24 YRS Female

SELF

NEW ASANSOL X-RAY CLINIC MOB -9434236862

10:37:14 AM  
DATE:-08-09-2021



PATIENT'S NAME: - SNEHA SHARMA

AGE: - 24 YEAR

SEX: - FEMALE

REF. BY DR.: - M.O.BANK OF BARODA.

DATE: - 08-09-2021

## REPORT

### CHEST X - RAY P A VIEW

Soft tissue around chest and bony cage --- normal.

No active lung lesion in either field.

Cardiac configuration normal.

Pleural recesses are clear.

## I M P R E S T I O N

✓ **NORMAL SKIAGRAM OF CHEST.**

### ADVICE

Clinical co-relation.

DR. DIPANKAR DASGUPTA.

(M.B.B.S., D.M.R.D)

(Regd.No:- WB-34374)



PATIENT'S NAME:- SNEHA SHARMA	AGE:- 24 YEAR	SEX:- FEMALE
REF. BY DR.:- M.O.BANK OF BARODA.	DATE :- 08-09-2021	

## U. S. G. OF WHOLE ABDOMEN

### LIVER

Marginally enlarged with fatty changes. (Measure: - 134.79 mm.)

### PORTA

Portal vein at porta hepatis measures:- 5.98 mm. in diameter.  
The appearance of porta is normal.

### GALL BLADDER

An echogenic calculus noted in lumen of gall bladder. (Measure: - 11.29 mm).

### COMMON BILEDUCT

Common bile duct is not dilated (1.54 mm.)  
No calculus or any intraluminal echogenicity.

### PANCREAS

Normal echo-texture of the pancreas is seen. No space occupying lesion is seen.  
Its relation with the anatomical landmark is normal.

### SPLEEN

Enlarged. (Measure:- 125.60 mm.)

### KIDNEYS

Both the kidneys are normal in shape, size, margin and axis.  
Cortico medullary differentiation is normal.  
No calculi or any hydronephrotic changes noted.  
(Rt. Kidney Measure:- 99.11 mm. and Lt. Kidney Measure:- 111.66 mm. in length.)

### URINARY BLADDER

Normal shape and size of the urinary bladder is seen.  
No intraluminal echo is noted.

### UTERUS

A/V, Bulky. (Measure:- 90.58 mm. x 42.16 mm. x 45.29 mm.)

### OVARIES

Normal shape and size of the ovaries are seen. Normal echo texture is seen.  
No space occupying lesion is seen in the ovaries.  
(Right ovary Measure: - 38.77 mm. x 32.18 mm.)  
(Left ovary Measure: - 35.68 mm. x 23.62 mm.)

### ➤ IMPRESSION :-

- ❖ HEPATOSPLENOMEGALY.
- ❖ CHOLELITHIASIS.

#### ADVICE

Clinical co-relation.

**DR. DIPANKAR DASGUPTA.**  
(M.B.B.S., D.M.R.D)  
(Regd.No:- WB-34374)

**PATIENT'S NAME :- SNEHA SHARMA**

**AGE:- 24 YEAR      SEX:- FEMALE**

**REF BY DR:- M.O. BANK OF BARODA**

**DATE:- 08-09-2021**

**U.S.G. OF WHOLE ABDOMEN**

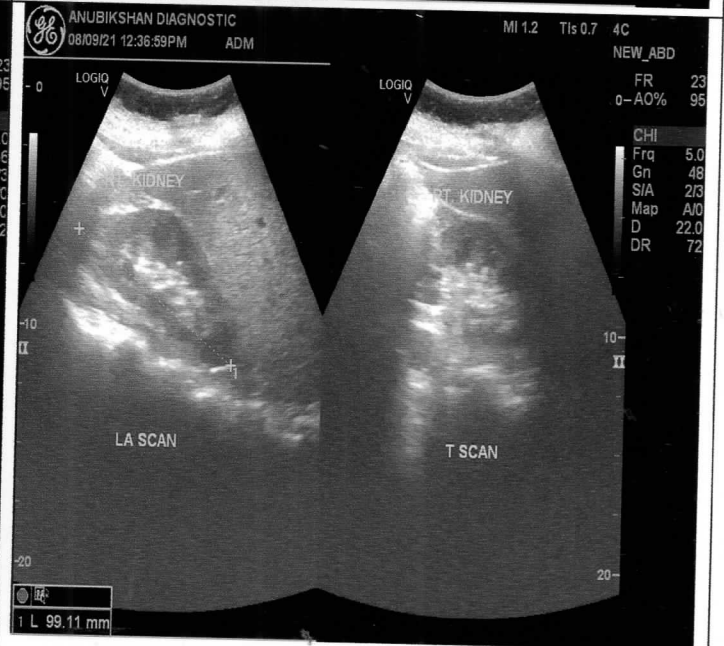
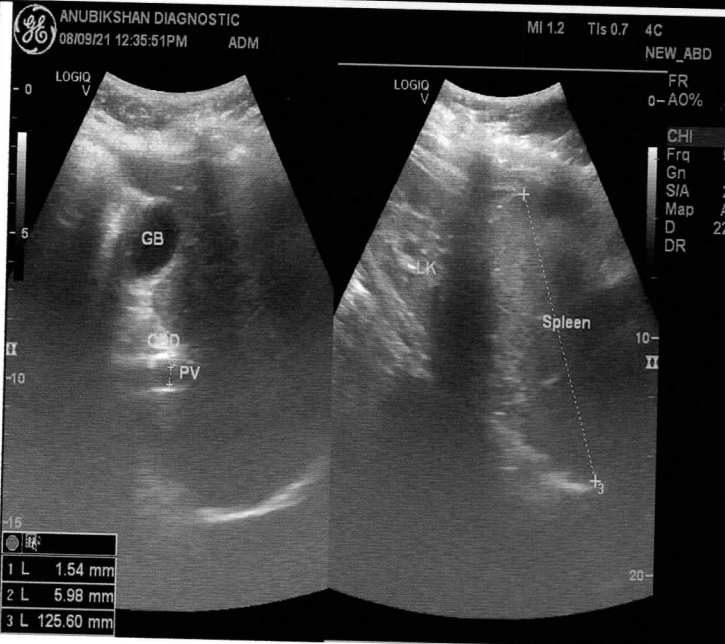
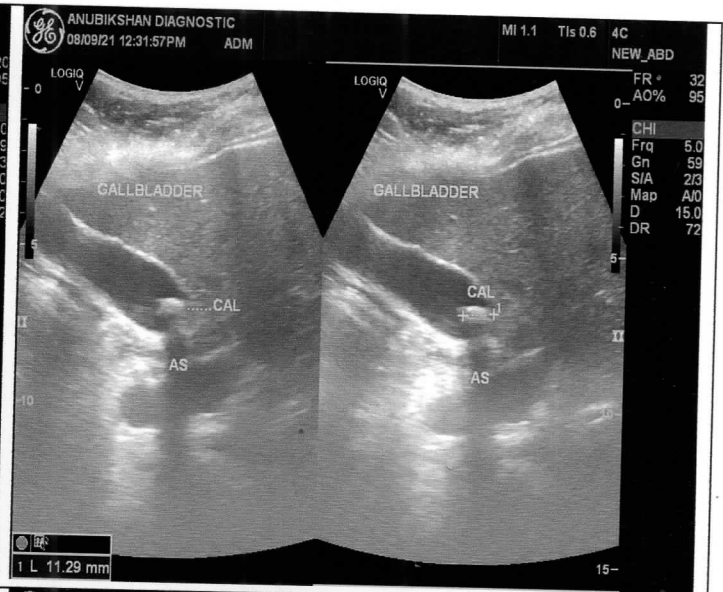
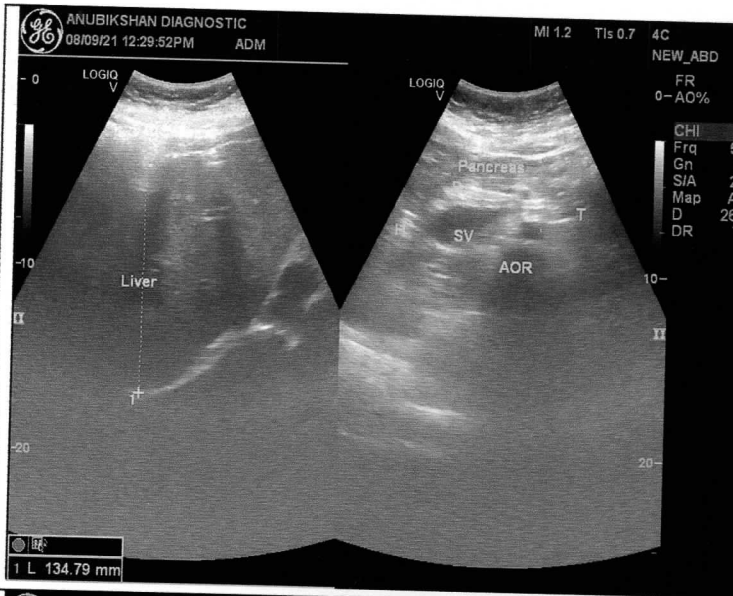
# **ANUBIKSHAN**

## **DIAGNOSTIC CENTRE**

**NEAR ASANSOL DISTRICT HOSPITAL (MAIN GATE)  
S.B.GORAI ROAD (EAST), PIN - 713301**

**LANDLINE:- 0341-3590332 // MOB - 7872772680**

**E- mail ID: - anubikshan.dc @ gmail.com      (1)**





**PATIENT'S NAME :- SNEHA SHARMA**

**AGE:- 24 YEAR    SEX:- FEMALE**

**REF BY DR:- M.O. BANK OF BARODA**

**DATE:- 08-09-2021**

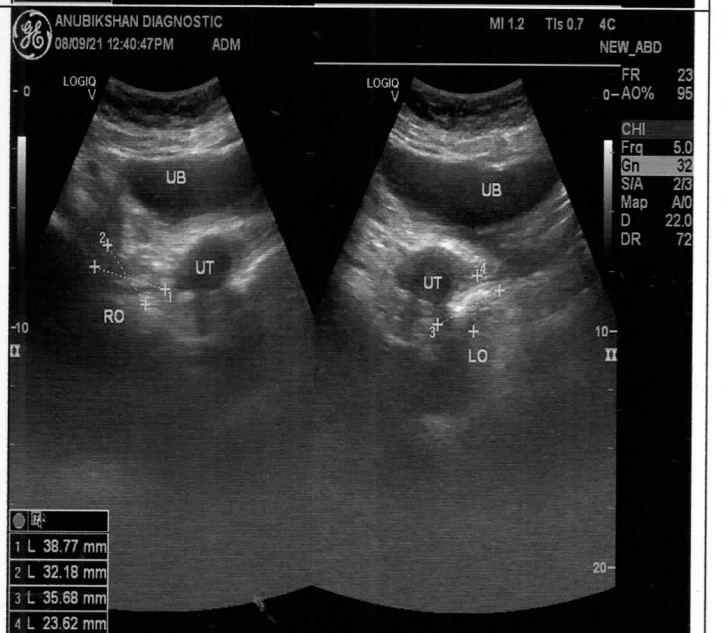
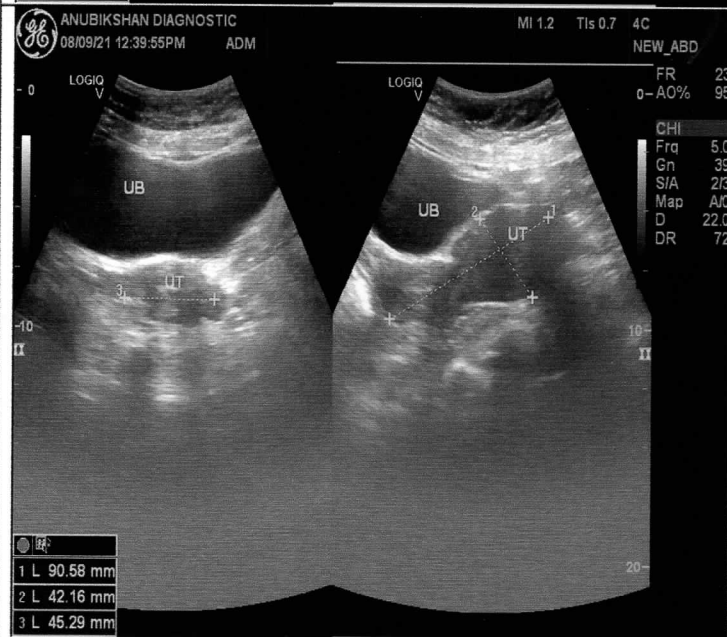
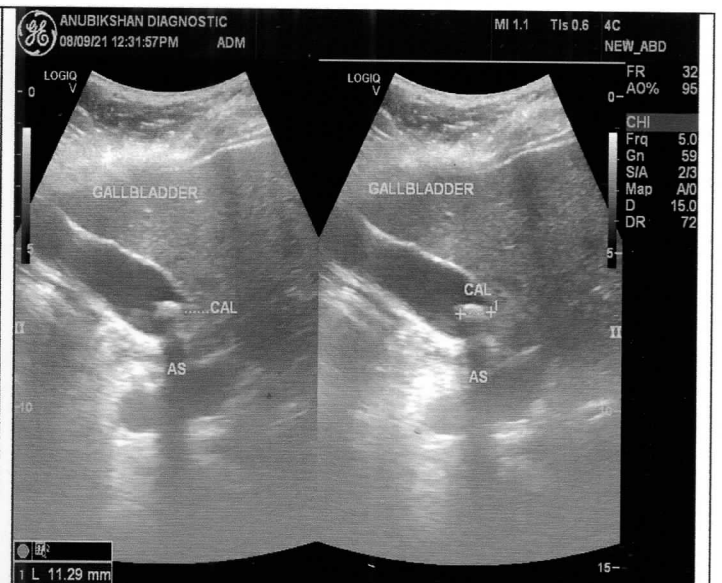
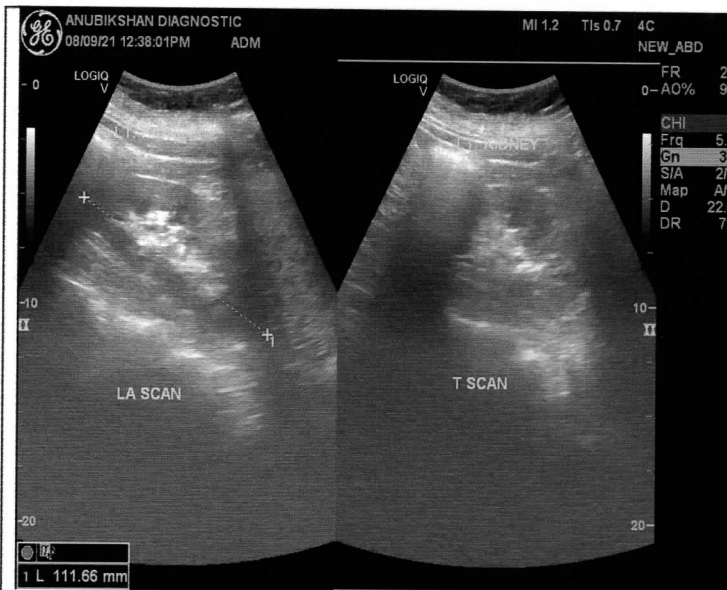
**U.S.G. OF WHOLE ABDOMEN**

# **ANUBIKSHAN** **DIAGNOSTIC CENTRE**

**NEAR ASANSOL DISTRICT HOSPITAL (MAIN GATE)  
S.B.GORAI ROAD (EAST), PIN - 713301**

**LANDLINE: - 0341-3590332 // MOB - 7872772680**

**E- mail ID: - anubikshan.dc @ gmail.com    (2)**





# ANUBIKSHAN

Diagnostic Centre

Near Asansol District Hospital (Main Gate)  
S.B. Gorai Road, Asansol-713301  
Email ID : anubikshan.dc@gmail.com  
website: www.anubikshan.com

PATIENT ID: 2021I3331 NAME: SNEHA SHARMA AGE: 24 YR FEMALE  
ADVISED BY: Dr. M.O. BANK OF BARODA, .  
DATE OF RECEIPT : 08/09/2021 DELIVERY DATE : 08/09/2021 TIME : 07:00 PM

## HEAMATOLOGY TEST

TEST	RESULT	NORMAL RANGE
* Haemoglobin :-	12.6 gm/dl	12 - 16 gm/dl
* Total Leucocyte Count :-	6,600 /cu mm	4,000-11,000/cu mm
* Differential Leucocyte Count ::		
* -----		
Neutrophil	60 %	40-75%
Lymphocyte	34 %	20-45%
Monocyte	01 %	2-10%
Eosinophil	05 %	1-6%
Basophil	00 %	0-1%
* Erythrocyte Sedimentation	12 mm / 1st hour	Less than 15 mm (M) Less than 20 mm (F)
* P. C. V.	46 %	45.0-50.0% (M) 37.0-47.0% (F)
* M. C. V.	92.0 fl.	77-93 fl
* M. C. H.	25.2 pg.	27.0-32.0 pg
* M.C.H.C.	27.4 gm/dl.	31.0-35.0 gm/dl
* Platelet Count	2,12,000 /cu mm	1.5 - 4.0Lakh/cu mm
* R. B. C.	5.0 million/cu mm	6.0-8.0million/cu mm(M) 3.8-5.8million/cu mm(F)

All Reference ranges are age and sex matched. Reference limit mentioned herein are in accordance with the literature provided along with the kit. Which may change in chemistry or the kit.

DR. APARNA MONDAL.  
M.B.B.S., M.D (Pathology)  
(Regd. No. 57881)



# ANUBIKSHAN

Diagnostic Centre

Near Asansol District Hospital (Main Gate)  
S.B. Gorai Road, Asansol-713301  
Email ID : anubikshan.dc@gmail.com  
website: www.anubikshan.com

PATIENT ID: 2021I3331 NAME: SNEHA SHARMA AGE: 24 YR FEMALE  
ADVISED BY: Dr. M.O. BANK OF BARODA,  
DATE OF RECEIPT : 08/09/2021 DELIVERY DATE : 08/09/2021 TIME : 07:00 PM

## BIO CHEMISTRY REPORT

TEST	RESULT	NORMAL RANGE
Plasma Glucose (Fasting)	97.6 mg/dl	70 - 115 mg/dl
Plasma Glucose (P.P)	DUE SAMPLE	80 - 150 mg/dl.
Cholesterol	130.0 mg/dl	00 - 200 mg/dl
Triglyceride	75.0 mg/dl	0 - 200 mg/dl
HDL Cholesterol	35.0 mg/dl	40 - 90.0 mg/dl
LDL Cholesterol	80.0 mg/dl	00 - 130 mg/dl
V.L.D.L.	15.0 mg/dl	23 - 45 mg/dl
CHOLESTEROL/HDL RATIO	3.7 : 1	upto . - 5.0
LDL/HDL RATIO	2.3 : 1	upto - 3.0
Creatinine	0.82 mg/dl	0.7 - 1.4 mg/dl
B.U.N.	15.0 mg/dl	5.0 - 21.0 mg/dl
Uric-Acid	3.2 mg/dl	2.6 mg/dl - 6.0 mg/dl
Serum Bilirubin (Total)	0.82 mg/dl	0.1 - 1.2 mg/dl
Serum Bilirubin (Direct)	0.36 mg/dl	0.0 - 0.4 mg/dl
Serum Bilirubin (Indirect)	0.46 mg/dl	UPTO - 0.8 mg/dl

All biochemistry done by fully automated system Diasys respons 910.

All Reference ranges are age and sex matched. Reference limit mentioned herein are in accordance with the literature provided along with the kit. Which may change in chemistry or the kit.

DR. APARNA MONDAL.  
M.B.B.S., M.D (Pathology)  
(Regd. No. 57881)

Phone : 0341-2221195, Mobile : 9732362727, 7872772680



# ANUBIKSHAN

Diagnostic Centre

Near Asansol District Hospital(Main Gate)  
S.B. Gorai Road, Asansol-713301  
Email ID : anubikshan.dc@gmail.com  
website: www.anubikshan.com

PATIENT ID: 2021I3331 NAME: SNEHA SHARMA AGE: 24 YR FEMALE  
ADVISED BY: Dr. M.O. BANK OF BARODA, .  
DATE OF RECEIPT : 08/09/2021 DELIVERY DATE : 08/09/2021 TIME : 07:00 PM

## BIO CHEMISTRY REPORT

TEST	RESULT	NORMAL RANGE
S.G.P.T	57.2 U/L	00 - - 35.0 U/L
S.G.O.T	35.4 U/L	00 - 31.0 U/L
Alkaline Phosphatase	75.6 U/L	35 - 105 U/L
Total Protein	7.6 gm/dl	6.6 - 8.8 gm/dl
Albumin	4.4 gm/dl	3.5 - 5.2 gm/dl
Globulin	3.2 gm/dl	2.3 - 3.5 gm/dl
A : G	1.2:1	upto - 2.5:1
G.G.T	24.6 U/L	00 - 38 U/L

All biochemistry done by fully automated system Diasys respons 910.

All Reference ranges are age and sex matched. Reference limit mentioned herein are in accordance with the literature provided along with the kit. Which may change in chemistry or the kit.

DR. APARNA MONDAL.  
M.B.B.S., M.D (Pathology)  
(Regd. No. 57881)



# ANUBIKSHAN

Diagnostic Centre

Near Asansol District Hospital(Main Gate)  
S.B. Gorai Road, Asansol-713301  
Email ID : anubikshan.dc@gmail.com  
website: www.anubikshan.com

PATIENT ID:2021I3334 NAME: SNEHA SHARMA AGE:24 YR FEMALE  
ADVISED BY:Dr. M.O. BANK OF BARODA, .  
DATE OF RECEIPT : 08/09/2021 DELIVERY DATE : 08/09/2021 TIME : 07:00 PM

## REPORT ON BLOOD GROUP & Rh

TEST	RESULT	NORMAL RANGE
BLOOD GROUP	"AB"	
RH Factor	"POSITIVE"	

All Reference ranges are age and sex matched. Reference limit mentioned herein are in accordance with the literature provided along with the kit. Which may change in chemistry or the kit.

DR. APARNA RONDAL  
M.B.B.S., M.D (Pathology)  
(Regd. No. 57881)



Pathology Department

REPORT ON EXAMINATION OF

**GLYCOSYLATED HEMOGLOBIN**

PATIENT'S NAME: - SNEHA SHARMA

AGE :- 24 YEAR

SEX:- FEMALE

REF. BY DR.:- M.O. BANK OF BARODA

DATE:- 08-09-2021

**HbA1C**

<u>TEST</u>	<u>RESULT</u>	<u>NORMAL RANGE</u>
HbA1C	4.4 %	NON-DIABETIC - (<6%)
		GOOD CONTROL-(6.0%-7%)
		FAIR CONTROL- (7.1%-8%)
		POOR CONTROL- (>8%)

**Alert:** - Poor control may develop long term complications such as Retinopathy, Nephropathy, Neuropathy and Cardiopathy etc.

**Comment:** - MBG is a value calculated from HbA1c and indicator of average more or less glucose Level over past three months.

DR. APARNA MONDAL.  
M.B.B.S., M.D (Pathology)  
(Regd. No. 57881)



PATIENT ID: 2021I3331 NAME: SNEHA SHARMA AGE: 24 YR FEMALE  
ADVISED BY: Dr. M.O. BANK OF BARODA, .  
DATE OF RECEIPT : 08/09/2021 DELIVERY DATE : 08/09/2021 TIME : 07:00 PM

## URINE ROUTINE EXAMINATION

### PHYSICAL EXAMINATION

Colour : STRAW  
S.P. Gravity : 1.010  
Appearance : CLEAR  
Sediment : NIL


### CHEMICAL EXAMINATION

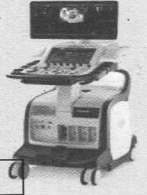pH : 6.0  
Protein : NIL  
Sugar : NIL  
Blood : NIL

### MICROSCOPICAL EXAMINATION

R.B.C : NIL  
Pus Cells : 1-2/HPF  
Epithelial Cells : 2-3/HPF  
Casts : NOT FOUND  
Crystals : NOT FOUND  
Bacteria : NOT FOUND  
Others : NOT FOUND

All Reference ranges are age and sex matched. Reference limit mentioned herein are in accordance with the literature provided along with the kit. Which may change in chemistry or the kit.

  
DR. APARNA MONDAL.  
M.B.B.S., M.D (Pathology)  
(Regd. No. 57881)



PATIENT'S NAME: - SNEHA SHARMA      AGE:- 24 YRS      SEX:- FEMALE  
REFERRED BY DR: - M.O.BANK OF BARODA.      DATE:- 09-09-2021

## Transthoracic Echo 2-D/M-Mode, Echo Report

### 2-D/ M-Mode Measurements :( mm.)

	Observed Values(mm)	Normal Values(mm)
Aortic root diameter	28.12	20 -36 mm
Left Atrium Size	34.20	19 - 40 mm

	End Diastolic(mm)	End Systolic(mm)	Normal Values(mm)
Interventricular Septum	9.88	18.24	ED=6-10
Left Ventricle Size	49.40	30.40	ED=37-53; ES=22-40
Posterior Wall Thickness	9.88	14.44	ED=5-10

LV Ejection Fraction (%)	68.56%	55 - 80%
--------------------------	--------	----------

### ❖ FINDINGS :-

1. No LV Regional Wall Motion Abnormality, Global LVEF is 68.56%.
2. Normal Cardiac chambers dimension.
3. All valves normal.
4. Normal L.V. Compliance.
5. No intracardiac clot/veg.
6. No pericardial effusion.
7. Normal RV systolic function.

### ❖ IMPRESSION

**NORMAL 2D ECHO CARDIOGRAPHY.**

**DR. KAUSHIK SUR.**  
**(M.B.B.S., M.D., D.M)**  
**(Sr. Consultant Interventional Cardiologist**  
**(Regd.No:- WB-62545)**



PATIENT'S NAME :- SNEHA SHARMA

AGE:- 24 YEAR SEX:- FEMALE

REF BY DR:- BANK OF BARODA.

DATE:- 09-09.2021

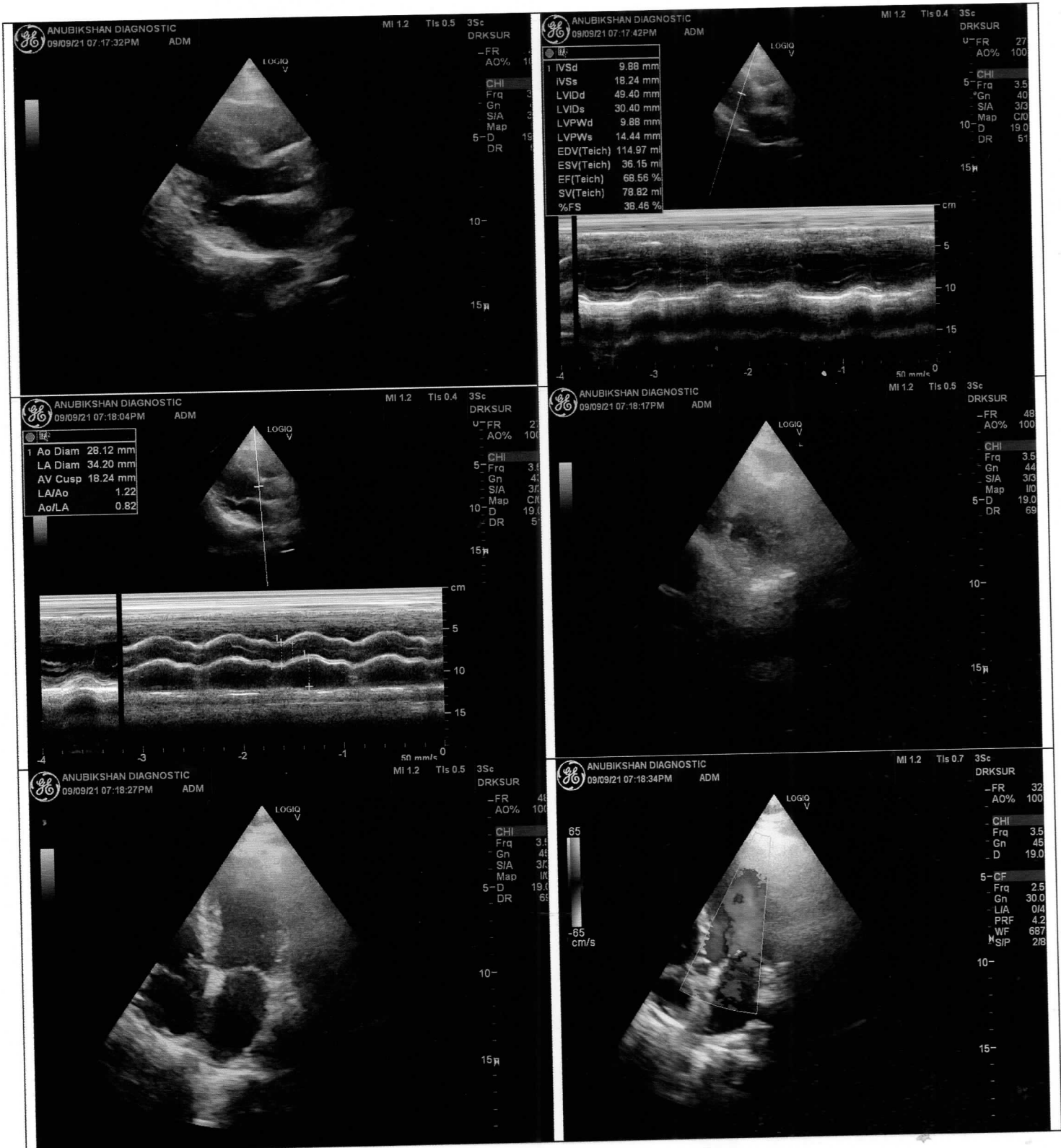
2D ECHO DONE BY:- DR. KAUSHIK SUR, (M.D, D.M)

# ANUBIKSHAN DIAGNOSTIC CENTRE

NEAR ASANSOL DISTRICT HOSPITAL ( MAIN GATE )  
S.B.GORAI ROAD (EAST), PIN - 713301

LANDLINE: - 0341-3590332 // MOB - 7872772680

E- mail ID: - anubikshan.dc @ gmail.com





# ANUBIKSHAN

Diagnostic Centre

Near Asansol District Hospital(Main Gate)  
S.B. Gorai Road, Asansol-713301  
Email ID : anubikshan.dc@gmail.com  
Ph. : 0341-2221195, M. : 9732362727, 7872772680



## ECG FORMAT

PATIENT NAME:- SNEHA SHARMA

AGE:- 24 YRS

GENDER:- FEMALE

REF BY DR: - M.O.BANK OF BARODA.

DATE:- 08.09.2021

- ❖ RATE :- 74
- ❖ AXIS :- Normal
- ❖ P-WAVE :- Normal
- ❖ P-R :- Normal
- ❖ QRS :- Normal
- ❖ ST-T :- No change
- ❖ T-WAVE :-

➤ IMPRESSION :- Normal sinus rhythm

❖ ADVICE :-

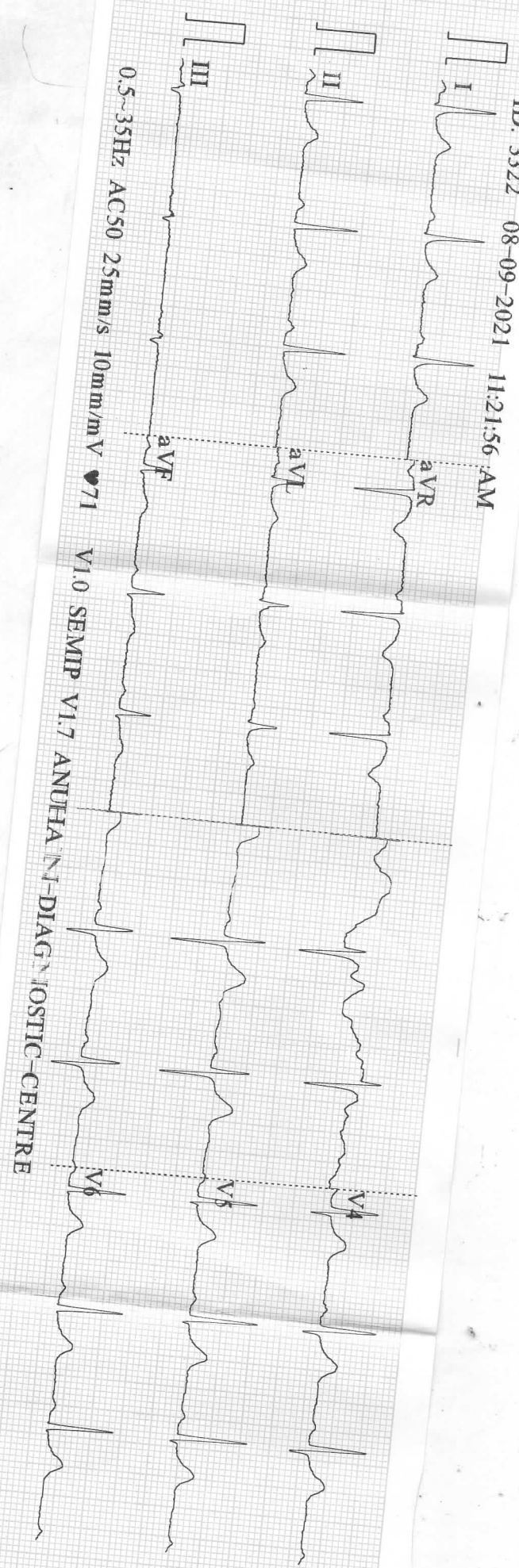
Dr. SUNIL GUPTA  
MBBS MD (Medicine)  
Reg No WBMC 48372

*[Signature]*  
Dr. S. Gupta  
48372 WB

Dr. SUNIL GUPTA  
MBBS MD (Medicine)  
Reg No WBMC 48372

BpL

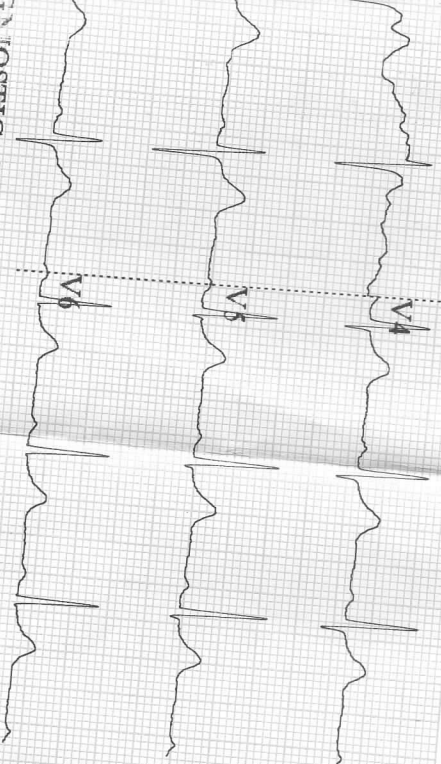
ID: 3322 08-09-2021 11:21:56 AM



Capitol

DIAGNOSTIC CENTRE

PAPER 12



P 3322

male / mmHg  
 47 years / kg  
 cm

R	:	72	bpm
r	:	101	ms
RS	:	156	ms
	:	75	ms
QTc	:	372/410	ms
QRST	:	38/29/35	ms
M/SV1	:	1.115/0.784	mV

BPL  
 Minnesota Code:  
 9-4-1

Diagnosis Information:  
 Sinus Rhythm  
 \*\*\*Normal ECG\*\*\*

SNEHA SHARMA - 24 / R  
 M.O. Bank of Baroda  
 8/9/2021

Stela Sharma  
 Report Confirmed by: