

## MEDICAL SUMMARY

NAME:	MR. NAVNEET MISHRA	UHID:	221116
AGE:	31 yrs.	Date of Health Check:	04/04/23
GENDER:	Male.	Date of Post Consultation:	

Height:	178 cm	Marital status:	
Weight:	68 kg	No. of Children:	

C/o: - no fresh complaints

K/C/O:

Present Medication: /nil

P/M/H:

-nil

P/S/H:

- nil

r/A : Smoking -

no

Alcohol -

occ.

Tobacco/Pan -

no

Family History: Father -

eu (thyroid)

Mother -

ea (thyroid - tumor)

O/E:

Lymphadenopathy:

BP: 110/70 mmHg

Pulse: 72/min

Pallor/Icterus/Cynosis/Clubbing:

/nil

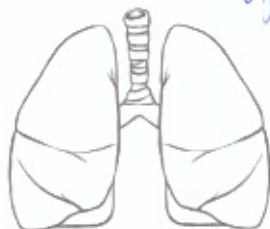Temperature: Norm

Scars: no

Oedema:

S/E:

RS: ABBG



P/A: - soft

- normal



CVS: S2 @

Extremities & Spine:

CNS: -

ENT:

Skin: -

Vision :

	Without Glass		With Glass	
	Right Eye	Left Eye	Right Eye	Left Eye
Far				
Near				
Colour Vision				
Advise				





Indira Health And Lifestyle Private Limited.  
**NABL Accredited Laboratory**  
"Xtrium", Ground Floor, Next to Holy Family Church,  
Andheri - Kurla Road, Chakala, Andheri (East), Mumbai - 400 093.  
Tel.: +91 22 46105555, Mob.: 98200 87235  
E: andherieast@apolloclinic.com



Name	: Mr. Navneet Mishra	Gender	: Male	Age	: 31 Years
UHID	: AM10.221116	Bill No	: ACR128782	Lab No:	A-368-12
Ref. by	: SELF	Sample Col.Dt	: 04/04/2023 09:55		
Barcode No	: 1353	Reported On	: 04/04/2023 19:39		

**TEST**

**RESULTS**

**Blood Grouping (ABO & Rh)-WB(EDTA) Serum**

ABO Group:	<b>:B:</b>
Rh Type:	<b>Positive</b>
Method :	Tube Agglutination (forward and reverse)

**Anushka Chavan**  
Entered By

**Ms Kaveri Gaonkar**  
Verified By

**Dr. Milind Patwardhan**  
M.D(Path)  
Chief Pathologist

End of Report  
*Results are to be correlated clinically*



Indira Health And Lifestyle Private Limited.  
**NABL Accredited Laboratory**  
"Xtrium", Ground Floor, Next to Holy Family Church,  
Andheri - Kurla Road, Chakala, Andheri (East), Mumbai - 400 093.  
Tel.: +91 22 46105555, Mob.: 98200 87235  
E: andherieast@apolloclinic.com



Name : Mr. Navneet Mishra      Gender : Male      Age : 31 Years  
UHID : AM10.221116      Bill No : ACR128782      Lab No: A-368-12  
Ref. by : SELF      Sample Col.Dt : 04/04/2023 09:55  
Barcode No : 1353      Reported On : 04/04/2023 19:40

TEST	RESULTS	UNITS	BIOLOGICAL REFERENCE INTERVAL
<b>PLASMA GLUCOSE</b>			
Fasting Plasma Glucose :	99	mg/dL	Normal < 100 mg/dL Impaired Fasting glucose : 101 to 125 mg/dL Diabetes Mellitus : $\geq$ 126 mg/dL (on more than one occasion) (American diabetes association guidelines 2016)
Post Prandial Plasma Glucose :	80	mg/dL	Normal < 140 mg/dL Impaired Post Prandial glucose : 140 to 199 mg/dL Diabetes Mellitus : $\geq$ 200 mg/dL (on more than one occasion) (American diabetes association guidelines 2016)

Method : Hexokinase

Vasanti Gondal  
Entered By

Ms Kaveri Gaonkar  
Verified By

  
Dr. Milind Patwardhan  
M.D(Path)  
Chief Pathologist

End of Report  
Results are to be correlated clinically







Indira Health And Lifestyle Private Limited.  
**NABL Accredited Laboratory**  
"Xtrium", Ground Floor, Next to Holy Family Church,  
Andheri - Kurla Road, Chakala, Andheri (East), Mumbai - 400 093.  
Tel.: +91 22 46105555, Mob.: 98200 87235  
E: andherieast@apolloclinic.com



Name : Mr. Navneet Mishra                      Gender : Male                      Age : 31 Years  
UHID : AM10.221116                      Bill No : ACR128782                      Lab No: A-368-12  
Ref. by : SELF                      Sample Col.Dt : 04/04/2023 09:55  
Barcode No : 1353                      Reported On : 04/04/2023 19:40

TEST                      RESULTS                      UNITS                      BIOLOGICAL REFERENCE INTERVAL

**LFT(Liver Function Tests)-Serum**

S.Total Protein (Biuret method)	8.38	g/dL	6.6 - 8.7
S.Albumin (BCG method)	5.20	g/dL	3.5 - 5.2
S.Globulin (Calculated)	3.18	g/dL	2 - 3.5
S.A/G Ratio:(Calculated)	1.64		0.9 - 2
S.Total Bilirubin (DPD):	0.88	mg/dL	0.1 - 1.2
S.Direct Bilirubin (DPD):	<b>0.31</b>	mg/dL	0.1 - 0.3
S.Indirect Bilirubin (Calculated)	0.57	mg/dL	0.1 - 1.0
S.AST (SGOT)(IFCC Kinetic with P5P):	38	U/L	5 - 40
S.ALT (SGPT) (IFCC Kinetic with P5P):	<b>44</b>	U/L	5 - 41
S.Alk Phosphatase(pNPP-AMP Kinetic):	<b>134</b>	U/L	40 - 129
S.GGT(IFCC Kinetic):	11	U/L	11 - 50

Vasanti Gondal  
Entered By

Ms Kaveri Gaonkar  
Verified By

  
Dr. Milind Patwardhan  
M.D(Path)  
Chief Pathologist

End of Report  
Results are to be correlated clinically



Indira Health And Lifestyle Private Limited.  
**NABL Accredited Laboratory**  
"Xtrium", Ground Floor, Next to Holy Family Church,  
Andheri - Kurla Road, Chakala, Andheri (East), Mumbai - 400 093.  
Tel.: +91 22 46105555, Mob.: 98200 87235  
E: ancherieast@apolloclinic.com



Name : Mr. Navneet Mishra      Gender : Male      Age : 31 Years  
UHID : AM10.221116      Bill No : ACR128782      Lab No: A-368-12  
Ref. by : SELF      Sample Col.Dt : 04/04/2023 09:55  
Barcode No : 1353      Reported On : 04/04/2023 19:39

TEST	RESULTS	UNITS	BIOLOGICAL REFERENCE INTERVAL
<b>RFT - Renal Profile-serum</b>			
S.Urea(Urease-GLDH)	15.3	mg/dL	10.0 - 45.0
S. Urea Nitrogen( Calculated)	7.14	mg/dL	5 - 20
S.Creatinine(Jaffe's Kinetic)	0.73	mg/dL	0.50 - 1.3
S.Uric Acid(Uricase-POD)	6.8	mg/dL	3.4 - 7.0
S.Total Protein(Biuret)	8.38	g/dL	6.6 - 8.7
S.Albumin(BCG)	5.20	g/dL	3.5 - 5.2
S.Globulin(Calculated)	3.18	g/dL	2 - 3.5
A/G Ratio(Calculated)	1.64		0.9 - 2
S.Sodium(Na) (ISE-Direct)	140	mmol/L	135 - 145
S.Potassium(K) (ISE-Direct)	4.8	mmol/L	3.5 - 5.3
S.Chloride(Cl) (ISE-Direct)	101	mmol/L	95 - 106
S.Calcium(NM-BAPTA)	10.0	mg/dL	8.6 - 10.0
S.Phosphorus(UV Phosphomolybdate)	2.65	mg/dL	2.5 - 4.5

Ms Kaveri Gaonkar  
Entered By

Ms Kaveri Gaonkar  
Verified By

Dr. Milind Patwardhan  
M.D(Path)  
Chief Pathologist

End of Report  
Results are to be correlated clinically



Indira Health And Lifestyle Private Limited.  
**NABL Accredited Laboratory**  
"Xtrium", Ground Floor, Next to Holy Family Church,  
Andheri - Kurla Road, Chakala, Andheri (East), Mumbai - 400 093.  
Tel.: +91 22 46105555, Mob.: 98200 87235  
E: andherieast@apolloclinic.com



Name : Mr. Navneet Mishra      Gender : Male      Age : 31 Years  
UHID : AM10.221116      Bill No : ACR128782      Lab No: A-368-12  
Ref. by : SELF      Sample Col.Dt : 04/04/2023 09:55  
Barcode No : 1353      Reported On : 04/04/2023 14:22

TEST      RESULTS      UNITS      BIOLOGICAL REFERENCE INTERVAL

**Lipid Profile- Serum**

S. Cholesterol(Oxidase)	195	mg/dL	Desirable < 200 Borderline: >200-<240 Undesirable: >240
S. Triglyceride(GPO-POD)	119	mg/dL	Desirable < 150 Borderline: >150-<499 Undesirable: >500
S. VLDL:(Calculated)	23.8	mg/dL	Desirable <30
S. HDL-Cholesterol(Direct)	56	mg/dL	Desirable > 60 Borderline: >40-<59 Undesirable: <40
S. LDL:(calculated)	115.2	mg/dL	Desirable < 130 Borderline: >130-<159 Undesirable: >160
Ratio Cholesterol/HDL	3.5		3.5 - 5
Ratio of LDL/HDL	<b>2.1</b>		2.5 - 3.5

Vasanti Gondal  
Entered By

Ms Kaveri Gaonkar  
Verified By

Dr. Milind Patwardhan  
M.D(Path)  
Chief Pathologist

End of Report  
Results are to be correlated clinically





Indira Health And Lifestyle Private Limited.  
**NABL Accredited Laboratory**  
"Xtrium", Ground Floor, Next to Holy Family Church,  
Andheri - Kurla Road, Chakala, Andheri (East), Mumbai - 400 093.  
Tel.: +91 22 46105555, Mob.: 98200 87235  
E: andherieast@apolloclinic.com



Name : Mr. Navneet Mishra      Gender : Male      Age : 31 Years  
UHID : AM10.221116      Bill No : ACR128782      Lab No: A-368-12  
Ref. by : SELF      Sample Col.Dt : 04/04/2023 09:55  
Barcode No : 1353      Reported On : 04/04/2023 14:22

**TEST      RESULTS      UNITS      BIOLOGICAL REFERENCE INTERVAL**

**Thyroid (T3,T4,TSH)- Serum**

Total T3 (Tri-iodo Thyronine) (ECLIA)	1.97	nmol/L	1.3 - 3.1 nmol/L
Total T4 (Thyroxine) (ECLIA)	89.95	nmol/L	66 - 181 nmol/L
TSH-Ultrasensitive (Thyroid-stimulating hormone) Method : ECLIA	1.79	µIU/ml	Euthyroid :0.35 - 5.50 µIU/ml Hyperthyroid : < 0.35 µIU/ml Hypothyroid : > 5.50 µIU/ml

Grey zone values observed in physiological/therapeutic effect.

**Note:**

**T3 :**

1. Decreased values of T3 (T4 and TSH normal) have minimal Clinical significance and not recommended for diagnosis of hypothyroidism.
2. Total T3 and T4 values may also be altered in other conditions due to changes in serum proteins or binding sites ,Pregnancy, Drugs (Androgens,Estrogens,O C pills, Phenytoin) etc. In such cases Free T3 and free T4 give corrected Values.
3. Total T3 may decrease by < 25 percent in healthy older individuals

**T4 :**

1. Total T3 and T4 Values may also be altered in other condition due to changes in serum proteins or binding sites, Pregnancy Drugs (Androgens,Estrogens,O C pills, Phenytoin), Nerphrosis etc. In such cases Free T3 and Free T4 give Corrected values.

**TSH :**

1. TSH Values may be transiently altered because of non thyroidal illness like severe infections,liver disease, renal and heart failure. Severe burns, trauma and surgery etc.
2. Drugs that decrease TSH values e,g L dopa, Glucocorticoids.
3. Drugs that increase TSH values e.g. Iodine,Lithium, Amiodarone

Vasanti Gondal  
Entered By

Ms Kaveri Gaonkar  
Verified By

Dr. Milind Patwardhan  
M.D(Path)  
Chief Pathologist

End of Report  
Results are to be correlated clinically





31 Years Male

Location: Room: Order Number: Indication: Medication 1: Medication 2: Medication 3:

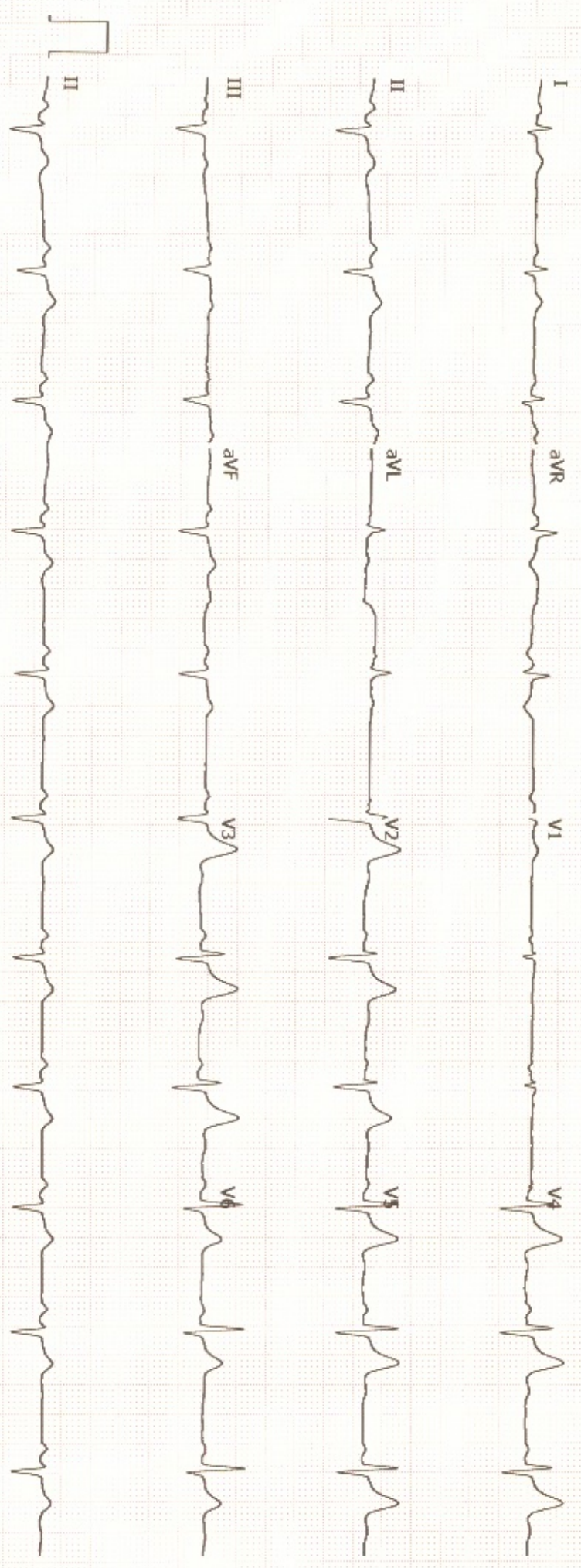
Technician: Ordering Ph: Referring Ph: Attending Ph:

66 bpm -- / -- mmHg

QRS : 88 ms  
QT / QTcBaz : 366 / 383 ms  
PR : 140 ms  
P : 94 ms  
RR / PP : 908 / 909 ms  
P / QRS / T : 55 / -76 / 47 degrees

Normal sinus rhythm  
Left axis deviation  
Abnormal ECG

Dr DINESH ROHIRA  
Echocardiologist  
DNB (Internal Medicine)  
Reg No. 2008/04/0837



GE MAC2000 1.1 12SL™ V241 25 mm/s 10 mm/mV ADS 0.5v-20 Hz 50 Hz 4x2.5x3\_25\_R1

Unconfirmed

Name : Mr Navneet Mishra      Gender : Male      Age : 31 Years  
 UHID : AM10.0000221116      Bill No : ACR128782      Lab No :  
 Ref. by : Self      Date : 04-Apr-2023      Time : 12:37 PM

**Echo (Color Doppler)**

DIMENSIONS	VALUES (RANGE)	DIMENSIONS	VALUES (RANGE)
AO (ed)	25mm	IVS (ed)	9mm
LA (es)	32mm	LVPW (ed)	9mm
RVID (ed)	20mm	EF	60%
LVID (ed)	45mm	EPSS	3mm
LVID (es)	26mm		

**MORPHOLOGICAL DATA**

**Mitral Valve**

AML      Normal  
 PML      Normal  
**Aortic Valve**      Normal  
**Tricuspid Valve**      Normal  
**Pulmonary Valve**      Normal  
**Right Ventricle**      Normal  
 Left ventricle      Normal  
**Interatrial Septum**      Intact  
**Interventricular Septum**      Intact  
**Pulmonary Artery**      Normal  
**Aorta**      Normal



---

Name : Mr Navneet Mishra      Gender : Male      Age : 31  
UHID : AM10.0000221116      Bill No : ACR128782      Lab No :  
Ref. by : Self      Date : 04-Apr-2023      Time : 12:37 PM

---

**Right Atrium**      Normal  
**Left Atrium**      Normal  
**LV - RWMA**      Normal  
**LV - FUNCTION**      Normal  
**Pericardium**      Normal  
**Doppler Studies**      Normal  
**IMPRESSION :**      **Normal LV and RV Systolic Function LVEF=60%**



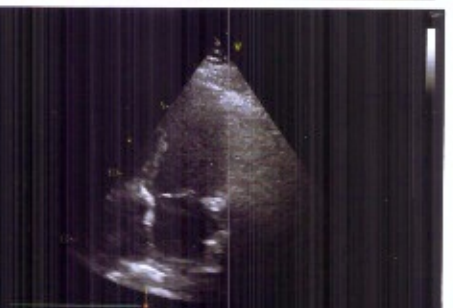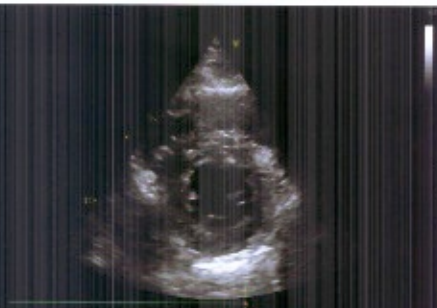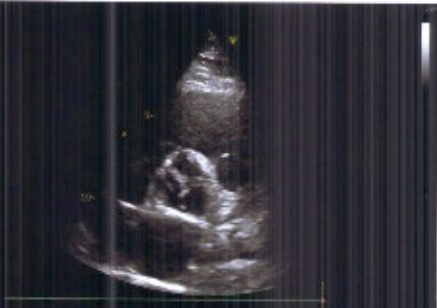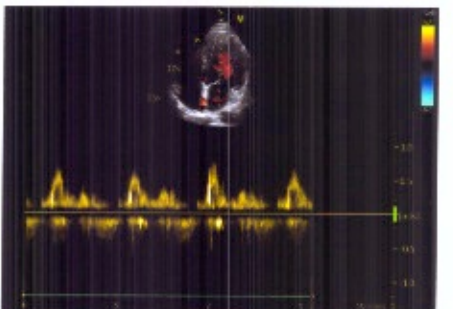
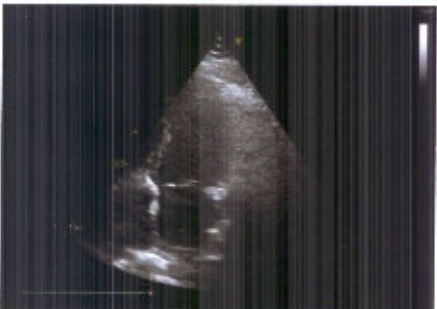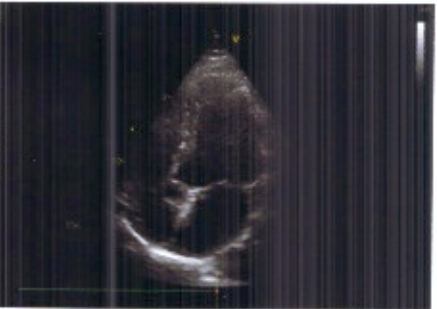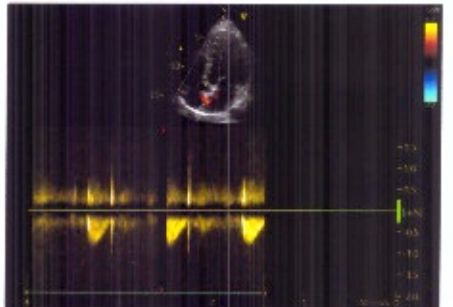
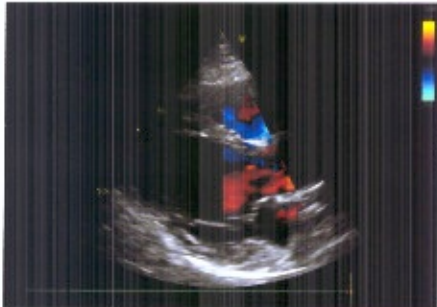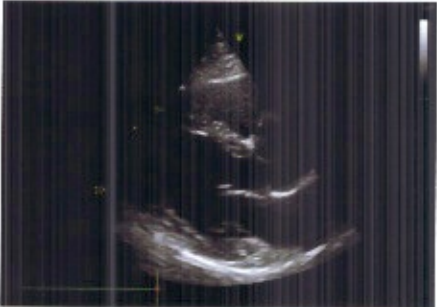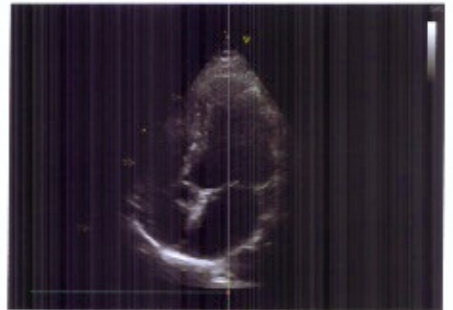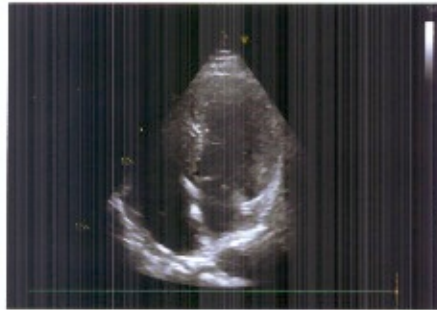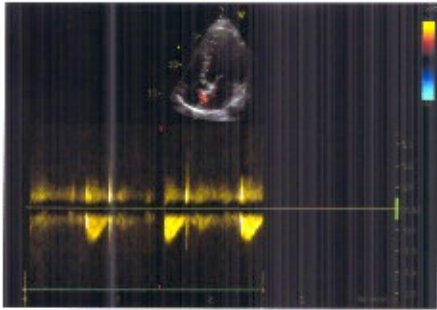
Dr. Dinesh Rohira  
Consultant - D.N.B. (Medicine)

# Apollo Clinic

Xtrim Ground Floor, Next to Holy Family Church,  
Andheri (E).

Patient ID: 2023Ap0021  
Name: MR NAVNEET MISHRA  
Sex: M

Date: 04-Apr-2023



Ultrasound

Name : Mr Navneet Mishra      Gender : Male      Age : 31 Years  
UHID : AM10.0000221116      Bill No : ACR128782 Lab No :  
Ref. by : Self      Date : 04-Apr-2023 Time : 01:00 PM

Ultrasound Whole Abdomen (Male)

LIVER : Liver is normal in size and echotexture. No focal intra-hepatic lesion detected. Intra-hepatic biliary radicals are not dilated. Portal vein and CBD appear normal in calibre.

GALL BLADDER : Physiologically well distended Gall bladder is seen with normal wall thickness. No evidence of any calculus or abnormal mass lesion seen.

PANCREAS : Pancreas is normal in size and echotexture.

SPLEEN : Spleen is normal in size & echotexture.

Aorta and IVC appear normal in course and calibre.


KIDNEYS : Both Kidneys are normal in size, position, have smooth outlines and show a uniform parenchymal echogenicity. The cortico-medullary ratio is well maintained. There is no evidence of any calculi or Pelvi-calyceal dilatation seen on either side. No abnormal focal mass lesions seen.  
Rk: 10.9 x 4.3 cms Lk : 10.9 x 4.8 cms

The Urinary Bladder is well distended. Its walls show a smooth outline. There is no evidence of any intraluminal or perivesical abnormality.

PROSTATE : Prostate is normal in size and echo-texture. No focal lesion seen.

No free fluid or lymphadenopathy seen.

IMPRESSION : Normal sonography of abdomen and pelvis



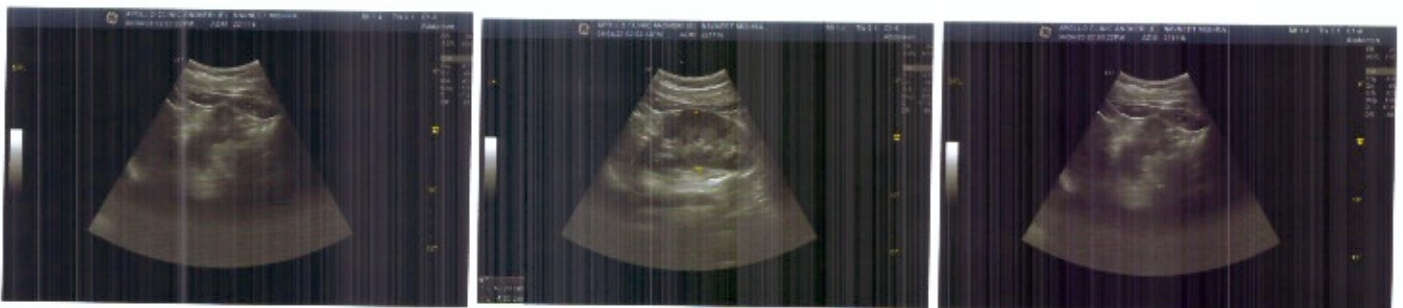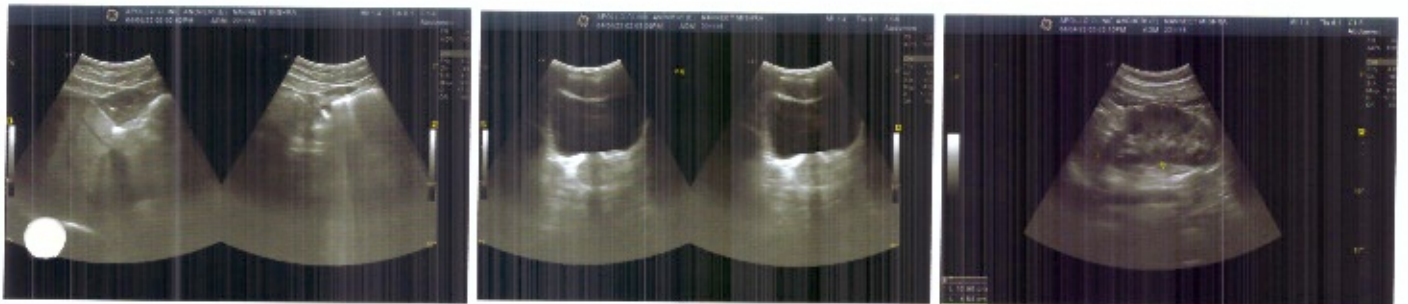
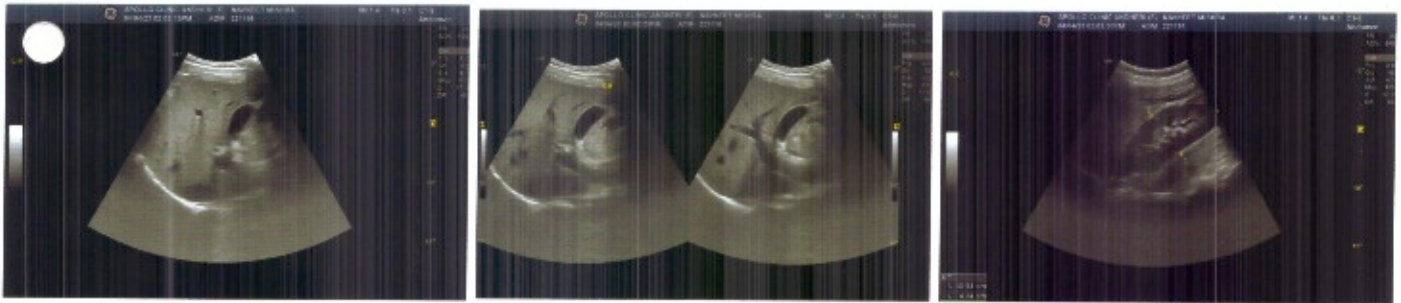Dr. Anagha Shetty  
Consultant Radiologist



**Apollo Clinic**  
Xtrim Ground Floor, Next to Holy Family Church,  
Andheri (E).

Patient ID: 221116  
Name: NAVNEET MISHRA  
Sex: M

Date: 04-Apr-2023





Name : Mr Navneet Mishra

Gender : Male Age : 31 Years

UHID : AM10.0000221116

Bill No : ACR128782 Lab No :

Ref. by : Self

Date : 04-Apr-2023 Time : 02:37 PM

Xray Chest PA

Both lung fields do not reveal any significant pulmonary parenchymal lesion.

Both costophrenic and cardiophrenic angles are clear.

Both hila appear normal.


Cardiac size is within normal limits.

Both the domes of diaphragm appear normal in contour and position.

Visualised bony thorax and dorsal spine appear normal.

IMPRESSION : Normal x-ray chest.

Note: Findings in Chest Xray are affected by many factors. Any findings on Chest Xray need to be confirmed by Chest CT.



Dr. Anagha Shetty  
Consultant Radiologist

# APOLLO CLINIC

Andheri - East

Date 04/04/23

Patient Name MR. NAVNEET MISHRA

Age 31y Sex M.

Complaints : Dryness @.

Visual Acuity :

	RE	LE
Distant - Unaided	6/6	6/6
With Glasses		
Near Vision	N6	N6

Slit Lamp Examination : (B) APS-wm

Application Tonometry : Applanation :

Colour Vision : Normal

Fundus Examination through undilated pupil :

Media -  
Cup / Disc Ratio -  
Shape -  
Colour -  
Margins -  
Macula -  
Vessels -  
Periphery -

(B) OD - 0.3  
mild  
Mac-RPE changes

Impression : (B) wsm

Rx (B) locally  
① Refresh tear eyedrop  
2 times/day x 1mth



# APOLLO CLINIC


Andheri - East

Date 4/4/2023

Patient Name Navneet Mishra

Age 31 Sex M

For ENT Check - Up		
	RIGHT	LEFT
Ears -		
Tympanic Membrane -		
	Ⓜ	Ⓜ
Tuning Fork Test -		
Rinnes -	+	+
Weber -	→	
Nose -	Ⓜ	
Throat -	Ⓜ	
Remarks -	C/N	

  
Dr. Anita Babiwale  
M.S. (ENT) DLO  
Consultant ENT Surgeon  
Regn. No. 2009/10/3551

NABL Accredited : The highest Quality Certification for Medical Laboratories in our country  
Consultation • Diagnostics • Health Check-Ups • Dentistry • Skin Clinic • Weight Loss Clinic

Name: MR. NAVNEET MISHRA

Age: 31 yr

Date of Health Check: 02/04/23

## DENTAL EXAMINATION

Scaling & Polishing : \_\_\_\_\_

Fillings : \_\_\_\_\_

Root Canal : \_\_\_\_\_

Extraction : \_\_\_\_\_

Replacement of Missing Teeth : \_\_\_\_\_

Any other Remarks : \_\_\_\_\_

Doctor's Sign & Stamp :

### Findings and Recommendation :

no significant abnormality detected

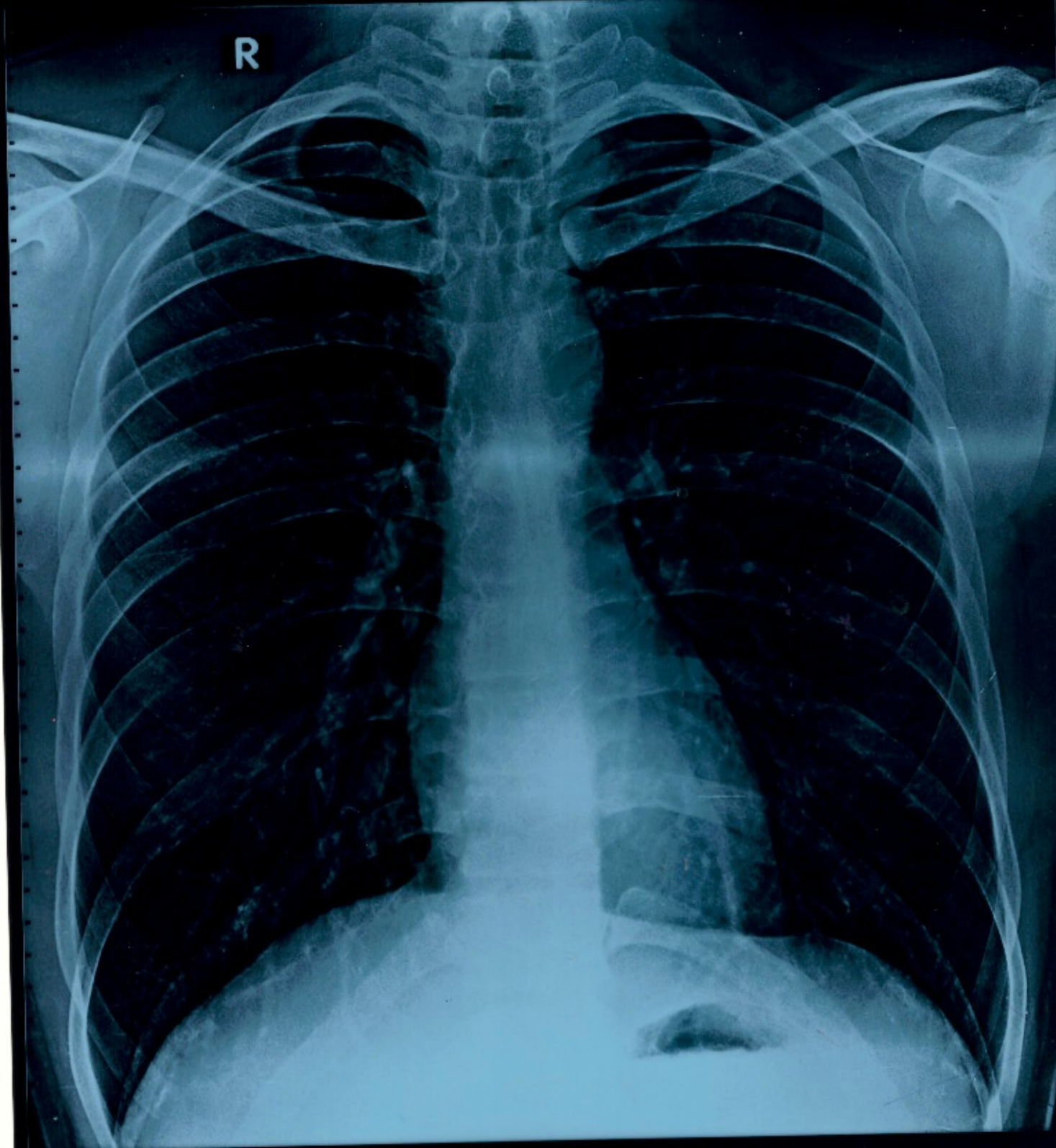Recommendation

— Follow regular diet & exercise.



Signature:  
Consultant - Internal Medicine





221116 MR. NAVNEET MISHRA 31Y M CHEST PA 04-Apr-23  
APOLLO CLINIC